

**ACCUTANE—IS THIS ACNE DRUG TREATMENT
LINKED TO DEPRESSION AND SUICIDE?**

HEARING
BEFORE THE
**COMMITTEE ON
GOVERNMENT REFORM**
HOUSE OF REPRESENTATIVES
ONE HUNDRED SIXTH CONGRESS
SECOND SESSION

DECEMBER 5, 2000

Serial No. 106-248

Printed for the use of the Committee on Government Reform



Available via the World Wide Web: <http://www.gpo.gov/congress/house>
<http://www.house.gov/reform>

U.S. GOVERNMENT PRINTING OFFICE

73-924 DTP

WASHINGTON : 2001

For sale by the Superintendent of Documents, U.S. Government Printing Office
Internet: bookstore.gpo.gov Phone: (202) 512-1800 Fax: (202) 512-2250
Mail: Stop SSOP, Washington, DC 20402-0001

COMMITTEE ON GOVERNMENT REFORM

DAN BURTON, Indiana, *Chairman*

BENJAMIN A. GILMAN, New York	HENRY A. WAXMAN, California
CONSTANCE A. MORELLA, Maryland	TOM LANTOS, California
CHRISTOPHER SHAYS, Connecticut	ROBERT E. WISE, JR., West Virginia
ILEANA ROS-LEHTINEN, Florida	MAJOR R. OWENS, New York
JOHN M. McHUGH, New York	EDOLPHUS TOWNS, New York
STEPHEN HORN, California	PAUL E. KANJORSKI, Pennsylvania
JOHN L. MICA, Florida	PATSY T. MINK, Hawaii
THOMAS M. DAVIS, Virginia	CAROLYN B. MALONEY, New York
DAVID M. McINTOSH, Indiana	ELEANOR HOLMES NORTON, Washington,
MARK E. SOUDER, Indiana	DC
JOE SCARBOROUGH, Florida	CHAKA FATTAH, Pennsylvania
STEVEN C. LATOURETTE, Ohio	ELIJAH E. CUMMINGS, Maryland
MARSHALL "MARK" SANFORD, South	DENNIS J. KUCINICH, Ohio
Carolina	ROD R. BLAGOJEVICH, Illinois
BOB BARR, Georgia	DANNY K. DAVIS, Illinois
DAN MILLER, Florida	JOHN F. TIERNEY, Massachusetts
ASA HUTCHINSON, Arkansas	JIM TURNER, Texas
LEE TERRY, Nebraska	THOMAS H. ALLEN, Maine
JUDY BIGGERT, Illinois	HAROLD E. FORD, JR., Tennessee
GREG WALDEN, Oregon	JANICE D. SCHAKOWSKY, Illinois
DOUG OSE, California	
PAUL RYAN, Wisconsin	BERNARD SANDERS, Vermont
HELEN CHENOWETH-HAGE, Idaho	(Independent)
DAVID VITTER, Louisiana	

KEVIN BINGER, *Staff Director*

DANIEL R. MOLL, *Deputy Staff Director*

JAMES C. WILSON, *Chief Counsel*

ROBERT A. BRIGGS, *Clerk*

PHIL SCHILIRO, *Minority Staff Director*

CONTENTS

	Page
Hearing held on December 5, 2000	1
Statement of:	
Callais, Lori and Amanda, Denham Springs, LA; Stacy and Mike Baumann, Mundelein, IL; and Charles H. Jackson, Jr., Lubbock, TX	6
Pariser, David M., M.D., FACP, American Academy of Dermatology, Pariser dermatology specialist, Ltd., Virginia Clinical Research, Inc., Norfolk, VA; Douglas Jacobs, M.D., Roche consultant, associate clinical professor of psychiatry, Harvard Medical School, Wellesley, MA; James T. O'Donnell, PHARMD., M.S., assistant professor of pharmacology, Rush Medical School, Palletine, IL; and Jonca Bull, M.D., Food and Drug Administration, accompanied by Phyllis Huene, M.D.	44
Letters, statements, etc., submitted for the record by:	
Baumann, Mike, Mundelein, IL, prepared statement of	19
Baumann, Stacy, Mundelein, IL, prepared statement of	24
Bull, Jonca, M.D., Food and Drug Administration, prepared statement of	100
Callais, Amanda, Denham Springs, LA, prepared statement of	14
Callais, Lori, Denham Springs, LA, prepared statement of	9
Jackson, Charles H., Jr., Lubbock, TX, prepared statement of	32
Jacobs, Douglas, M.D., Roche consultant, associate clinical professor of psychiatry, Harvard Medical School, Wellesley, MA, prepared state- ment of	61
O'Donnell, James T., PHARMD., M.S., assistant professor of pharmacol- ogy, Rush Medical School, Palletine, IL, prepared statement of	73
Pariser, David M., M.D., FACP, American Academy of Dermatology, Pariser dermatology specialist, Ltd., Virginia Clinical Research, Inc., Norfolk, VA, prepared statement of	49

ACUTANE—IS THIS ACNE DRUG TREATMENT LINKED TO DEPRESSION AND SUICIDE?

TUESDAY, DECEMBER 5, 2000

HOUSE OF REPRESENTATIVES,
COMMITTEE ON GOVERNMENT REFORM,
Washington, DC.

The committee met, pursuant to notice, at 1 p.m., in room 2154, Rayburn House Office Building, Hon. Dan Burton (chairman of the committee) presiding.

Present: Representatives Burton, Morella, Horn, Mica, Waxman, Norton, and Kucinich.

Staff present: Kevin Binger, staff director; Daniel R. Moll, deputy staff director; James C. Wilson, chief counsel; David A. Kass, deputy counsel and parliamentarian; Sean Spicer, director of communications; S. Elizabeth Clay and Nicole Petrosino, professional staff members; Robert A. Briggs, chief clerk; Michael Canty and Toni Lightle, legislative assistants; Josie Duckett, deputy communications director; Leneal Scott, computer systems manager; John Sare, deputy chief clerk, Corinne Zaccagnini, systems administrator; Phil Schiliro, minority staff director; Kristin Amerling, minority deputy chief counsel; Kate Anderson and Sarah Despres, minority counsels; Ellen Rayner, minority chief clerk; and Jean Gosa and Earley Green, minority assistant clerks.

Mr. BURTON. Good afternoon. A quorum being present, the Committee on Government Reform will come to order.

I ask unanimous consent that all Members' and witnesses' written opening statements be included in the record. Without objection, so ordered.

I ask unanimous consent that all articles, exhibits, and extraneous or tabular material referred to be included in the record. Without objection, so ordered.

We are here today to talk about the acne medication Accutane and concerns that the drug is linked to depression and suicide.

Accutane was licensed by the Food and Drug Administration in 1982 as an oral prescription drug for the treatment of severe acne. Current recommendations indicate that the drug should only be used when a patient has not responded to other treatments including antibiotics.

During the course of our investigation, we were told by the dermatologists that while the drug has many severe side effects, that there is no other treatment available. However, we also learned that many individuals have been prescribed this drug for less severe forms of acne. I am attaching for the record an article outlining natural treatments for acne.

The most well-known adverse effect attributed to Accutane is birth defects of the children born to women who take the drug during pregnancy. However, we will focus today's hearing on the mental health issues. Did the Department of Health and Human Services fulfill its public safety obligation in making the public aware of the potential for depression and suicide related to this drug?

A significant number of psychiatric events, mostly severe depression, have been reported through post-marketing surveillance. The FDA has received reports of 66 suicides and 1,373 psychiatric adverse events other than suicide related to Accutane.

According to Roche Pharmaceuticals, the manufacturer of Accutane, the number of domestic and foreign reports of serious adverse events in the post-marketing adverse events data base for Accutane as of April 30 was 5,665. The largest percentage of these reports were psychiatric problems. Almost 19 percent of the adverse events reported to Roche were psychiatric.

Also, the most recent Periodic Adverse Drug Event Report for Accutane includes, for a 12-month period, over 750 new psychiatric adverse event reports, both foreign and domestic, including 200 that were coded as serious events, 9 reports of suicide attempts, and 6 reports of suicides.

Four questions arose during the course of this investigation.

When did the issue of depression and suicide first arise regarding Accutane?

What actions did Roche and the FDA take to determine if there was a causal link?

When and how was the public notified?

And, fourth, was the public notification adequate?

According to Roche, there is no evidence of increased risk of depression or suicide related to Accutane. Instead, they believe that the events reflect the multiple risk factors in the population of adolescents and young adults afflicted with the disfiguring disease of acne.

While the package insert for the Accutane contains language that warns of depression and suicide, this information is not typically provided to patients by either the physician or the pharmacist. Extensive patient education is required regarding pregnancy prevention while on Accutane because of the risk of birth defects. However, there is no system in place to educate patients and families about depression and, potentially, suicide.

We learned through our investigation that reports of depression and suicide are not new. The first report of depression in patients taking Accutane occurred in September 1982. Two patients in a clinical trial with 523 patients reported depression. Roche received five adverse experience reports of depression in 1983. In November 1983, Roche received its first report of attempted suicide. In November 1984, Roche received its first report of suicide. In May 1986, Roche received reports of five or six positive rechallenges in patients who experienced depression during Accutane therapy. In these patients, the depression went away when they stopped taking Accutane and began again after starting Accutane therapy over again. Positive rechallenge is a significant indicator of a causal link between a drug and the adverse event.

As early as November 1984, Roche began including information on the package insert about reports of depression. Even though French authorities required a label change to include “suicide attempt” in March 1997, the FDA did not require Roche to make a label change until February 1998. FDA also required that Roche notify physicians who were likely to prescribe Accutane.

In February 1998, the FDA issued a “Talk Paper” advising consumers of and health care providers of new safety information regarding Accutane; and the paper stated as follows.

Although the Accutane label already included information regarding depression as a possible adverse reaction, the agency felt health care providers and others needed additional information as a result of adverse events the agency has received. FDA and the drug manufacturer are strengthening this label warning, even though it is difficult to identify the exact cause of these problems. Patients who reported depression also reported that the depression subsided when they stopped taking the drug and came back when they resumed taking it.

What is disturbing to me is that the FDA published an article in their own consumer magazine entitled, “On the Teen Scene: Acne Agony” in July 1999. Thirty percent of the article focuses on Accutane. It goes into great detail about the pregnancy prevention because of birth defects, but it fails to make any mention of depression and suicide. This article appeared 16 months after FDA’s advisory. Why did the FDA not use its own consumer magazine to notify the public of this concern?

Today we will hear from three families.

Amanda Callais was prescribed Accutane as a 14-year-old in September 1997. By November, she was seriously depressed and attempted suicide. The psychiatrist treating her for depression was not aware of the connection between Accutane and depression and did not suspend her use of the drug after her suicide attempt. She remained seriously depressed. In February 1998, Amanda’s mother, Lori, learned of the FDA’s warning and stopped Amanda’s treatment. Amanda quickly made a full recovery. Mother and daughter are here today to share their experience.

Stacy and Mike Baumann of Mundelein, IL, lost their son Daniel to suicide in December 1999. Daniel began Accutane treatment in July 1999. He suffered many adverse effects: chapped lips, dry skin and itching, joint and muscle pain, headaches, nausea, loss of appetite, mood swings and insomnia. The physician thought this depression was school-related and never mentioned the FDA warning.

Mr. Charles Jackson of Lubbock, TX, lost his 17-year-old son Clay in January 2000. Clay had been on Accutane for about 3 months. The family was provided no information by the physician regarding the FDA warning.

Of course, we have one of our colleagues in the Congress who lost his son. Bart Stupak’s son was lost to suicide not too long ago, and he believes it was Accutane-related as well.

Accutane is only supposed to be prescribed for severe recalcitrant nodular acne after every other treatment option has failed. Dr. David Pariser of Norfolk, VA, will be testifying on behalf of the American Academy of Dermatology and providing an overview of the types of acne and when Accutane is recommended.

Dr. Douglas Jacobs, on faculty at Harvard and a Roche consultant, will present his evaluation of the adverse drug events regarding psychosis, depression and suicide and Accutane.

Dr. James O'Donnell, assistant professor of pharmacology at Rush Medical School, will present information regarding the connection between Accutane and other vitamin A derivatives and depression and suicide.

Dr. Junco Bull will testify on behalf of the FDA.

I realize that this issue will be difficult for some of you to discuss. To those families who have lost loved ones because of this or because we believe that is what caused it, our heart goes out to each and every one of you. I know it is going to be a difficult time for you today, and we really appreciate you being here. I do hope that this hearing can help resolve some of the unanswered questions so that these tragedies will be avoided in the future.

The hearing record will remain open until December 18.

I am happy to recognize my colleague from California, Mr. Waxman.

Mr. WAXMAN. Thank you, Mr. Chairman.

Mr. Chairman, today's hearing addresses an issue of great importance, and I want to begin by commending the work of Congressman Bart Stupak in this area. His tireless efforts to raise public awareness about the risks of Accutane have, I am sure, already helped many families. His efforts have also been instrumental in encouraging Hoffman-La Roche and the FDA to do more to learn about the risks of Accutane and to inform patients and families about those risks.

Accutane is a powerful and effective drug for the treatment of severe recalcitrant acne. For many acne sufferers, it is the only drug that can cure them of an otherwise scarring disease. Because of this drug's benefits, it is imperative that we understand all of its risks and fully inform patients and their families.

We already know a great deal about Accutane's risks of severe birth defects. That knowledge has provided the basis for patient education targeting women of child-bearing age. But the same is not true of the risk of psychiatric disorders, and that must be changed.

I am troubled by how little we know about the link between Accutane and psychiatric disorders. No study has proven conclusively that Accutane causes psychiatric disorders, but a great deal of evidence suggests that there may be a link. A recent FDA analysis of voluntary reports, so-called adverse event reports, found that 147 cases of suicide and hospitalized depression have been associated with Accutane since it was first introduced in 1982. Even more disturbing, evidence shows that many patients feel depressed while taking Accutane, stop feeling depressed after treatment ceases, and then feel depressed again when treatment is resumed.

Officials at FDA state that such cases "provide the best evidence to support a relationship between Accutane and psychiatric disorders." But this is not conclusive proof, and it is unacceptable that such an important question has gone unanswered for so long.

I am also troubled by the lack of information provided to patients and their families. As we will hear today, and as was the case for Congressman Stupak, many families are completely unaware that depression and suicide have been associated with Accutane. While the risk of depression has been a part of the label since 1985, the risk of suicide was not added to the label until 1998, and patients

and their families simply did not have reliable and valuable access to this information until Hoffman-La Roche changed the Accutane box in only May of this year. But this new warning is still not reaching all users, because many old boxes without the warning remain in circulation. With a risk as detrimental and tragic as suicide, it is unacceptable that patients, including many minors, and their families are not informed about it. A box warning is insufficient. Until a pamphlet specifically geared for patients is issued under the MedGuide program, they will not be fully informed.

I am heartened by some positive developments. Hoffman-La Roche has agreed to work with FDA on a patient informed consent form and the immediate guide pamphlet to warn of the risks of psychiatric disorders. Both will clearly discuss the risk of depression and suicide and will do a great deal to inform patients and their families of these grave risks. I call on FDA and Roche to implement the immediate guide and patient consent forms quickly.

Most important of all, Roche has finally agreed to fund research into the link between Accutane and psychiatric disorders. Roche will be working with both NIH and FDA on the design of this research. I want to emphasize that this research must be independent, comprehensive, and extensive enough to answer the very serious questions about the psychiatric risks of this drug. This research is crucial and long overdue. I look forward to hearing from our witnesses and exploring how to improve the information and improve our understanding about Accutane.

Mr. Chairman, should there be further hearings on this subject, I would like to work with you. I think we ought to hear from the Hoffman-La Roche company representatives themselves, because there are questions that I think they ought to answer. But I am pleased that you have called this hearing. I think you have witnesses that can help us understand the problem and give us a good guide as to what public policy recommendations we need to make as representatives of the people. Thank you very much.

Mr. BURTON. Thank you, Mr. Waxman.

Mrs. Morella.

Mrs. MORELLA. Thank you, Mr. Chairman.

Just briefly, I want to thank you for holding this hearing on this issue. There is nothing that we can do in this committee that is more important than ensuring that the medication given to individuals, particularly children, is safe and effective. I can't imagine any pain that is more grievous than finding that the medication prescribed for your child or family member actually caused them significant pain or, in some instances, even led to their death.

Today's hearing will hopefully enlighten all of us on the efficacy of Accutane, whether its side effects lead to depression and suicide. I know the witnesses that come before us will elucidate both the positive and the negative outcomes of Accutane. I do want to thank the first panel for their courage in coming before us.

This drug, Accutane, which has helped thousands of individuals who have serious acne problems, may also have dangerous psychological side effects. It is essential that we look at all facets of the issue before any decision is rendered. Preventing others from benefiting from Accutane without ample evidence to the contrary could be considered pernicious, just as continuing to prescribe the drug

if we know it is dangerous. In the end, our objective today must be to ensure that all available information is passed on to families and patients about all possible side effects.

I look forward to hearing the testimony today and discerning an appropriate role for our committee.

I yield back the balance of my time.

Mr. BURTON. Thank you, Mrs. Morella.

Mr. Horn.

Mr. HORN. Thank you, Mr. Chairman.

This is a very important hearing. When you look at what seems to be an absolute flood of suicides in many of the high schools of America, I would hope someone in these two panels would tell us if there is any medical data as to whether Accutane has resulted in a type of suicide that hasn't been with other types of suicide. That is the question I would like to know: What else besides Accutane?

Mr. BURTON. Thank you, Mr. Horn.

I will now turn to our witnesses. Would you all rise, please.

[Witnesses sworn.]

Mr. BURTON. I think we will start right down here at the left, Mrs. Callais, and we will then have you and your daughter both make your statements. If you could try to confine your statements to 5 minutes, that will be fine. If you go a little bit over, we will be lenient, but we would like for you to stick to that as closely as possible.

STATEMENTS OF LORI AND AMANDA CALLAIS, DENHAM SPRINGS, LA; STACY AND MIKE BAUMANN, MUNDELEIN, IL; AND CHARLES H. JACKSON, JR., LUBBOCK, TX

Mrs. LORI CALLAIS. In August 1997, my 14-year-old daughter, Amanda, was a normal teenager. She liked school and made straight A's. She liked talking on the phone for hours at a time. She had a new boyfriend, and she liked life. But that quickly changed.

On September 23, 1997, Amanda started taking the acne medication Accutane. She was excited about taking Accutane because the dermatologist said that the acne Amanda had been undergoing treatment for since the 6th grade would be cleared up.

During the visit to the dermatologist, Amanda and her father, who accompanied her, were given an explanation about the physical side effects, a warning about pregnancy and a pamphlet to read at home. So together Amanda and I carefully read that pamphlet and the release form her father had signed.

I remember the warning about pregnancy and the many physical side effects, but I do not remember seeing the word "depression" in that pamphlet. It definitely was not on the release form, and I know the word "suicide" was never mentioned anywhere. However, by November, Amanda had fallen into such a depression that she wanted to die. On November 15, my daughter took 40 pills in an attempt to kill herself; and she came within hours of succeeding.

After her suicide attempt, we continued to follow the doctors' orders, only now psychiatrists and therapists were involved. On the advice of those doctors, we admitted her to an adolescent facility; and she started taking anti-depressant medication along with the

Accutane. By the way, the Accutane was continued with a psychiatrist's approval.

As Amanda's depression worsened, despite the therapy and medication, the only thing we could visibly see working was the Accutane. Her lips dried out, cracked and bled; her joints ached; and she was always thirsty. But the dermatologist told us that that was just the effect of Accutane, nothing to be worried about, just don't get pregnant.

Finally, after 3 months of treatment, in February 1998, even the psychiatrist could not understand why Amanda was getting worse. By now, she had lost 15 pounds, she slept through her classes, she never talked on the phone, she would not take a bath, she cut her hands with razor blades, and she generally hated the world, and my daughter hated herself. My husband and I watched our daughter die before our eyes, and now even the expert was telling us they could not help Amanda, and she did not understand why she was so depressed. I cannot begin to describe the hopelessness and the terror we felt as parents. We did not know how to help our own child, and we were trying.

Then, on February 26, 1998, I found out from a friend about the FDA's warning about the possible depressive effects of Accutane. She happened to see it on television. You know, I never did see that information. I had to get a copy of the warning from the Internet. As a matter of fact, I gave that information to both the psychiatrist and the dermatologist, because you see, they knew nothing about the new warning.

I threw the pills away, and within days I watched my daughter make a miraculous recovery. Within 1 month, her psychiatrist, who knew and had approved of Amanda taking Accutane all of those months before, could not believe the change in my daughter. Thank God, we have gotten our normal, at times aggravating, but definitely normal, teenaged daughter back; and, yes, she still talks for hours on the phone.

Amanda stopped taking the drug, but we have not stopped telling people about the effects of this drug, and I have not stopped hearing about the devastating effect it has on teenagers. We have done news articles in our local paper, we have appeared on news shows, we have done whatever it takes to get the word out. But should I have to do this? Is it my job to tell the world that this drug is dangerous and needs to be studied and controlled?

I know that Roche Pharmaceuticals would tell you that Accutane does not affect teens, that teenagers are depressed anyway, especially teens with acne. After 16 years of teaching teenagers every day, and I am an English teacher, I can tell you that, while teens' emotions are very volatile, very few are clinically depressed and even fewer are suicidal. Shame on Roche for not giving our children a fair chance and just casually dismissing their lives as a trivial matter. It is time to find out the truth about this drug. Therefore, I demand that the FDA take action. The FDA must require Roche to produce their worldwide data base of adverse psychiatric reactions to this drug. The FDA must hold Roche Pharmaceuticals accountable.

The FDA must also require Roche to explain why the French changed their warning in March 1998, but the FDA was not aware

of the change until a year later. Claiming ignorance about the warning in France is not an excuse or an explanation, it is a cover-up, because, you see, Roche's parent company is in Europe.

Finally, I demand, ask, plead and beg as a mother that the FDA require an independent study to be conducted on Accutane to look into and determine if and how Accutane and the United States and Roaccutane in the rest of the world causes depression. We need to see an unbiased study done to investigate this matter.

I know that recently Roche issued a strong warning label, but at this point warning labels are not enough. Our children are dying because a drug company makes lots of money from this drug. This is the same company cited for once advertising that Accutane helped depression, this just 1 month after the FDA required the warning about suicide. Is the almighty dollar and corporate bottom line worth more than our children?

We would never allow our children to play Russian Roulette with a gun, but we allow that to happen every time a prescription for Accutane is given. If you do not act and act promptly, you have just pulled the trigger. I just hope it is not your child, and I hope and pray that the chamber of that gun isn't loaded. Thank you.

Mr. BURTON. Thank you, Mrs. Callais.

[The prepared statement of Mrs. Lori Callais follows:]

**Testimony of
Lori C. Callais
Before the
Committee On Government Reform
2154 Rayburn, Washington, DC 20515
December 5, 2000**

In August 1997, my 14 year old daughter, Amanda, was a normal teenager. She liked school and made straight A's; she liked talking on the phone for hours at a time; she had a new boyfriend; she liked life, but that quickly changed.

On September 23, 1997, Amanda started taking the acne medication Accutane. She was excited about taking Accutane because the dermatologist said that the acne Amanda had been undergoing treatment for since the 6th grade would be cleared up. During the visit to the dermatologist, Amanda and her father had been given an explanation about the physical side effects and a warning about pregnancy and given a pamphlet to read at home. So, together Amanda and I carefully read the pamphlet and the release form. I remember the warning about pregnancy and the many physical side effects, but I do not remember seeing the word depression in that pamphlet; it definitely wasn't on the release form, and I know the word suicide was never mentioned anywhere. However, by November 1997, Amanda had fallen into a depression so deep that she wanted to die. On November 15, 1997, she took 40 pills in an attempt to kill herself.

After her suicide attempt, we continued to follow Doctors' orders, only now psychiatrists and therapists were involved. On the advice of those doctors, we admitted her to an adolescent facility and she started taking antidepressant medication along with the Accutane, the Accutane was continued with the psychiatrist's approval. We did not tell the dermatologist about the depression, however, because we did not know that this could be related to the Accutane. The psychiatrist and the emergency room doctor, who had treated Amanda after the suicide attempt, assured us that this was an acne drug and therefore not related to the depression and suicide attempt. I know this because we asked them if it could have caused her depression. We were told that it could not.

As Amanda's depression worsened, despite therapy and medication, the only thing we could visibly see working was the Accutane. Her lips dried out, cracked, and bled; her joints ached, and she was always thirsty. But these were just the effects of the Accutane, the dermatologist said, nothing to be worried about, just don't get pregnant. Throughout the entire time Amanda was on Accutane, the dermatologist warned about pregnancy. The dermatologist never asked about depression or mood swings or changes. Most visits with the dermatologist lasted no more than 10 minutes.

Finally, after three months of treatment, in February 1998, even the psychiatrist could not understand why Amanda was getting worse. By now Amanda had lost 15 pounds, slept through her classes, never talked on the phone, would not take a bath, cut her hands with razor blades and generally hated the world and herself. My husband and I were watching our daughter die before our eyes and now even the expert was saying she

couldn't help Amanda and didn't understand what was happening. I cannot begin to describe the hopelessness and terror we felt as parents.

Then on February 26, 1998, I found out from a friend about the FDA's warning about the possible depressive effects of Accutane. She happened to see it on television. I never did see that information. I had to get a copy of the warning from the Internet. As a matter of fact, I had to give the information to both my daughter's psychiatrist and her dermatologist because they knew nothing about the new warning. The dermatologist explained that had she known about Amanda's depression, she would not have related it to the Accutane.

I threw the pills away and within days watched my daughter make a miraculous recovery. Within one month her psychiatrist, who knew and had approved of Amanda taking Accutane all of those months before, could not believe the change in Amanda. Thank God, we have gotten our teenage daughter back.

Amanda stopped taking the drug, but we have not stopped telling people about the effects of this drug or stopped hearing about the devastating effects it has on teenagers. We have done news articles in our local paper, appeared on news shows, whatever it takes to get the word out. But should I have to do this? Is it my job to tell the world that this drug is dangerous and needs to be studied and controlled?

I know that Roche Pharmaceuticals will tell you that Accutane does not effect teens, that teenagers are depressed anyway, especially teens with acne. After 16 years of teaching teenagers every day, I can tell you that while teens' emotions are volatile, very few are clinically depressed and even fewer are suicidal. Shame on Roche for not giving our children a fair chance and just casually dismissing their lives as a trivial matter. It is time to find out the truth about this drug; therefore, I demand that the FDA take action. The FDA must require Roche to produce their world wide data base of adverse psychiatric reactions to this drug. The FDA must hold Roche accountable. This data base is easily accessible to Roche and is located in Welwyn, England. The FDA must require Roche to provide that data base containing all psychiatric adverse reactions and examine it carefully.

The FDA must also require Roche to explain why the French changed the warning in March of 1997, but the FDA was not aware of the change until a year and six months later? Claiming ignorance about the warning in France is not an excuse or an explanation, it is a cover-up because Roche's parent company is in Europe. Finally, I demand, ask, plead, and beg, as a mother, that the FDA require an independent study be conducted on Accutane to look into and determine if and how Accutane in the United States and Roaccutane in the rest of the world causes depression. We need to see an unbiased study done to investigate this matter.

I know that recently Roche Pharmaceuticals issued a stronger warning label, but at this point warning labels are not enough. Our children are dying because a drug company makes lots of money from this drug. This is the same company cited for once advertising that accutane helped depression, this just one month after the FDA required the warning about suicide. Is the all mighty dollar and corporate bottom line worth more than our children? We would never allow our children to play Russian Roulette with a gun, but we allow that to happen every time a prescription is given for Accutane. If you

do not act and act promptly, you've just pulled the trigger. I just hope it is not your child and I hope and pray that the chamber of that gun isn't loaded.
Lori C. Callais

Timeline for Amanda Callais

September 17, 1997	Dermatologist prescribes Accutane; blood tests and pregnancy test performed
September 23, 1997	Amanda starts taking Accutane
November 15, 1997	Amanda attempts to commit suicide and begins treatment for depression
February 27, 1998	Amanda stops taking Accutane
April 1998	Amanda released from treatment by psychiatrist

Mr. BURTON. Amanda, would you like to make a couple of comments?

Ms. AMANDA CALLAIS. At some point in everyone's life, they are faced with the decision to grow up. Most of the time, this is not a conscious decision, it is just a natural part of life. Unfortunately, I didn't have that choice. At 14, I was forced to leave my childhood behind because of the monster under the bed, Accutane.

The summer after my eighth grade year, I talked on the phone with my friends and boyfriend, I went to the movies, and I planned for high school in the fall. I also worried a little bit about my face because, although I had been undergoing treatment for acne for several years, my face and back were still broken out. But lately the dermatologist had been talking about Accutane, so I knew that there was hope.

Before I knew it, school was here; and high school was great. I joined some new clubs, I made the volleyball team, and I was elected freshman class reporter. This year was definitely turning into one of the best years of my life. And then on September 17 my dermatologist prescribed Accutane for my face. We talked about the physical side effects of the drug, and she warned me about pregnancy. She then sent me home with a pamphlet to read.

Of course, my appearance became worse before it got better. My lips chapped and bled, and my skin dried out. But my dermatologist and I had discussed all of these physical side effects of Accutane, so I didn't care, because it just proved that the drug was working.

My downfall started from the moment that I took the first pill. After 2 weeks, my happy mood began to slowly dissolve. I found myself feeling sad, and I often cried for no reason. I began to slack off on my school work because I was just too tired to care about my grades. I frequently argued with my parents and friends. In fact, I often provoked arguments until I was in a screaming fit with the other person.

In 6 short weeks, everything about the best year of my life had become nonexistent. I just didn't care any more; and on November 14, 1997, I took 40 pills and went to sleep, never expecting to wake up. However, at 3 o'clock that morning, I did wake up, and I was sick. My parents found me, took me to the hospital where my stomach was pumped.

I was then taken to an adolescent facility where I stayed for a week under the care of a psychiatrist, and I began taking Prozac. However, even the Prozac didn't help. No matter how hard I tried to feel better and be normal, and believe me I did try very hard, I just sank deeper into depression. I began to restrict my food and lost over 15 pounds. My grades dropped, and I went from being a 4.0 student to making C's and D's. I wanted to sleep all of the time. I hated myself more and more each day and began to cut my hands with razor blades. Ironically, the only good thing in my life was my clear skin because of the Accutane.

During that time, I watched a monster live in my body and control my actions. I wanted to feel better and be happy, but I couldn't, no matter how hard I tried. No matter how much therapy I attended, and no matter how much medication I took, I was miserable. I had no control over my life. A monster was in charge.

Fortunately, that changed at the end of February when my mom heard about the warnings for Accutane. Do you remember that little drug? It was going to help make this year the best year of my life, right? I had been taking it all along. I had even taken it at the adolescent center with the psychiatrist's approval.

After that report, Mom took me off of Accutane; and within 2 weeks I began to feel normal again. I started eating and quit cutting myself. I began to study again and stayed awake in my classes. By the end of March, the Accutane was out of my system, and I was working hard to catch up, but I was in control. No monster in sight. By April, my psychiatrist released me from her care, saying that I had made a full recovery. All of my doctors agreed that they had never seen a turnaround like this, and my depression must surely have been caused by the Accutane.

That year became a defining moment in my life when I was forced to grow up. I just find it sad that I was never given the chance to choose, to hold on to my innocence and keep my childhood for a little bit longer.

I have had to pay the price and face the consequences for a choice that I didn't voluntarily make. I think the people who make Accutane should have to face the consequences for stolen innocence and lost lives because of the choices they make to hide the devastating effects of this drug. I know that Accutane causes depression, no matter what the so-called experts say. I have lived to tell my story. There were two girls that year: me and me on Accutane.

Today, I am grateful just to be alive. I am a senior in high school and plan to go to college next year. I was lucky. I survived Accutane. But I will live with the memories of that year every time I gaze in a mirror.

You must do something about this drug, because so many people do not survive. You see, the monster under the bed is supposed to be imaginary, not a pill you take to clear up your skin.

Mr. BURTON. Thank you very much, Amanda.

[The prepared statement of Ms. Amanda Callais follows:]

**Testimony of
Amanda Callais
Before the
Committee On Government Reform
2154 Rayburn, Washington, DC 20515
December 5, 2000**

At some point in everyone's life they are faced with the decision to grow up. Most of the time it is not a conscious decision, it is just a natural part of life. Unfortunately, I didn't have a choice. At 14, I was forced to leave my childhood behind because of the monster-under-the-bed, Accutane.

The summer after my 8th grade year was rather boring, I talked on the phone with my friends and boyfriend, went to the movies, and planned for high school in the fall. I also worried a bit about my face because although I had been undergoing treatment for acne for several years, my face and back were still broken out, but lately the dermatologist had been talking about Accutane, so I knew that there was hope.

Before I knew it, school and high school was great I joined some new clubs; I made the volleyball team, and I was elected Freshman Class reporter. This year was definitely turning into one of the best years of my life. And then on September 17, the dermatologist prescribed Accutane for my face. We talked about the physical side effects and she warned me about pregnancy and then she sent me home with a pamphlet to read.

Of course my appearance got worse before it got better. My lips chapped and bled, and my skin dried out, but my dermatologist and I had discussed all of the physical side effects of Accutane, so I didn't care because it just proved that the Accutane was working.

My downfall started the moment I took the first pill. After two weeks, my happy mood began to slowly dissolve. I found myself feeling sad and I often cried for no reason. I began to slack off from my school work because I was just too tired to care about my grades. I frequently argued with my parents and friends. In fact, I often provoked arguments until I was in a screaming fit. In six short weeks everything about the best year of my life had become nonexistent. I just didn't care anymore and on November 14, 1997, I took 40 pills went to sleep expecting never to wake up. However, at 3:00 that morning I woke up and was sick. My parents found me and took me to the hospital and my stomach was pumped. I was then taken to an adolescent facility where I stayed for a week under the care of a psychiatrist and I began taking Prozac.

However, even the Prozac didn't help. No matter how hard I tried to feel better and be normal, and I did try very hard, I just sank deeper into depression. I began to restrict my food and lost over 15lbs. My grades dropped and I went from being a 4.0 student to making C's and D's. I wanted to sleep all of the time. I hated myself more and more each day and began to cut my hands with razor blades. Ironically, the only good thing in my life was my clearer skin because of the Accutane.

During that time, I watched a monster live in my body and control my actions. I wanted to feel better and be happy, but I couldn't no matter how hard I tried, no matter how much therapy or medication, I was miserable. I had no control over my life, the

monster was in charge. Fortunately, that changed at the end of February when my mom heard about the warnings for Accutane. Do you remember that little drug? It was going to help make this year the best year of my life, right? I had been taking it all along, I had even taken it at the adolescent center with the psychiatrist's approval.

After that report, Mom took me off Accutane and within two weeks I began to feel normal again. I started eating and quit cutting myself. I began studying again and staying awake in my classes. By the end of March the Accutane was out of my system and I was working hard to catch up, but I was in control, no monster in sight. By April my psychiatrist released me from her care saying that I had made a full recovery. All of my doctors agreed that they had never seen a turn around like this and my depression must have been caused by the Accutane.

That year became a defining moment in my life when I was forced to grow up. I just find it saddening that I was never given the chance to choose, to hold on to my innocence and keep my childhood for a little bit longer. I have had to pay the price and face the consequences for a choice I didn't voluntarily make. I think the people who make Accutane should have to face the consequences for stolen innocence and lost lives because of the choices they make to hide the devastating effects of this drug. I know that Accutane causes depression, no matter what the so-called experts say. I have lived to tell the tale. There were two girls that year, me and me on Accutane.

Today I am grateful to just be alive. I am a senior in high school and plan to go to college next year. I was lucky, I survived Accutane, but so many others don't. You must do something about this drug because the monster-under-the-bed is supposed to be imaginary, not a pill you take to clear up your skin.

Mr. BURTON. Mr. Baumann.

Mr. BAUMANN. Can I take 7 minutes?

Mr. BURTON. Sure.

Mr. BAUMANN. May I say that, listening to Amanda for the first time, I can see exactly what happened to my son. It was the same thing.

I am coming to Washington today not in anger, but with some hope. I am not angry at the school system that called us in unexpectedly and with no previous communication to sit down in a small room in front of two administrators and three armed police officers to be told our son, Dan, was to be home-schooled as a result of the Columbine tragedy simply because he wore black. They were afraid, and I understand that.

I am not angry at the dermatologist who diagnosed the cause of Daniel's acne as being stress-related and even pinpointed the day of the meeting as its beginning, but then prescribed Accutane as an initial remedy rather than a last resort with no patient/parent counseling as to the possible consequences. I am not sure if he was not aware or just thought that the risk was not worth mentioning in light of the great results that could be obtained.

I am not angry at the pharmacy that distributed this expensive drug for not counseling us in any way as to the potential side effects. I recently went to the same pharmacist for a prescription for antibiotics, and he spent 5 minutes talking with me, including talking to me about the side effects, which included nothing at that time more serious than possible stomach ache if not taken with a meal. I know he cares.

I am not angry with the company that labels the drug, even though the labeling did not include the dangerous potential side effects of suicide, although I am not sure why it did not.

I am not angry with the drug company that makes Accutane, because I believe that, for many, it is a Godsend.

I am not angry at the therapist in Lincoln, NE, last Thanksgiving, who, when told that Dan had scored high on a Suicide Risk Inventory test, elected to interview him over the phone from home and clear him from all risk. Dan committed suicide 2 weeks later.

Mostly, I am not angry with myself or my wife, Stacy, for thinking that our son's behavior was just that of a normal, healthy, independent-thinking teenager who was going through a phase in life.

I do not know if our dermatologist giving up his practice had anything to do with our son's death or not, but I do know that he is now teaching at Loyola University. I can only hope that he teaches his students that the use of these drugs, even for dermatology, should not be taken lightly.

I met a friend from high school not long ago in a Sam's Club. It turns out she was there to pick up a prescription for her son of Accutane. When I asked if she was aware of the potential risk, she looked at me like I was crazy. I asked if she was counseled by her dermatologist who is different from ours. She said she was not. I asked her if this drug was prescribed when other remedies had failed and found out that it had been prescribed first before any other remedies had been tried. I then asked to look at the labeling and letter that came with her prescription and found that it made no mention of depression or suicide, and the pharmacist made no

mention of suicide for sure, and the pharmacist said nothing about these potential dangers to her. The pharmacy and the labeling company were both different than ours. I then tried to reiterate my concern and was dismissed with, "My son is very well-liked, outgoing and happy," much like my Dan, as though nothing could happen to her son.

I don't think hearing the potential risks from me meant anything to her. I believe that people do have the right to determine the amount of risk that they are willing to assume for themselves, but they do not have the right to impose that risk on others unbeknownst to them.

I fly small airplanes for a living and on occasion take people from one place to another in bad weather. If there is a thunderstorm in my path, I let them know the possible consequences and that it will be safe. However, it may be very uncomfortable. Even if the situation changes, we may have to divert and delay or possibly not be able to get to the intended destination. I believe the choice is theirs, and if I lose a few trips as a result, so be it.

I have found that this drug can be very dangerous to pregnant women and is associated with various birth defects and that there is no circumstance under which it should be prescribed. According to the Physicians' Desk Reference, women should sign a form stating that they will not get pregnant while on Accutane.

I have seen a television commercial, which is animated, of kids sitting around a computer. Then the computer screen is shown with a picture of a boy's face with dots on it, representing acne. The child at the computer presses a button and the dots disappear. Call Roche for more info. I don't think it is as easy as pressing a button on your computer and getting rid of your acne.

I saw a doctor on TV saying there is no link between this drug and suicide but later found that the drug company itself funded his research. In my mind this is a conflict of interest and, at the very least, gives the appearance of impropriety. In the PDR, Roche itself lists depression and suicide in bold, which means highlighted, as possible adverse reactions.

I believe that this is a powerful drug and have no doubt that it can clear up or at least improve even the most severe acne, which my son did have. I realize that the drug company is in the business to make money, and I am sure that a widely prescribed expensive drug like Accutane does just that. But my question would be, at what cost?

My suggestions: I do not necessarily think that this drug should be pulled from the market, but I think its distribution should be handled differently and additional research conducted by an independent source as to potential hazards. I wonder if my son's suicide was ever reported to the FDA and how many others might be out there. Wouldn't it be OK if we let people know that there may be a danger and let them decide for themselves if it is an acceptable risk? So what if the drug company makes a little less money? After all, I believe most people think that smoking is harmful, but many still do it, and the cigarette companies are still in business.

None of us as individuals has the time or resources to fight for all of the causes that are important in life, but if by coming here

today we are able to find a stronger, more powerful voice to carry on this investigation and education, we have done our job.

In conclusion, I would like to thank you for letting me come here and speak my piece. If sharing my experience helps even one person, the trip will have been worth it. I believe that life should always be held with a higher regard than money, and that fear, greed, and ignorance, all things I think that can be overcome with compassion, understanding and education, all played a part in my son's death.

Last, my greatest hope is that by coming here, in some small way, my son's life will be given meaning and his death dignity. Thank you.

Mr. BURTON. Thank you, Mr. Baumann.

[The prepared statement of Mr. Baumann follows:]

I come to Washington today, not in anger, but with hope.

I am not angry at the school system that called us in unexpectedly, and with no previous communication, to sit in a small room in front of 2 School Administrators and 3 armed Police Officers to be told our son, Dan was to be home schooled as a result of the Columbine incident simply because he wore black! They were fearful and I understand.

I am not angry at the Dermatologist who correctly diagnosed the cause of Daniel's acne as being stress related and even pinpointed the day of the meeting as its beginning. But then prescribed Accutane as an initial remedy rather than a last resort with no Patient/Parent counseling as to the possible consequences. I am not sure if he was not aware or just thought that the risk was not worth mentioning in light of the great results that could be obtained.

I am not angry at the Pharmacy that distributed this expensive drug for not counseling us in any way as to the potential side effects. I recently went to the same Pharmacist to receive a prescription for antibiotics and spent 5 minutes talking with him about the reason for the antibiotics use, as well as its potential side effects, which included nothing more serious than possible stomach ache if taken without eating, so I know he cares.

I am not angry with the company that labels the drug even though the labeling did not include the dangerous potential side effects although I am not sure why it did not.

I am not angry with the Drug Company that makes Accutane because I believe that it is a godsend too many.

I am not angry at the Therapist in Lincoln, Nebraska last Thanksgiving who, when told that Dan had scored high on a Suicide Risk Inventory test, elected to interview him over the phone from home and clear him from risk (Dan committed suicide in 2 weeks).

And mostly, I am not angry with myself or my wife Stacy for thinking that our son's behavior was just that of a normal, healthy, independent thinking teenager who was going through a phase in life.

I do not know if our Dermatologist giving up his practice had anything to do with our son's death or not. But I do know that he is now teaching at Loyola University. I can only hope that he is teaching that even though Dermatologists may not be involved in life threatening surgeries on a regular basis there job is no less important and the drugs they may use should not be taken lightly.

I met a friend from High School not long ago in a Sam's Club. It turns out she was there to pick up a prescription of Accutane for her son. When asked if she was

aware of the potential risks involved she looked at me like I was nuts. When I asked if she was counseled by her Dermatologist (different than ours) she said she was not. I asked her if this drug was prescribed when other remedies had failed and found out that it had been prescribed first before any other remedies had been tried. I then asked to look at the labeling and letter that came with her prescription and found that it made no mention of depression or suicide and the Pharmacist said nothing about these potential dangers (different Pharmacy and labeling company). I then tried to reiterate my concern and was dismissed with "My son is very well liked...outgoing and happy" (much like Dan) as though nothing could happen to him. I don't think hearing of potential risk from me meant anything to her (sad).

I believe that people have some right to determine the amount of risk that they are willing to assume for themselves, but they do not have a right to impose that risk on others unbeknownst to them.

I fly small airplanes for a living and on occasion take people from one place to another in bad weather. If there is a thunderstorm in our path I will advise them that even though the trip can be done safely it may be uncomfortable. But if the situation changes we may have to divert and delay or possibly not be able to get to the intended destination. I believe the choice is theirs and if I lose a few trips as a result so be it.

I have found that this drug can be very dangerous to pregnant women and is associated with various birth defects, and that there is no circumstance under which it should be prescribed. According to the PDR women should sign a form stating they will not get pregnant while on Accutane.

I have seen a television commercial (animated) of kids sitting around a computer. Then the computer screen is shown with a picture of a boy's face with dots on it (acne). The child at the computer presses a button and the dots disappear. Call Roche for more info.

I saw a Doctor on TV saying that there is no link between this drug and suicide, but later found that the Drug Company itself funded his research. In my mind this is a conflict of interest and at the very least gives the appearance of impropriety. In the PDR Roche itself lists depression and suicide in bold (highlighted) as possible Adverse Reactions.

I believe that this is a powerful drug and have no doubt that it can clear up or at least improve even the most severe acne. I realize that the drug company is in business to make money and I am sure that a widely prescribed expensive drug like Accutane does just that. My question would be "at what cost?".

My Suggestions:

I do not necessarily think that this drug should be pulled from the market but I think its distribution should be handled differently and additional research conducted by an independent source as to potential hazards.

1. Evaluation of candidate (by Physician)
 - a) History
 - b) Cause of Acne
 - c) Health
2. Consultation with Parent/Guardian as to potential risks. To inform/educate Parents and allow them to be involved in monitoring for signs of trouble.
3. Use drug as a last resort (as recommended) after other remedies have failed.

I wonder if my son's suicide was ever even reported to the FDA and how many others there might be out there.

Wouldn't it be okay if we let people know that there may be a danger and let them decide for themselves if it is an acceptable risk? So what if the Drug Company makes a little less money. After all, most people believe that smoking is harmful but many still do it and there are still cigarette companies.

None of us as individuals has the time or resources to fight for all the causes that are important in life but if by coming here today we are able to find a stronger more powerful voice to carry on this investigation/education we have done our job.

In conclusion, I would like to thank you for letting me come here and speak my peace. If sharing my experience helps even one person the trip will have been worth it. I believe that life should always be held with a higher regard than money and that fear, greed, and ignorance (things that can be overcome with compassion, understanding and education) all played a part in my son's death. Lastly, my greatest hope is that by coming here in some small way, my son's life will be given meaning and his death dignity.

Mr. BURTON. Mrs. Baumann.

Mrs. BAUMANN. Daniel began Accutane therapy on June 25, 1999, 3 days after his first visit to the dermatologist. On June 22, Daniel's dermatologist told us that the breakout was a result of high school stress and even pinpointed the week the stress may have begun. The dermatologist sent Daniel home with a prescription for Prednisone, Erythromycin, a shopping list that included Purpose Bar, Colladerm Fluid/Jell, Presun Ultra Gel and vitamin B5.

In addition, we received two brochures that we were to read before starting Accutane therapy: Important Information Concerning Your Treatment With Accutane and What Young Men Need to Know About Acne and Its Treatment With Accutane. Daniel and I read both brochures and felt that it was something that we needed to do and were looking forward to the promising results. This was a very big decision for us, considering we didn't have insurance and was going to be self-paid throughout the Accutane therapy, monthly dermatologist visits, and blood tests.

It wasn't long before the side effects started: chapped lips, dry skin and itching, joint and muscle pains, headaches, nausea, loss of appetite, mood swings, and insomnia. This was a very difficult summer for Daniel. He didn't even want to leave the house anymore and just wanted to stay in his room all day.

On the first day of school, Daniel cried as we were driving there. He was 15 at the time, going to be a sophomore. He didn't know why he was crying. He said he just felt weird. School was very difficult for Daniel this term, and he had a very hard time concentrating.

Daniel and I went to the dermatologist every month, and we were told that this was all very normal and to be expected. He assured us that the mood swings were normal and would be going away as soon as the Accutane therapy ended.

On December 11, 1999, Daniel committed suicide.

I called the dermatologist 2 days after Daniel's death and talked to him directly and let him know what had happened and that we wouldn't be making our next appointment. He offered his deepest condolences.

At the time of Daniel's death, we knew nothing about Accutane and its adverse reactions linked to depression and suicide. It wasn't until 2 months later, on February 9, that I discovered that Accutane might have played a role in Daniel's suicide. I was having lunch with some friends and a concerned friend mentioned that she had heard that Prednisone may be linked to depression and she knew Daniel was taking this for his acne. As soon as I came home that afternoon, I looked for Daniel's entire prescription receipts and started reading everything I could. I got on line and used the two key words: Accutane and suicide, and found the FDA's Med Watch News dated February 26, 1998: "important new safety information about Accutane." I was home alone at the time and just couldn't believe what I was hearing and learning for the very first time.

In addition, I also discovered that the brochures Daniel's dermatologist gave us were copyrighted in 1996 and 1997, respectively. The brochures had no adverse reactions reporting depression, psychosis, suicidal ideations, suicide attempts and suicide. I

was finding it very hard to believe that Daniel's dermatologist had no idea or updated information to hand out to his patients.

I have since visited the pharmacy where Daniel's prescriptions were filled and asked the pharmacist if she knew any of the adverse reactions associated with Accutane. She was not aware of depression and suicide. She immediately grabbed the 40 milligram package from the shelf and was surprised to find out that the depression and suicide warning was not present on the packaging.

I find it interesting that 5 months after Daniel's death his dermatologist unexpectedly announces to his patients by the way of a postcard that he was closing down his practice to teach at Loyola University.

In addition to everything that continues to point that Accutane played a role in Daniel's suicide is a picture that I received from a friend on the day after Thanksgiving this year. Looking at this picture brought tears to my eyes. His beautiful smile of hopes, dreams and promises had been taken away before Accutane therapy. I realize that we have pictures of Daniel before Accutane all smiling and pictures of Daniel on Accutane, no smiles.

As you can imagine, this past year has been very painful for our family, and the more we research, the more we realize that somehow or another our precious son's life fell through the cracks. I am not looking for an out. I do know this for a fact: The dermatologist provided us with outdated information. The pharmacist didn't provide any patient counseling. Renlar Systems and First Data Bank package insert did not include the most current adverse reaction, suicide. Roche's labeling did not include in the warning depression and rarely suicidal thoughts, suicide attempts and suicide.

The FDA has allowed Roche to continue to profit from this drug for far too long without taking any responsibility for the damage it continues to do to our children. Mistakes were made by many, and now we are all suffering because this could have all been prevented if everybody did their jobs.

I hope that this limited information I have provided today will somehow make a positive difference in our children's future. Thank you for giving me an opportunity to share Daniel's story with you.

[The prepared statement of Mrs. Baumann follows:]

Stacy Baumann - Testimony
"Accutane - Is this Drug Treatment Linked to Depression and Suicide?"

Daniel began Accutane therapy on June 25, 1999, three days after his first visit to the Dermatologist. On June 22nd Daniel's Dermatologist told us that the break out was a result of High School stress and even pinpointed the week the stress may have began. The Dermatologist sent Daniel home with a prescription for Prednisone, Erythromycin, a shopping list that included Purpose Bar, Colladerm Fluid/Gel, Presun Ultra Gel and Vitamin B5. In addition, we received two brochures that we were to read before starting Accutane therapy, "IMPORTANT INFORMATION CONCERNING YOUR TREATMENT WITH ACCUTANE" (Exhibit 1) and "WHAT YOUNG MEN NEED TO KNOW ABOUT ACNE...AND ITS TREATMENT WITH ACCUTANE" (Exhibit 2). Daniel and I read both brochures and felt that this was something that we needed to do and looked forward to the promising results. This was a very big decision for us, considering we didn't have insurance and was going to be self pay throughout the Accutane therapy, monthly Dermatologist visits and blood tests.

It wasn't long before the side effects started: chapped lips, dry skin and itching, joint and muscle pain, headaches, nausea, loss of appetite, mood swings and insomnia. This was a very difficult summer for Daniel, he didn't even want to leave the house anymore and just wanted to stay in his room all day in bed. On the first day of school Daniel cried as we were driving there, he was 15 at the time going to be a sophomore, he didn't know why he was crying he said he just felt weird. School was very difficult for Daniel this term and he had a very hard time concentrating. Daniel and I went to the Dermatologist every month and we were told that this was all very normal and to be expected, he also assured us that the mood swings were normal and would be going away as soon as the Accutane therapy ended.

On December 11, 1999 Daniel committed suicide.

I called the Dermatologist two days after Daniel's death away and talked to him directly to let him know what had happened and that we wouldn't be making our next appointment, he offered his deepest condolences.

At the time of Daniel's death we knew nothing about Accutane and its Adverse Reactions linked to depression and suicide. It wasn't until 2 months later on February 9th that I discovered that Accutane might have played a role in Daniel's suicide. I was having lunch with friends and a concerned friend mentioned that she had heard that Prednisone may be linked to depression and she knew that Daniel was taking it for his acne. As soon as I came home that afternoon I looked for Daniel's entire prescription receipts and started reading everything I could. I got online and used the two key words ACCUTANE and SUICIDE and found the FDA's Med Watch News dated February 26, 1998 "IMPORTANT NEW SAFETY INFORMATION ABOUT ACCUTANE". I was home alone at the time and just couldn't believe what I was learning for the very first time.

Stacy Baumann - Testimony

"Accutane - Is this Drug Treatment Linked to Depression and Suicide?"

In addition, I also discovered that the brochures Daniel's Dermatologist gave us were copyrighted in 1996 and 1997 respectively. The brochures had no Adverse Reactions reporting depression, psychosis, suicidal ideation, suicide attempts and suicide. I was finding it very hard to believe that Daniel's Dermatologist had no idea or updated information to hand out to his patients.

I have since visited the Pharmacy where Daniel's prescriptions were filled and asked the Pharmacist if she knew of any Adverse Reactions associated with Accutane, she was not aware of depression and suicide. She immediately grabbed a 40MG package from the shelf and was surprised to find out that the Depression and Suicide warning was not present on the packaging.

I find it interesting that 5 months after Daniel's death, his Dermatologist unexpectedly announces to his patients by way of postcard that he was closing down his practice to teach at Loyola University.

In addition to everything that continues to point that Accutane played a role in Daniel's suicide is a picture that I received from a friend of his the day after Thanksgiving this year. Looking at this picture brought tears to my eyes, his beautiful smile full of hopes, dreams, and promises had been taken before Accutane Therapy. I realized that we have pictures of Daniel before Accutane (all smiling) and pictures of Daniel on Accutane (no smiles) (Exhibit 3).

As you can imagine this past year has been very painful for our family and the more we research the more we realize that some how or another our precious son's life fell through the cracks. I am not looking for an out; I do know this for a fact:

- The Dermatologist's provided us with outdated information.
- The Pharmacist's didn't provide any patient counseling.
- Renlar Systems and First Data Bank package insert did not include the most current Adverse Reaction "Suicide" (Exhibit 4 & 5).
- Roche's labeling did not include in the warnings "...DEPRESSION, AND RARELY SUICIDAL THOUGHTS, SUICIDE ATTEMPTS AND SUICIDE..."
- The FDA has allowed Roche to continue to profit from this drug for far to long with out taking any responsibility for the damage it continues to do to our children.
- Mistakes were made by many and now we are suffering because this could have been all prevented if everyone did their jobs.

I hope that limited information I have provided today will somehow make a positive difference in our children's future. Thank you for giving me an opportunity to share Daniel's story with you.


WARNING TO FEMALE PATIENTS

- **YOU MUST HAVE A BLOOD OR URINE TEST DONE BY YOUR DOCTOR WHICH SHOWS YOU ARE NOT PREGNANT BEFORE YOU START TAKING ACCUTANE**
- **YOU MUST WAIT UNTIL THE 2ND OR 3RD DAY OF YOUR PERIOD TO START TAKING ACCUTANE**
- **YOU MUST USE TWO FORMS OF EFFECTIVE BIRTH CONTROL FOR AT LEAST 1 MONTH BEFORE, DURING AND FOR 1 MONTH AFTER TAKING ACCUTANE**
- **YOU MUST SEND IN THE FORM INSIDE THE MEDICATION PACKAGE TO SIGN UP FOR THE CONFIDENTIAL FOLLOW-UP SURVEY**

YOU MUST NOT TAKE ACCUTANE IF YOU ARE PREGNANT OR MAY BECOME PREGNANT DURING TREATMENT. YOU MUST USE RELIABLE CONTRACEPTION (BIRTH CONTROL) FOR AT LEAST 1 MONTH BEFORE TREATMENT, DURING TREATMENT, AND FOR 1 MONTH AFTER TREATMENT. PLEASE SEE COMPLETE WARNING TO FEMALE PATIENTS ON PAGE 2.

ACCUTANE 10-mg
20-mg
40-mg
capsules
isotretinoin

Available in three strengths

20-mg  40-mg
10-mg

Roche **Roche Laboratories**
A Member of the Roche Group

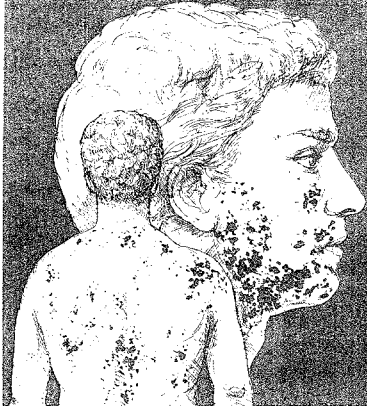Roche Laboratories Inc.
340 Kingsland Street
Nutley, New Jersey 07110-1199

Plandex 23001
Lot 0000035023
18-002-023-045-126

Printed in U.S.A.
RCS 1195-96

SIXTH EDITION

**IMPORTANT
INFORMATION
CONCERNING
YOUR
TREATMENT
WITH
ACCUTANE** 10-mg
20-mg
40-mg
capsules
isotretinoin



A Product of Roche Research

Copyright © 1996 by Roche Laboratories Inc. All rights reserved.

Exhibit 1



*Baseline
12 months after one course of therapy
Photograph uncut/etched*

What young men
need to know
about acne...

ACCUTANE
isotretinoin

Brought to you by Roche, a leader in dermatology

Roche Roche Laboratories
A Member of the Roche Group
Roche Laboratories Inc.
350 Kingsland Street
Nutley, New Jersey 07110-1198
PRINTED IN USA

PANJLX 23253
LOT 025088 023
8-002-323-051-27

and its
treatment with

ACCUTANE
isotretinoin

Exhibit 2




exhibit 3

file://C:\My Documents\Accutane Info\A...\Dan before&during.JPG 12/04/00

Prepared for
DANIEL BAUMANN

Drug Name	Quantity
ACCUTANE 40MG CAP	30
Date	Prescription No.
6/25/99	00178075

Prescribed by
JAMES SWAN

TAKE 1 CAPSULE BY MOUTH EVERY DAY

Your Pharmacy
 DOMINICK'S PHARMACY #140
 1150 W. MAPLE
 MUNDELEIN, IL 60060

Your Pharmacist Phone
 SCOTT FANCIULLO (847) 566-7021

Please call me if you have further questions concerning this medication.

ABOUT YOUR MEDICINE

ISOTRETINOIN (eye-soe-TRET-i-noyn)

This medicine is a retinoid used to treat severe acne. It may also be used to treat other conditions as determined by your doctor.

PROPER USE OF THIS MEDICINE

Follow the directions for using this medicine provided by your doctor. THIS MEDICINE COMES WITH A PATIENT INFORMATION LEAFLET. Read it carefully. Ask your doctor, nurse, or pharmacist any questions that you may have about this medicine. TAKE THIS MEDICINE with food or milk. STORE THIS MEDICINE at room temperature in a tightly-closed container, away from heat and light. IF YOU MISS A DOSE OF THIS MEDICINE, take it as soon as possible. If it is almost time for your next dose, skip the missed dose and go back to your regular dosing schedule. Do not take 2 doses at once.

PRECAUTIONS WHILE USING THIS MEDICINE

DO NOT TAKE VITAMIN A, or vitamin supplements containing vitamin A, while you are taking this medicine. IF YOU WEAR CONTACT LENSES, you may have difficulty wearing them during and after therapy.

REPORT ANY CHANGES IN VISION to your doctor immediately. A SUDDEN DECREASE IN NIGHT VISION may occur while you are taking this medicine. Use caution when driving at night and avoid driving at night if you experience this effect. THIS MEDICINE MAY CAUSE increased sensitivity to the sun. Avoid exposure to the sun, sunlamps, or tanning booths until you know how you react to this medicine. Use a sunscreen or protective clothing if you must be outside for a prolonged period. TO PREVENT CRACKING OF LIPS, use a lip lubricant. KEEP ALL DOCTOR AND LABORATORY APPOINTMENTS while you are using this medicine. DO NOT DONATE BLOOD for transfusion during therapy or for 30 days after stopping therapy. DO NOT USE THIS MEDICINE if you are pregnant. IF YOU SUSPECT THAT YOU COULD BE PREGNANT, contact your doctor immediately. Use an effective form of birth control for at least 1 month before beginning therapy, all during therapy, and for 1 month after this medicine is stopped. IF YOU HAVE DIABETES, this medicine may affect your blood sugar. Check blood sugar levels closely and ask your doctor before adjusting the dose of your diabetes medicine.

POSSIBLE SIDE EFFECTS OF THIS MEDICINE

SIDE EFFECTS, that may go away during treatment, include temporary worsening of acne; dry and peeling skin; itching; rash; thinning of hair; fatigue; or dry mouth, nose, or eyes. If they continue or are bothersome, check with your doctor. CHECK WITH YOUR DOCTOR AS SOON AS POSSIBLE if you experience bone, joint, or muscle pain or stiffness; abdominal pain; yellowing of the skin or eyes; dark urine; rectal bleeding; severe diarrhea; mood or personality changes; skin infections; persistent, severe headaches; vomiting; depression; suicidal thoughts or tendencies; or blood red vision. If you notice other effects not listed above, contact your doctor, nurse, or pharmacist.

Renlar Systems, Inc.
 Expires 8/02/99

Exhibit C

Rx:6604237 Oct 25,1999
 For:BAUMANN, DANIEL
 Dr. SWAN, JAMES
 ACCUTANE 40MG

DOMINICKS #10-1140 # 10-1
 1150 W MAPLE
 MUNDELEIN, IL 60060
 (847)566-7021

GENERIC NAME: ISOTRETINOIN (eye-soe-TRET-i-noyn)

COMMON USES: This medicine is a retinoid used to treat severe acne. It may also be used to treat other conditions as determined by your doctor.

HOW TO USE THIS MEDICINE: Follow the directions for using this medicine provided by your doctor. **THIS MEDICINE COMES WITH A PATIENT INFORMATION LEAFLET.** Read it carefully. Ask your doctor, nurse, or pharmacist any questions that you may have about this medicine. **TAKE THIS MEDICINE** with food or milk. **STORE THIS MEDICINE** at room temperature in a tightly-closed container, away from heat and light. **IF YOU MISS A DOSE OF THIS MEDICINE,** take it as soon as possible. If it is almost time for your next dose, skip the missed dose and go back to your regular dosing schedule. Do not take 2 doses at once.

CAUTIONS: **DO NOT TAKE VITAMIN A,** or vitamin supplements containing vitamin A, while you are taking this medicine. **IF YOU WEAR CONTACT LENSES,** you may have difficulty wearing them during and after therapy. **REPORT ANY CHANGES IN VISION** to your doctor immediately. **A SUDDEN DECREASE IN NIGHT VISION** may occur while you are taking this medicine. Use caution when driving at night and avoid driving at night if you experience this effect. **THIS MEDICINE MAY CAUSE** increased sensitivity to the sun. Avoid exposure to the sun, sunlamps, or tanning booths until you know how you react to this medicine. Use a sunscreen or protective clothing if you must be outside for a prolonged period. **TO PREVENT CRACKING OF LIPS,** use a lip lubricant. **KEEP ALL DOCTOR AND LABORATORY APPOINTMENTS** while you are using this medicine. **DO NOT DONATE BLOOD** for transfusion during therapy or for 30 days after stopping therapy. **FOR WOMEN: DO NOT USE THIS MEDICINE** if you are pregnant. **IF YOU SUSPECT THAT YOU COULD BE PREGNANT,** contact your doctor immediately. Use an effective form of birth control for at least 1 month before beginning therapy, during therapy, and for 1 month after this medicine is stopped. **IT IS UNKNOWN IF THIS MEDICINE IS EXCRETED** in breast milk. **DO NOT BREAST-FEED** while taking this medicine. **IF YOU HAVE DIABETES,** this medicine may affect your blood sugar. Check blood sugar levels closely and ask your doctor before adjusting the dose of your diabetes medicine.

POSSIBLE SIDE EFFECTS: **SIDE EFFECTS,** that may go away during treatment, include temporary worsening of acne; dry and peeling skin; itching; rash; thinning of hair; fatigue; or dry mouth, nose, or eyes. If they continue or are bothersome, check with your doctor. **CHECK WITH YOUR DOCTOR AS SOON AS POSSIBLE** if you experience bone, joint, or muscle pain or stiffness; abdominal pain; yellowing of the skin or eyes; dark urine; rectal bleeding; severe diarrhea; mood or personality changes; skin infections; persistent, severe headaches; vomiting; depression; suicidal thoughts or tendencies; or blood red vision. If you notice other effects not listed above, contact your doctor, nurse, or pharmacist.

The information in this monograph is not intended to cover all possible uses, directions, precautions, drug interactions, or adverse effects. This information is generalized and is not intended as specific medical advice. If you have questions about the medicines you are taking or would like more information, check with your doctor, pharmacist, or nurse.

Copyright 1999 First DataBank, Inc. All rights reserved. Database Edition 99.3 Information Expires November 29, 1999

Thank you for shopping at Dominick's

EXHIBIT

Mr. BURTON. Mr. Jackson.

Mr. JACKSON. Mr. Chairman, thank you for inviting me to come here and testify before this committee today. This is going to be extremely difficult for me to talk about. However, it is extremely important for me to be here so we can hopefully prevent just one parent from having to experience the pain and grief that my family has had to endure, so that maybe all of this will be worthwhile.

On January 13, 2000, my 17-year-old son and my best friend, Clay, died from a self-inflicted gunshot in our home. Around 4 p.m. that day, imagine my wife and my 10-year-old son coming home to find his lifeless body dead in his bedroom. I will never be able to remove what they saw that day from their memory. This is going to stay with them for the rest of their lives.

Clay began going to a dermatologist at the age of 14 for normal teenage acne. In October 1999, at the age of 16, his treating physician decided to put Clay on Accutane for his mild acne. There was never any mention of suicide as a side effect. The information that Clay brought home from the dermatologist was a brochure dated 1994 and made no mention of suicide. The only thing that concerned the dermatologist was our ability to pay for the drug. The package insert that came with the prescription made no mention of suicide as a side effect. The pharmacist where we had all of Clay's prescriptions filled never mentioned suicide as a side effect. The first time that we were ever made aware of any relationship between Accutane and suicide was when we heard the news stories about Congressman Stupak's loss of his son and the information that he uncovered. Looking back, I have to assume that neither the dermatologist nor the pharmacist knew anything about the link between Accutane and suicide.

We are given so much freedom in this country to make choices for ourselves because we have so many checks and balances built into the system to protect the citizens sometimes we make those choices blindly. That trust has been violated. I am not sure who is to blame. I do not have those answers. I just know that that trust and faith that I once had has been greatly diminished.

Also, in looking back, I wish that I had taken seriously that young investigating officer who investigated Clay's death when he asked me the question back in January, was Clay taking Accutane and did I think that this attributed to his death. Oh, how I wish I had taken him seriously then, and maybe Congressman Stupak's son would be here with us today.

I would be happy to answer any questions you might have, Mr. Chairman.

[The prepared statement of Mr. Jackson follows:]

Congress of the United States
Committee on Government Reform

Hearing
"Accutane - - Is this Acne Drug Treatment
Linked to Depression and Suicide?"
Tuesday, December 5, 2000

Testimony of Charles H. "Stoney" Jackson, Jr.

Thank you for inviting me to come hear and testify before this committee today. This will be very difficult for me to talk about however it is extremely important for me to be here before you today, if it will prevent just one parent from having to experience the pain and grief that my family has had to endure then all of this will be worthwhile.

In April of 1997 I took my oldest son Clay who was 14 years old at the time to his first appointment with a dermatologist. His course of treatment was the normal expectation for any teenager, monthly facial cleansings and antibiotics. In September of 1998 at the age of 15 Clay's treating physician added the use of Brevoxyl gel to his treatment. In June of 1999 Clay was now 16 years old and could take himself to see the doctor, his treating physician changed his medication to Retin A. In August of 1999 his treating physician changed his medication to Differin. Each time the dermatologist would change Clay's medication Clay would come home and tell us that they had changed his prescription and we need to take it to the pharmacy to be filled.

On October 6 1999 at age 16 Clay's treating physician decided it was time for Clay to begin using Accutane. The doctor ordered a blood test and sent home with Clay a brochure, copyright dated 1994 Sixth Edition, about Accutane with all of the benefits and with a whole host of side effects of which 90% did not pertain since Clay was a male patient. It did mention depression, only if you had a family history of, but there was no mention of suicide. Clay explained that the doctor needed our permission before he could prescribe this medication. Clay explained the side effects that the doctor told him he could expect which were dry skin, chapped lips and could easily be sunburned. The doctor told Clay that he knew we did not have a drug card with our health insurance plan, so Clay needed to talk to us before he would write Clay a prescription because it was very expensive and he was concerned whether or not we would be willing to pay for the medication. Wanting what was best for my son and some of Clay's friends at school were using the drug, so I decided to give my permission to start his treatment. A decision that has haunted me now for the last 60 days. On October 15, 1999 I had the first prescription for 40mg of Accutane filled at the pharmacy for Clay to take. The pharmacist said for Clay to be careful and wear sun block every day because he could be sunburned very easily and that he could expect to have dry skin and

chapped lips. The same thing the doctor had told Clay earlier. There was never any discussion with the doctor or the pharmacist about the risk of suicide while using this drug.

As predicted Clay's skin did become very dry, his lips would get chapped and if he forgot to apply sunblock he would get sunburned. His acne did get worse in the beginning and then it began to clear up. He did experience some back pain the first month while taking the medication, this was the only side effect that Clay had that we weren't expecting. Everything else seemed to be normal.

Then on January 13, 2000 our 17 year old son and my best friend, Clay, died from a self inflicted gun shot in our home. Around 4:00 PM in the afternoon my wife and my 10 year old son came home to find Clay's lifeless body dead in his bedroom. I will never be able to remove what they saw that day from their memory, this will stay with them for the rest of their lives. Clay had left school at noon to come home and eat lunch which he did on several occasions. When he did not return to school none of the teachers or administrators thought much about it, Clay was so involved in so many different activities they assumed he was attending one of these.

At the time and for several months, nobody could explain what possibly happened on that day. Was this an intentional act or was it some horrible accident that could have been avoided. During the course of the investigation of Clay's death by the Sheriff's department, the investigating officer asked if Clay was taking Accutane and did we think this drug might have attributed to his death. We replied that yes Clay was taking Accutane but thought it to be ridiculous to think that could possibly have anything to do with his death, it's a skin medicine to clear up acne. The officer agreed with us and he continued his investigation. The final cause of death as determined by the county medical examiner was that Clay shot himself.

On October 5, 2000 my wife and I caught the last 3 seconds of a story on the 10 o'clock news on a local TV station. We both looked at each other and asked what was that about. I went to my office the next morning and pulled up the local TV station's website and found the story that caught our attention. It was a very brief story and did not tell a whole lot. I asked the four ladies working in our office if any of them saw the story. They had all four seen the news story, it was about Congressman Stupak's loss of his son, they said it was a story about a young man that had lost his life and the only thing different about this young man and Clay, was their names. I went to the House of Representative's website and found Congressman Stupak's website where I found that he had already created a folder for Accutane. What I pulled up on Congressman Stupak's website was unbelievable for this would be the first time that I had ever seen or heard anything about the FDA ordering the drug manufacturer of Accutane to include suicide in their product warning as far back as February of 1998. I spent the rest of that day going to various Internet search engines and typing in the word accutane. I was

astonished to find so much negative information concerning this drug and that this information had been out there for so many years. Why didn't we look into this before we agreed to let Clay take this. Then we thought maybe it did say something in the packet and we just overlooked the million word small print on the warning label that came with the packet. I went to the local pharmacy where we had all of Clay's prescriptions filled and asked them if there was a computer printout that had the warnings and side effects or was it just the stuffer that came with the packet. They said there wasn't anything on the computer, the only thing that they provided was what came with the packets. I asked if they would mind removing one of the warning stuffers and let me see it. They removed one and as I suspected, it had no warning concerning suicide. I asked them if they knew there was a new warning label out concerning this product and they said they had heard something about it but wasn't sure, something was on the news or something, but they had not seen anything in any of the trade journals that they receive. I then asked if they would mind checking all of their inventory of Accutane and see if by chance any of them had the new warning label. They removed all of their packets from their inventory and none of them had the new warning.

My wife and I left town for a few days to get away, but before we left I contacted some insurance underwriters, nurses, other pharmacist and friends to look into this matter for us and to get back with us to make sure this wasn't just an isolated case. We were overwhelmed by the amount of responses that we received reporting that this was not an isolated case and they provided us with even more information concerning all of the psychological side effects associated with this drug. And the fact that this information had been made available for several months prior to Clay beginning to use Accutane.

All of a sudden all of the pain that we experienced at the time of Clay's death was coming back. It was as if we had never grieved at all, we were having to relive this nightmare again. More unanswered questions kept us up at nights and brought out a stage of grief that we had not experienced until now. ANGER!

How could a doctor send an outdated brochure home with a sixteen year old to talk to his parents about taking this powerful drug without the doctor ever having any conversation with the parents. How did he not know about these psychological side effects, or if he knew why didn't he tell us about them. How can a doctor prescribe a medication that is clearly licensed to be used as a treatment of last resort and for the most severe cases of acne. Clay's acne was very mild, there was no reason for Clay to be using Accutane. Why was his main concern whether or not we were willing to pay for this treatment.

How can a drug company receive such a stern warning from the FDA to change their warning label and not recall all of the outstanding inventory in all of the pharmacies and make that change immediately. Why has it taken so long to make the changes to their warning label. Their slow response and denial of the

need for the new warning makes you suspicious of what are they trying to hide that we don't know about.

As an insurance agent for 22 years I had to ask myself Why would an insurance company pay for a drug that contains such a warning about the risk of suicide that is being prescribed to teenagers.

Clay was not a depressed teenager, he was full of life. He was a member of the 4-H of which he held various offices over the years. He was nominated to the Who's Who in High School Achievement his Freshman, Sophomore and Junior years. He was in the Gifted and Talented Program at school. He was on the Varsity Baseball Team for his school as a Freshman and as a Sophomore and was already being recruited by several colleges and universities. He was also an active member of the FFA, serving as Vice President for his local chapter and the Lubbock District FFA. Clay was on the Chapter Conducting team and participated in many livestock shows around the state. He was a member of the Courtesy Corps at the last National FFA Convention in Kansas City, Mo. and at the first National FFA Convention in Louisville, Kentucky. Clay also competed in UIL Persuasive Speaking, Clay recognized that having all of the knowledge in the world wouldn't benefit you if you couldn't speak in public or have the ability to express yourself. Evidence of this is a poem that Clay wrote for his Advanced Placement English class on October 26, 1999, just 11 days after he started his treatment of Accutane. (A reprint of this poem is included at the end of the packet) The two things that Clay loved doing more than anything, livestock shows and playing baseball, were just about to begin, the first stock show was scheduled for the day after he died. Clay didn't have time to be depressed there was too much of life yet to experience and too many dreams left unfulfilled.

Congressman Stupak's son died more than five months after Clay died. I have to wonder what if I had taken the investigating officer in Clay's death seriously and looked into his suspicions about whether the drug Accutane had something to do with Clay's death. What if I had found then what I know now and what if I could have garnered this much attention, would his son be alive today. I don't guess we'll ever know that answer, but what if we don't do anything now, how many more teenagers will die needlessly and how many parents will have to go through the most painful experience that you cannot even begin to imagine.

Life is Short

Life is short, pray hard.
When I think I'm alone
Is the time I'm really blessed.
Because that is the finest hour
When God and I get closer.
Even if I don't see it right then,
God is my best friend, my closest friend.

Life is short, play hard.
I grew up being a Wildcat,
And I've never known how to dog it.
There has always been that fire inside
That burns rapidly out of control.
I might not be number one at the end,
But my reward is as precious as a diamond.

Life is short, and I've lived hard.
As I near my senior year of high school,
Many fond memories come back to me,
Loud and soft ones, pleasant and painful ones,
The memories are instilled in my heart forever.
But the real advantage I have over everybody else,
Is that I'm a Wildcat, I always have been and always will be.
My friends, teachers, coaches and memories
Will always be held close to my heart,
I may outgrow the letter jacket and even this school,
But I'll never outgrow the memories and friendships.

Mr. BURTON. First of all, on behalf of the committee, I want to thank you all for being here, and I want to once again express our condolences for the tragedies that you have had to encounter and will continue to live with.

Let me start with you, Mr. and Mrs. Baumann. You found out after your son was gone that, prior to his death, on the Internet there was information that showed that there was depression and possible suicide if they took Accutane.

Mrs. BAUMANN. That is correct.

Mr. BURTON. So this information was on the Internet before this tragedy occurred, but you had never been told that by a pharmacist or a dermatologist or the company itself?

Mrs. BAUMANN. That is correct. The information that the dermatologist gave me are brochures that are made by La Roche that were copyrighted in 1996 and in 1997.

Mr. BURTON. But the point I want to make is that had you been aware of the problem when it was first put on the Internet, if it had been properly given to you by the company or the pharmacist or the dermatologist, this whole tragedy very well might have been avoided?

Mrs. BAUMANN. I agree.

Mr. BURTON. How about you, Mr. Jackson?

Mr. JACKSON. Yes, sir. The same situation. This was 9, 10 months after Clay died before we even suspected anything like this, and we saw the news story, went to Congressman Stupak's Web site and saw the information that he had.

I think what got our attention was that, even though it was 9, 10 months later, we heard the little news story on the 10 o'clock local news and we saw like the last 3 seconds, and my wife and I both reacted because there was something about Accutane, something about suicide, but we didn't catch the whole story. And that was—that put us back to January when this investigating officer asked us this. You know, at the time we thought it to be absolutely ridiculous, and now we hear this story, we find Congressman Stupak's Web site, we see all of this mountain of information that has obviously been available for as much as 2 years prior to Clay's death.

Mr. BURTON. So had you been able to have that information before, you would have seen the signs and it very well may have been avoided.

Mr. JACKSON. There would have been absolutely no way that young man would have ever been on that drug. Because the other thing we learned was that it was a drug of last resort and for very severe cases of acne. Clay did not have those traits. In my opinion, he had no reason to be on this drug. He had a normal, 16 year-old face that—it just did not—it was not the severe case that this drug is licensed to be prescribed for.

Mr. BURTON. Mrs. Callais and Amanda, had you known what was available prior to Amanda going on Accutane, you probably wouldn't have had her on that, or at least you would have noticed the signs.

Mrs. LORI CALLAIS. I think that we possibly would have started it. You don't know until you are on this drug how you are going to react. But I know had we had the information—I can only tell

you what happened when we walked into the emergency room and my husband looked at the emergency room physician and he said, do you think Accutane could cause this, because it was the only drug she was taking, and his response was, no, that is an acne drug. So, had we known, we would have taken it away from her immediately, but we didn't have that option, so she continued it.

Mr. BURTON. But the point is the physician at the hospital when you went had no knowledge whatsoever about the side effects of Accutane, even though it had been reported much earlier and was on the Internet.

Mrs. LORI CALLAIS. I don't know that at that time, because this was back in 1997, it was on the Internet. Apparently, it was in the PDR, buried, the possible depression, but we didn't know that, and apparently neither did the physicians. Because had we known any of that and had it been available to us, we definitely would have taken her off Accutane.

Mr. BURTON. OK. Thank you.

Mr. Waxman.

Mr. WAXMAN. Thank you, Mr. Chairman.

Thank you all for your testimony. I know how difficult it must be to come before a committee of the Congress and share your pain, and we certainly want to extend our sympathies to you. I think your being here is very important as we explore this issue and we learn what we can.

You have all said, as I understand it, that if you had known about this risk, if there was some information about a risk of suicide versus clearing up some acne, none of you would have put your children at that kind of risk. Is that a fair statement from all of you?

Mrs. BAUMANN. Yes.

Mr. JACKSON. Yes.

Mrs. LORI CALLAIS. Yes.

Mr. WAXMAN. And you didn't know until very late that the problem in the case of suicides might have been related to using Accutane. Once you learned, or at any point, did you ever let the company know that you think there was a problem related to the drug or let the FDA or your doctor know about it?

Mr. JACKSON. We notified the FDA. We filled out an adverse event report form and sent it to the FDA. I found it strange that that was a voluntary reporting system that we were supposed to do, but we were not aware that it is even out there. And a dermatologist for sure isn't going to be sending in that type of a report.

Mr. WAXMAN. And this was how many months after your son's death?

Mr. JACKSON. This was in—it is October or November of this year when we sent the report in.

Mr. WAXMAN. So it was after you heard about Congressman Stupak's son and you started making this connection and then you took it upon yourself to let the FDA know.

Mr. JACKSON. Right.

Mr. WAXMAN. Did you let your doctor know?

Mr. JACKSON. No. You know, it is extremely hard to go back in that office, and because of everybody is so scared of getting sued

and nobody wants to say anything, so nobody will talk to you. I don't want to put that attitude out there, but I was interested in knowing what was in Clay's medical file. And I called over there and I asked to have a copy of all of his medical records and they said, no problem, would you like to come by and pick those up. Yes, that would be fine. So I went by later that day and signed the release and picked up a copy of his file and left, and it was just business as usual. There was no, how are you doing or—you know what I mean? It was really strange. And I go back out in the car and I sit in the parking lot, and what I could read of his handwriting, you know, there is absolutely nothing in that file. It is just the dates of the appointments.

Mr. WAXMAN. As far as you know, the doctor didn't even know about the association of Accutane with suicide.

Mr. JACKSON. No. And this is a highly respected dermatology clinic in our community. This isn't some rookie—I mean, this is a prominent, very well respected dermatology clinic in our community, and the brochure that we come home with is dated 1994, and when he was put on the drug was in 1999, 5 years later.

Mr. WAXMAN. Mr. and Mrs. Baumann, I am asking the question, were you contacted by the doctor or the company or the FDA? Not in any way to be critical, but just to know if you did; and if you didn't, I can understand you not doing it. But what would be your answer?

Mrs. BAUMANN. I contacted the doctor 2 days after Dan's death to let him know that Dan had passed away and that we wouldn't be making his next appointment that week, and this was before I even knew that there may be a potential link between Accutane and depression and suicide. I don't know if the doctor reported it to the FDA. I can guess he didn't, because I would assume that someone would have contacted me; and, like I said, I do know that, 5 months after Dan's death, the doctor is now not in practice and teaching at Loyola University.

Mr. WAXMAN. Well, Congressman Stupak recommended further studies about the links between Accutane and psychiatric disorders, as well as for increasing the information for patients and for families to receive that information about those risks. I assume all of you think, at the minimum, we ought to know more about this problem and people ought to be advised about the risks that they never even would have dreamed that they are subjecting their children to.

Mrs. Callais, did you ever contact anybody about your experience with Accutane and the relationship you started to think was there?

Mrs. LORI CALLAIS. Actually, I did. The next day, the day that I found out, after I found out about the warning, when it first came out from the FDA, I called Roche Pharmaceuticals, because their number was on there, because it said, report it, and I called. And I remember something that the person that I talked to said that just struck me as horrible. She said, you know, we have had a lot of calls about those things today. And I thought, my God. And I said, how many kids have died? And she said, hmm, I don't know. I also talked to them again a couple of months later, because they were supposed to call back in 30 days to see how Amanda was.

They didn't bother. As you can understand, I was furious by this time.

I have talked to my daughter's dermatologist, and I talk frequently now. I still use that dermatologist. It took a lot to go back, but I trusted that she didn't know, and she didn't know. And since that time, she and I have talked. She always wants to know that I am doing it, because we talk all the time. I go everywhere I can to tell about this drug. And she has said that, since Amanda's case, she has pulled three patients off of the drug, and she now asks them about how they are doing, if they are depressed. But she is the only dermatologist that I know of in our entire area that even bothers to ask, and she only asks because she knows about Amanda. So I don't know that anybody else ever even checks. I mean, who tells their dermatologist they are depressed? You go to your doctor. You don't go to your dermatologist.

Mr. BAUMANN. I know that Stacy has talked to the pharmacy about it on a couple of occasions and I think even recently the pharmacist said that they have done some of their own investigating as well.

Mr. WAXMAN. Mr. Chairman, if you will allow me, we do know that even before any of you had your experiences with Accutane that the company knew that there was some association with the use of Accutane, and the FDA had knowledge about it as well. In Europe, they are taking stronger action. My feeling is that they are the ones who should be telling you, not you telling them, so that we can avoid these problems.

Mr. BAUMANN. The word that came to my mind when I did find out is I felt bushwhacked.

Mr. BURTON. Mrs. Morella.

Mrs. MORELLA. Thank you. I want to add my voice to those who have said that we thank you very much for coming and telling your story. As a parent myself, and I think all of us on this panel are, we can empathize with what you have been going through, as much as one can who hasn't experienced it.

It seems to me, from what you have said, Accutane has almost an immediate reaction. I mean, we are talking about things that have happened within several months; is that correct?

Mrs. BAUMANN. Probably several weeks.

Mr. BAUMANN. From listening to Amanda in the back give a report to a news—it is exactly the same thing that happened with Daniel, too, and I can't remember the question that was asked, but it was so appropriate. The reaction is immediate, but it is continually worsening. Would you say that is accurate?

Ms. AMANDA CALLAIS. Since I have been on the drug, and I am the only one on this panel who can state how it feels to be on Accutane, the physical side effects occur very quickly, but within days of taking Accutane, my mood began to change. Within a week, I was crying for absolutely no reason.

I think one of the easiest examples to tell people is my dad bought me a jacket that I had wanted, I wanted it for a few months, and when he gave it to me, I looked at it and I burst into tears, because he hadn't asked me, and I didn't understand why I was so upset. But I was, and I couldn't stop crying. So it definitely

takes effect very quickly. Within days, my mood had begun to change, along with the physical side effects of the drug.

Mrs. MORELLA. I am trying to understand, the warning statement that is contained within the insert with Accutane now warns against depression and possible suicide; is that correct? It does now?

Mrs. LORI CALLAIS. It does now, but I caution you about one thing on this depression. It is not a normal depression. It doesn't act like you would normally see. Also, if you don't know what teenage depression is, or clinical depression, you have no clue.

This doesn't happen in such a way that you wake up one morning, oh, my child is depressed. It happens each—a little more each day until finally you wake up 1 day about 6 to 7 weeks later, and it is generally about 2 months into the treatment, 7 weeks, something is wrong. So it is very, very gradual. So while it may explain depression or say depression now, you need an explanation of what depression is.

Mrs. MORELLA. Someone who is on Accutane needs to be watched, monitored every day, to see whether there are nuances that can be determined from 1 day to another.

Now, this warning was not on there, though, back in what 1997? Did it happen in 1998, is that what we are talking about?

Mrs. LORI CALLAIS. February 26, 1998, the warning came out.

Mrs. MORELLA. 1998. And the French did it before we did?

Mrs. LORI CALLAIS. In March 1997. I guess French people are more receptive to depression than Americans—

Mrs. MORELLA. Or more aware of it, in terms of the sensitivity of it.

Mrs. LORI CALLAIS [continuing]. But I hope not. But that's what happened at the time. I realized that, and I wondered—I thought that if another country came out with such a warning, that the FDA would—has requirements that Roche should have immediately told them.

Mrs. MORELLA. FDA has that reputation of making sure that every precaution is taken well before other countries, generally.

And I think all of you have said that your doctors really were not aware of the intensity of the consequences of Accutane.

Mr. Baumann.

Mr. BAUMANN. I am not sure if they weren't aware. One of my customers is a physician, and he says that he does not routinely tell everybody all the bad things that can happen as a result of a drug being administered, because the instances in many cases are so small of bad things that it is just whether it is not worth it or what, I don't know.

Mrs. MORELLA. It seems to me that it should be in great big, bold print, because I have read aspirin bottles which say, you know, all kinds of horrible things could happen as a result of taking more than two aspirin at any one time.

Mr. BAUMANN. I would like to respond to your previous question. We did meet our friend, who was picking up an Accutane prescription for her son, and I asked her to look at the labeling. I even asked her to save it for me, but apparently she didn't think that it was an important thing that I was asking her, so she didn't, but

there was nothing on her labeling. And this was just last summer—this summer.

Mrs. MORELLA. Sometimes even labeling is such small print also; not only are we not accustomed to looking at warnings, but such small print.

Again, it almost sounds as though doctors, either they are—they feel that they are worried about the risk of being sued, whether that is a problem, liability problem, or whether they just don't know. So it seems like in a recommendation that might come from this committee there should be something with regard to educating doctors, too. Do you agree?

Mr. BAUMANN. Definitely.

Mrs. MORELLA. I mean, I am trying to figure out what it is we need to do.

Mrs. BAUMANN. I would say some physician education and patient, potential patient, education. We need to educate the children and the parents.

Mrs. LORI CALLAIS. One of the things that I noticed about physicians, dermatologists particularly, and what I have heard said over and over from them—you have to understand I now go and talk, I ask everybody about it—they will say, well, I have never seen it before. Or they will say, well, the risk is so minimal that, you know, I have not seen this; it is not something to worry about.

I don't think that the dermatologists actually believe that depression is a possibility, and if they don't see it—and if a child commits suicide, they will never see them again, and if a child is depressed, the amazing thing about Accutane is you pull them off, and they get better. So once they stop the treatment, well, then they are OK, so then you don't ever see that part of it. So I don't think that they are really aware, or if they are, they just assume it won't happen to them.

Mr. BAUMANN. I feel that parent education is most important because it is the parents that monitor their children most of the time. The physician only sees them on occasion, once a month, and the parents—had I known what Amanda here had said earlier, it would be very easy to see the signs as a parent.

Mrs. LORI CALLAIS. May I ask something that I have wanted to see done ever since then because I realized it? If there was some way that every time a child went to the dermatologist right now they could fill out a little—just a little checklist and a parent had to fill that checklist out of certain symptoms, that would clue you in as to what is going on; as a physician, you could take it and do it. I even think there is one in existence today, and that can be done. It is a profile of some sort, something that lets the parent and the physician know what is going on with that kid.

Mrs. MORELLA. You mean a profile before?

Mrs. LORI CALLAIS. Every time—you start before, what is your mood, how many hours a night do you sleep, do you have insomnia or something, something so you have a base to start, and then once they start, if every visit that child went to the dermatologist, and I am saying very selective, not mild or moderate anymore.

Mrs. MORELLA. OK. So you continue to monitor?

Mrs. LORI CALLAIS. You continue the monitoring so that physician has, right in their hands, they can see something going on.

But you need the parents to do that because I am afraid the kids would not necessarily tell the truth. They would be afraid they would be taken off.

Mrs. MORELLA. Exactly.

Mr. BAUMANN. One thing that seems to be a tie here that I heard Mr. Jackson say also in the back was lean people seem to be—low body fat seems to make a difference.

Our son was very thin. He stopped eating. He slept all the time. He didn't want to go to school. He didn't care about his grades. He lost his desire to live, I believe, and he also was very thin at the end and very depressed. He stopped taking care of our dogs, and he had done that all of his life. He loved those dogs.

Mrs. MORELLA. It almost seems like there should be a connection between the mental health groups as well as the physical health groups in this particular situation. Maybe we can work something out.

I want to thank you very much for your—did you want to make another statement?

Mr. MICA. I believe there are some obvious signs. As a parent now, hearing what I am hearing today, I think there are some obvious signs that can be very easily interpreted, and maybe we can avoid other people having the problems.

Mrs. MORELLA. And, again, the studies that have been mentioned, I would think we should move ahead fast with those. I thank you very much.

Thank you, Mr. Chairman.

Mr. BURTON. Thank you, Mrs. Morella.

Mr. Horn.

Mr. HORN. Thank you, Mr. Chairman.

I have been very moved by your studies, and I have known a lot of children that have had Accutane when my own children were going to school. Fortunately, we did not have the problems that occurred and led to death, but the dermatologists that I have known have put it under a very controlled manner of just 6 weeks or that, and then they haven't given it anymore.

Now, to what extent they have this knowledge, I think, Mr. Chairman, there is a nice list of major associations attached to an article in your opening testimony. We ought to send them all the files we have got here and copies so that they could understand, your daughters, your sons, what happened to them. I would think they ought to be getting increasingly conscious of the effect of this, and then obviously in the second panel we will get into it. But if we have to do it on a human side, certainly we could give some of you the package of testimony we have had, and that might sway a few doctors into asking the questions you want them to ask that they apparently, according to your testimony, do not ask.

In my opening statement, I said I would like to know the difference between suicides that have Accutane and the suicides that don't, and the degree to which that is likely to happen. Now, maybe we will hear that on panel two, I don't know, but that certainly is a question we ought to ask and try to deal with.

So I thank you and yield back my time.

Mr. BURTON. Thank you, Mr. Horn.

I want to thank the witnesses for their testimony. I know it has been very difficult for all of you. Let me just say that we on this committee and in the Congress will do everything we can to make sure that the information that you have given us today in your testimony is disseminated as widely as possible so that parents and children across the country will have as much information as possible so that these tragedies won't occur in the future. Once again, thank you very much. Thank you very much for being with us today.

Our next panel is Dr. Pariser, Dr. Jacobs, Dr. O'Donnell, Dr. Bull and Dr. Huene.

Dr. Huene.

Mr. MITCHELL. Mr. Chairman, it was the Department's understanding that Dr. Huene was coming to accompany the witness and would answer any questions that our witness Dr. Bull might not be able to answer for you. I thought that was our understanding with the staff.

Mr. BURTON. That's fine. Does she prefer not to be at the table; is that correct?

Mr. MITCHELL. Yes, Mr. Chairman, that is our preference.

Mr. BURTON. OK. Well, if we have questions for her, I presume she will come forward at the time.

Mr. MITCHELL. Yes, Mr. Chairman, that's the case.

Mr. BURTON. Would you stand, though, Dr. Huene, along with the rest of the table.

[Witnesses sworn.]

Mr. BURTON. OK. We will start with Dr. Pariser.

Did I pronounce that correctly?

Dr. PARISER. Yes, sir. Thank you. Dr. David Pariser.

Mr. BURTON. You are a dermatologist; is that correct?

Dr. PARISER. Yes, sir.

STATEMENTS OF DAVID M. PARISER, M.D., FACP, AMERICAN ACADEMY OF DERMATOLOGY, PARISER DERMATOLOGY SPECIALIST, LTD., VIRGINIA CLINICAL RESEARCH, INC., NORFOLK, VA; DOUGLAS JACOBS, M.D., ROCHE CONSULTANT, ASSOCIATE CLINICAL PROFESSOR OF PSYCHIATRY, HARVARD MEDICAL SCHOOL, WELLESLEY, MA; JAMES T. O'DONNELL, PHARMD., M.S., ASSISTANT PROFESSOR OF PHARMACOLOGY, RUSH MEDICAL SCHOOL, PALLENTINE, IL; AND JONCA BULL, M.D., FOOD AND DRUG ADMINISTRATION, ACCOMPANIED BY PHYLLIS HUENE, M.D.

Dr. PARISER. Good afternoon, Mr. Chairman and members of the committee. My name is David Pariser. I am a dermatologist in private practice in Norfolk, VA. I am also the chief of dermatology and a professor of dermatology at the Eastern Virginia Medical School in Norfolk, and I am on staff in four Norfolk-area hospitals.

For the last 24 years, I have had the opportunity to treat thousands of patients with acne of varying degrees of severity. Furthermore, I also maintain an active practice in clinical research. Over the last 8 years, I have participated in over 150 research projects and clinical trials, including numerous acne clinical trials for a variety of pharmaceutical companies, including three trials funded by Roche Pharmaceuticals.

I have received indirect funding in the past through the National Institutes of Health, but not any from that agency in the past year.

In addition to my daily medical duties, I am a member of the board of directors of the American Academy of Dermatology. I am here today on behalf of the over 13,000 members of the Academy and millions of patients, and I wish to express my appreciation for your invitation to appear before you and discuss the drug isotretinoin, commonly referred to today as Accutane.

My No. 1 concern when treating patients, and that of the Academy's, is for patient safety. We are committed to ensuring the safe use of this drug, and we are also committed to ensuring that Accutane continues to be available to patients who need it.

Like many of my colleagues, I was drawn to the specialty of dermatology for intellectual as well as personal reasons. As a young man, I personally suffered from severe cystic acne, and today my face bears the scars of my battle with this disease.

I have a 20-year-old son who suffers from severe cystic acne, and I have prescribed Accutane for him. He just finished his second 5-month course of Accutane at age 20, having taken a previous course when he was 15.

Acne is not simply a cosmetic problem. This is a disease, and in some cases a very serious skin disorder. It is the most common skin disorder of any age group affecting 85 percent of all teenagers, approximately 20 million Americans. Acne is a disease of the pilosebaceous unit, the hair follicle, which consists of an oil gland connected to it, and although found all over the body, these pilosebaceous units are larger and more numerous on the face, on the scalp, on the upper back and the chest. There is where acne is most prevalent.

In normal skin, the oily substance, called sebum, produced by the sebaceous gland empties onto the skin surface through the opening of the follicle. So while we do not know exactly what causes acne, we do know that changes in the lining of this hair follicle occur that prevent the sebum from passing through the follicle to the skin surface.

In acne, the cells that line the follicle are shed too quickly and clump together, and these clumped cells block the follicle so that the sebum cannot reach the surface of the skin; and then bacteria, which normally and harmlessly live on the skin surface, begin to grow in the follicle, and all of these factors together produce the inflammation.

Now, dermatologists will classify the type of acne by the presence of particular types of lesions. And in the written information that I have provided for you, there is a detailed description of the different forms of acne lesions.

But in addition to these lesions on the skin, acne has a number of psychosocial effects. Studies have shown that people with acne suffer from social withdrawal, decreased self-esteem, poor body image, embarrassment, feelings of depression, anger, and also higher rates of unemployment.

As a clinician, I often see patients with moderate to severe acne who have difficulty in making eye contact when speaking, and many cannot even bear to look at themselves in the mirror.

Many people believe that acne is a result of poor hygiene. Dirt or surface skin oils do not cause acne, and believing this myth can actually make acne worse because vigorous scrubbing and washing can sometimes actually irritate and interfere with topical therapy.

Acne is not caused by diet. Extensive scientific studies have not found any meaningful connection between eating things like fried foods and chocolate with acne, although in some individual patients there may appear to be a cause-and-effect relationship.

Acne is not caused by stress, although stress can influence acne and many other medical diseases.

Some people feel their acne is improved by sunlight, and some patients do get a temporary drying effect from sun exposure. Sun exposure should not be recommended as a major treatment for acne since it can lead to the development of skin cancer.

Dermatologists have a number of effective acne treatments at their disposal, and after appropriate evaluation a dermatologist may recommend cleansing agents, over-the-counter medications, topical and systemic drugs to treat acne. And again, in the written information supplied there is a more detailed discussion of some of the treatments.

Nonprescription products, such as cleansers, many over-the-counter medications, are, in fact, quite effective for mild cases of acne. In advanced cases, however, some of the stronger cleansers can irritate the skin and even further aggravate acne.

Prescription products, such as benzoyl peroxide, topical treatments, work by destroying bacteria that are associated with acne and works well for mild acne if used continuously.

Another product topically that's available over the counter without prescription, salicylic acid, does help to correct some of the abnormal shedding of skin cells and unclogging the pores.

If acne fails to respond to some of these intermediate treatments, this is the place for the oral vitamin A derivative known as isotretinoin, or Accutane.

Accutane has proven to be our most powerful weapon against recalcitrant cystic acne and has dramatically changed the way dermatologists manage this terrible disease. Despite its tremendous benefits, though, this drug is not prescribed casually. It is a serious medication. Typically, patients with treatment-resistant acne are placed on a 5-month course of Accutane, and after usually 2 to 3 months, most patients will begin to see a dramatic decline in the number of nodules and deep cystic lesions. A few patients, such as my son, may require a second course of treatment at a later time, but generally not more than two courses.

Now, before prescribing the drug, I counsel patients about the many risks that are associated with Accutane. I instruct them not to take any vitamin supplements containing vitamin A while taking Accutane since there may be some additive toxicity. I tell them to avoid sun exposure. I test the blood to assess liver function if needed and always test for level of the triglycerides, fatty substance in the blood, which may be elevated in up to 25 percent of people who take Accutane.

Of course, women who are pregnant or may become pregnant during therapy must never take the drug. There is a pregnancy program that is developed by the manufacturer of the drug which

I have incorporated into the routine of my office. I speak frankly to all female patients about the devastating birth defects and discuss the importance of using two forms of contraception.

And all women of child-bearing potential, that is any female old enough to have a menstrual period and not surgically sterilized who is prescribed this drug, must have a negative pregnancy test prior to receiving their first dose and should not begin their Accutane until the second or third day of the menstruation.

I am aware of the warnings on the label concerning the changes in mood, depression, and I monitor my patients' behavior. I have a personal belief that it is as important to be up front and honest with patients about their mood changes, potential depression, just as objectively as I talk to them about the dryness and chapped lips which they will get or about the potential elevation in the triglycerides.

I am aware of the reports that have been mentioned already today about patients who take Accutane who seem to get mood changes, who go off it and mood changes get better; they go back on, and the mood changes can recur. I have had one or two patients myself who have had that.

I am also aware of suicide of patients who have had severe acne that have not been prescribed Accutane; mostly young men who—where the burden of the taunting of their peers was too heavy to bear.

Far more commonly, however, far, far more commonly, I have seen the remarkable positive changes in patients' mood and demeanor due to the resolution or significant improvement of their disease. It is as if a great burden has been lifted from these people, and their faces and their bodies are cleared of acne.

If I have any doubts about the patient or doubt whether a female will be compliant about using birth control, or if anyone has an underlying mental health concern or previous history of depression, I may not prescribe this medication; but I would say that there are people who have clinical depression and who are on antidepressant medications for whom I have prescribed Accutane when given appropriate psychological followup.

Given the many benefits of this drug, I am concerned about efforts to create a mandatory registry. A mandatory registry may not be the best method to improve patient safety. Regulation cannot and must not be substituted for the frank, personal and complete discourse inherent in the physician/patient relationship.

To this date, it is my understanding that the FDA has mandated only one mandatory physician/patient pharmacy registry system for the drug called thalidomide. This drug, there has only been 11,000 patients registered over the last 2 years. Now Accutane, on the other hand, is prescribed to nearly 500,000 new patients annually; a tremendous high number compared to thalidomide, mostly by practitioners in private practice. If there were a registry program that was instituted, the economic burden and administrative burden of this would be tremendous for patients, for physicians, for pharmacists, let alone the tremendous increase in the cost of therapy.

Education of all parties, physicians, patients, nursing staff, medical support personnel, pharmacists, is paramount and must be an

ongoing enterprise. Efforts to educate patients should be and have been reevaluated and improved, and new knowledge must be incorporated into physician practices.

Continuing medical education and nursing education programs are and continue to need to be amended to assure that new information is disseminated to all. This is how it should be; and education and not regulation is how we will further reduce the small number of inadvertent pregnancies and the psychological events that are occurring.

Thank you again for allowing the American Academy of Dermatology to appear before you today, and I will be glad to answer any questions at this time.

Mr. BURTON. Thank you.

[The prepared statement of Dr. Pariser follows:]

**Submitted testimony for David Pariser, MD
Hearing of the House Government Reform Committee
“Accutane-Is this Acne Drug Treatment Linked to Depression and Suicide?”**

December 5, 2000

Good afternoon, Mr. Chairman and members of the Committee. My name is David M. Pariser, M.D. I am a dermatologist in private practice in Norfolk, Virginia. I am also the Chief of Dermatology and a professor of dermatology at the Eastern Virginia Medical School in Norfolk and am on staff at four Norfolk area hospitals.

Since becoming a dermatologist, I have participated in over 150 research projects and clinical trials. I have participated in numerous acne clinical trials for variety of pharmaceutical companies, including three trials funded by Roche Pharmaceuticals. Although I have received funding in the past through the National Institutes of Health, I have not received funding from that agency in the past year.

In the 24 years that I have practiced dermatology, I have treated thousands of acne patients. The severity of the disease in these patients varied, and I have used a number of different treatment regimens to treat the disease.

In addition to my medical duties, I am a member of the Board of Directors of the American Academy of Dermatology. The Academy is the largest dermatological association in the United States and our mission is to promote and advance the highest possible standards in clinical practice, education and research in dermatology and related disciplines. On behalf of over 13,000 members of the American Academy of Dermatology and our millions of patients, I wish to express my appreciation for your invitation to appear before you today.

Like many of my colleagues, I was drawn to this specialty for both intellectual as well as personal reasons. As a young man, I suffered with severe acne and today my face bears the scars of my battle with this disease. If you were to attend any meeting of the Academy, you would notice that many of my colleagues have the same appearance.

Acne is not simply a cosmetic problem. Acne is a disease, and in some cases a very serious skin disease. Acne is the most common skin disorder of any age group and affects 85% of all teenagers, or more than 20 million Americans. In about 30% of acne cases, mostly women, the disease persists well into adulthood. It is not uncommon for dermatologists to have acne patients who are in their 30s and 40s.

Acne has a significant impact on our economy. Each year, Americans spend well over \$100 million for nonprescription acne treatments alone. Hundreds of millions more are

spent each year on special cleansers and soaps, prescription therapies, and physician visits. Time lost from school and work is also significant.

But what is acne, and how is it caused? Acne is a disease of the pilosebaceous units. The pilosebaceous unit consists of an oil gland (the sebaceous gland) connected to a hair follicle. Although found all over the human body, pilosebaceous units are larger and more numerous on the face, scalp, upper back and chest – the same areas of the body where acne is more prevalent.

In normal skin, the oily substance produced by the sebaceous gland empties onto the skin surface through the opening of the follicle. While we do not know the basic cause of acne, we do know that changes in the lining of the hair follicle occur that prevent the sebum from passing through the follicle to the skin's surface. In acne, the cells that line the follicle are shed too quickly and clump together. These clumped cells block the follicle's opening so that the sebum cannot reach the surface of the skin. Bacteria that normally and harmlessly live on the skin, called *Propionibacterium acnes*, begin to grow in the hair follicle. These bacteria produce chemicals that cause inflammation. Inflammation is a response to disease or injury that is characterized by swelling, redness, heat and pain.

There are a number of different types of lesions associated with acne. They are called comedones, papules, pustules, and nodules or cysts. Comedones are simply enlarged, non-inflamed hair follicles that are plugged with oil and bacteria. A closed comedo, also known as a whitehead, appears on the skin surface as small whitish bumps. An open comedo is also known as a blackhead because it looks black on the skin's surface. The black coloration of an open comedo is not due to dirt, but discoloration of the sebum.

Inflamed lesions vary in severity. Papules are more serious lesions than whiteheads or blackheads. Papules are inflamed comedones that appear as pink bumps on the skin and can be painful to the touch. More serious are pustules and nodules. Pustules are inflamed puss-filled lesions that resemble whiteheads, but with a red ring around the base. Nodules or acne cysts are the most serious of acne lesions. A nodule is a large, deep-seated, puss-filled, often painful lump. Acne with nodules often results in permanent scarring and requires treatment by a physician.

A dermatologist will classify the type of acne by the presence of particular types of lesion. Papulopustular acne also known as acne vulgaris is characterized by the presence of comedones and mildly inflammatory lesions. The severity of a case of papulopustular acne is determined by the ratio of comedones to papules and pustules. The higher the numbers of inflammatory lesions that are present on the skin, the more severe the acne.

Nodulocystic acne is more severe than papulopustular. As mentioned, these lesions are large, inflamed and extremely painful. The potential for permanent scarring is greatest with nodulocystic acne. Scarring occurs as a result of a flaw in the skin's healing process. As the skin tries to heal itself from the ravages of the nodules, pitting develops in the skin.

The most severe, and fortunately rare, inflammatory form of acne is called acne conglobata. In this form of the disease, comedones with multiple openings, nodules, abscesses and draining sinus tracts are present. Acne nodules are connected beneath the skin's surface to other nodules and bacterial infection is also present. This type of acne develops primarily on the back, buttocks and chest. It is extremely difficult to treat and sometimes requires surgery. Scarring is often very severe and keloidal. This type of acne is found in adults and not teenagers, primarily in males.

In addition to the lesions on the skin, acne has a number of psychosocial effects. Dr. Sulzberger, a renowned dermatologist, once said this about acne: "There is no single disease which causes more psychic trauma, more maladjustment between parents and children, more general insecurity and feelings of inferiority and greater sums of psychic suffering than does acne."

We now appreciate the significant impact that acne and acne scarring have on a person's outlook on life. Recent studies have shown that people with acne suffer from social withdrawal, decreased self-esteem, reduced self-confidence, poor body image, embarrassment, feelings of depression, anger, preoccupation, frustration, and higher rates of unemployment. These effects are interrelated, and may have a crippling impact on a young person's social life, academic achievement, and job status.

As a clinician, I often see patients with moderate to severe cases of acne that have difficulty making eye contact when speaking, look downwards when I speak to them, and often mumble their responses. Many often cannot bear to look at themselves in the mirror. These psychosocial symptoms are often exacerbated if the patient believes many of the lingering myths about the disease - that their case of acne is their fault.

Many people believe that acne is the result of poor hygiene. Dirt or surface skin oils do not cause acne. Believing this myth can actually make acne worse as vigorous washing and scrubbing will irritate the skin. Skin should be gently cleansed twice a day with a mild soap, patted dry, and if needed treated with an appropriate medication.

Acne is not caused by diet. Extensive scientific studies have not found a connection between eating fried foods or chocolate and acne. Of course, eating a balanced and nutritious diet always makes sense, but making a teenager feel guilty about the french fries that he ate for lunch is of no value in the fight against acne.

Acne is not caused by stress, although stress can influence acne. The ordinary stresses of day-to-day living do not cause acne. However, there are some stress disorders and forms of mental illness that are linked to the development of acne. For example, bipolar disorder, also called manic depression, is often treated with lithium and other potent drugs. Acne is sometimes a side effect of these drugs.

Acne is not improved by sunlight. While some patients do get a temporary drying effect from sun exposure or exposure to the ultraviolet radiation of a tanning bed, this effect is both short-lived and dangerous, as exposure to the harmful rays of the sun and tanning beds is linked to the development of skin cancer.

Another myth about acne is that you have to let it run its course. The truth is much more encouraging. There are a number of systemic and topical treatments that are currently available to treat acne. There is no reason that a teenager or adult should endure acne or run the risk of acne scarring today.

Your dermatologist has a number of effective acne treatments at their disposal. After appropriate evaluation, your dermatologist may recommend certain cleansing agents, over the counter medications or may prescribe more potent topical and systemic drugs to treat your acne. Your dermatologist can also help you to make more informed decisions on appropriate water-based, oil-free makeup and concealers.

Nonprescription products include cleansers advertised for the treatment of acne. In mild cases of the disease, these cleansers may be helpful. In more advanced cases, however, these cleansers may irritate the skin and further aggravate the acne. Other nonprescription products include benzoyl peroxide, a topical treatment that works by destroying the bacteria associated with acne. This product does work well for mild cases of acne, if used continuously. However, benzoyl peroxide has no effect on sebum production and does not slow the shedding of cells in the follicle that are responsible for blocking the follicle. Another product, salicylic acid, does help to correct the abnormal shedding of cells and unclogging pores. This product also has its shortcomings, as salicylic acid does not slow sebum production and like benzoyl peroxide must be used continuously. Stronger versions of both of these drugs are also available by prescription.

A variety of topical and systemic prescription treatment regimens are available. These drugs have varying mechanisms of action and all have side effects. Some drugs may be prescribed in combination with other drugs.

Topical creams such as adapalene, azelaic acid, tretinoin, and tazarotene are prescribed to unblock oil ducts. Adapalene is a retinoid-like compound that normalizes the differentiation of follicular epithelial cells resulting in a decreased formation of comedones. Individuals using adapalene are advised to avoid the sunlight and tanning

beds and products containing salicylic acid. Drying, itching, scaling and burning are common side effects of this product.

Azeliac acid is a naturally occurring saturated dicarboxylic acid. Azeliac acid acts as an antimicrobial, and itching, burning, stinging and tingling are common side effects. In rare cases use of azeliac acid has resulted in contact dermatitis.

Tretinoin is a topical retinoid that decreases the cohesiveness of follicular epithelial cells, stimulating mitotic activity in these cells and causing the extrusion of the comedones. As with adapalene, patients must avoid sun exposure and the drug must not be used on sunburned skin. Although true contact allergy to the product is rare, individuals with sensitive skin may suffer blistering and redness using the drug.

Tazarotene is a member of the acetylenic class of retinoids and is also prescribed for patients with psoriasis. Common side effects include desquamation, burning/stinging, dry skin, erythema and itching. More rare side effects include skin pain, fissuring, localized swelling and skin discoloration.

There are also topical sulfur preparations that are prescribed for acne. The exact mode of action for these agents is unknown, but it is believed that topical sulfur drugs both inhibit the growth of *P. acnes* and the suppress formation of free fatty acids in the sebum. Local irritation is a side effect and these drugs have also been linked to life-threatening or less severe asthmatic episodes in susceptible people.

Antibiotics are also frequently prescribed for acne patients. Antibiotics may be topical or taken orally (systemic). Antibiotics work by killing the *P. acnes* bacteria. Topical products are available in gels, creams and lotions. Systemic antibiotics are prescribed for more severe forms of acne, as topical antibiotics are limited in their ability to penetrate the skin. Of course, antibiotics do not address the other causative factors in acne and have significant side effects. Antibiotic resistance is also on the rise. Antibiotics must not be prescribed to women who are pregnant and some antibiotics may reduce the effectiveness of oral contraceptive pills, thereby increasing the risk of pregnancy during treatment.

Oral contraceptives are also prescribed to female patients to help counteract the effect of male hormones or androgens on acne. The maximum benefit of oral contraceptives on acne is usually realized in 3 to 4 months. Corticosteroids are an anti-inflammatory medication and may be injected by a dermatologist into very severely inflamed acne lesions to help heal the lesion.

If the acne fails to respond to these intermediate treatments, I will then prescribe an oral Vitamin A derivative known as isotretinoin or more commonly known as Accutane. I believe that Accutane should only be prescribed by dermatologists, who have a special competence in the diagnosis and treatment of skin diseases, especially

recalcitrant cystic acne. This is to ensure the safety of the patient, which must always be our top concern.

Accutane has proven to be our most powerful weapon against recalcitrant, cystic acne, and has dramatically changed the management of this disease. Despite its tremendous benefits, I do not prescribe this drug casually – it is a serious medication. However, I do believe that the benefits of this drug far outweigh its risks – if I did not, I certainly would not have allowed my son, who suffers from acne, to take this drug. My son recently completed a five-month course of therapy with Accutane.

Typically, patients with treatment resistant acne are placed on a five-month course of Accutane therapy. After several months on the drug, most patients will see a dramatic decline in the number of nodules. In a few cases, patients may require a second course of treatment.

This drug has a number of side effects, as all drugs do, some of which are significant. The most common side effects are mild or moderate in intensity and include dry skin, nasal dryness, and chapped lips. Some patients also complain of fatigue.

Before prescribing the drug, I counsel my patients about the risks associated with Accutane. I instruct them to not to take any vitamin supplements containing Vitamin A while taking Accutane. I tell them to avoid sun exposure while on the drug, a recommendation common to many acne treatments. I test their blood to assess their liver function and the level of their triglycerides. I warn them that they may have problems wearing their contact lens when taking Accutane and to see their ophthalmologist about obtaining eyeglasses.

Of course, this drug must never be taken by women who are pregnant or who may become pregnant during therapy. I have systematized the pregnancy prevention program developed by the manufacturer into the routine of my office. I speak frankly to my female patients about the devastating birth defects associated with the use of this drug, and the importance of not becoming pregnant while taking this medication. I also discuss the importance of using two, not one, forms of contraception during the course of treatment – one hormonal form of birth control as well as a barrier method. All women who are prescribed the drug must first have a negative pregnancy test prior to receiving their prescription and are told not to begin treatment until the second or third day of their next menstruation.

I am aware of the warnings on the label concerning changes in mood, which were added to the label in August 1986, including depression, and monitor my patient's behavior. These changes did educate physicians to look for mood changes in their patients. I have heard anecdotes from colleagues who have had patients who responded negatively to the drug, and whose mood recovered after therapy was stopped. These stories are fortunately very rare. I am also aware of cases of suicide in patients with

severe acne who have not been prescribed Accutane – young men for whom the burden of the taunting of their peers grew too heavy to bear. Fortunately, these too are rare. More commonly, I have seen the remarkable, positive changes in a patient's mood and demeanor due to the resolution of their disease. It is as if a great burden had been lifted as their faces and bodies cleared of the acne. Clearer skin facilitated social interaction, academic standing improved, and older patients felt more confident in their careers. However, the Academy believes, and I share this sentiment, that more study on the psychiatric effects of this drug should be undertaken.

If I have any doubts about my patients, whether I doubt that she will be compliant in using reliable birth control or if he has an underlying mental health concern, I will not prescribe this medication. Indeed, the physician education materials provided by the manufacturer clearly instruct physicians not to prescribe this drug if they have any doubts whatsoever. Should I note an adverse reaction in any of my patients taking Accutane, I alert the FDA's MedWatch program (which can be done by phone, fax, letter or email) and I contact Roche Medical Services using their toll-free number.

Given the many benefits of the drug, I am concerned about efforts by the FDA to substitute regulation for education. The creation of a mandatory registry is not the best method to improve patient safety. Regulation cannot and must not be substituted for the frank and personal discourse inherent in the physician/patient relationship.

To date, the FDA has mandated only one mandatory physician/patient/pharmacy registry – for thalidomide. Access to the drug is limited, as only physicians who are registered may prescribe the drug and pharmacists who are registered dispense the medication. There are very few, if any, physicians in private practice who are registered to prescribe thalidomide. Of the 57,000 dispensing pharmacies in the United States, only 8,000 initially enrolled in the registry and only 4,000 remain, due to the prohibitive costs associated with the registry. Also, very few patients have been enrolled in the thalidomide registry – 11,000 over two years.

Accutane, on the other hand, is prescribed to nearly 500,000 new patients annually and is a drug prescribed mainly by practitioners in private practice settings. Nearly 50% of the members of the American Academy of Dermatology are solo practitioners and 27% of dermatologists practice in offices with two dermatologists. Few dermatologists are in large single or multi-practice settings and fewer still are in academic practices. Solo practitioners do not have the flexibility or resources to hire an individual solely dedicated to overseeing compliance with a mandatory registry, as would a physician in an academic setting with greater resources at his/her disposal. Therefore, the treating physician would be compelled to refer their patient to a complete stranger for dispensing of the drug. The patient would then be forced to have one of the most private of discussions with a doctor who is a stranger and who has not earned their trust. The psychological effect of this change would certainly have a chilling effect on the tone and content of this conversation.

Education, of all parties – physicians, patients, nursing staff and other medical support personnel – is paramount and must be an ongoing enterprise. Efforts to educate patients should be, and have been, reevaluated and improved and new knowledge must be incorporated into our practices.

New information about fertility and patient understanding about the efficacy of certain forms of contraception has been included in the new Accutane targeted pregnancy prevention program and physicians, nurses and other office staff must be educated about this new information so that we may begin to implement these recommendations. Continuing medical education and nursing education programs are being amended to ensure that this new information is provided to all. This is how it should be. This is how we will further reduce the very small number of inadvertent pregnancies that continue to occur. Substituting a mandatory registry over a redoubled physician and patient education effort is no guarantee of success.

I am also concerned that the effects of a registry may have unforeseen consequences for the care of patients with other diseases. The National Institutes of Health and academic health centers are supporting research projects that examine the efficacy of this drug for a number of different diseases, including rosacea, ichthyosis, neuroblastoma, sarcoidosis, the prevention of skin cancers in individuals with xeroderma pigmentosum and nevoid basal cell carcinoma syndrome, and emphysema. Indeed, the Italian counterpart to the FDA recently approved Accutane for use as a preventative treatment for neuroblastoma. Institution of a mandatory registry could have a chilling effect on this type of research.

Thank you again for providing the American Academy of Dermatology with the opportunity to appear before you today. I would be most happy to answer any of your questions.

Mr. BURTON. Mr. Jacobs.

Dr. JACOBS. Thank you, Mr. Chairman, and good afternoon, and other members of the committee. I am Douglas Jacobs. I am a psychiatrist on the faculty of Harvard Medical School. I am also executive director of the National Depression Screening Day, which is a nonprofit organization which does receive several Federal grants.

My interest in suicide began—and I am going to be summarizing my statement rather than reading it. Excuse me. My interest in suicide began in 1972 when my first patient who I was caring for hung himself in a hospital only to be saved by another patient. As a young physician, psychiatrist in training, that was an overwhelming experience for me, and obviously for my patient. When I interviewed my patient, he said to me, I have been a bad patient. I thought to myself, no, I have been a bad doctor.

That experience has stimulated and propelled my entire career. I have devoted myself to the understanding of suicide. I have learned a lot. There is still a lot to learn.

In that context, I have examined—I have treated suicidal patients, I have done research, and I have edited several textbooks. As part of this journey, I have also become very interested in the problem of depression. Depression in the 1980's, with studies from the National Institute of Mental Health, it was determined it was underdiagnosed and undertreated. And since depression is clearly linked to suicide, although not a cause of it per se, it was in that context that I decided to try out a model of screening for depression, and this might answer some of the questions of Mrs. Morella and Mr. Horn, that could we screen for depression like we screen for other medical disorders? And it has been an experiment; I think it is an experiment that has succeeded in the sense that we can do it. The problem is that there is much more to be done.

For example, of the 20 million Americans who experience depression each year, less than 20 percent are in active treatment. So we have many Americans, including young people, if we look at young people, and there are approximately 20 million 15 to 19-year-olds, their prevalence of depression is about 6 percent, which means about a million young people that age experience depression each year, and of that group only 200,000 or so get treatment. Many of them end up in physicians' offices. Many of them end up not getting treatment.

In order to answer your question, Mr. Horn, about 2,000 of that group goes on to commit suicide each year, and I will explain that the suicides that I have looked at in Accutane work are no different than the suicides that are occurring throughout America. And it is in that context that I have also formed a high school depression screening program and a suicide prevention program called SOS, Signs of Suicide, in which we are trying to communicate to young people that it is better to have a mad friend than a dead friend, because as young people who don't let their families know, the suicides occur out of the blue, and we see it—we see a suicide occurring.

I was asked by Roche to evaluate the suicide and depression reports and the Medwatch reports. I have been a consultant to them, but I am here today at your invitation.

Let me say in order to first understand suicide, to put it in some perspective demographically, suicide is the eighth leading cause of death. There are about 30,000 suicides each year. In the young population, ages 15 to 24, it is the third leading cause of death. Suicide rose dramatically in that age group from 1950 to 1980, where it tripled. Since 1980 to now, it has remained about the third leading cause of death. It is clearly something that we have to address.

Depression, as I indicated, occurs in about 6 percent of the population. What we know about suicide is that from a clinical perspective, it occurs with severe depression. The majority are not in mental health treatment. The majority have seen a physician within the last 6 months. The majority are male. The majority commit suicide on their first attempt.

If one looks just at the profiles of the Accutane suicides, just from a demographic standpoint, that is what we see: The majority are male, they are not in treatment, it is their first attempt.

If we could show table 1, and I think you all have this, but this is a graph to illustrate the complexity of suicide. It is a multifactorial event. No 1 factor causes suicide, and there are 12 or 14 factors. I have put this specific to adolescents who do have age-specific stressors of self-esteem and image related to severe acne, academic problems, disciplinary crisis, humiliation.

When I was asked by Roche to look at these spontaneous reports, I said to myself, well, how could Accutane cause suicide? So from what I know about suicide, I said, well, does it somehow affect suicidal behavior? Does it cause impulsiveness? Does it affect the neurobiology? And does it cause psychiatric illness?

That's my orientation since I didn't see how it could relate to any of these other factors.

In terms of neurobiology, and, again, what we know about depression, and, again, I will talk specifically about that, we believe that there is some alteration of the brain messenger chemicals that affect our mood centers. We do not believe that isotretinoin, Accutane, affects the neurotransmitter system causing some alteration that would lead to a depressive illness.

Impulsiveness, again, is related to neurobiology. There is no evidence that there is any neurobiologic substrate causing impulsiveness.

In terms of suicidal behavior, and this really relates to what we see in the spontaneous reports, and there is not a one-to-one relationship between suicidal ideation, suicide attempt and suicide, of the 5 million Americans who have suicidal ideation, less than 30,000 go on to complete suicide. And out of that group, we believe about 600,000 attempt suicide.

In the Medwatch reports there are categories of suicidal ideation. The problem in evaluating those is that suicidal ideation from a clinical standpoint is defined as thoughts of suicide accompanied by an intent to die, whereas thoughts of death—which has a prevalence of about 2.6 percent. Thoughts of death has a prevalence of about 28 percent. So what is in the Medwatch—spontaneous reports may or may not be suicidal ideation. The same for suicide attempts.

Let me just say, and I know it is—it is not a chart that I included, but if one were to simply look at the Accutane series of events that I believe are on Congressman Stupak's Web site there are various numbers listed. If one took the prevalence that I am reporting to you today, the numbers reported in these events are much, much smaller. For example, there are a total of 155 cases of suicidal ideation. In terms of prevalence, just in terms of the base population, one would anticipate 390,000 cases of suicidal ideation. In terms of hospitalization, there is 475. In terms, again, prevalence, one would anticipate 13,500.

Now this gets to psychiatric illness. Psychiatric illness is clearly the No. 1 risk factor for suicide, yet the majority of Americans, fortunately, with psychiatric illness—which is also part of the hope when I am consulted that just because you have a psychiatric illness, you are not fated to die by suicide—that of the 20 million Americans who experience depression, less than 20,000 go on to suicide.

What we have heard today, descriptions of depression, I thought I would try to define what we mean and what is depression and what is depressive symptoms, and if we could show the next chart, the American Psychiatric Association has developed a diagnostic and statistical manual which has a criteria for depression that really states that there has to be physical—social and occupational impairment for a 2-week period of time with five of these nine symptoms.

What is important here is that there are multiple symptoms; not only emotional symptoms such as depressed mood and loss of interest, but cognitive, the way one thinks about oneself, their bodily changes, and then the most serious, thoughts of death or suicide.

When looking at the issue of the spontaneous reports in terms of depression, the question is, is this depression, or is this the blues, or are these just moods changes? In the majority of cases, in my opinion, what we are seeing are mood changes. They do not satisfy criteria for clinical depression.

There were some comments made earlier about positive challenges and dechallenges. I have looked at all of those cases. Again, the majority of those cases, the mood symptoms go away without specific treatment once, quote, the drug is stopped. That would not be the case if this were clinical depression. Clinical depression has a time course of 6 to 9 months; where in the values of treatment, specific psychiatric treatment, is that improves treatment in 1 to 2 months.

Mr. BURTON. Excuse me, Doctor. Could you summarize relatively soon because we want to make sure we get to everybody.

Dr. JACOBS. In terms then of the specific suicide cases, the spontaneous reports I looked at in terms of gender, the relationship to on/off Accutane, the issue of concealment of symptoms, and then the issue of does Accutane exacerbate underlying illness.

It was my conclusion that the gender distribution is the same; that there was a report of temporal association, that some committed suicide on Accutane, some off Accutane. There is no predominance. A compelling series of cases are a group of cases, and there are about 10 to 12 of them, who had underlying psychiatric illness. They were given Accutane from anywhere from 6 months to 18

months. They didn't develop any symptoms, no exacerbation of their psychopathology. Anywhere from 6 to 10 years later, they committed suicide. To me, this is as close to a—obviously, it is not a study per se, but if one were designing a study of saying giving a drug to an adverse group, that causes suicide, this didn't happen.

If I could just read the last part. You have asked my thoughts on the adequacy of a passive adverse event reporting system in this context. Although I am not an expert in adverse event reporting mechanisms generally, I believe that in this matter the adverse event reporting system has performed its function of providing a signal of a potential issue. In light of the overall incidence of these conditions, the appropriate focus is on the education of prescribers and patients as well as further study, scientific study, and analysis.

In conclusion, although the current scientific evidence does not support a causal link between Accutane, depression and suicide, given the clinical population in dermatology and in all medicine in terms of where I am committed in terms of my career, it is still important for health professionals to be aware of psychiatric risk factors. Monitoring patients for depression, depressive systems and suicidal ideation can help identify any patients who may be at risk and improve patient care by facilitating appropriate diagnosis and treatment of patients experiencing clinical depression.

It is my understanding that enhancements are being implemented in the communication of psychiatric information to Accutane prescribers and patients. I welcome these efforts, and I believe they will have a beneficial impact on the dermatologic patient population as a whole.

Thank you for this opportunity.

Mr. BURTON. Thank you, Dr. Jacobs.

[The prepared statement of Dr. Jacobs follows:]

STATEMENT BY

**DOUGLAS G. JACOBS, M.D.
ASSOCIATE CLINICAL PROFESSOR OF PSYCHIATRY
HARVARD MEDICAL SCHOOL**

**BEFORE THE
COMMITTEE ON GOVERNMENT REFORM
U.S. HOUSE OF REPRESENTATIVES**

**"ACUTANE: IS THIS ACNE DRUG
TREATMENT LINKED TO DEPRESSION AND SUICIDE?"**

DECEMBER 5, 2000

Mr. Chairman and Members of the Committee, thank you for the opportunity to testify before the Committee on Government Reform on issues related to Accutane (isotretinoin), depression and suicide. I am an Associate Clinical Professor of Psychiatry at Harvard Medical School, where my major research interests have been the study of the phenomenon of suicide and the evaluation and treatment of suicidal patients. My work has included using principles of a psychological autopsy in reviewing over 300 suicides on an intensive basis. I have served as a consultant to Hoffmann-La Roche in the clinical review and evaluation of reports of suicide in the isotretinoin-treated patient population, and I recently presented that clinical review to the Food and Drug Administration's Dermatologic and Ophthalmic Drugs Advisory Committee.

Over the past decade and a half, reports have emerged proposing a possible link between isotretinoin and depression, suicidal ideation, and suicide. In my statement today, I would like to review the clinical features of depression and suicide, and then provide an overview of my clinical analysis of suicide reports in the Accutane patient population. As I will explain, based

on a careful review of the variety of factors relevant to suicide and the relevant suicide reports, it is my conclusion that Accutane use is not causally linked to suicide.

Suicide: An Overview

Although the base rate of suicide in the United State has remained unchanged since 1979, averaging between 11.9 and 12.1 per 100,000 people, with an annual incidence rate of suicide of less than 0.01%, the demographics of suicide have changed substantially over the last quarter century. Currently, 50% of all suicides are under the age of 40. The suicide rate for those age 15-19 has increased over the past 25 years and suicide is the third leading cause of death for this age group, the population most likely to be treated with Accutane.

Suicide is a complex and multi-causal event (see Table 1). There are typically many factors and circumstances involved in the suicide of a particular individual, and there is no single variable that allows us to predict who will and who will not suicide. While there have been studies on the putative biological substrates associated with suicide, we can not determine precisely one neurologic or biologic pathway to the act of suicide.

Suicide risk factors include the presence of psychiatric illness, life stressors, family history of suicide, the presence of hopelessness, access to weapons, and the presence of a comorbid medical condition. No one factor, however, even psychiatric illness, can predict or determine suicide. Although 90-95% of people who commit suicide have some form of psychiatric illness, generally depression, alcoholism or schizophrenia, the majority of people with these disorders do not kill themselves. Therefore, while we consider psychiatric illness a necessary but not sufficient condition for suicide, it is a distal risk factor and not the sole factor related to suicide.

Suicide is generally associated with clinical depression, although the majority of people who commit suicide are not in mental health treatment at the time of death. Despite the fact that

most people who commit suicide are not receiving mental health treatment, 75% have seen a physician in the previous six months. The majority of these individuals have seen a physician for a physical complaint, rather than a mental health complaint.

To date, no drug product has been found to cause suicide. Although certain drugs have been accused of such an association, there is no evidence to support these claims.

Suicidal Ideation and Suicide Attempts; Definitional Issues

Studies indicate that approximately 5 million adults in the U.S. experience suicidal ideation each year, a prevalence of 2.6%. Suicidal ideation is specifically defined as not only a fleeting thought of suicide, but an active wish to die and an active thought of one's own self-annihilation. A non-specific version, which is less clinically significant, refers to just thoughts of death and has a prevalence of 28%. It is this version that appears in most of the spontaneous reports.

It is estimated that for each completed suicide there are approximately 18 to 23 suicide attempts, resulting in a 0.3% annual prevalence of suicide attempts, or 600,000 suicide attempts annually. Although a previous suicide attempt is a risk factor for suicide, 90% of those who attempt suicide do not go on to complete suicide. Definitional issues are again important in understanding the Medwatch reports. The basic distinction is self-destructive behavior that is accompanied by suicidal intent versus self-destructive behavior that is reported regardless of intent to die. This has particular relevance in the youth population. The suicide attempts or self-destructive behaviors that are described in the reports generally do not refer to the presence or absence of the intent to die.

Depression and Suicide

In examining depression in relation to isotretinoin, it is important to distinguish between depression and "the blues." Whereas depression is a whole body illness that includes both

physical complaints and mood disturbances, the blues refers simply to changes in mood and affect. In addition, while depression can result in suicide and may include suicidal ideation as a symptom, the blues rarely produce suicidal thoughts. While approximately 6-8% of the U.S. population currently has depression, mood symptoms consistent with the blues are experienced by 25% of the population at any given time.

Biologically, it is hypothesized that depression is associated with altered functioning of neurotransmitters. Psychologically, negative life experiences can exacerbate or precipitate depressive episodes. The etiology of depression is complex, however, and it must be kept in mind that personality, developmental, genetic, and environmental factors all play a role in the onset of depression. There is a strong genetic component to depression and a family history of major depression is a risk factor.

Depression is characterized by nine criteria, five of which must be met for a diagnosis of depression (see Table 2). The first two symptoms, depressed mood and loss of interest in life and activities, are key, and one must be present for a diagnosis of depression. In addition, four of the additional seven criteria must also be present. All criteria must be present for a two-week period. One of the major difficulties in recognizing and diagnosing depression is that many of the symptoms, such as appetite and sleep changes, are non-specific and are present in a number of emotional and physical disorders. In addition, the somatic complaints that accompany depression are often mistaken for signs of physical illness and a diagnosis of depression is overlooked.

Isotretinoin: Examining the Data

In looking at the signal of psychiatric events in the isotretinoin patient population, it is important to note that the reports of depression in the Medwatch reports and in the literature on isotretinoin are below the background incidence of depression for the general population. The

depressions that are reported are typically not severe and do not meet the full criteria for clinical depression. Because the patients were not evaluated psychiatrically prior to the onset of their mood disturbances, it is difficult to evaluate how drastic the mood changes truly were and whether or not they were pre-existing. Many of the patients were not treated for depression, even though depressive symptoms were reported. Had these patients been suffering from clinical depression, treatment would have been required to alleviate the symptoms. In fact, many of the patients remained on isotretinoin without exacerbation of their depressive symptoms.

In the original controlled clinical trials of isotretinoin there were no diagnoses of depression. In the subsequent studies, up to 5.5% of the patients reported major depressive symptoms, some of which were confirmed by a psychiatrist. None of these patients required antidepressants according to the physician's reports. In another study, only 1% reported depressive symptoms but, again, none required antidepressant treatment, indicating a low level of severity of depressive symptoms. Therefore, while these patients may have had depressive symptoms, there is not conclusive evidence that they had a major depressive disorder.

In addition, as previously mentioned, confounding factors may result in depressive symptoms without the presence of clinical depression. Although in the dechallenge and rechallenge reports in the Medwatch reports, the changes in mood and the temporal relationship to isotretinoin may have met some of the criteria for a Substance-Induced Mood Disorder (drug-induced depression), serious questions still remain. The clinical significance of this observation is uncertain in light of the often cyclic nature of these symptoms or diseases. For example, there are no reported studies or observations which suggest an association between Substance Induced Mood Disorder and suicide. Furthermore, this diagnostic category fails to account for potentially confounding variables and risk factors and is generally attributed to substances used in abuse. In particular, in the majority of Medwatch reports, we do not have the patients' complete histories

and, therefore, do not know if they had any pre-existing depression, other psychopathology or genetic predisposition and thus cannot use them to assign a diagnosis such as Substance-Induced Mood Disorder (drug-induced depression).

Based upon my review, the suicides in the Accutane-treated population, as recorded in the Medwatch reports, are consistent with what we know about suicide. There were multiple scenarios, generally involving a psychiatric illness, family history of depression or suicide, family problems, concurrent medication, and other confounding factors. The average age and gender -- young and male -- of the victims were consistent with the typical profile.

Although many of the Medwatch reports from families indicated that the suicide appeared to come "out of the blue," this is not atypical of suicide cases in general. Despite the fact that 70% of people who commit suicide communicate their suicidal intent, young people in particular often discuss it with friends rather than family, or keep it suppressed. This means that many families are not aware of their child's suicidal thoughts and do not recognize the warning signs of the impending suicide. In fact, many of the cases reported in the Medwatch reports appear to have exhibited other, preexisting risk factors for suicide that remained unrecognized or undiagnosed. If a full psychological autopsy, which examines multiple factors, were to be performed, the cause of suicide in these patients would not be viewed as associated with isotretinoin, but rather to the myriad of other factors that indicated suicide risk.

Finally, there is no evidence that there is a biochemical basis for Accutane to be associated with depression, suicide, or suicide attempts. While there is evidence that suggests that clinical depression is associated with an alteration in the neurotransmitter system, there are no current data to conclude that isotretinoin causes such alterations. Although the retinoids may have some postulated relationship to CNS functions, and it remains a rare possibility that isotretinoin may be associated with some mood symptoms in certain individuals, the evidence

does not suggest a causal link between isotretinoin and major depression or suicide. In addition, there is no evidence that the reported mood symptoms are of clinical significance.

Conclusion

In summarizing my findings on the Medwatch reports, I examined various categories in terms of their relationship to isotretinoin use; demographics, confounding factors, pre-existing psychiatric history, concealment of symptoms and no apparent psychopathology. There was no alteration in the gender distribution in the suicide cases. There was no significant impact in terms of the suicides occurring on or off Accutane. There was no exacerbation of underlying psychiatric disorders. The lack of warning signs seen in many of the cases is consistent with what we know about youth suicide.

You have asked for my thoughts on the adequacy of a passive adverse event reporting system in this context. Although I am not an expert in adverse event reporting mechanisms generally, I believe that in this matter the adverse event reporting system has performed its function of providing a signal of a potential issue. In light of the overall incidence of these conditions, the appropriate focus at this point is on education of prescribers and patients as well as further scientific study and analysis.

In conclusion, although the current scientific evidence does not support a link between isotretinoin and depression, suicidal ideation, or suicide, given the clinical population in dermatology, it is still important for health care professionals to be aware of psychiatric risk factors. Monitoring patients for depression, depressive symptoms, and suicidal ideation can help identify any patients who may be at risk and improve patient care by facilitating appropriate diagnosis and treatment of patients experiencing clinical depression. It is my understanding that enhancements are being implemented in the communication of psychiatric information to

isotretinoin prescribers and patients. I welcome these efforts, and I believe they will have a beneficial impact on the dermatological patient population as a whole.

Thank you for the opportunity to provide this statement. I will be happy to take questions.

TABLE 1
Suicide: A Multi-Factorial Event - Adolescent

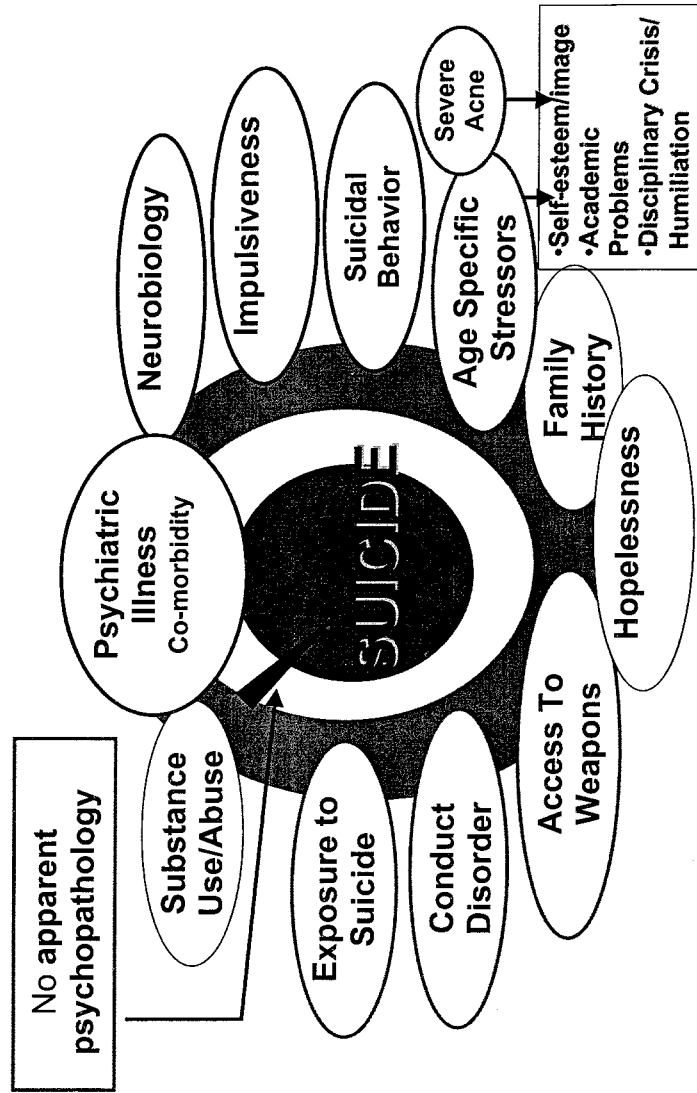


TABLE 2
Criteria for Depression

- Depressed Mood
- Loss of interest or pleasure in activities
- Weight loss or gain without dieting or changes in appetite
- Changes in sleeping patterns
- Psychomotor agitation or retardation
- Fatigue or loss of energy
- Feelings of worthlessness or guilt
- Inability to concentrate, indecisiveness
- Thoughts of death or dying

Mr. BURTON. Dr. O'Donnell.

Mr. O'DONNELL. Mr. Chairman, members of the committee, thank you for the invitation to share my comments with you regarding an overview of existing research and information linking acne, depression, psychosis and suicide with other drugs like Accutane and other drugs used to treat acne.

I am an assistant professor of pharmacology at the Rush Medical College in Chicago. I am also a licensed pharmacist and a certified nutritionist. I do not hold any Federal grants, although I have testified as an expert witness in matters against Roche.

I would like to project my one slide and leave it projected for the course of my comments. My review has included the basic pharmacology and toxicology of vitamin A, and if we could focus just on the top three chemical formulae there, from the audience you won't be able to see that, but please take my word that the three molecules of retinol, tretinoin and isotretinoin are practically identical. There is only an extremely minor change on the far right end aliphatic group between an OH and a COOH. That won't mean anything to you as a layperson, but as a chemist and a pharmacologist, looking at these three chemicals, not knowing anything different, you would predict the same actions, including the same toxicities.

This is part of the basic pharmacology and toxicology of vitamin A and retinoids. This was considered as part of the Accutane clinical research data base, and it is also referred to in published literature describing hypervitaminosis A, a condition which is caused by too much retinol, too much vitamin A.

Now vitamin A and retinoids have been used to treat skin conditions for 50 years, and we now have almost 20 years' experience with Accutane, and clearly Accutane is a very effective drug. I am certainly not encouraging anyone to remove it from the therapeutic armamentarium to treat severe acne.

I do question if 1.5 million prescriptions are written for 500,000 patients per year, how many of those patients qualify according to the prescribing indications approved by the FDA for severe recalcitrant acne? I would direct that question to the gentleman from the Academy of Dermatology because he did not include that information in his remarks.

The mechanism of action as to how Accutane improves or cures acne, from my reading, is unknown. We also don't know why Accutane and vitamin A substances cause psychiatric conditions. Perhaps I am using the word "cause" very casually, and I should correct myself. Clearly, there are associated reports of psychiatric conditions that have been reported for the last 150 years with vitamin A. Polar explorers used to eat anything they would find on the icecaps, and they ate polar bears, and they favored the livers. Some of them became psychotic, and they reported conditions since then, since 1856, of neurotoxicities, toxic psychosis, schizophrenia-like symptoms. These have been published throughout the literature since that time.

Similar toxicities to vitamin A toxicity have been reported in the literature as well as case reports for Accutane. In fact, the investigational brochure for Accutane in 1978 stated, and I quote, adverse reactions seen with the use of orally administered Accutane

are essentially those of hypervitaminosis A. So, in other words, you're expected as a pharmacologist, as a chemist, when you are using a drug, you have to look at history and learn from history. We have a long history of psychiatric toxicity associated with vitamin A. It is not surprising that we have similar reports of similar psychiatric toxicity associated with Accutane.

I am not going to comment on Dr. Jacobs' or Roche's analysis. I think he made a very succinct and accurate presentation of that data. Nor will I comment on the FDA's analysis because they are here to speak for themselves.

I would like to mention an analysis that was undertaken in Ireland by a scientist who did a pharmacoepidemiological analysis of psychiatric side effects associated or reported with Accutane and five other drugs, five other oral treatments used to treat acne. The other drugs were primarily tetracycline antibiotics, which is a common first-line treatment for acne, and also some hormones which some dermatologists and other physicians use to treat acne.

Dr. Middlekoop's findings were that there were more reports for psychiatric adverse events and suicide worldwide from isotretinoin than from the use of the five other acne therapies combined, and her statistics describe a several hundredfold increase in risk of psychiatric side effects with acne.

Now, since we don't know the mechanism of action as how acne works—excuse me, how Accutane works on acne, we also heard we don't know the mechanism of action of why vitamin A retinols and Accutane cause these toxicities. No one questions that they do. Fortunately, we do now have warnings that say because of these reports, this may be associated with suicides, suicide ideation and so forth.

The case reports are suggestive of an association. Clearly, we don't have solid scientific information proving the cause, but this is a neurobiological issue. Sometimes we can't get into the brains to actually prove what works. We heard from Dr. Jacobs that we don't believe that the neurotransmitters are affected, and neurotransmitters certainly are responsible for depression and other psychoses—excuse me, and psychoses. But there is literature that does suggest that retinols are associated with schizophrenia and retinols are associated with genes that transcribe the neurotransmitters in the brain.

I am going to stop, because my time is over, with a comment that I am pleased to hear that an informed consent form will be provided. I would also state that since historically we know that vitamin A is accepted to cause these toxicities, that instead of saying we need to prove that—that Accutane actually does this, I would turn the tables and say, let's prove that it doesn't, and until we do, take precautions and especially warn patients and their families, because otherwise they are the ones who are really the ones who have to monitor it and prevent—make a choice whether they want to take that risk, and if they do, then recognize and be able to avoid a tragedy. I thank you.

Mr. BURTON. Thank you, Dr. O'Donnell.

[The prepared statement of Mr. O'Donnell follows:]

OVERVIEW OF EXISTING RESEARCH AND INFORMATION LINKING
ACCUTANE (ISOTRETINOIN), DEPRESSION, PSYCHOSIS AND SUICIDE

PRESENTATION TO THE
CONGRESS OF THE UNITED STATES
HOUSE OF REPRESENTATIVES
COMMITTEE ON GOVERNMENT REFORM

Hearing Title: "Accutane - Is this Acne Drug
Treatment Linked to Depression and Suicide?"

Tuesday, December 5, 2000
1 p.m.

Room 2154 Rayburn House Office Building

Presentation by:

James O'Donnell PharmD MS ABCP FACN CNS
Assistant Professor of Pharmacology
Rush Medical College
Chicago

Biographical Sketch

I, James O'Donnell, earned Bachelor's and Doctorate degrees in Pharmacy from the Universities of Illinois and Michigan respectively, and earned a Master's degree in Clinical Nutrition from the Rush University. I completed a residency in Clinical Pharmacy at the University of Illinois Research Hospitals. I am an Assistant Professor of Pharmacology at the Rush Medical College and a Lecturer in the Department of Medicine at the University of Illinois College of Medicine. I have served as a consultant to the Drug Enforcement Administration, Illinois Department of Public Health, Illinois Department of Mental Health, and several Public Defender's and State's Attorneys offices, all in the areas of pharmacology, drug effects and drug use. I am the Founding Editor of the Journal of Pharmacy Practice. I am a Diplomate of the American Board of Clinical Pharmacology, a Diplomate of the Board of Nutritional Specialties, and a Fellow in the American College of Nutrition, and member of several professional societies. I have consulted to government agencies and pharmaceutical companies in matters related to research, evaluation of adverse event reports, and preparation of technical material supporting marketing and sales. I am a co-editor of Pharmacy Law: Litigating Pharmacy Cases (L&J, 1995) and the editor of Drug Injury: Liability, Analysis, and Prevention (L&J, 2000). A copy of my Curriculum Vitae is attached. I have not received any Federal Government grants and contracts.

Disclosure	3
Objective	3
Introduction	3
Mechanism Of Action	5
Chemistry, Terminology and Metabolism	5
Adverse Effects Of Accutane	5
Hypervitaminosis A	6
Psychiatric Adverse Events	7
Pseudotumor Cerebri (PTC)	8
Retinoids Implicated in Schizophrenia	9
Accutane and Depression	9
Adverse Drug Reaction Reports	10
FDA Meeting of the Dermatologic and Ophthalmic Drugs Advisory Committee Accutane Associated Psychiatric Events September 19, 2000	12
Submission Of ADR Reports	15
Revised Label Warning	16
FDA's Battle With Accutane	16
Indications For Use - Overprescribing	17
Summary And Recommendations	17
Table 1. Worldwide Psychiatric ADR Reports (WHO)	19
Table 2. UK ADR data (source: MCA)	20
Table 3. Prescription Data (England 1982-97)	20
REFERENCES	21

Disclosure

I have testified as a witness for plaintiffs in product liability suits against Roche; however, I am not here in the capacity of an expert witness, and am not being compensated for my time associated with this Committee presentation.

Objective

My objective today is to provide information describing the association of Accutane to depression, psychosis, and suicide to the Committee. That information comes from a variety of sources, including my experience and training as a pharmacist, pharmacologist, and nutritionist:

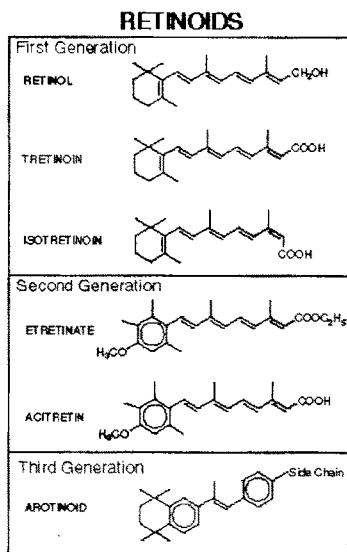
- Basic pharmacology and toxicology of Vitamin A and Retinoids
- Accutane clinical research
- Published literature describing Hypervitaminosis A as well as Accutane
- Adverse reaction Reports (US and Europe)
- Expert Analysis of Causation
- My own personal assessment and recommendations.

Introduction: Vitamin A and Retinoids

Since early this century animal research revealed modifications of epithelial structure such as increased epidermal keratinization and squamous metaplasia of the mucous membrane, under conditions of vitamin A deficiency. The finding that these defects could be corrected by administering vitamin A led to the emergence of vitamin A as an anti-keratinizing factor. The first synthesis of vitamin A fifty years ago opened a new era into the chemical synthesis of vitamin A derivatives, collectively known as retinoids.

First synthesized in 1955 Accutane (Ro 4-3780, isotretinoin), a first generation retinoid, was shown to be highly efficacious in the therapy of disorders of keratinization (e.g., Darier's disease, ichthyosis). Peck *et al.* (1978) were the first investigators to demonstrate this drug's value in the treatment of severe acne and in September 1982 it was approved for use in the USA by the Food and Drug Administration (FDA). From 1993 to 1997, prescriptions in the US jumped 52% (to 1.5 million).

Figure 63-1 from
Goodman & Gillman's
The Pharmacological Basis of Therapeutics, 9th Edition, 1996



Mechanism Of Action

Acne is due to an interaction of the normal skin bacteria with the patient's abnormal type of sebaceous lipids (Cunliffe, 1998) and is associated with an increased sebum production and ductal cornification. The acne bacteria, *Propionibacterium acnes*, reside on the surface of the skin in quite high numbers, especially in oil-rich areas. If they colonize the pilosebaceous duct in the presence of comedones (blackheads and whiteheads), then inflammation is likely to be triggered resulting in papules, pustules and if inflammation is more expansive, nodules. Although the exact mechanism of the anti-acne action of isotretinoin is unknown it is unique in its ability to affect, albeit not to the same degree, all the known etiological factors of acne; reduction of sebum production, lessening of comedogenesis, decreases surface and ductal colonization by *Propionibacterium acnes* (Cunliffe, 1997).

Chemistry, Terminology and Metabolism

Although the term vitamin A has been used to denote specific chemical compounds, such as retinol or its esters, this term now is used more as a generic descriptor for compounds that exhibit the biological properties of retinol. Retinoid refers to the chemical entity retinol or other closely related naturally occurring derivatives. Retinoids also include structurally related synthetic analogs, which need not have retinol-like (vitamin A) activity. (Marcus, 1996)

Isotretinoin is a metabolic product of the dietary vitamin A and provitamin A carotenoids. Retinol (vitamin A) is absorbed from the gastrointestinal tract and metabolized in the liver, into retinal. Retinal is then irreversibly oxidized into retinoic acids, which reversibly interconvert into each other. The 2 isomers (retinoic acid and 13-retinoic acid) have an identical chemical structure. Isotretinoin and retinoic acid are further metabolized into oxo-isotretinoin and oxo-retinoic acid, respectively, where interconversion again takes place between both metabolites (Wiegand, 1998). The elimination half-life of isotretinoin and its 4-oxo metabolite are 29 and 22 hours, respectively (Nulman, 1998).

Adverse Effects Of Accutane

Over the years Accutane has proven its excellence in the treatment of severe recalcitrant acne. However it is associated with a long list of side-effects which are frequent, varied and at times severe. The most commonly occurring adverse reactions are those involving the skin and mucous membranes, which occur in all patients treated with Accutane. Other side effects reported include skin fragility, pyogenic granuloma-like lesions and epidermal blistering, paronychia and alopecia (Bigby, 1988). Gastrointestinal intolerance occurs in 20% of patients treated (Bigby, 1988). Muscular or joint pain, are quite common with Accutane use. Myalgia and arthralgias occur in 16% of patients treated, which usually abate when the medication is discontinued (Orfanos, 1997).

Blepharitis and conjunctivitis associated with Accutane use were recognized well before it's

marketing. Corneal opacities and acute myopia have been reported in government publications and in the ophthalmologic literature. Other ocular reactions include optic neuritis, cataracts, decreased night vision, blurred vision and photosensitivity. Pseudotumor cerebri (PTC) and headaches are also associated with the drug. In common with other retinoids at pharmacological doses, Accutane causes elevation of serum lipids particularly triglycerides.

Hypervitaminosis A

Hypervitaminosis A is the condition resulting from an excess of retinol in the body.

Vitamin A is an essential factor in physiological growth, visual function, epithelial cell differentiation and reproduction and is believed to exert its influences at the DNA level where it plays an important role in regulating transcription of a number of genes.

An intake of retinoids greatly in excess of requirement results in a toxic syndrome known as hypervitaminosis A. Some or all of the symptoms of hypervitaminosis A also are the major toxic effects that are manifest during the therapeutic use of natural and synthetic retinoids in the treatment of skin disorders. Accutane (Isotretinoin), being an analog of vitamin A, shares many of the side effects experienced with vitamin A. Vitamin A (retinol) is ingested in the diet as retinyl esters, which are transported to the liver and hydrolyzed in hepatic parenchymal cells. Excess retinol is converted to retinyl esters again and stored in the liver. Retinol binds to Retinol Binding Protein (RBP). When the amount of vitamin A present exceeds the capacity of RBP to bind to it the excess retinol binds to lipoproteins, and in this form it has toxic effects (Bendich, 1989).

There are two types of Hypervitaminosis A, acute and chronic. Acute hypervitaminosis A results from ingestion of a very high dose of vitamin A over a short period of time. Typical symptoms include bulging fontanel in infants and headache in adults, nausea, vomiting, fever, vertigo and visual disorientation. Peeling of the skin may also occur. Chronic hypervitaminosis A is more common than the acute form and results from continued ingestion of high doses for months or even years. Symptoms include anorexia, dry itchy skin, alopecia, increased intracranial pressure, fatigue, irritability, somnolence pronounced craniotabes and occipital edema, skin desquamation, fissuring of the lips, pain in the legs and forearms, neurologic disturbances and lethargy. Elevated blood lipids are also common. (Wilson, 1996) This reads just like the Accutane package insert.

Most frequently, high intakes in children are the result of overzealous prophylactic vitamin therapy on the part of parents. Toxicity in adults has resulted from extended self-medication or food fads, as well as from the use of retinoids for the therapy of acne or other skin lesions. The toxicity of retinol depends on the age of the patient, the dose, and the duration of administration. Although vitamin A toxicity is uncommon in adults who consume less than 30 mg of retinol per day, mild symptoms of chronic retinoid intoxication have been detected in individuals whose intake was about 10 mg per day for 6 months (see Bendich and Langseth, 1989). In infants, the daily consumption of as little as 7.5 to 15 mg of retinol for 30 days has induced toxicity. The

acute consumption of more than 500 mg of retinol in an adult, 100 mg in a young child, or 30 mg in an infant frequently results in poisoning. Acute and sometimes fatal poisoning in human beings also is known to follow the ingestion of polar bear liver, which contains up to 12 mg of retinol per gram. The Food and Nutrition Board of the National Research Council (1980) has warned that the ingestion of more than 7.5 mg of retinol daily is ill advised. Nevertheless, almost 5% of users of vitamin A in the United States exceed that amount.

Signs and symptoms of acute poisoning include drowsiness, irritability or irresistible desire to sleep, severe headache due to increased intracranial pressure, dizziness, hepatomegaly, vomiting, papilledema, and, after 24 hours, generalized peeling of the skin. (Guzzo, 1996)

Psychiatric Adverse Events

Vitamin A intoxication resulting in generalized as well as Central Nervous System (CNS) symptoms, was first alluded to in 1856 by Elisha Kane (Kane, 1856), the arctic explorer. He recorded symptoms of vertigo, headache, drowsiness and irritability following ingestion of polar bear liver, which was later found to contain a high concentration of vitamin A. Over the succeeding 140 years, case reports of the occurrence of acute schizophrenia or remitting psychosis associated with either hypervitaminosis A (Halter, 1991; Haupt, 1977; Landy, 1985) or vitamin A deficiency (Oliver, 1986) have appeared in the literature. These provide literature precedent and biologic plausibility to the causation analysis.

In 1972, Restak reported a case of toxic psychosis in a patient following vitamin A treatment (50,000 IU 2/3 times daily) for acne, which required hospitalization. About six months after initiating vitamin A therapy, the patient experienced the onset of prolonged depression, bouts of elation alternated with despondency, disturbed sleep, insomnia and loss of appetite. Twelve months later, while on holidays, she became more agitated and depressed, and lost weight. She also developed blurred vision, hyperacusis, vertigo, strong feelings of ego alienation, and lethargy. Following psychiatric referral, total remission occurred over 6 months of close observation and anti-depressant therapy. The authors cautioned the "use of the vitamins as preventatives for such benign entities as acne." (Middelkoop, 2000)

In 1992, a case report described a patient, with no previous psychiatric history, who presented with a 1-year history of depressed mood and poor concentration (McCance-Katz, 1992). Medication included only a multivitamin preparation of 25,000 IU of vitamin A per day, for 2 years. Hamilton Depression Ratings confirmed full cessation of depressive symptoms after stopping treatment. Other reports of lethargy, loss of interest in surroundings, insomnia, listlessness, profound daily fatigue, anorexia and irritability, in association with vitamin A, have been documented (Stimson, 1961; Shaw, 1953; Oliver, 1958; Bifulco, 1957; Elliot, 1965).

Pseudotumor Cerebri (PTC)

First described by Gerber *et al.*, in 1954, PTC (benign intracranial hypertension) has long been

associated with Vitamin A administration (Lombaert, 1976; Siegel, 1972). PTC is accompanied by symptoms such as papilledema, vision problems, nausea and severe headaches. PTC occurs in 30% to 50% of patients with hypervitaminosis A (Selhorst, 1984) and is characterized clinically by 3 criteria (Spector, 1984; Marcus, ; DiGiovanna et al, 1986):

Neurologic and ocular symptoms and signs of increased intracranial pressure, which may include headache, nausea, transient visual obscurations, sixth-nerve palsies and papilledema.
Radiologically demonstrable normal or small-sized cerebral ventricles
Elevated Cerebrospinal fluid.

PTC has been associated with isotretinoin therapy (Lee, 1995; Roytman, 1988) and the retinoid, etretinate (Bonnetblanc, 1983) and combination therapy with tetracyclines may increase the risk for it occurring.

I testified In the case of Wagner v. Roche Laboratories (decided Nov. 13th 1996), a consumer brought a products liability action against Roche, alleging that the defendant failed to adequately warn of the association of Accutane with PTC and of the dangers of concomitant use of Accutane and certain antibiotics such as Minocin (minocycline), a tetracycline derivative. Ms. Wagner was prescribed Accutane on Nov 8th 1982 for acne in addition to Minocin which the patient had previously been on. Six weeks later the a neurologist diagnosed papilledema and PTC. Steroids were prescribed to treat the PTC and as a result, the appellant experienced avascular necrosis. Appellant underwent several surgeries to replace both hip joints and a shoulder joint. The appellants theory of recovery at trial was premised on her presentation of expert testimony by myself that (a) "Accutane is so similar chemically to Vitamin A that appellees either were aware, or should have been aware, that Accutane also had the potential to cause PTC", and (b) "that because the two antibiotics the appellant was receiving were both associated with PTC, the combination of the two increased that risk." Dr. Elias, one of the physician investigators who participated in the clinical trials of Accutane, testified that the testing done by the appellees prior to FDA approval, was deficiently designed because it failed to monitor for neurological toxicity, and that because of the similarity with vitamin A, Roche should have predicted the same association of Accutane with PTC. In addition, I testified that even in the absence of specific instances of PTC in clinical trials, Roche should have predicted an association and should have warned of this possible effect. In fact, the Investigational Drug Brochure", dated March 20th 1978, which contains an extensive listing of abnormalities in it's "Precautions and Warnings" section, reported in patients with "chronic vitamin A intoxication. "Papilledema with increased intracranial hypertension" was one of the reported associated abnormalities listed. The same document also stated "A review of the clinical studies discussed in this brochure indicates that the adverse reactions seen with the use of orally administered Accutane are essentially those of hypervitaminosis A".

Retinoids Implicated in Schizophrenia

Goodman has recently proposed retinoid dysregulation as a possible cause of schizophrenia

(Goodman, 1995). Schizophrenia is now considered to be a neurodevelopmental disorder with first evidence of the disorder occurring in the midgestational period, the time when fetal brain is actively developing. Vitamin A which is essential in gene regulation and expression, is particularly active in brain neurodevelopment at this time. Goodman has put forward three lines of evidence for an association. The first is the resemblance of symptom presentations of retinoid toxicity to the stigmata of schizophrenia e.g., thought disorder, mental deficit, enlarged ventricles, microcephaly and congenital malformations. The second line of evidence comes from the finding that specific gene loci which have been suggestively linked to schizophrenia, are known loci of genes within the retinoid signaling system. Retinoids are handled in the body by a complex genetic cascade necessary for the metabolism of retinol to retinoic acids. The major genes in the retinoid cascade are the nuclear retinoid receptors RAR and RXR. The loci of two of the genes involved in the regulation of this cascade, RXR β and RAR β , have been suggestively linked to schizophrenia. It has recently been found that RXR is necessary for the expression of dopaminergic neurons in the midbrain region in mice, which have been implicated by numerous studies as abnormal in schizophrenia (Kapur, 1996). The third line of evidence shows schizophrenia genes as targets of retinoid regulation. Retinoic acid binds to RARs and RXRs and this complex then binds specific regions of target genes and in this way regulate the expression of multiple target genes. Among the many genes shown to be targets of retinoic acid are dopamine and serotonin, both of which have been proposed as candidate schizophrenia genes. (Middelkoop, 2000)

Alteration of neurotransmitters is a classic hallmark of the psychoses. Recent work has shown that retinoic acid is a major regulator of several of the genes involved in neurotransmission (Berrard, 1993).

Accutane and Depression Literature Reports

Depression associated with Accutane therapy has, in the past, been described as idiosyncratic. Increasing reports of depression associated with its use show it is not the rarity it was once considered to be. Between 1982 and 1998 24 cases of psychological distress associated with the use of this drug were reported in the literature. Most of these cases reported the subsequent emergence of depression with features similar to that of hypervitaminosis A. (Middelkoop, 2000) Other authors have published case reports of Vitamin A poisoning. (Nagai, 1999; Aggarwal, 1996; Grisson, 1996; Alemayehu, 1995; Fishbane, 1995; Lewin, 1994; Drouet, 1998; Sharieff, 1996; Gerber 1954; Pasquariello, 1977; Rose, 1967; Braun, 1962)

Systemic side effects are generally less significant if therapy is short-term. Transitory abnormal elevations in serum transaminases occur rarely. Acute idiosyncratic hepatitis has not been seen with isotretinoin as it has with etretinate. Hyperlipidemia is frequent, with 25% of patients developing increased triglyceride levels and, less frequently, increased cholesterol and low-density lipoproteins and decreased high-density lipoproteins (Bershad et al., 1985). Myalgia and arthralgia are common complaints. Headaches occur and rarely are a symptom of pseudotumor cerebri. Occasionally, patients have drug-associated depressive episodes. Long-term therapy may produce skeletal side effects, including diffuse idiopathic skeletal hyperostoses, extraskelatal ossification, particularly at tendinous insertions, and, in children, premature epiphyseal closure (DiGiovanna et al., 1986; Marcus, 1996).

In 1983, one year after market release, Hazen *et al.* (1983) reported 5.5% (6/110) of patients with acne

experienced depressive symptoms, manifested by malaise, crying spells and forgetfulness, within 2 weeks of commencing isotretinoin therapy. Meyskens also noted similar psychological changes in patients with cancer treated with 3mg/kg/d isotretinoin. The ADRRS of the American Academy of Dermatology, received reports of 104 suspected adverse reactions to isotretinoin, between October 1982 and June 1985, of which CNS Disorders represented 22.1% (23/104), second to Skin and Mucous membrane reactions (27.9%) (29/104) (Bigby, 1988). These CNS reactions included headache, depression, dizziness and personality disorder. Scheinman (1990) reported 1% of patients treated developed depressive symptoms with oral isotretinoin, which were diagnosed by a psychiatrist and which the severity of symptoms interfered with their normal functioning. In this particular report, the relationship of depression to isotretinoin therapy was confirmed by rechallenge. This was also confirmed by Villalobos' (1989) patient, who reported the onset of hallucinations and paranoia on day 11 of isotretinoin therapy, which subsided when drug intake was stopped and recurred shortly after resumption of isotretinoin. Gatti in Italy (1991), reported a case of suicide which happened 2 months after stopping isotretinoin therapy. Bravard *et al.* (1993) described 3 case reports of depression where none had a prior history. One of these patients attempted suicide during the 4th month of isotretinoin therapy, and one committed suicide 3 months after cessation of therapy. (Middelkoop, 2000)

Cessation of depressive symptoms does not always occur upon withdrawal of the drug. Byrne *et al.* (1995) described three patients who presented with severe depression, which required active treatment. In all three cases, the patients moods improved with anti-depressant therapy. Despite the recurrence of one of the patients acne, follow-up showed no depressive symptoms, confirmed by a score of 5 on the Hamilton Depression Rating Scale.

Adverse Drug Reaction Reports

Middelkoop conducted a pharmacoepidemiologic analysis of Accutane and other drugs used to treat acne and reports of suicide, depression, and other psychiatric adverse drug effects.

Among the many products available, Dianette, doxycycline, minocycline, oxytetracycline and tetracycline are five most commonly prescribed anti-acne treatments. Based on available information, there are more reports of psychiatric adverse events and suicide worldwide from isotretinoin than from the use of the other 5 acne therapies combined (Table 1, World Health Organization). Worldwide 1830 reports of psychiatric events attributable to the 6 medications, are identified, of which isotretinoin was implicated in 59.8% (1095/1830). Second to this was minocycline, implicated in 14.2% (261/1830). 47 and 56 cases of suicide and suicidal ideation were reported in association with the use of Accutane, respectively, with none being reported for the other medications. Of 75 cases of attempted suicide reported, 89.3% (67/75) were associated with the use of isotretinoin, with 4% (3/75) associated with the use of both Dianette and tetracycline, and 2.6% (2/75) for minocycline. ADR data for the UK (Table 2, Medicines Control Agency (MCA)) reflect a similar pattern, with 51.9% (135/262) of psychiatric ADRs attributed to isotretinoin. In addition, all cases of suicide/suicide attempt/suicide ideation were associated with the use of this medication. The source for this data relies on voluntary reporting and probably represents significant underreporting as not all serious ADR's are reported. (Middelkoop, 1999; 2000)

Isotretinoin, an acne drug used by more than 8 million people, has been associated with severe depression and even suicidal behavior that may remit when the drug is withheld. A definite cause and effect relationship between

isotretinoin use and depression has not been established, and it is not surprising that the presence of severe acne itself may predispose teenagers and young adults to depression. Nonetheless, this possible side effect of isotretinoin should be kept in mind whenever the drug is prescribed. (Hauser, 1998)

Table 3 shows the number of prescription items dispensed in England from 1982 to 1997. Isotretinoin, while attracting the largest percentage of psychiatric ADRs, had the lowest number of prescriptions issued (12,400). During this period 1,214,600 prescriptions were dispensed for Dianette, of which the indication for 184,200 prescriptions was acne. Dianette was implicated in only 1.9% (5/262) of psychiatric ADRs.

Minocycline is used extensively in the treatment of acne vulgaris (8,802,000 prescriptions issued between 1982-97. Between 1970-97, 6.5 million patients (Shapiro et al., 1997) were treated with minocycline in the UK. A total of 45 psychiatric adverse events were received by the MCA between 1973 and 1997. Accutane has a UK patient exposure of 50,000 (8 million worldwide, PharmFocus data) and has received reports of 135 psychiatric adverse events. Based on these figures, the incidence rates of psychiatric adverse reactions for Accutane and Minocycline are 270 and 0.692 per 100,000 people treated, respectively. These medications, (with the exception of Accutane) are used to treat conditions other than acne. As patient exposure data for these medications, where the indication was acne, was unobtainable the frequency of psychiatric reactions attributable to these medications, in the population of acne patients, remains unknown. Middelkoop concluded that Accutane is several hundred times more likely to cause depression than the five other acne.

A major component of the evaluation of reports of suspected adverse drug reactions, or events in a clinical trial, can be a judgment about the degree to which any reported event is, in fact, causally associated with the suspected, or investigational drug. In reality, a particular event is associated or is not associated with a particular drug, but the current state of information almost never allows a definitive determination of this dichotomy. (Jones 1994)

The analysis of causality and association in adverse drug events has not changed in the last 20 years. Riddell (1983) describes the "ways and means" of confirming or denying the possibility of an ADR which constitute a validation process that removes suspected cases from the merely anecdotal category. They are:

1. Temporal eligibility - drug must be administered at some interval of time before the reaction occurs.
2. Latent period - There is an interval from the time at which a drug is first administered to the beginning of the ADR.
3. Exclusion - are any other drugs or existing conditions responsible. This method is not applicable in all cases of possible ADR, either because of insufficient data or because of simultaneous eligibility of more than one drug.
4. De-challenge - condition improves on discontinuation of the drug, and
5. Re-challenge - condition reoccurs upon re-exposure to the drug (usually not deliberately, since a suspicion of an association with an adverse event would preclude intentional re-

exposure of a patient to the same adverse event.

6. Singularity of the drug - Is there something unique about the adverse reaction experience that is not consistent with any other drug taken or any existing disease condition.
7. Pattern - ADR been described in the literature with this drug or another in the same pharmacologic class, or it may refer to a morphologic pattern in a target organ that suggests an association with a particular drug or group of drugs. (Prior history with Hypervitaminosis A provides a literature precedent, a biological plausibility).
8. Drug Identification (qualitative or quantitative) - a major utility in overdose cases.

Causality assessments were usually expressed in terms of a qualitative probability scale, for example "definite" vs. "probably" vs. "possible" vs. "doubtful" vs. "Unrelated." (Hutchinson 1989)

**FDA Meeting of the Dermatologic and Ophthalmic Drugs Advisory Committee
Accutane Associated Psychiatric Events September 19, 2000**

Several experts from Roche as well as FDA addressed the issue of Accutane and depression and suicide.

Dr. Russell Ellison (Roche) stated:

"We had a signal (psychiatric events) which had yet to be confirmed, and stated that Roche has been very diligent in trying to evaluate and trying to confirm this signal." He and his consultants (Drs. Nelson and Jacobs) opined that there was insufficient evidence to attribute causality to the Accutane psychiatric toxicity reports. "We believe that the evidence from these investigations does not support a causal association between Accutane and psychiatric events, including suicide. That is, the signal has not been confirmed by these investigations."

Dr. Robert Nelson (Roche, Pharmacoepidemiological Analysis) provided his analysis and opinions.

"Suicide attempts and completed suicides. Suicidal ideation is under DSM-IV as a depressive case. There were a total – and this is worldwide total – of 168 reports before the data lock point. 104 were attempts; 64 were completed suicides. My overall conclusions. Given no clear biological plausibility, no consistent pattern in the data that I reviewed, complex environment of background symptoms, very high background rates of disease, very high background rates of alternative risk factors, I conclude that there is no evidence in these data to support a causal relationship between Accutane administration and psychiatric disorders."

Dr. Mills, an epidemiologist, commented and criticized Middelkoop's data (slide presented by Liam Grant):

"If I remember the slide correctly, 1,400,400 prescriptions for one of the antibiotics with no suicides, no suicidal ideation. Now, you tell me that there's a population of a million and a half people anywhere in this country where nobody has any of those problems. It's a classic case of poor reporting. I personally would make absolutely nothing out of the data there for that simple reason, that you're just not getting accurate reporting at all."

Lawyer Richard Josephson who has represented Roche on Regulatory and other matters, pleaded the Advisory Committee for a scientific review.

"In law and in science we have adopted your methodologies. After years of not considering the scientific method in courts, we now have adopted from science the scientific method. If you look just briefly at the scientific method, they ask on the question of the contention of whether Accutane causes psychiatric reactions, the extent to which the theory has been assessed based on scientific valid reasoning and methodology, whether the theory has been subjected to peer review, case reports versus peer-reviewed studies, whether the theory is only based on subjective belief or speculation, whether there is a potential rate of error in this case in the adverse drug reports, and whether the underlying theory or technique has been generally accepted as valid by the scientific community.

I merely ask you to consider the fact that you now have a label, which under the scientific method, no one here can conclude that Accutane causes those effects. As you consider what remedial action, if any, is needed or additional action is needed, I only ask that you keep that in mind."

Dr. Alan Byrne (FDA), stated:

"Therefore, in relation to isotretinoin, my clinical observations have been that this agent can influence mood in certain individuals. My feeling is that the effects on mood may be very persistent, and obviously anything that can precipitate a depressive illness may be life-threatening because there is a significant risk of suicide with depressive illness.

Dr. Marilyn Pitts (FDA, Case Review) offered the following comments:

"The top 10 adverse events for Accutane include depression, ranked number 6. By contrast, we looked at tetracycline, which is another agent used for less severe acne. We have 8 cases of depression and 2 deaths, and we looked at Claritin in the AERS database where we have 10 cases of depression and 2 deaths.

In 1998, OPDRA analyzed spontaneous adverse drug event reports of positive dechallenge/rechallenge cases of depression, mania, psychosis, and suicide attempt. The 2998 case series supported the Accutane labeling change, which included a warning concerning psychiatric disorders. The warning stated that Accutane may cause depression, psychosis, and rarely, suicidal ideation, suicide attempts, and suicide.

In summary, we have 41 Accutane associated dechallenge/rechallenge cases. 76 percent were without a reported psychiatric history. The median time to onset of symptoms during the first course of Accutane was 30 days, and a median recovery time of 4.5 days. During the second course, or the rechallenge course, the time to onset of symptoms was shorter in the cases that provided the information. Also, after the second course of Accutane, depression persisted in some patients after discontinuation of Accutane and/or medical intervention. There was a possible dose-response to Accutane observed in 6 patients.

In conclusion, dechallenge/rechallenge cases provide strong evidence to support a link between a drug and an observed adverse event. We have presented 41 cases of positive dechallenge/rechallenge which provide further evidence to support a relationship between Accutane and depressive symptoms.

Dr. Wysowski (FDA, Postmarketing Experience Suicide and Depression), provided the following analysis:

“Over the 18-year period of marketing, the FDA received reports of 37 U.S. patients who committed suicide, 24 on Accutane and 13 after stopping the drug. Twenty two (22) percent of suicide cases were reported to have a psychiatric history. About 57 percent had other possible contributing factors for depression. In addition to the suicides, the FDA received reports of 110 U.S. Accutane users hospitalized for depression, suicidal ideation, and suicide attempt, 85 on Accutane and 25 after stopping the drug.

About a third of patients had positive dechallenges with psychiatric treatment, and nearly a third experienced persistent depression after drug discontinuation. One person had a positive rechallenge, while three others were rechallenged and were able to continue on Accutane with alcohol abstinence, dose lowering, and continued use of an antidepressant.

As of May 2000, the FDA received reports of 284 U.S. Accutane users with non-hospitalized depression. 45 percent were received in 1998 after depression and suicide were added as a warning to the labeling. About half of the non-hospitalized patients reported accompanying side effects such as dry mucous membranes, headaches, hair loss, and joint and muscle pain. About 50 percent of reports were from consumers and relatives, a higher proportion compared with most reports for most drugs.

The top 10 adverse events reported for Accutane include depression that ranks number 6. Of course, the degree of under-reporting is unknown and may be quite substantial.

There are several pieces of evidence supportive of a possible association between Accutane and depression and suicide. These include the relatively large number of reports of serious depression, more than for most drugs in the FDA's database, the temporal association between use of Accutane and onset of depression, positive dechallenges in individuals who felt better once Accutane was discontinued and psychiatric care was obtained, and positive rechallenges in individuals who experienced symptoms again after restarting the drug.

So, in summary, the FDA has received reports of suicide and serious depression in U.S. Accutane-treated patients. The case reports are suggestive of an association with Accutane, but do not allow definitive determination as to whether Accutane causes depression and suicide in treated patients.”

Dr. Kathryn O'Connell (FDA, Biological Plausibility and Risk Management):

“The first item that I mentioned was we ask ourselves, do we see psychiatric adverse events? Have they been reported with distinct substances that bind to the same physiologic receptor? Dr. Byrne and several other people have already referred to the fact that it is known that high dose vitamin A, hypervitaminosis A, has been associated with psychiatric adverse events. If you look in the published cases about time to offset, the most useful data -actually the paper has already been referred to I think by Dr. Byrne and perhaps by the sponsor as well that was published by Scheinman, et al. in 1990. I want to emphasize that this was not a trial done to examine the psychiatric adverse events of Accutane. This was just 700 patients – I believe it was an NIH trial that had received Accutane for various indications. It wasn't even all acne. 7 patients in that group had enough psychiatric problems to come to attention. Let's put it that way. But of those 7 patients that they reported in this paper, it's notable that the symptoms in all 7 of them resolved within 1 week of stopping Accutane, and 1 of the patients was rechallenged and

did have a positive rechallenge.

For Accutane, the central nervous system, interestingly, ranks second only to psychiatric in the highest percentage of serious adverse events – serious adverse events – in the Hoffmann-LaRoche postmarketing database for Accutane. So, I think it's clear that Accutane affects the central nervous system.

We don't know a mechanism for the psychiatric adverse events observed with any of the retinoids..

Dr. Miller recommended improvements in asking Accutane patients appropriate question to evaluate them from a psychiatric point of view.

“What would help me and make my practice much easier would be to have a specific form that would be dealt with with each patient that would include the pregnancy contraceptive issues, that would include the appropriate questions that I would ask from a psychiatric standpoint because I don't know what those questions are, but those questions that the psychiatrists feel are appropriate. And upon completion of that form, I would then be able to write a prescription for a patient. But the fulfillment of the recommendations would be the sine qua non for my writing the prescription for Accutane. I think this would help.”

On the second question before the committee regarding what kinds of future studies are both desirable and feasible:

Would further studies help clarify the relationship between Accutane use and psychiatric events? Yes: “Intervention”; Basic science studies; retrospective epidemiological studies.

Submission Of ADR Reports

ADR reports often paint an incomplete picture as the cases which are filed each year represent only a fraction of actual cases. According to the UK MCA only 10-15% of serious ADRs are ever reported. A FDA MedWatch Continuing Education article (Goldman et al 1996) describes significant underreporting in the United States. He cited estimates that rarely more than 10% of serious ADRs, and 20% of non-serious reactions are reported to the British spontaneous reporting program. A similar estimate is that FDA receives direct reports of less than 10% of suspected serious ADRs This means that cases spontaneously reported to any surveillance program, which comprise the numerator, generally represent only a small portion of the number that have actually occurred. The effect of underreporting can be somewhat lessened if submitted reports, irrespective of number, are of high quality.

Under regulations a pharmaceutical company must submit all ADR reports to the FDA periodically (at least annually) or on an expedited basis within 15 days of receipt. The FDA, on January 5th 1998, sent a warning letter to Hoffman-LaRoche (New Jersey) for failing to submit a number of adverse drug experience reports that were both serious and unexpected, within 15 working days as required by regulations (21 CFR 314.80 (c)(1)) as recently as October 1997 (with some dating back to 1989) (Scrip 1998). The letter documented, among others, two ADR reports for Accutane which were received by the manufacturers on 9/04/91 and 7/24/91. Both reports were not received by the FDA until 10/8/97 (FDA/Middelkoop personal communication). In one case, for Tigason, the company reported the adverse drug event almost 11 years after receiving the information. Thus,

although regulations require it, sometimes even the companies do not report in a timely basis, if at all. (Middelkoop, 2000)

Revised Label Warning

On February 25th 1998, the FDA issued a Talk Paper declaring new safety information regarding isotretinoin, as a result of adverse event reports the agency received. The revised information leaflet, now reads "*Psychiatric disorders: Accutane may cause depression, psychosis and, rarely, suicide ideation, suicide attempt and suicide. Discontinuation of Accutane therapy may be insufficient; further evaluation may be necessary. ...Of the patients reporting depression, some reported that the depression subsided with discontinuation of therapy and recurred with reinstitution of therapy*". Earlier information leaflets read "*depression has been reported in some patients on Accutane therapy. In some of these patients, this has subsided with discontinuation of therapy and recurred with reinstitution of therapy*". Thus, FDA has spoken: Accutane is linked to depression, psychosis, and suicide.

Almost one year prior to this revision, the French product label was altered on March 3rd 1997, to include 'suicide attempt' as a side effect of isotretinoin therapy, and reads "*In rare occasions, neuropsychological problems have been recorded (behavioral difficulties, depression, convulsions and suicide attempts)*" (French Product License, 1997). This revision was introduced in France following a prospective national inquiry (1993-94) in which Roche and more than 2000 state dermatologists participated. This inquiry followed a paper presentation, which reported on a suicide associated with isotretinoin therapy (Bravard, 1993). The results of this inquiry were presented at the 3rd Forum of the National and Provincial Journal of Dermatology at Mont Pellier (March 14-17 1996) but were never published. It was almost one year later, before this warning was introduced in any other country. According to The Star-Ledger (11/16/98) "Roche never informed the FDA of this new label change, who did not learn of the French label warning until this summer [1998]". Revised warnings have now been introduced in Ireland (May 1998) and UK (April 1998). Many have asked why French physicians and their parents were given a stronger and more explicit warning than their counterparts in the U.S., UK, and Ireland.

FDA's Battle With Accutane

During the 1980s and early 1990s FDA officials debated options to control and prevent the occurrence of Accutane-exposed pregnancies, including its removal from the market. The Columbus Dispatch (07/14/1996) documented David Graham's (section chief of the FDA's epidemiology branch) investigation of the situation and detailed several documents and memos which showed the FDA battling itself and Hoffman-LaRoche. Such documents revealed that between 1982 and 1987 approximately 1.2 million people were treated with Accutane. 560,000 were women of which 427,000 were between the ages of 12 and 44, and more than 90% of females treated did not have severe cystic acne. In a 1990 memo Graham wrote "The magnitude of injury and death has been great and permanent with 11,000 to 13,000 Accutane-related abortions and 900-1,100 Accutane-related birth defects. There is no alternative to immediate withdrawal". This analysis by Graham provides strong evidence that the overwhelming use of Accutane is not for severe acne.

INDICATIONS FOR USE - OVERPRESCRIBING

The package insert approved indication for Accutane states that "Accutane is indicated for the treatment of severe recalcitrant nodular acne... Because of significant adverse effects associated with its use, Accutane should be reserved for patients with severe nodular acne who are unresponsive to conventional therapy including systemic antibiotics."

Despite the plethora of serious side-effects associated with Accutane therapy and the high number of exposed pregnancies which occur every year due to poor compliance with prescription guidelines, there is evidence of prescription outside of the specified indication. Published accounts document high rates of use in non-severe acne patients, and many authors endorse its use in mild and moderate acne, claiming an excellent safety profile. Clearly, teenagers with acne benefit from improvement of their disease. However, to ignore the serious reports of depression and other psychiatric toxicities is to continue to place this population at risk.

SUMMARY AND RECOMMENDATIONS

While the future may hold interesting possibilities for the therapeutic uses of the retinoids, the present ambiguity about therapeutic versus potential hazardous side-effects of these retinoids, shows that a greater level of scrutiny needs to be given to adverse reactions. Given the increasing reports of depression and suicide associated with Accutane, special care must be exercised in prescription and in monitoring.

An FDA memo of February 1998 stated that for a majority of the evaluable cases of suicide, suicide attempt or suicide ideation associated with Accutane, for the majority, there was no antecedent history of depression, and the patients were not noted or known to be depressed in the time period prior to their suicide. As a result of underreporting, the actual number of suicides could be 10 times greater than the number of reports.

Clearly, Roche's and FDA's and Middelkoop's number differ and vary greatly. Any study, any case evaluation, any reporting system can be faulted, criticized, subject to bias and misinterpretation.

The numbers are alarming. The price is death and destruction of our children and young adults.

We don't need absolute scientific proof in order to recognize a signal and act on it. Indeed, the mechanism of action of Accutane in treating acne is unknown! In fact, the FDA rarely has more than signal before significant warning changes and sometimes drug withdrawal occurs.

In my opinion, we have sufficient evidence to be very concerned and take some corrective steps. The link between Vitamin A toxicity, including CNS toxicity, and Accutane is indisputable. This gives us literature precedent and biologic plausibility. Opponents claim that the teenage population is at high risk for suicide. All the more reason to be cautious when prescribing Accutane, a drug which is suspected of causing psychiatric toxicity even though causality has not been proven. The link between retinoids and schizophrenia is biologically plausible.

I'm not suggesting that Accutane be withdrawn from the market. Clearly, for patients with severe acne, it has an important place in therapy. However, the drug is overwhelmingly prescribed for minor and moderate conditions, despite existing warnings to the contrary in the package insert.

Patient registries, independent epidemiologic studies, and scientific research documenting the pathophysiological basis of Accutane psychiatric toxicity are needed. A consumer education campaign via FDA consumer alerts, encouraging prescribers to limit prescriptions in non-severe patients and use whatever consent forms are developed can help inform the public and prescribers, and thus limit the toxicity. Clear patient package information, describing and informing of the psychiatric risks is important so that the patient and their family make a decision to accept the risk, and if so, to be vigilant for signs of toxicity, so that the drug can be stopped and the patient monitored. Since an informed consent is already designed to warn of pregnancy risks, the psychiatric toxicities could easily be added.

Table 1. Worldwide Psychiatric ADR Reports (WHO)

Medication	Extract period	Psychiatric ADRs (% of total)	Suicide	Suicide Attempt	Suicidal Ideation
*Roaccutane	1982-98	1095 (59.8)	47	67	56
Minocycline	1971-98	261 (14.2)	0	2	0
Doxycycline	1965-98	213 (11.6)	0	0	0
Tetracycline	1964-98	169 (9.2)	0	3	0
†Dianette	1980-98	55 (3.0)	0	3	0
Oxytetracycline	1965-98	37 (2.0)	0	0	0

*Roche data cut-off date May 1998

†Values for Dianette include data for ethinylestradiol and cyproterone

Table 2. UK ADR data (source: MCA)

Medication	Psychiatric ADRs (% of total)	Extract Period	Suicide	Suicide Attempt	Suicidal Ideation
Roaccutane	135 (51.5)	1982-99	9	8	6
Minocycline	45 (17.1)	1973-98	0	0	0
Tetracycline	32 (12.2)	1964-98	0	0	0
Oxytetracycline	23 (8.7)	1965-98	0	0	0
Doxycycline	22 (8.3)	1965-98	0	0	0
Dianette	5 (1.9)	1987-98	0	0	0

Table 3. Prescription Data (England 1982-97)

Medication	*Prescriptions (x1000)	Indication Acne
Tetracycline	147237.0	NA
Oxytetracycline	31301.7	NA
Doxycycline	13650.0	NA
Minocycline	8802.9	NA
Dianette	1214.6	184.2
Isotretinoin	12.4	12.4

*Data provided by Dept. of Health, Statistics Division 1E, Prescription Cost Analysis System

REFERENCES

- Aggarwal A: Acute toxicity of vitamin A administered with measles immunization [letter; comment]. *Comments Comment on: Indian Pediatr* 1996 Dec;33(12):1053-5 *Indian Pediatrics*. 34(5):456-7, 1997 May
- Alamayehu W: Pseudotumor cerebri (toxic effect of the "magic bullet"). *Source Ethiopian Medical Journal*. 33(4):265-70, 1995 Oct.
- Bendich A, Langseth L: Safety of vitamin A. *Am J Clin Nutr* 1989;49:358-371.
- Berrard S, Faucon BN, Houhou L, Lamouroux A, Mallet J. Retinoic acid induces cholinergic differentiation of cultured newborn rat sympathetic neurons. *J Neurosci Res* 1993;35:382-89.
- Bifulco MH: The relation of vitamin A intake to cerebrospinal fluid pressure. *J Mount Sinai Hosp NY* 1957;24:713-719.
- Bigby M, Stern RS: Adverse reactions to isotretinoin. *J Am Acad Derm* 1988;18:543-552.
- Bonnetblanc JM, Hugon J, Dumas M: Intracranial hypertension with etretinate. *Lancet* 1983;22:974.
- Braun E: Vitamin A excess, deficiency, requirements, metabolism, and misuse. *Pediatr Clin North Am* 1962;9:935.
- Bravard P, Knig M, Rzeznick JC: Isotretinoin et depression: soyons vigilants. *Nouv Dermatol* 1993;12:215.
- Byrne A, Costello M, Greene E et al: Isotretinoin therapy and depression - Evidence for an association. *Ir J Psych Med* 1998;15(2):58-60.
- Comments Comment in: *Rev Neurol (Paris)* 1998 Nov;154(11):784-5
- Cunliffe WJ: Optimum treatment of acne: a mechanistic approach to a good clinical outcome. *Mod Med Ireland* 1998;28(7/8):31-34.
- Cunliffe WJ, van de Kerkhof PCM, Caputo R: Roaccutane treatment guidelines: Results of an international survey. *Dermatology* 1997;194:351-357.
- Drouet A and Valance J:[Benign intracranial hypertension and chronic hypervitaminosis A (see comments)]. [French]
- Elliot RA, Dryer CG: Hypervitaminosis A: Report of a case in an adult. *JAMA* 1965;161:1157-1159.
- Fishbane S, Frei GL, Finger M, et al: Hypervitaminosis A in two hemodialysis patients. *American Journal of Kidney Diseases*. 25(2):346-9, 1995 Feb.
- Gatti S, Serri F: Acute depression from isotretinoin (letter). *J Am Acad Derm* 1991;25:132.

- Gerber A, Raab AP, Sobel AE: Vitamin A poisoning in adults: With description of a case. *Am J Med* 1954;16:729-745.
- Goldman SA, Kennedy DL, Graham DJ, Gross TP, Kapit RM, Love LA, and White GG. The Clinical Impact of Adverse Event Reporting. Staff College, Center for Drug Evaluation and Research, Food and Drug Administration, October, 1996.
- Goodman AB: Chromosomal locations and modes of action of genes of the retinoid (Vitamin A) system support their involvement in the etiology of schizophrenia. *Am J Med Gen* 1995;60:335-348.
- Goulden V, Layton AM, Cunliffe WJ: Current indications for isotretinoin as a treatment for *Acne vulgaris*. *Dermatology* 1995;190:284-287.
- Grissom LE, Griffin GC and Mandell GA: Hypervitaminosis A as a complication of treatment for neuroblastoma. *Pediatric Radiology*. 26(3):200-2, 1996.
- Guzzo CA, Lazarus GS, and Werth VP: Chapter 64 Dermatological Pharmacology in Goodman & Gillman's *The Pharmacological Basis of Therapeutics*, 9th Edition, 1996.
- Halter U: Der fall aus der Praxis (224). Akuter exogener reaktionstypus (Delirium) nach einnahme von Tigason. *Schweizerische Rundschau für Medizin Praxis* 1991;80:883-884.
- Haupt R: Acute symptomatic psychosis in vitamin A intoxication (authors translation) [German]. *Nervenarzt* 1977;48:91-95.
- Hauser SL: Isotretinoin May Be Implicated in Severe Depression. Update to Chapter 385: Mental Disorders and to Chapter 55: Eczema, Psoriasis, Cutaneous Infections, Acne, and Other Common Skin Disorders in *Harrison's Principles of Internal Medicine*, 14th Edition, 1998
- Hazen PG, Carney JF, Walker AE et al: Depression - a side-effect of 13-cis retinoic acid therapy. *J Am Acad Derm* 1983;9(2):278-279.
- Hutchinson TA, Lane DA. Assessing methods for causality assessment. *J Clin Epidemiol* 1989, 42: 5-16.
- Jones JK. Determining Causation from Case Reports, in Strom BL., *Pharmacoepidemiology*, Second Edition, Wiley, New York, 1994, at page 365.
- Kane EK: Arctic explorations in the years 1853, 1854, 1855. Philadelphia. Childs and Peterson Pub 1856;1:392.
- Kapur S: High levels of dopamine D2 receptor occupancy with low-dose haloperidol treatment: A PET study. *Am J Psychiatry* 1996;153(7):948-950.
- Landy D: Pibloktoq (hysteria) and inuit nutrition: Possible implication of hypervitaminosis A. *Soc Sci Med* 1985;21:173-185.

- Layton AM: Long-term safety and efficacy of oral isotretinoin in less severe acne. *Retinoids Today and Tomorrow* 1996;43:6-7
- Lee AG: Pseudotumor cerebri after treatment with tetracycline and isotretinoin. *Cutis* 1995;55:165-168.
- Lewin AH, Bos ME, Zusi, et al: Evaluation of retinoids as therapeutic agents in dermatology. *Pharmaceutical Research*. 11(2):192-200, 1994 Feb.
- Lombaert A, Carton H: Benign intracranial hypertension due to hypervitaminosis A in adults and adolescents. *Eur Neurol* 1976;14:340-350.
- Marcus R and Couiston AM: Chapter 63, Fat-Soluble Vitamins, Vitamin A, K, and E; Vitamin A, in Goodman & Gillman's *The Pharmacological Basis of Therapeutics*, 9th Edition, 1996.
- McCance-Katz EF, Price LH: Depression associated with vitamin A intoxication. *Psychosomatics* 1992;33(1):117-118.
- Meyskens, F.L. Jr. Short clinical reports. *J Am Acad Derm*, 6:732, 1982.
- Middelkoop T: Accutane: Focus on Psychiatric Toxicity and Suicide, Chapter in O'Donnell JT: *Drug Injury, Liability, Analysis and Prevention*, Lawyers & Judges Publishers, Tucson, AZ, 2000
- Nagai K, Hosaka H, Kubo et al: Vitamin A toxicity secondary to excessive intake of yellow-green vegetables, liver and laver. *Journal of Hepatology*. 31(1):142-8, 1999 Jul.
- Nulman I, Berkovitch M, Klein J: Steady-state pharmacokinetics of isotretinoin and its 4-oxo metabolite: Implications for fetal safety. *Pediatrics* 1998;38:926-930.
- Oliver TK and Havener WH: Eye manifestations of chronic vitamin A intoxication. *Arch Ophthalmol* 1953;60:19-22.
- Oliver J: Keratomalacia on a "healthy diet". *Br J Ophthalmol* 1986;70:357-360.
- Orfanos CE, Zouboulis CC, Almond-Roesler B, Geilen CC: Current use and future potential role of retinoids in dermatology. *Drugs* 1997;53(3):358-388.
- Ortonne JP: Oral isotretinoin treatment policy. Do we all agree? *Dermatology* 1997;195(suppl 1):34-37.
- Pasquariello PS, Schut L, Borns P: Benign increased intracranial hypertension due to chronic vitamin A overdosage in a 26-month-old child. *Clin Pediatr* 1977;16:379-382.
- Peck GL, et al: Treatment of Darier's disease, lamellar ichthyosis, pityriasis rubra pilaris, cystic acne and basal cell carcinoma with oral 13-cis-retinoic acid. *Dermatologica* 1978;157 (Suppl):11.
- Revue Neurologique*. 154(3):253-6, 1998 Apr.

- Riddell RH, ed. Pathology of Drug-Induced and Toxic Diseases. Churchill Livingstone, New York, 1982 (3-9).
- Rose A, Matson D: Benign intracranial hypertension in children. *Pediatrics* 1967;39:227
- Roytman M, Frumkin A, Bohn TG: Pseudotumor cerebri caused by isotretinoin. *Cutis* 1988;42:399-400.
- Scheinman PL, Peck GL, Rubinow DR et al: Acute depression from isotretinoin. *J Am Acad Derm* 1990;22(6):1112-1114.
- Scrip Magazine: French tighten rules on Roaccutane. *Scrip* 1996;2159:21.
- Selhorst JB, Jennings S, et al: Liver lover's headache: Pseudotumor cerebri and vitamin A intoxication. *JAMA* 1984;252(24):3365.
- Shapiro LE, Knowles SR, Shear NH: Comparative safety of tetracycline, minocycline and doxycycline. *Arch Dermatol* 1997;133:1224-30.
- Shariëff GQ: Pseudotumor Cerebri and Hypercalcemia Resulting From Vitamin A Toxicity [Case Report]. Volume 27(4) April 1996 pp 518-521
- Shaw EW, Niccoli JZ: Hypervitaminosis A: Report of a case in an adult male. *Ann Intern Med* 1953;39:131-134.
- Siegel NJ, Spackman TJ: Chronic hypervitaminosis A with intracranial hypertension and low cerebrospinal fluid concentration of protein. *Clin Pediatr (Phila)* 1972;11:580-584.
- Spector RH, Carlisle J: Pseudotumor cerebri caused by a synthetic vitamin A preparation. *Neurology* 1984;34:1509-1511.
- Stimson WH: Vitamin A intoxication in adults: Report of a case with a summary of the literature. *New Eng J Med* 1961;265:369-373.
- Villalobos D, Ellis M and Snodgrass WR: Isotretinoin (Accutane)-associated psychosis. *Vet Human Toxicol* 1989;31(4):231.
- Wiegand UW, Chou RC: Pharmacokinetics of oral isotretinoin. *J Am Acad Derm* 1998;39(suppl. pt 3):S8-S12
- Wilson JD: Chapter 79, Vitamin Deficiency and Excess. Vitamin Excess, Vitamin A and Carotenes in Harrison's Principles of Internal Medicine, 14th Edition, 1998

Mr. BURTON. Dr. Bull.

Dr. BULL. I would first like to thank the families for being here. I think the human face that they place on this is far more compelling than any Medwatch form that I have ever viewed in this area.

Mr. Chairman, members of the committee, I am Jonca Bull. I am Deputy Director of the Office of Drug Evaluation V of the Center for Drug Evaluation and Research of the Food and Drug Administration.

I appreciate the opportunity to discuss the committee's concerns regarding the drug Accutane. Helping to ensure the safe and effective use of Accutane has involved difficult scientific and ethical issues for FDA. We have taken our regulatory responsibilities concerning this drug very seriously.

FDA approved Accutane in 1982 for use in the treatment of severe recalcitrant cystic acne that is unresponsive to conventional therapy, including antibiotics. Accutane is uniquely effective in treating patients with this disease, but is associated with serious adverse events, including birth defects. For this reason, it continues to be one of FDA's most difficult challenges in the area of post-approval risk management.

FDA must constantly balance the public need for access to effective therapies with the risks associated with their use. FDA has been proactive in addressing the issue of risk management. We recognize, however, that FDA is but one of many players that can and must have an impact on the safety of health care in the United States.

Because Accutane is the only product that can potentially cure cystic acne, FDA permitted the continued marketing of the product in spite of the known risk of birth defects and other serious reactions. FDA has proceeded to periodically reassess the risk-benefit equation.

From 1983 through 1990, FDA and the manufacturers stepped up efforts to communicate the significant risk to women of child-bearing age. The original clinical trials for market approval for Accutane did not contain significant reports of depression or mood disorders. However, in the mid-1980's, due to postmarketing reports of depression, a label revision was done to include changes in mood and depression as part of the adverse reaction section.

FDA began a reevaluation of the psychiatric illness reports in 1996 when a physician in the Reviewing Division noted two cases of suicide in a routine listing of recent adverse events associated with Accutane. Reports such as this does not necessarily mean that the event has any relationship to the drug. Accutane, however, had previously been associated with depression as already noted in the Accutane labeling.

Because suicide is the most serious consequence of depression, the FDA Reviewing Division enlisted the help of specialists in the FDA Epidemiology Division to try to determine whether the cases could possibly be related to Accutane use.

The divisions undertook a systematic analysis of the published literature, previously reported cases entered into data bases and incoming safety reports. These reports were not numerous relative to the rate of depression and suicide expected to be seen in the population likely to receive Accutane, teens and young adults. Some of

the reports, however, included important details that did suggest the possible involvement of Accutane.

Therefore, in May 1997, the FDA began working with the manufacturer to fully evaluate the data and determine appropriate next steps. In February 1998, a labeling change moved psychiatric adverse events in the professional labeling to the warning section. While Accutane labeling had previously included depression in the adverse reaction section, it was hoped that the addition of wording that calls attention to possible suicidal behavior would help further ensure that prescribers would take appropriate actions if patients developed mood changes. Even though a causal relationship between Accutane and suicidal behavior had not been scientifically established, this action was thought prudent, given the available information.

In addition, a letter was sent to doctors who might prescribe Accutane, as well as those likely to see patients who develop psychiatric disturbance. FDA also posted a special notice about Accutane on its public Web site and released a talk paper to the press to further ensure wide attention and dissemination of this warning. There was also an update placed on the FDA consumer Web site. FDA also instructed the manufacturer to discontinue promotional claims regarding the psychosocial benefits of Accutane treatment for acne.

Patient information is intended to remind the patient about important things they discussed about their treatment with their prescriber. It is not often—it is often not identical to the wording of professional labeling. Prior to the 1998 change in the professional labeling, there were five signs of potentially serious problems listed as bullets for patients, with all capital letter instructions to stop Accutane and call their doctor immediately.

All of these bullets, except mood changes, reflected serious adverse events in the warning section of the professional labeling. Thus, when psychiatric problems were moved in 1998 to the warning section of the professional labeling, it was already in the proper list in the patient information.

As with other symptoms of possible serious or fatal problems, the patient information on mood changes did not include specific information about the possible outcome, that is, suicide, instead being followed by the advice to stop the drug and call the doctor immediately due to the possibilities of serious consequence.

After the 1998 labeling change about psychiatric disorders, FDA embarked on a very comprehensive reassessment of the overall labeling and risk management for Accutane. The revised patient information resulting from this work was implemented on an interim basis, with a commitment by the manufacturer to conduct patient comprehension testing and to pursue further revision. The interim revision implemented in the summer of 2000 captures the possible outcome for mood disorder; that is, suicide. The need for research to determine if the linkage was causal began soon after the labeling change. The manufacturer undertook multiple epidemiologic studies. Results reported thus far have been inconclusive.

Epidemiologic studies by FDA of the dechallenge/rechallenge cases, also analyzed by Roche study, are suggestive of the critical need for further research. It is very likely that a controlled mass

clinical study would not be feasible for ethical and technical reasons. Therefore, an important goal of seeking outside expert advice was to explore other approaches.

In September 2000, the Dermatologic and Ophthalmic Drugs Advisory Committee again discussed Accutane. The two major topics were prevention of fetal exposure and risk management strategies for the uncertain risks of psychiatric effects associated with the use of Accutane.

On the issue of psychiatric events, the committee unanimously agreed that there was sufficient concern about Accutane to justify exploring additional risk management strategies, even though the risk was uncertain. The committee recommended that the manufacturer add the information about the adverse events to the informed consent documents signed by patients and their parents or guardians prior to receipt of Accutane; that they develop and distribute an enhanced prescriber educational program about the psychiatric events; that a medication guide be developed and implemented for Accutane.

The committee was also asked whether further studies to help clarify the relationship between Accutane use and psychiatric events were needed, and, if so, what kinds of studies. The committee discussed the many ethical and technical problems with controlled clinical trials in this instance and offered ideas for other types of studies with an emphasis on basic science research, particularly focused on the adolescent central nervous system, as well as epidemiologic studies in addition to those already under way. The agency is working with the manufacturer as well as the National Institutes of Health to implement the committee's recommendations.

In conclusion, Accutane continues to be one of the more challenging products that FDA regulates. We think the record demonstrates the agency's continued concern regarding this product and our efforts to manage the associated risks. We are hopeful that research will establish whether or not the psychiatric events associated with the use of Accutane are truly caused by the drug. We will continue to work with the manufacturer to keep health professionals and consumers aware of the risks associated with Accutane and the circumstances under which it should be used and prescribed.

Thank you for the opportunity to discuss this important matter.
[The prepared statement of Dr. Bull follows:]



DEPARTMENT OF HEALTH & HUMAN SERVICES

Food and Drug Administration
Rockville MD 20857

STATEMENT BY
JONCA BULL, M.D.
DEPUTY OFFICE DIRECTOR
OFFICE OF DRUG EVALUATION V
CENTER FOR DRUG EVALUATION AND RESEARCH
FOOD AND DRUG ADMINISTRATION

BEFORE THE
COMMITTEE ON GOVERNMENT REFORM
U.S. HOUSE OF REPRESENTATIVES

DECEMBER 5, 2000

RELEASE ONLY UPON DELIVERY

Introduction

Mr. Chairman and Members of the Committee, I am Jonca Bull, M.D., Deputy Director of the Office of Drug Evaluation V, Center for Drug Evaluation and Research (CDER), Food and Drug Administration (FDA or the Agency). I appreciate the opportunity to discuss the Committee's concerns regarding the drug Accutane. Helping to ensure the safe and effective use of Accutane has involved difficult scientific and ethical issues for FDA. We have taken our regulatory responsibilities concerning this drug very seriously.

FDA approved Accutane in 1982 for use in the treatment of severe, recalcitrant cystic acne that is unresponsive to conventional therapy, including antibiotics. In most cases, cystic acne is severely disfiguring, causing red cysts and nodules, which can leave deep scars. Accutane is uniquely effective in treating patients with this disease, but is associated with serious adverse events including birth defects. For this reason, it continues to be one of FDA's most difficult challenges in the area of post-approval risk management.

FDA must constantly balance the public need for access to effective therapies against the risks associated with their use. FDA has been proactive in addressing the issue of risk management. For example, as one of her first initiatives as Commissioner, Dr. Jane E. Henney established a Task Force to evaluate the system for managing risks of FDA-approved medical products, focusing particularly on FDA's part in the system. We recognize that FDA is but one of many players that can and must have an impact on the safety of health care in the United States. One of FDA's primary responsibilities is in the premarket phase. A major goal of the premarketing review of a drug is to help ensure by the careful review of the data collected in the

clinical trials that products are truthfully and adequately labeled for their intended use and target population. Approval of a drug product is based on FDA's acceptance and review of data collected during the course of the drug's development, including the results of clinical trials demonstrating that the drug is safe and effective for its intended use. No drug, however, is 100 percent safe; no pharmacologically active medicine exists that does not have side effects. FDA realizes that when an approved new drug becomes widely used in clinical practice, health care professionals may observe differences from clinical trial results in both the incidence and/or types of adverse drug experiences. For this reason, FDA's other primary responsibility is postmarketing surveillance--to monitor rare, serious, unexpected adverse drug events (i.e., serious or unexpected adverse reactions not described in the approved labeling). The Agency monitors reports from manufacturers, consumers, and health professionals to determine if any safety problems or trends can be identified and takes action accordingly.

After a drug is approved, the prescriber assumes primary responsibility for managing the product risks (and benefits) for the individual patient because of his/her specific knowledge of the unique circumstances surrounding each individual patient. In this situation, FDA's role has been to assist the prescriber by requiring that risks and benefits are described in the labeling and promotional materials, and to assure, through postmarketing surveillance of reports of potential new safety information, that this new information about risks is relayed promptly to clinicians. To minimize risks, product labeling often describes how to select patients, how to select and modify the dose schedule for individual patients, how to avoid interacting treatments, how to monitor for drug toxicity, and what measures to use to avoid or mitigate drug toxicity. FDA and manufacturers rely on practitioners to prescribe products with full knowledge of the prescribing

information and limitations detailed in the product labeling. Likewise, practitioners presume their patients will use their medications according to directions given. We know, however, that this does not always happen.

Because all drugs have risks, it is critical that patients are fully informed about potential side effects as well as benefits before deciding to take a particular medicine. Once the choice to take a product is made, patients need to understand how to take the medicine properly, the precautions they should observe, and the signs of possible side effects. FDA has worked for over two decades to help ensure that patients get the full information that they need to take medicines as safely as possible. In 1980, the Agency published a rule requiring FDA approved patient labeling for ten drugs/drug classes, with the expectation that this would be extended to all prescription drugs. In 1982, the rule was revoked in favor of private sector efforts to provide patient information that FDA would monitor.

By 1994, FDA surveys showed that only 58 percent of patients were receiving some sort of information with prescriptions. Therefore, in 1995, FDA published a proposed rule, commonly called MedGuide, that set forth goals for the distribution of useful prescription drug information to consumers, and would have required manufacturers to include drug information for the patient when a product posed a serious and significant public health concern. In August 1996, Congress passed legislation that provided another opportunity for private achievement of the MedGuide goals. Consequently, a private sector Action Plan was developed to meet the need. In 1998, FDA published a final rule requiring patient labeling (MedGuides) for products that pose “serious and significant” public health concerns, anticipating an average of no more than five to

ten products annually. This rule became effective on June 1, 1999, and provides the framework under which the proposed Accutane MedGuide is being developed. For the vast majority of products that will not have MedGuides, patient information given out with prescriptions is expected to be provided by the voluntary private sector effort.

Adverse Effects Associated with Accutane

When Accutane was approved, the most common adverse reaction reported was severe drying and chapping of the lips, which occurred in about 90 percent of patients. In addition, 25 percent of patients treated had an elevation of serum triglycerides (fatty substances in the blood), and elevated cholesterol levels. The labeling of the drug, therefore, suggested that physicians closely monitor these levels during treatment. Also, the approved labeling also informed physicians that about 40 percent of patients developed conjunctivitis, 16 percent developed musculoskeletal symptoms, less than 10 percent of patients experienced rash or thinning of hair, and about five percent experienced peeling of palms and soles, skin infections, nonspecific urogenital findings, nonspecific gastrointestinal symptoms, fatigue, and increased susceptibility to sunburn. Because teratogenicity was observed in animals, Accutane was contraindicated in patients who were pregnant or planning to become pregnant, or in nursing mothers.

During the first ten years after the initial marketing of Accutane, the primary focus of concern was managing the established risk of birth defects, a risk initially suspected and noted in the labeling. FDA's staff held numerous meetings with the company, analyzed adverse event reports, and convened at least seven Advisory Committee meetings.

Because Accutane is the only currently available product that can potentially cure cystic acne, FDA permitted the continued marketing of the product in spite of the known risk of birth defects and other serious reactions. FDA has proceeded to periodically reassess the risk/benefit equation. From 1983 through 1988, FDA and the company stepped up efforts to communicate the significant risks to women of child-bearing age. These efforts included: 1) physician labeling changes; 2) repeated mailings of special letters to doctors and pharmacists detailing proper use and emphasizing the risks; 3) two articles in FDA's Drug Bulletin, which reached more than a million health professionals, emphasizing proper prescribing of Accutane; 4) distribution to patients through doctors of a patient information leaflet highlighting the risks; 5) distribution to pharmacists of red warning stickers to be placed on each prescription bottle; and 6) issuance of press releases and background papers to the general news media for use in warning the public about the risks associated with Accutane.

Despite these efforts, there was evidence that the drug was being used in thousands of women of child-bearing age with less severe acne than that for which the drug was approved, i.e., for severe recalcitrant cystic acne which does not respond to conventional therapy. In 1988, the Centers for Disease Control and Prevention (CDC) published an article describing four cases of multiple, serious birth defects occurring from 1983 to 1987, and cited additional cases previously reported. Consequently, FDA convened another Dermatologic Drugs Advisory Committee (the Committee) meeting to consider various options for dealing with the problem. The Committee listened to presentations from experts in several medical specialties, as well as scientists from CDC, FDA, Hoffman La-Roche, Public Citizen's Health Research Group, the American Academy of Pediatrics, and the American Academy of Dermatology. At FDA's request,

additional experts participated in the deliberations, including doctors specializing in obstetrics, birth defects, genetic diseases, reproductive sciences, clinical pharmacology, and epidemiology. At the end of the day-long session, the Committee unanimously recommended continued sale of Accutane with revised labeling for physicians and patients and further restrictions in connection with distribution of the drug including: 1) increased prominence and strength of warnings and contraindications through new packaging, and more explicit information about the degree of risk; 2) recommended use only in women who have had a negative pregnancy test (if they are able to bear children); and 3) written acknowledgement from patients taking the drug that they have been informed of the risk of birth defects. In a split vote, the Committee recommended that the drug's use be restricted by one or more of the following: 1) dispensing only by certain physicians, 2) special restrictions for high risk patients, 3) requiring a second opinion for high risk female patients, or 4) requiring an educational program for certification of physicians to dispense the drug. The Committee also asked for continued monitoring of use and reports of all adverse events.

After the Committee made its recommendations, in May 1988, FDA issued a letter to Hoffman-La Roche outlining actions designed to limit or prevent misuse of the drug. The May 1988 letter provided in part: 1) that Accutane be dispensed in a blister pack with the patient warnings (including pictures showing the severity of birth defects) and other information as part of the package itself (this information was provided in addition to the pamphlets physicians provide to patients); and 2) physicians and women patients be asked to sign a form acknowledging their understanding of the very great likelihood of serious birth defects if the drug was taken during pregnancy. More detailed physician and patient labeling was also mandated. FDA's letter also

called for extensive educational campaigns aimed at physicians, pharmacists, and patients and encouraged publication of advertisements on the teratogenic effects of the drug.

Furthermore, FDA's 1988 letter stated that the blister pack should include a tear-off postcard addressed to the company requesting the patient's name, telephone number, address, and permission to be contacted by the company for studies requested by FDA. FDA requested a follow-up study to ascertain patient awareness, disease status, contraception use, information regarding any pregnancy, and the outcome of that pregnancy. The letter also requested reporting of all pregnancy exposures and an effort to find out why patients, despite warnings, became pregnant or used the drug when already pregnant. The company was asked to do further clinical trials using lower doses of the drug, or higher doses for a shorter period of time.

In mid-1989, the company fully implemented its "Pregnancy Prevention Program for Women on Accutane." This program included the unprecedented educational efforts and restrictions requested by the May 1988 letter from FDA. Consequently, in May 1990, Accutane underwent review by FDA's Dermatologic Drugs Advisory Committee. FDA asked the Committee to evaluate the effectiveness of the company's efforts to curb drug/pregnancy exposures and birth defects, and whether additional measures were necessary. The Committee concluded that the manufacturer made a very strong effort to inform patients and physicians of the risk associated with Accutane but that the data on recent efforts was limited. Data included one infant reported with defect in 1990, four in 1989, and three in 1988, compared to ten for 1987 and 12 for 1986. The Committee recommended: 1) that educational materials emphasize the importance of the initial pregnancy test before beginning treatment with Accutane; 2) that physicians stress to

patients the importance of the informed consent forms and that such forms be available in numerous languages; 3) pregnancy prevention counseling be made available and emphasized; and 4) that the manufacturer design a program to ensure that patients returned all leftover medications so they would not take Accutane without a dermatologist's supervision.

Warnings Regarding Accutane and Depression and Suicidal Behavior

The original New Drug Application (NDA) safety database for Accutane did not contain reports of depression or mood disorders. In the mid-1980s, however, due to postmarketing reports of depression, a labeling revision was done to include depression as part of the adverse reactions section. The labeling provided: "Depression has been reported in some patients on Accutane therapy. In some of these patients, this has subsided with discontinuation of therapy, and recurred with reinstatement of therapy." In addition, the adverse reactions section stated: "The following CNS reactions have been reported and may bear no relationship to therapy: seizures, emotional instability, dizziness, nervousness, drowsiness, malaise, weakness, insomnia, lethargy, and paresthesias."

FDA began a re-evaluation of the psychiatric illness reports in 1996, when a physician in the reviewing division noted two cases of suicide in a routine listing of recent adverse events associated with Accutane. Reports such as this do not necessarily mean that the event has any relationship to the drug. Accutane, however, had previously been associated with depression as already noted in the Accutane labeling. Because suicide is the most serious consequence of depression, the FDA reviewing division enlisted the help of specialists in the FDA epidemiology division to try to determine whether the cases could possibly be related to Accutane use. The

division undertook a systematic analysis of the published literature, previously reported cases entered into databases, and incoming safety reports.

These reports were not numerous relative to the rate of depression and suicide expected to be seen in the population likely to receive Accutane, namely teens and young adults (sometimes referred to as the “background” rate). Some of the reports, however, included important details that did suggest the possible involvement of Accutane. Some reports described a consistent pattern of symptoms in patients with no previous history of such symptoms and no other identifiable reason for their occurrence. Other cases were described in which the symptoms began during the Accutane treatment and then resolved soon after the medicine was stopped. In a subset of these cases, Accutane was then restarted and the same symptoms returned. While these findings do not prove that Accutane causes psychiatric illness, they are suggestive of a possible link.

In May 1997, when an association appeared possible, FDA began working with the company to fully evaluate the data and determine appropriate next steps. In February 1998, a labeling change included psychiatric adverse events in the professional labeling’s Warnings section, stating: “Psychiatric Disorders: Accutane may cause depression, psychosis, and rarely, suicidal ideation, suicide attempts, and suicide. Discontinuation of Accutane therapy may be insufficient; further evaluation may be necessary. No mechanism of action has been established for these events (see Adverse Reactions: Psychiatric).” The Adverse Reactions section stated “psychiatric: suicidal ideation, suicide attempts, suicide, depression, psychosis (see warnings: Psychiatric Disorders), emotional instability.” While Accutane labeling had previously included

depression in the adverse reactions section, it was believed that the addition of wording that called attention to possible suicidal behavior would help to ensure that prescribers would take appropriate actions if patients developed mood changes. Even though a causal relationship between Accutane and suicidal behavior still had not been scientifically established, this action was thought prudent given the available information.

In addition, a letter was sent to doctors who might prescribe Accutane, as well as those likely to see patients who develop psychiatric disturbance. FDA also posted a special notice about Accutane on its public website and released a Talk Paper to the press to help ensure wide attention and dissemination of this warning. FDA also instructed the company to discontinue promotional claims regarding the psychosocial benefits of Accutane treatment for acne.

Patient information is intended to remind patients about important things they discussed about their treatment with their prescriber. It is often not identical to the wording of professional labeling. Prior to the 1998 change in the professional labeling, there were five “signs” of potentially serious problems listed as bullets for patients, with all capital letter instructions to stop Accutane and call their doctor immediately. All of these “bullets” except mood changes reflected serious adverse events in the Warning section of the professional labeling. Thus, when psychiatric problems were upgraded in 1998 to the Warning section of the professional labeling, it was already in the proper list in the patient information. As with other “symptoms” of possible serious or fatal problems, the patient information on mood changes did not include specific information about the possible outcome (suicide), instead being followed by the advice to stop the drug and call the doctor immediately due to the possibility of serious consequences. For

example, the patient information said to watch out for yellow skin or abdominal pain. This reflects professional labeling about hepatotoxicity or pancreatitis, which can be fatal.

After the 1998 change regarding psychiatric disorders, FDA embarked on a very comprehensive re-assessment of the overall labeling and risk management for Accutane. This comprehensive re-evaluation included the following: 1) ways to improve methods to prevent birth defects; 2) possible interactions with drugs not on the market in 1982 when Accutane was approved (e.g., new contraceptive therapies); 3) epidemiologic study of accumulating reports of adverse events not in the labeling to decide on inclusion; 4) safety issues specific to young growing patients; 5) re-organization of the information to make it more useable for prescribers; and 6) re-design of the patient information to improve visibility of items not related to pregnancy prevention, adding new information, and providing specific information about possible outcomes for serious events. The revised patient information resulting from this work was implemented on an interim basis with a commitment by the manufacturer to conduct patient comprehension testing and to pursue further revisions. The interim revision, implemented in the summer of 2000 captures the possible outcome for mood disorder (suicide) but did not accomplish this goal for all of the bulleted serious adverse events.

FDA and the company also began to address the need for further research into the potential link between Accutane and psychiatric events soon after the 1998 labeling change. Roche began a number of studies. The company and FDA had frequent working meetings and some results were submitted to FDA beginning in late 1999. Some of these studies were discussed at the September 2000 meeting of FDA's Dermatologic and Ophthalmic Drugs Advisory Committee,

at least one has been published, and the results of another are expected soon. To date, these studies do not provide a definitive answer. It is very likely that a controlled masked clinical study would not be feasible for ethical and technical reasons and a major goal of seeking outside expert advice in September 2000 was to explore other approaches.

September 2000

As noted previously, in September 2000, the Dermatologic and Ophthalmic Drugs Advisory Committee again discussed Accutane. The two major topics were prevention of fetal exposures and risk management strategies for the uncertain risk of psychiatric effects associated with the use of Accutane. On the pregnancy prevention issue, the Committee agreed on the following three goals or principles: 1) no one should begin Accutane therapy if pregnant; 2) no pregnancies should occur while on Accutane therapy; and 3) a monitoring program should be implemented to assess progress toward these goals. FDA presented five designs to achieve these goals, and the majority of the Committee voted on a design that included: 1) education and informed consent; 2) complete participation including registration of patients and physicians; and 3) tracking of pregnancy exposures including a pregnancy registry, surveys, and external data. The Committee did not want restricted distribution.

On the issue of psychiatric events, the Committee unanimously agreed that there was sufficient concern about Accutane to justify exploring additional risk management strategies even though the risk was uncertain. The Committee recommended that the manufacturer: 1) add the information about the adverse events to the informed consent document signed by patients and/or their parents or guardians prior to receipt of Accutane; 2) develop and distribute an enhanced

prescriber educational program about the psychiatric events; and 3) develop and distribute a Medication Guide for Accutane. The Committee also was asked whether further studies to help clarify the relationship between Accutane use and psychiatric events were needed and if so, what kind of studies. The Committee discussed the many ethical and technical problems with a controlled clinical trial and offered ideas for other types of studies with an emphasis on basic science research, particularly focused on the adolescent central nervous system, as well as epidemiologic studies in addition to those already underway. The Agency is working with the manufacturer to implement the Committee's recommendations.

Conclusion

Accutane continues to be one of the more challenging products FDA regulates. We think the record demonstrates the Agency's continued concern regarding this product and our efforts to manage the associated risks. We hope that the future will bring a product effective for severe recalcitrant cystic acne without the risk of birth defects or other possible serious adverse events. We are also hopeful that research will establish whether or not the psychiatric events associated with the use of Accutane are truly caused by the drug. We will continue to work with the manufacturer to keep health professionals and consumers aware of the risks associated with Accutane and the circumstances under which it should be used and prescribed. Thank you for the opportunity to discuss this important matter.

Mr. BURTON. I presume that Dr. Huene does not want to make an opening statement; is that correct?

Dr. BULL. No.

Mr. BURTON. OK.

We will probably have a couple of rounds of questions, questions at least as far as I am concerned. So bear with us. We are going on 5-minute rounds, and then we will come around with a second round for those who want to ask more questions.

Dr. Jacobs, are you aware that a month after the "dear doctor" letter was sent out warning doctors about the concern about Accutane being linked to depression, that the FDA sent a warning letter to Roche Laboratories about advertising that made false or misleading statements and promoted Accutane for an unapproved use?

According to the warning letter, "Roche's promotional materials state or suggest that Accutane is safe and effective in the treatment of what Roche describes as the psychosocial trauma and emotional suffering associated with acne, including negative psychosocial effects such as depression and poor self-image." This claim is particularly troublesome in light of information recently presented in a "dear doctor" letter that Accutane may cause depression, psychosis and rarely suicidal ideation, suicide attempts and suicide.

As someone who is an expert in suicide, how would you respond to a company promoting a drug with reported suicides for a treatment for psychosocial trauma?

Dr. JACOBS. Well, first of all, I am not aware of any communications between Roche and FDA. I mean, you are bringing that to my attention. I have not seen that.

The issue for me, as an expert, is that suicide and depression can occur in the Accutane-treated population. On the other hand, we know that persons who have severe acne, as was indicated by Dr. Pariser, can have psychiatric symptoms, including depressive symptoms, anxiety symptoms. The Accutane can be helpful.

Clearly, the need to communicate accurate information I certainly support. I was aware of that label change. From a scientific standpoint, I do not see that Accutane causes depression or causes suicide. The issue is should a physician be aware of mood changes in their patients? Should a physician be aware of suicidal ideation?

Part of the project I am involved in, National Depression Screening Day, and to answer Mrs. Morella, we have a primary care outreach, and part of what we do is we educate physicians about what the signs and symptoms of depression are and how to ask about suicide.

So I think it is important. Should it be specific for Accutane, I think it should be for all physicians, including dermatologists.

Mr. BURTON. You are not aware? That was my question, you were not aware that the FDA wrote a letter to—or contacted Roche saying that they were giving questionable information?

Dr. JACOBS. No, and maybe it is important to clear up. My relationship to Roche, I have served as a consultant, specifically from a scientific standpoint looking at the data in the spontaneous reports; and that's the nature of my consultation.

Mr. BURTON. What drugs are you aware of that can cause depression and suicide?

Dr. JACOBS. Well, that's also a very interesting question. In my opinion, there is no one drug out there that causes depression or suicide.

In the PDR, and I have researched this, there are about 100 drugs listed that, "cause depression." However, that is not a—because it is in the PDR, that is not a scientific study. What this is is these are drugs that cause depressive symptoms. I think it is important—

Mr. BURTON. OK.

Dr. JACOBS. The issue of beta blockers, which many people are familiar with, cause lethargy, lack of energy, and physicians are aware it, "can cause depression," but it is not depression per se; it is depressive symptoms. And none of those drugs are associated with suicide.

If you are asking about drug-induced, quote, depression, it is symptoms of depression that don't satisfy the criteria that I indicated earlier, but there is no study that shows that that type of, "depression is associated with suicide."

Mr. BURTON. Well, you are a consultant to Roche. Are you still a consultant with Roche?

Dr. JACOBS. Yes, I am.

Mr. BURTON. OK. Have you done similar reviews of suicide and possible drug causal link for any of these drugs you are talking about?

Dr. JACOBS. In terms of looking at—I have looked at some of the issues of fluoxetine, or Prozac. In the context of my consultation with Roche, I reviewed the entire literature on drug-induced depression, and I mentioned about beta blockers. I didn't do the research.

Mr. BURTON. But you found no causal link?

Dr. JACOBS. I found no causal link.

Mr. BURTON. OK. That answers my question.

Dr. JACOBS. OK.

Mr. BURTON. Mr. Waxman.

Mr. WAXMAN. Thank you very much, Mr. Chairman.

Let me start off with you, Dr. Pariser. I have heard estimates that as many as 80 percent of patients for whom Accutane is prescribed have only moderate or mild acne, not the severe cystic acne for which Accutane is approved. This is undoubtedly why Accutane had over \$485 million in sales in the United States last year. This overprescribing exposes significantly more people to the very serious and, as we have discussed, unknown risks of Accutane. How much does the Academy believe that Accutane is overprescribed, and what is your position on what should be done to limit it?

Dr. PARISER. Thanks for the question.

Well, I don't know that we have any systematic information on exactly how much acne may be prescribed, technically speaking, off label.

Mr. WAXMAN. Accutane?

Dr. PARISER. I am sorry. How much Accutane is prescribed for acne which is not in nodular, cystic, recalcitrant and unresponsive to other therapies.

I think that it is a clinical dilemma that many of us who treat acne all the time face. I will commonly see a patient who has acne which may be recalcitrant, which may be nonresponsive to other therapies, but which may not be cystic acne; and yes, I have prescribed Accutane in those situations. There are no statistics that I am aware of.

Mr. WAXMAN. Do you believe that there is an overprescribing of Accutane?

Dr. PARISER. Well, I would have to know what the numbers were first. Accutane is prescribed for many off-label indications.

Mr. WAXMAN. Off-label means not for—

Dr. PARISER. For acne which is recalcitrant, which is nonresponsive.

Mr. WAXMAN. There could be dermatologists who are prescribing it for acne cases for which the FDA never envisioned this particular drug to be prescribed?

Dr. PARISER. I think that is a correct statement, but it is in the context of many drugs that we prescribe in ways that are not directly labeled.

Mr. WAXMAN. What is the Academy doing to ensure that members are better informed about these risks?

Dr. PARISER. Well, every year at our annual meeting, which is attended by, last year, over 90 percent of our membership, we have seminars on acne among many other factors; we have various continuing medical education efforts that are going on, and those are the major efforts of education that the Academy sponsors. There are other venues from which our members get information.

Mr. WAXMAN. Our earlier witness, Amanda and her mother, testified that their dermatologist and other treating physicians did not know about the possible relationship between Accutane and depression. How do you explain the ignorance of her dermatologist and other psychiatrists and treating physicians about the relationship? Are they not informed by the Academy? Are they not informed by FDA? Are they not informed by Roche?

Dr. PARISER. Well, I think all of the above would be applicable. I am personally heart-saddened by the fact that many of my colleagues seem to be less informed on this than they should be, and I have no defense for that. I think it is something which we all have to work harder to do. Education has got to happen.

Mr. WAXMAN. Dr. Jacobs, I want to begin by asking a few questions about your background.

Have you served as an expert witness or been deposed on behalf of defendants in cases involving patient suicides?

Dr. JACOBS. Yes, I have.

Mr. WAXMAN. And have the defendants been practicing drug companies or drug companies like Roche?

Dr. JACOBS. The defendants have primarily been physicians or health care providers. There have been very few cases in which I have actually testified on behalf of pharmaceutical companies in a medical legal matter.

Mr. WAXMAN. How many cases have you been involved with, and what percentage of your income comes from these cases?

Dr. JACOBS. Well, I have been doing this work since about 1980, and I have been involved in approximately 300 medical legal mat-

ters, and in terms of my income, approximately 70 percent of my income comes from my consultation in medical legal matters.

Mr. WAXMAN. You represented Roche before the FDA when the agency decided in 1998 to strengthen the warning on psychiatric disorders; isn't that correct?

Dr. JACOBS. I was asked to serve as a consultant. I don't know if I would officially say I represented Roche. I was a consultant for them certainly.

Mr. WAXMAN. For Roche, and then you testified—

Dr. JACOBS. At the FDA hearing; that is correct.

Mr. WAXMAN. Do you think the FDA was wrong to strengthen their warning and do you think the French and the British Governments were also wrong to have similar warnings on Accutane?

Dr. JACOBS. I certainly don't think they were wrong. From the data I saw, if I were asked is that accurate, is that an accurate statement that Accutane—and I think the label reads Accutane, and I don't know whether it is "may cause" or Accutane "causes depression, psychosis, and in rare cases suicide attempts and suicide." As a scientist, I did not see that. From a public health standpoint to alert patients that—to alert families and physicians that the Accutane-treated population are at risk just as other populations are at risk for depression and suicide, as a physician dedicated to informing the public about suicide, you know, I don't think that is wrong at all.

Mr. WAXMAN. Just on this one point, I know my time has expired, but FDA requires Roche to add the following new boldface warning to Accutane's package insert—FDA is still unaware of the new French warning—"Warning: Psychiatric disorders; Accutane may cause depression, psychosis and, rarely, suicidal ideations, suicide attempts, and suicide. Discontinuation of Accutane therapy may be insufficient. Further evaluation may be necessary. No mechanism of action has been established for these events."

Then there is "Adverse Reactions. In the postmarketing period, a number of patients treated with Accutane have reported depression, psychosis and, rarely, suicidal ideations, suicide attempts, and suicide. Of the patients reporting depression, some reported that the depression subsided with discontinuation of therapy and recurred with reinstitution of therapy."

My question to you, with that warning label, were you testifying in support of that warning label or were you testifying in opposition? And if you were asked your opinion, would you have urged FDA to have that warning label?

Dr. JACOBS. I wasn't testifying for or against labels. That is not my area. I was asked to testify on my scientific analysis of the spontaneous reports. It is up to the FDA to make their conclusions based upon my testimony.

As I indicated before, because there is not a scientific rationale for that label, I am certainly not in opposition to that label. It is certainly conservative. There are certainly some patients, as we have heard today, who have had unfortunate experiences while on Accutane. And to the degree that physician awareness and family awareness that depression can occur in young people, that suicide can occur, and if this is a way to alert people, I am all for it.

Mr. WAXMAN. Thank you. Was Roche advocating this, or was Roche urging, to your knowledge, that they not go with this label?

Dr. JACOBS. I was unaware—that is not the level that I get involved in. I know that there were discussions after my presentation between Roche and the FDA, and then I heard—I only heard the outcome. I wasn't involved in the process.

Mr. WAXMAN. Thank you. I will wait for another round.

Mr. BURTON. Mrs. Morella.

Mrs. MORELLA. Thank you, Mr. Chairman. I will try to ask each of you quickly a question so I can get to all of you.

First of all, Dr. Pariser, you mentioned that it is not prescribed casually, and I am wondering—and yet it seems as though there is no system in place to educate parents and families.

With your extensive experience in dermatology, do you feel that physicians prescribing Accutane are doing enough to educate parents and families of the possible dangers of the drug?

Dr. PARISER. Well, there are many venues and many modalities of education. There is pamphlets, there is consent forms, there is education.

Mrs. MORELLA. Is there something that you feel is particularly good?

Dr. PARISER. But the main responsibility and the main place to educate is when the physician and the patient are together in the treatment room, with all other outside influences outside the closed door. I think it is the physician's responsibility to do that. If the physician chooses to use some of these educational aids to help that, I think that is fine, but it is the responsibility of the physician to do that. I spend more time in my practice talking to somebody about Accutane than I do—it takes me longer to do that than to take off a skin cancer or to do many other procedural services.

Mrs. MORELLA. So what you are saying is it should be done, it is the responsibility of the physician, but you don't have any guarantee it is being done.

Dr. PARISER. That is correct.

Mrs. MORELLA. Exactly. You also talk about the fact that you would see the symptoms develop—or actually, let me put it this way. Accutane is prescribed for like a 5-month period and then maybe it is prescribed again, and yet hearing from our previous panel, they seem to see adverse symptoms almost immediately and certainly within a couple of months, but they even said during the first week. So is there a disconnect there?

Dr. PARISER. The clinical studies that were done of Accutane that derived the data on its efficacy were done with defined courses of 16—usually 16 to 20 weeks of treatment as a defined period of time usually once, and sometimes that 16- to 20-week period can be repeated again later if adequate treatment did not occur prior to that, but usually, not more than that. I don't think Accutane should be or is casually prescribed in the situation of take a little bit now and a little bit later. I think that is a misuse of the drug.

Mrs. MORELLA. Except it gets to what I am pointing out that we heard from previous testimony, that that is a very long period of time for a course of action, because we can detect adverse consequences sooner than that.

But let me go on then to Dr. Bull. Picking up on what Mr. Pariser has said in his testimony, he discusses the difficulties of the creation of a registry, a mandatory registry for Accutane and uses Thalidomide as an example and says that there will be a lot more that would be required.

Is FDA considering a registry of that nature, and do you see some similar problems besetting the Thalidomide registry?

Dr. BULL. I would add that the Thalidomide experience with the registry certainly informs how the registry is approached. There is also another drug, RU-486, that does have a patient registry in place.

With regard to Accutane—and I think actions that ensure the safe use of the drug, particularly for a potent drug with the risk profile that Accutane has, I think really compels that we investigate other options in terms of the sufficiency of our current risk management structure, and we are working with the manufacturer in terms of instituting the registry. So that will—

Mrs. MORELLA. Is there a time line that you could offer at this time?

Dr. BULL. We hear from the sponsor at this point in time as early as next summer, the summer of 2001.

I would like to add as well with regard to the MedGuide and the enhanced informed consent, we expect to have those out by the first of the year, sometime in January 2001. So Roche has gotten in a draft to the agency, we have responded, and we are optimistic that it is in its final stages to be distributed and available to patients.

Mrs. MORELLA. I feel that the chairman would probably want to have the committee notified of what is happening in that regard.

Then finally, for Dr. Jacobs and Dr. O'Donnell, just briefly, if you think the dangers of Accutane were made clear to patients and their families, do you think there is a connection that that would lessen the chances of depression and suicide? Has there been any evidence to show that patients who knew about the dangers of the drug were less likely to experience depression or attempt suicide?

Dr. JACOBS. I am not aware of any—

Mrs. MORELLA. I know this is a difficult thing to say, cause and effect, at this point.

Dr. JACOBS. I am not aware of any studies that has looked at that. Certainly, making families aware of signs of depression, signs of suicide, as I indicated before, would not only be helpful in the Accutane-treated population, but in all families in suicide, that the suicide rate unfortunately has remained about the same. Most people are not aware that depression can occur in young people, about 6 percent, that suicides do occur, and what the warning signs are. So education clearly would be helpful.

Mrs. MORELLA. My time has elapsed. Thank you, Mr. Chairman.

Mrs. MORELLA. Sorry. I didn't give you a chance to answer, Dr. O'Donnell. Thank you.

Mr. BURTON. Go ahead.

Mr. O'DONNELL. I think your first question was if you tell them about it, would it decrease the occurrence? It is not going to decrease it. But as you heard from Amanda, that had they known, they would have recognized the association and stopped it. And

that is a basic premise in any drug treatment. That is why it is important to put warnings and package inserts in so that if it occurs, the doctor can look and say oh, yes, this is associated. If not, they are not going to make the connection.

I do believe that for the patient who goes and demands to their mother or father to go to the dermatologist and demand Accutane because they have one pimple, that if they learn about the risks, they are going to realize that maybe we shouldn't take this risk. For those who need it because it is severe acne or it is maybe not so severe, but it is disturbing to them, they recognize the risk and they can avoid tragedy by educating their child. And I have heard, I have heard—and I agree, this is not clinical depression according to DSM4. Maybe it is Accutane depression. We have Accutane, we have an Accutane-induced birth defect which has its own diagnosis. Children say—they don't say I am depressed, they say I feel weird, or they just spend more time in their room. And having raised teenagers, you don't always know what they are thinking. But if you know that they are put at risk or they may be at risk, and since we hear from the psychiatrists they are at risk already because they are in that age group, do we want to give them another possible risk factor without doing whatever we can to recognize it and avoid the tragedy?

Mrs. MORELLA. It seems that we are looking for a balancing act too, the fact that maybe a physician should not prescribe it if someone comes in and says I want it, even though you are saying it is not prescribed casually. Maybe we also need a registry and maybe we want to make sure that the physicians educate the parents and the families.

Thank you, Mr. Chairman.

Mr. BURTON. Mr. Horn.

Mr. HORN. Thank you, Mr. Chairman. I am curious; what are the major magazines, professional magazines that dermatologists generally receive and that you receive? Would you say it is 5 or 10 or 20?

Dr. PARISER. A smaller number specifically related to dermatology. The Academy publishes a journal, the Journal of the American Academy of Dermatology, which is the premier educational journal for dermatologists. The Journal routinely carries articles about acne, about Accutane; the guidelines of care, for example, is published in that journal.

The other major clinical journal is the Archives of Dermatology which is an AMA publication, one of the AMA specialty journals that is read by most dermatologists, and there are probably 2 or 3 others that most dermatologists would be familiar with in some way, shape or form. It is not 10, but probably 5.

Mr. HORN. Dr. Jacobs, do you agree with that, or are there other magazines that would be professionally used by the typical dermatologist?

Dr. JACOBS. Well, I would really have to defer to Dr. Pariser on that. I mean in terms of psychiatry, generally psychiatrists read the professional journals of their particular specialty. But now with the information explosion on the Internet, certainly reviews are accessible to physicians, which actually make the reading of whole

journals probably less, but particular information is more available to physicians today.

Mr. HORN. Dr. O'Donnell, would you agree with your two colleagues on that?

Mr. O'DONNELL. Yes, I would. Yes, I could.

Mr. HORN. Dr. Bull, do you generally read the kinds of journals the professors have noted?

Dr. BULL. I would—Dr. O'Connell, who is with me today, would you agree with that? The publications that dermatologists generally read, the archives.

Mr. HORN. Well, I am interested in what is the major professional journals for a dermatologist, especially board certified dermatologists.

Dr. BULL. Yes, those are the major ones.

Mr. HORN. The reason I ask that is, aren't there a number of pharmaceutical ads that you find in most of these magazines? I mean the pharmaceutical companies do advertise in magazines, don't they?

Dr. PARISER. Yes, they do.

Mr. HORN. And these are professional magazines and they advertise in them; is that correct?

Dr. PARISER. Absolutely.

Dr. JACOBS. Yes.

Mr. HORN. I am just a country boy that wants to sort of figure out how it works. Have you ever seen a pharmaceutical ad that says we have a problem regarding clinical depression, suicide, whatever, and maybe you should be careful about this ad? Have you ever seen one of those ads?

Dr. JACOBS. I am not an expert on advertising, and I generally don't read the ads, but what I do know is that generally when a pharmaceutical product is advertised, that the whole package insert is there with both the risks and benefits of the medication. I am not saying that I read that, but it is there.

Mr. HORN. Well, that is part of the problem; people are busy and they have offices filled with people that they are trying to treat, and generally they treat very well. But I am just curious when a pharmaceutical company or the Academy puts an ad in or at least a warning on one of the professional journal pages, so they could say now you really should be very careful in prescribing this.

Dr. PARISER. Well, in the case—it is my understanding that all advertising of any—whether it is in a journal or whatever venue that any pharmaceutical company undergoes, is reviewed by FDA, I thought. I know in the case of the Journal of the American Academy of Dermatology, our premier journal, that there is medical oversight for all of the advertising and nonscientific pages that are in there such that there is nothing—nothing off the wall gets through.

Mr. HORN. Well, I guess my impression, and I have looked over the years at maybe 130 medical journals that were in the university library, and they sort of are usually pretty glowing with flowers in the ads and all the rest of it. And I just wondered, where does reality come from if it doesn't come from the profession?

Dr. JACOBS. Well, the issue of where reality comes from, it is a serious matter; and when I say I don't read those ads, it is because

I am aware of the medication indications. It is no different what is in there than what is in the PDR or what is available. The prescribing of medication is a very serious matter, whether it is Accutane or any other medication, and that has to be addressed between the physician and the patient and sometimes, if it is a minor, the family. And the reality has to come from the physician. I think medical journals have a responsibility to provide information. The issue of economic support, that is a reality, but the reality of medicine is that it is a practice, and it is something that has to be taken seriously between the physician and the patient.

Mr. HORN. How many MDs are board certified for dermatology?

Dr. JACOBS. I would have to defer to Dr. Pariser.

Dr. PARISER. There are approximately 8,000 to 9,000 in the United States. I think that is a close guess.

Mr. HORN. That is the board certified?

Dr. PARISER. Ninety-seven percent or so of those are members of the American Academy of Dermatology.

Mr. HORN. So how many thousand are not certified?

Dr. PARISER. Few.

Mr. HORN. Because the problems come, if they don't go to put in their standing hours or something in order for licensure, why, they are not going to hear it very much. And often they pick nice places to go, and I understand that; most professions do that, and it is a good way to get people in the door. But I just wondered to what extent, or is there a vigorous effort made by the professional leadership when there is a drug of one sort or the other or a practice of one sort or the other? It seems to me that would be one of the main channels, eyeball to eyeball, or send them an e-mail or whatever it is.

Dr. PARISER. Well, at the last annual meeting at the American Academy of Dermatology we had 17,500 registrants. There were seminars and symposium on acne as well as on dozens of other topics.

Mr. HORN. Do you think it made an effect?

Dr. PARISER. I think every little incremental change helps some. I don't know that there is a way that we measure the details of that particular kind of educational effort, but certainly a lot of effort goes into it.

Mr. HORN. I am going to have to leave, so may I just ask one more question?

Mr. BURTON. Sure, sure.

Mr. HORN. Have there ever been major studies of just plain old vitamin A versus Accutane? What is the effect, if any? Does vitamin A have suicidal tendencies, or what?

Dr. JACOBS. I am not aware of any such study. The only—what I am aware of about vitamin A, and that is mostly from reviewing the literature, is that it can cause symptoms that we see in depression, such as irritability, anorexia, loss of energy; it does not, from my understanding, cause clinical depression, and in that sense I have not seen it in any association with suicide.

Mr. HORN. Don't you think it would be worthwhile—

Mr. BURTON. Why don't you let Mr. O'Donnell answer that? I think he has information on that too.

Mr. O'DONNELL. Well, there have been no studies, because old drugs are not studied to determine what people already believe about them. And the reports that are in the literature that Dr. Jacobs referred to and I referred to earlier describe patients who are psychotic, who have schizophrenic-like symptoms, and suicides have been associated with vitamin A toxicity.

The condition of vitamin A toxicity causes a change in the brain chemistry. The condition that brings vitamin A toxic patients to the hospital is a swelling in the brain. When we talk about mental health, we have to convert that to chemical actions in the brain. So there is a damaging chemical action in the brain that has been known, and I don't know that anybody has done large-scale studies in rats, but we certainly wouldn't do that purposely in patients. I hope that answers your question.

Mr. HORN. No, it is very helpful, and I assume that some of the pharmacists have to write a dissertation or a thesis of some sort, and I would think that that is something they ought to really go after.

Mr. O'DONNELL. Of the vitamins, the first thing in pharmacy or pharmacology 101, is that fat-soluble vitamins are toxic, can be toxic, and vitamin A and vitamin D are major fat-soluble vitamins, and we constantly, and especially with people using—vitaminizing themselves and herbalizing themselves, we see more and more toxicity from these products that they can go and buy; and of the vitamins, that is where we have the major toxicity.

Mr. BURTON. Thank you, Steve.

Let me ask Dr. Pariser, does Roche Laboratories pay for any of your Academy's annual conference? Do they pay any of the fees for that?

Dr. PARISER. Roche, as well as many other pharmaceutical companies, give unrestricted grants to the Academy of Dermatology for various educational and other efforts. But they do not sponsor specific Academy—

Mr. BURTON. No, but I mean their money is being used to help pay for some of these events.

Dr. PARISER. That is correct.

Mr. BURTON. You know, I have been to conferences all of my life, and when you have a large number of people like 17,000, 18,000, 19,000 people and you have different meetings to inform those people, usually a very small number go to any one meeting because there are so many other things going on at the same time, including extracurricular activities such as golf and tennis and other things like that. You know what I am talking about.

Dr. PARISER. Yes, sir, I—

Mr. BURTON. I am sure you do, but let me just go on. There is no way at a conference like that that you could disseminate the kind of information on a wide-scale basis that everybody would be able to understand and digest.

One of the things that troubles me about this hearing today is we have people whose children committed suicide or were adversely affected by Accutane, and they had no knowledge whatsoever from their dermatologist or their pharmacist about this. And, in fact, the dermatologists didn't know anything about it, even though it had already been publicized. The pharmacists knew nothing about it,

even though it had been publicized. So your conference has not really gotten the job done as far as informing dermatologists across the country about the possible dangers psychologically, or suicide, of Accutane.

What I don't understand is if you are a member of an organization like that, why can't you just send out a fax to everybody in big bold black letters saying, Accutane can cause severe depression and possibly suicide, as has been said in current warning labels in France and other parts of the world? Why don't you do that?

Dr. PARISER. Well, perhaps if our membership hasn't availed itself of the other means of education, perhaps they wouldn't read that either; I mean, you could argue that. I agree with you that it is an annual meeting where there are many things going on. It may not be the best way to reach the masses.

Mr. BURTON. Let me ask you this. Do you think it would offend LaRoche Laboratories if you sent a fax out to every single one of your dermatologists around the country informing them of the possible dangers? Do you think it might offend them?

Dr. PARISER. I don't think it would.

Mr. BURTON. You don't? You don't think it would endanger the money that you get for these conferences?

Dr. PARISER. I don't think it would endanger the money, and even if it did, that would not be the mission of our Academy, to yield to those kinds of economic pressures.

Mr. BURTON. Why don't you just go ahead and send a fax out to all of the dermatologists in the country saying, this is a risk and many dermatologists evidently don't know about it; there was testimony before the Congress of the United States by people who had lost children, they knew nothing about it, even though it had been publicized on the Internet, and so we want to make sure you know about it. Why don't you do that?

Dr. PARISER. I will check into that.

Mr. BURTON. Would you do that? If you don't, do me a favor. Give me a list of all of your members and I will send the daggonne thing out, OK?

Dr. PARISER. We can do that.

Mr. BURTON. Because I don't want other people coming before our committee with their kids being dead because possibly Accutane caused it.

Now, let me ask you a question, Dr. O'Donnell. You said that the people who ate polar bear livers in the middle 1880's that were on polar expeditions had psychotic events because of the large amounts of vitamin A they were consuming in the livers of polar bears; is that correct?

Mr. O'DONNELL. Yes, sir.

Mr. BURTON. Was this just an isolated incident or was this something that happened more than once?

Mr. O'DONNELL. There were several reports, not many were published, but it was common knowledge that people had to avoid excessive use. But similar reports through—since then have published neurotoxicity, toxic psychosis. But the first report I referred to was a polar expedition in 1856.

Mr. BURTON. So vitamin A in large quantities definitely causes the kinds of problems you are talking about, and that is what Accutane, in main part, is made up of?

Mr. O'DONNELL. Yes, sir.

Mr. BURTON. You know, Dr. Bull, one of the things that I don't understand is—and I won't be able to ask Dr. Huene about this, I guess—but I would like to know just a little bit about how Accutane was approved and what kind of testing took place at the FDA before it was approved. I understand that this was approved before advisory committees were being utilized, so Dr. Huene and others evidently did some of the research on that before it was made—put into the public domain.

Can you tell me what kind of testing was done; and if not, can Dr. Huene give us that information?

Dr. BULL. Well, I can get it started and certainly if Dr. Huene wants to add to my statement, that would be certainly suitable.

FDA does not conduct research. We review research conducted by the manufacturer, so all of the research that we reviewed was done by Roche Pharmaceuticals.

Mr. BURTON. Let me interrupt you. When you review, when your advisory committees today—or whatever it was back in those days—reviews it, they review the scientific data in detail before they give an advisory opinion to the head of the FDA so that it can be approved?

Dr. BULL. The process begins with review of the protocol for the study, and once the studies are completed, review of the actual data, how well the study adhered to the standards that were set out for powering the study, the number of patients enrolled in the study, the parameters that were to be assessed to determine efficacy, what parameters were studied to assess the safety of the drug, and how well it meets the mark for what it has to have as its proposed indication.

Mr. BURTON. I have to yield to my colleague, but let me just cut through this and say what I want to find out is how extensive was the research, and was it thoroughly examined before they put this on the market? Did they have any kind of information about adverse impacts, about depression, about possible suicide? Was any of that looked into before they put this on the market?

Dr. BULL. The typical way that safety is assessed is based on what is reported. There are adverse events that are anticipated that studies I think probably bring a higher level of precision in terms of soliciting comments and direct information from investigators. Then there are others that are—could be considered at the discretion, and going back almost over 20 years ago when these studies were conducted may not have had quite as high a level of stringency applied to them in terms of reporting all things, because there is so much about a new drug that you don't know. So in a sense, every event that a patient may experience is sort of in play.

Mr. BURTON. Well, I have more questions on this. I will yield to Mr. Waxman right now, but I want to get back to that.

Dr. BULL. Certainly.

Mr. WAXMAN. Thank you very much, Mr. Chairman.

This drug was approved in 1982. This is now the year 2000, and we have heard more and more about the possible link between

Accutane and depression and suicide and suicide ideations and all of that.

In September of this year, there was an advisory committee meeting, and the FDA found out that as of May 2000, 37 suicides were associated with Accutane. Is that still the number of suicides associated with Accutane?

Dr. BULL. Thirty-seven?

Mr. WAXMAN. Yes.

Dr. BULL. In that ballpark. The numbers in terms of ones that have been assessed for not having duplicate reports in the data base is in that ballpark. I have to admit the latest number I have seen is 41, so there may have been some additions to the data base since September.

Mr. WAXMAN. So there have been more reports of suicide since September?

Dr. BULL. Yes. And certainly the publicity attendant to Representative Stupak's Web site and the reports on that have certainly stimulated more reports.

Mr. WAXMAN. FDA has always stated that Medwatch captures only 1 to 10 percent of actual adverse events. Can we assume that the number of reported suicides only represent a small fraction of the actual cases?

Dr. BULL. That is certainly reasonable.

Mr. WAXMAN. In 1997, a year before FDA required Hoffman LaRoche to place a warning about suicide on its label, French authorities required Roche to add a warning to Accutane about its risk of suicide. Roche did not inform the FDA of this warning change, and it was not until FDA required Roche to warn of suicide that FDA learned of the French regulatory action. Is that correct?

Dr. BULL. Yes, sir.

Mr. WAXMAN. Was Roche under any legal obligation to tell you of the French regulatory action, and wouldn't this information have been helpful to you in requiring new warnings for Accutane?

Dr. BULL. I will answer your second question first, which certainly it would have been helpful to have known. Your first question in terms of whether or not there was a legal responsibility, we have researched that, it was certainly addressed once we learned of the French labeling change, and our regulations are unclear as to whether or not labeling changes must be submitted. The action the agency is taking to address this is that we have a proposed rule that will address these kinds of gaps, because certainly that information is quite important.

Mr. WAXMAN. So for the future you will require this information from the pharmaceutical manufacturers?

Dr. BULL. Yes, sir.

Mr. WAXMAN. You had clear statutory authority for MedGuide in 1997 and 1998 when you were considering changes to Accutane labeling. Why didn't FDA require issuing a MedGuide with Accutane at that point, warning of birth defects, suicide and psychiatric disorders?

Dr. BULL. I think part of the decisionmaking at that point had to do with looking at MedGuide as a forward-looking tool, and I think initially was anticipated to be put in place for new drugs. Certainly, I think by all criteria Accutane, in terms of serious and

significant adverse events, fits the criteria, and it will certainly be one—it will be a drug that will have a MedGuide attached to it. I think in terms of why it wasn't considered in 1997, 1998, in terms of what our strategies were for implementing the rule, it was considered—I think certainly the continuing reports have compelled us to say it makes sense to have a MedGuide attached to this drug.

Mr. WAXMAN. Just for people who may be watching on television on C-SPAN, what is a MedGuide?

Dr. BULL. A Medication Guide is, I like to think of it as a plain-language tool to convey serious and significant adverse events to patients. What is special and unique about a MedGuide is that it is required to be given to the patient at the time of dispensing at the pharmacy.

Mr. WAXMAN. Now, a MedGuide is different than information to the dermatologist or the professional, isn't it?

Dr. BULL. Yes, sir.

Mr. WAXMAN. And when did information go to dermatologists first under direction of FDA about the possible association with Accutane and depression and suicides?

Dr. BULL. To dermatologists?

Mr. WAXMAN. Yes.

Dr. BULL. In February 1998 was a time that letters were sent out to the Academy of Dermatology members, the family practitioners, and psychiatrists.

Mr. WAXMAN. Has the clinical data about Accutane and psychiatric disorders changed since 1998, and do Roche and FDA know significantly more about the risks of suicide?

Dr. BULL. I think more work has been done; I think we still, in terms of data that is conclusive, we don't know—we don't have conclusive findings. There has certainly been some fairly large epidemiologic studies that have been undertaken; one was published in the Archives of Dermatology in October of this year, and I think certainly there is a need for more work, but the data remains inconclusive. Do we really know more? I think, unfortunately, no.

Mr. WAXMAN. I guess the question I would have to ask you is, if we don't know very much more about this whole problem of association with Accutane and depression and suicide than we did in 1998, why shouldn't the new box label warning, new informed consent form and new MedGuide have been made 2 years ago?

Dr. BULL. Because we don't—in terms of tools, and I think—one thing that FDA is learning is that our traditional tools for constraining safety information do not work as effectively as we would like to see them work. I think as we are learning more, with the overall changing paradigm of health care, given that we are realizing as well that the physician is the intermediary to the patient for information, that that linkage is not working as effectively as it used to. We really are having to look much more critically at what other mechanisms we can engage to make sure that consumers are fully informed about the adverse events of drugs. So this is part of an evolving picture for us and something that we are actively engaged in refining and enhancing our abilities to meet this need.

Mr. WAXMAN. Thank you very much.

Thank you, Mr. Chairman.

Mr. BURTON. We will let you ask more questions if you choose.

One of the things that bothers me is the question that was just asked by Mr. Waxman. You kind of just—we are not geared up to really get that kind of information out to the American people. That is kind of a copout I think, isn't it? I mean, the Food and Drug Administration is supposed to be the person, or the group that guarantees the safety and the efficacy of pharmaceuticals and drugs for the people of this country, and if something is going awry, you are saying oh, it takes so much time to get the information out. I mean 19,000 dermatologists, you can send letters out tomorrow to all of them in big bold print, to all the pharmacists in the country, you know, put it on e-mail, there is all kinds of ways to communicate in this age. I think it is a real copout for the FDA to say oh, we can't do that.

The other thing I wanted to ask you is this: In 1850-something, polar bear livers were causing psychiatric problems on people that were eating them because of large amounts of vitamin A. This pharmaceutical expert or pharmacologist—

Mr. O'DONNELL. Both.

Mr. BURTON. Both. Indicated that the brain swells up when you have too much vitamin A in it, which causes severe problems. When the testing was done back in the 1980's before you put Accutane on the market, did anybody check mice brains? Did they give them large amounts, or any kinds of animals, large amounts of vitamin A to check to see if it caused any side effects? Did anybody check that out?

Dr. BULL. Mr. Chairman, what I would like to do is for us to look back at the pharmtox data and get back to you on that.

Mr. BURTON. You came today not prepared, able to answer this question?

Dr. BULL. In terms of the specificity of your question regarding mice brains, I am not sure—

Mr. BURTON. Well, any kind of research. Rabbits, I don't care.

Was large amounts of vitamin A ever injected into any laboratory animals in a test to see if it caused any kind of mental problems in the animal, rat or whatever?

Dr. BULL. I would have to check—I think the responsible thing on my part would be to go back and have our pharmacologic and toxicological experts look back at the original data base, and we will get back to you on that.

Mr. BURTON. Dr. Huene, do you know if any tests were done like that?

Dr. HUENE. Well, I am sure the toxicity of vitamin A has been well known for a long time. This is a derivative of vitamin A, and it is not certain that this would produce the same effects on the brain—

Mr. BURTON. Why don't you come to the microphone so we can hear you? We will try not to badger you too much. I won't cause you too much of a problem, but I think it is really important.

Dr. HUENE. I am not a toxicologist, but I am sure that there have been extensive studies done on the effect of hypervitaminosis A on animal brains.

Mr. BURTON. When you approved this, or you made your recommendation, did any of the studies talk about this at all, about the possible toxicity or mental side effects or anything else that

might occur because of this? Because we are talking about vitamin A or a derivative of vitamin A?

Dr. HUENE. Right. Well, I don't remember in detail. It was a long time ago. But I know that extensive animal toxicity studies are done prior to even initiating clinical studies in any drug that is planned to be marketed.

Mr. BURTON. Well, can you, Dr. Bull, for our record—and I would like for you to send it to my right hand here, sitting on my left, Beth—could you send me any information you have on the studies that were conducted on the Accutane product before it was approved? And also I would like to have any information you have on vitamin A, because it just seems like to me, and I don't know what my colleague here feels, but it seems like to me, if vitamin A does have these kinds of side effects when given in large amounts—and you are talking about giving children who have acne a vitamin A derivative over a long period of time—that you would think it might have some kind of side effects which should have been mentioned prior to 1997 in France and 1998 here about possible mental or worse problems from large amounts of that being ingested.

Dr. BULL. I would add that the label does address a condition known as pseudotumor cerebri, which is I think the brain swelling that you referenced that was known to—

Mr. BURTON. That may be. But when we hear people whose children have committed suicide or who have had adverse events occur because of Accutane, and they didn't even know anything about this, were never warned by their dermatologist, were never warned by their pharmacist, they had no knowledge, they went home, started giving their child the pills and those side effects occur, my gosh, what a mistake, what a tragedy.

In any event, we would like to have that information submitted for the record, and I would like to have a list, if we don't have it, of all of the dermatologists in the country. And if your Association won't contact them, then I will figure out a way to do it myself, and the committee will. I think that we ought to put on our e-mail to all pharmacists in the country the warning that Roche is now putting on their labels so that they will all be aware of it as well.

Mr. Waxman.

Mr. WAXMAN. I would like to review some chronology about this Accutane product.

In June 1985, Roche amended the Accutane package insert under adverse reactions to state, "The following CNS reactions have been reported and may bear no relationship to therapy: Seizures, emotional instability, including depression, dizziness, nervousness, drowsiness, malaise, weakness, insomnia, lethargy and paresthesia."

That was in 1985 they first mentioned that there may be an adverse reaction, including depression. Now, this was after the drug had already been approved, but it had been approved in 1982. But in May 1988, FDA required stronger warnings and physician mailings on Accutane's risk of birth defects, and FDA also required additional studies, including followup patient surveys. An advisory committee to the FDA said that they recommended FDA restrict prescribing Accutane to board certified dermatologists, but FDA wouldn't go along with that recommendation; predictably, the

American Medical Association and the industry didn't want the prescriptions limited to this board certified specialty, they wanted any doctor to be able to prescribe the drug.

Then, it is interesting that in 1997, FDA issued a warning letter to Roche for failing to submit serious adverse event reports in a timely manner, and then Roche said well, their computer systems were responsible for delays of up to 8 years in complying with the law. So you shouldn't be criticized if you are trying to get the information and Roche is not giving it to you.

Then, finally, February 25, 1998, FDA required these warning labels, in new boldface, warnings about Accutane's association with suicide and all of that. And that was at a time when FDA was still not informed that the same warning labels had already been put on the year before in France, and Roche never informed the FDA. So it seems like—and then I gather, Dr. Jacobs, you testified at the hearing when they finally—which resulted in these warning labels—but you testified giving some suggestion that maybe it was more complicated than the causation or the clear relationship; is that a fair statement?

Dr. JACOBS. Yes. And I think, because I think it is important to emphasize, because I think even, Mr. Chairman, if I may just state something—

Mr. WAXMAN. Well, let me just, because I have some things I want to pursue in the few minutes I have. But your position was that it was a lot more complicated at that time. FDA heard your testimony. Roche, I presume, did not willingly agree—do you know whether they did, Dr. Bull, to these warning labels in 1998?

Dr. BULL. When you say "willing," to make the labeling change?

Mr. WAXMAN. At the time the FDA was telling Roche you ought to put a warning label, you have to put a warning label about the association of Accutane and psychiatric problems, Roche issued a press release saying, there is no proof of causation, and that "Teenagers are at risk for depression," which would suggest that they were saying to the public, teenagers are often depressed, teenagers because of that depression may commit suicide, in effect suggesting it is not related to Accutane.

Now, FDA did its job and said well, the warning labels have to be on this product. When that warning label was put on the product, what was it put on, the patient package insert or on the box? Where would it go?

Dr. BULL. The warning label in 1998 went into the professional labeling. The existing patient label at that point already included in capital letters changes in mood.

Mr. WAXMAN. So that the clearer warning label identifying the possible association of Accutane with suicide and depression went to professionals.

Dr. BULL. Yes, sir.

Mr. WAXMAN. Isn't it fair to say, Dr. Pariser, that most of the Accutane prescribed in this country is prescribed by board certified dermatologists?

Dr. PARISER. It is my understanding it is about 85 percent.

Mr. WAXMAN. Now, don't dermatologists as professionals get the information from the FDA about warnings?

Dr. PARISER. Sure. They all would have received that letter in 1998.

Mr. WAXMAN. So they received a letter in 1998. They didn't have to wait for an ad in a dermatological publication. They got a warning right from FDA to the professionals?

Dr. PARISER. Yes, sir.

Mr. WAXMAN. Now, then the issue that has been raised by my colleagues is does the Association of Dermatologists try to continue to impress upon dermatologists that this is a real concern. I assume that dermatologists are informed in a number of ways. They get their warnings from the FDA when they prescribe this drug and when they are contemplating using the drug for their patients. They get publication information from the Association of—whatever your Association is called.

Dr. PARISER. American Academy of Dermatology.

Mr. WAXMAN. I assume they would put in its publications information about this problem?

Dr. PARISER. Yes, sir.

Mr. WAXMAN. And then there are ads, but they are the weakest link because the ads are put in by the manufacturer, but even an ad put in by the manufacturer, they have to put in all of the warnings that go into the—as required by FDA in the fine print of the ad. So the issue is, are there better ways for your Association to inform dermatologists? They get the information, they are professionals, they get it from FDA, they get it from you.

At your annual meetings do you think there ought to be a greater emphasis on trying to educate dermatologists about this problem, and aside from the annual meetings, are there other ways you might try to drive this issue home to dermatologists, at least for the simple reason that, one, they ought to be careful not to prescribe the drug, unless it is a severe case, and second, if they have a patient, they ought to be asking the patient, are you suffering from—do you see any change in your mood? Do you feel weird? Do you feel sad? Sort of to followup, to see whether that patient might be experiencing some reaction to the drug?

Dr. PARISER. Well, I agree with what you are saying. Obviously the message has to get sought. In the cases we heard testimony from today, in some cases it hasn't. I don't know what the numerator and the denominator is in this equation of how many dermatologists really do get the message and really do it correctly. All the venues that you described are ways that professionals such as dermatologists educate themselves. Pharmaceutical venue, which is perhaps not the greatest, but it happens, is education through the pharmaceutical representatives that call on physicians' offices. That is a sales situation, it is not an educational situation, but there is an opportunity there to provide some education as well.

Mr. WAXMAN. Well, it could be, or it would be Roche handing out the press release saying that there is no proof of causation that—there is no root of causation that teenagers are generally at risk of depression.

Dr. PARISER. That is true, but anything that is handed out in the physician's office has to be approved by the FDA, so if they were going to hand that out, the FDA would have had to approve it.

Mr. WAXMAN. Then the chairman raised, it seems to me, the most important point: Let the patients and their families know. We generally assume doctors know, because they are the professionals, they have gone to medical school; if they are dermatologists, they have gone through specialty training, they have had to get board certification, which means they had to show some skill and proficiency in their specialization, and we assume they keep up with the information from FDA and from the pharmaceutical companies and from your Association. But just in case, shouldn't—does anybody disagree that the patient should get this information as well?

Dr. PARISER. No, they should; and it should be the patient's choice as to whether they are going to take Accutane or not and it should be an informed choice. I personally never tell a patient you have to take Accutane. Never.

Mr. WAXMAN. Do you ever tell a patient—

Dr. PARISER. Not to take Accutane?

Mr. WAXMAN. No. Do you ever tell a patient that if you take Accutane, there is an associated risk with depression and suicide; and do you want to recognize that and balance it out with the fact that a patient may be very down on himself or herself because of the acne, but things could be worse?

Dr. PARISER. Well, in my own personal practice I always do that, and I discuss the issue of mood changes, potential suicide, as objectively as I do of getting chapped lips or elevation of triglycerides and the chance of pregnancy. Obviously there are some who do not do that, but I think it is important that it be done.

Mr. WAXMAN. I have to tell you, as a father of no longer a teenage boy, but if the doctor said to me, by the way, you have an elevated risk of chapped lips, I might not pay so much attention; but if he said elevated risk of suicide, I certainly would want to pay more attention to it. So there is a question of do the dermatologists know about it or are they telling the patients. And whether they are telling the patients or not, shouldn't the patients know directly from the company or the FDA? And I guess the FDA is working on this med alert in order to inform the patients.

Thank you, Mr. Chairman, for allowing me to proceed beyond my time.

Mr. BURTON. Let me just say, I don't want to prolong the hearing, but I would like to have as much information on the research of the vitamin A as possible, and also, I just cannot fathom how, with all of the methods of communications that are available from the FDA to the doctors and everything else, how dermatologists would not be aware of the side effects of Accutane and how that would not be conveyed to the patient and the parents of the patient, and how all of those tragedies could be avoided just through simple communication.

Let me just say, while we are talking about Accutane's connection to depression and suicide, I was disturbed to learn that both the FDA and the manufacturer feel that the pregnancy prevention program is not working at optimum. Is it true that over 1,900 women have become pregnant while on the drug and that over 1,400 have been terminated through abortion? I don't understand how that is, after 18 years, that this program hasn't been fixed so that you don't have that kind of a problem. Is that the case? There

is still a large number of women getting pregnant while on Accutane, even though—

Dr. BULL. That data was reviewed at the recent advisory committee, and the data that you reference is generally accurate, which has led to the agency's actions to institute the registry that would ensure that women have a negative pregnancy test, two, before starting the drug, and that they only get a month's supply of the drug; that to get another month's supply would have to be confirmed by a negative pregnancy test. That is going to be part of what the registry will entail, because what we have learned is that the system that was put in place in the 1980's simply is not working.

Mr. BURTON. The Surgeon General initiated a suicide prevention program last year. His call to action makes no reference under risk factors to drugs that can lead to depression and possibly suicide.

What role has the FDA played in development of this program, and have you examined having the Surgeon General do public service announcements about this as well?

Dr. BULL. I am sorry. In terms of the program, Surgeon General's program on depression?

Mr. BURTON. Yes. Have you considered talking to the Surgeon General about doing public service announcements about possible depression and possible suicide because of things like this?

Dr. BULL. I think that is a very intriguing idea. We could certainly get in touch with this office. We haven't considered it, but it certainly is a very intriguing idea.

Mr. BURTON. Well, we would like to have the information that we talked about regarding the studies and what kind of research was done.

Do any of you have any final comments you would like to make to the committee before we adjourn?

Dr. JACOBS. I guess I have one, Mr. Chairman, and that is it is a very delicate comment, and it has to do with the issue the suicides that we have heard about today, that they have been caused by Accutane. These suicides are tragic, they occurred in relationship to Accutane, and I think there are steps that are being taken to address this issue. I think suicide is, after studying it for nearly 30 years, is one of the more complicated behaviors. We only understand that it occurs; we don't have any study that shows that our treatments prevent it; that with all of the outbursts of psychopharmacology, the suicide rate has not dropped. We do not stop our efforts.

Can one thing prevent suicide? Would informing a family about the risks of Accutane? I cannot say it. However, is it useful? Obviously, the answer is yes, but I think it is important to keep in perspective that not one thing, from my professional opinion, causes suicide.

Mr. BURTON. Well, I understand your position, Doctor. You have made it very clear. But with all due respect, we have had parents here today who saw dramatic changes in their children when they started using it.

They had no reason to believe it had anything to do with Accutane, and yet that was when it started. Two of the three that testified today, two of the three families, the suicide was successful.

One, fortunately, was not. All I can say is that those parents, had they known about the possible side effects, which has not been given to the public until recently, for that information to have been given them in a timely fashion, their children would probably be alive today. At least I believe they think that.

Anything else, Henry?

Mr. WAXMAN. The only other request, Mr. Chairman, if these witnesses would be willing, some of us may want to ask them additional questions in writing and ask them to submit responses for the record in writing.

Mr. BURTON. Sure. Yes, we would request that as a committee. Thank you, Henry, for mentioning that.

We will look forward to your response from the FDA regarding those studies.

Thank you very, very much. We may have additional hearings on this. We really appreciate your cooperation today. We stand adjourned.

[Whereupon, at 4:15 p.m., the committee was adjourned.]

[Additional information submitted for the hearing record follows:]

ACCUTANE

**Statement of Rep. Bart Stupak
October 5, 2000**

I want to thank you all for coming here today. This is one press conference Laurie, Ken and I, and the other families who have joined me, wish we never had to attend. The information on my website and the press packet you have received relate to my concern about the potential risks of Accutane. I want to explain to you today the reasons for my family's concern about Accutane, manufactured by Roche Laboratories. After everyone has had an opportunity to comment, we will take questions.

To begin with, I would like to give you some background on how this all came about. My son BJ died in May of this past year. His death, like the death of any child, is a parent's greatest heartache and we were devastated. Our son BJ loved life. He was involved in sports, many school activities, Treasurer of the student body and President-elect of the student council at Menominee High School in Menominee, Michigan. BJ had many friends. He was a happy teenager who had great potential for life. He showed no signs of depression or loss of enthusiasm for life.

BJ committed suicide. As Laurie removed BJ's personal items and was in the process of disposing of the few Accutane pills that were left from his prescription, she questioned whether Accutane was related to BJ's death. Laurie went on the Internet and typed in the word Accutane. She came across the MedWatch alert that had been issued by the FDA in February of 1998, and it raised questions that require answers on the use of this prescription medication and its relation to the death of children.

The MedWatch stated that due to the adverse event reports the FDA had received on Accutane, the FDA felt there was sufficient cause to strengthen the warning on the Accutane label to include the risk of psychosis and suicidal thoughts and actions.

The FDA in February of 1998 stated in a Memorandum the adverse events that had been reported from the use of Accutane. The Memorandum showed that there were 31 cases of suicide, suicide attempt or suicide ideation that were associated with the use of Accutane. Of that number, 12 were suicides, 9 of them male, 2 female, and 1 unknown, and the median age was 17. The average onset of the event was 88 days after the patient had started on the prescribed use of Accutane. As the FDA Memorandum stated: "(f)or the majority, there was no antecedent history of depression and the patients were not noted

or known to be depressed in the time period prior to their suicide."

I also found that Roche had received a warning letter in March 1998 from the FDA because Roche was marketing the drug as a treatment for depression, under the theory that it could help people who were suffering from depression and poor self-image as a result of their acne. The FDA warning letter to Roche stated that this promotion was false and misleading, and that Accutane had never been approved for treatment of depression. In fact, quite the opposite was true, as you will read in the warning letter which is enclosed in the press packet. In pertinent part, the FDA states:

Roche, however, has not systematically studied the ability of Accutane to modify or prevent such illnesses as depression and has presented no basis for asserting that Accutane is effective in improving the psychosocial and emotional well-being of such patients. This claim is particularly troublesome in light of information recently presented in a Dear Doctor letter, that Accutane may cause depression, psychosis, and rarely, suicidal ideation, suicide attempts and suicide.

As parents, Laurie and I took the information we had found very seriously. As I said earlier, BJ had not shown signs of depression, and if we had known that this drug could cause depression, suicide ideation, or suicide, BJ would never have come into contact with Accutane. The warnings on BJ's Accutane package contained none of these risks. The only warnings contained on the package were for the side effects of : headaches, nausea, vomiting, blurred vision, changes in mood, severe stomach pain, diarrhea, rectal bleeding, persistent feeling of dryness of the eyes, and yellowing of the skin or eyes and/or dark urine. Nothing about depression, suicide ideation or suicide.

All Accutane package labeling currently state that before a woman takes Accutane she must read, understand, and sign a consent form.

As a parent, I would have wanted to know of the risk of depression, suicide ideation and suicide, before allowing my child to take this drug. As a legislator, I believe that the public has a right to know of all risks associated with prescription drugs. There needs to be a thorough study implemented to determine the connection between Accutane, depression, suicide ideation and suicide. The study should be conducted by an independent third party, not by the FDA or Roche.

I am speaking out now because of my concern raised by the information I discovered. I believe the public needs to make its own informed decision about the risks associated with Accutane.

I can say that what Laurie and I turned up on our own caused us concern that there appeared to be a link. The MedWatch in 1998 indicates that the FDA had enough concern regarding a link to advise the inclusion of an additional warning. In mid-September the FDA

provided an Advisory Panel with a figure of 37 suicides attributed to the use of Accutane since 1983. The FDA raised their figure to 44 suicides over the same period after Roche corrected the FDA's number. My staff and I have painstakingly gone through the FDA's Adverse Event Reports connected with Accutane, and we found 54 suicides since 1998, the same year the FDA issued its MedWatch. Another 30 deaths that are most probably suicides occurred between 1983-1997, a time where the record-keeping was a little less precise. A total of 84 suicides and BJ's is not part of the adverse event reports. The compilation of statistics that we put together, and an explanation of our methodology to minimize inaccuracies is in the press packet as well.

As you can tell, our numbers, the FDA's numbers, and Roche's numbers are different and vary greatly- the FDA's numbers show an average of 2 suicides a year, our numbers show that in the last two and half years, there have been almost 2 suicides a month associated with the use of Accutane. I know that none of these numbers are complete, because there was no report on BJ. In fact, the FDA has indicated that the actual number of suicides as a result of Accutane could be as much as ten times higher than the reported numbers.

I believe that the statistics I mentioned previously are alarming enough to inform the public of the risk that may be associated with the use of Accutane and the recommendations contained in the press packet you received calling for an independent study and a uniform and immediate warning and notification system. The copies of the package labeling in the press packet that were received from Roche show that they still do not uniformly warn of the risks and the adverse side effects identified as depression, suicide ideation and suicide. BJ's package labeling never included any warning as to the risk of depression, suicide ideation and suicide. There is a concern here of a potential risk to the health and safety of our children.

I have given you our recommendations and they are posted on my website. Thank you for your concern.



[Homepage](#) | [Welcome Message](#) | [About Bart](#) | [Bart's News Stand](#) | [1st District Information](#) | [Visiting the Nation's Capital](#)
[How To Get in Touch](#) | [Constituent Services](#) | [Service Academy Nominations](#) | [Michigan's Higher Education](#) | [1st District Web Links](#)

ACCUTANE

Background Information

Accutane/Roaccutane (Isotretinoin)

**Manufacturer: Hoffman-Roche, a Swiss Co.
Roche in U.S., Nutley N.J.**

Roche submitted its "new" drug application in July 1981 and the FDA approved it less than a year later on May 21, 1982.

1982-1988 - Thousands of women were warned only that the drug caused birth defects in animals, and no precautions were taken. "Between 1982-1988, more than 1000 babies were born missing ears, major organs and portions of the brain. Others were stillborn. Still others were aborted."

March 3, 1997 - France - French studies showed users of Accutane/Roaccutane suffered from severe depression and suicidal ideation. French equivalent of FDA ordered warning to consumers.

Accutane is Hoffman-Roche's second-largest-selling drug, bringing in \$800 million in sales in 1998.

[Homepage](#) | [Welcome Message](#) | [About Bart](#) | [Bart's News Stand](#) | [1st District Information](#) | [Visiting the Nation's Capital](#)
[How To Get In Touch](#) | [Constituent Services](#) | [Service Academy Nominations](#) | [Michigan's Higher Education](#) | [1st District Web Links](#)

ACCUTANE**FDA Memorandum dated 2/23/98**

Page 1

MEMORANDUM **DEPARTMENT OF HEALTH AND HUMAN SERVICES**
PUBLIC HEALTH SERVICE
FOOD AND DRUG ADMINISTRATION
CENTER FOR DRUG EVALUATION AND RESEARCH

DATE: *FEB 23 1998*

FROM: **Roger Goetsch, PharmD,**
Postmarketing Safety Evaluator, HFD-735

Amarilys Vega, MD, M.P.H.
Medical Officer, HFD-733

THROUGH: **Ralph Lillie, R.Ph., M.P.H., Acting Director** *DeGruen to R. Lillie 2/23/98*
Division of Pharmacovigilance and Epidemiology, HFD-750

SUBJECT: **Isotretinoin and Depression: Spontaneous reports data presented to the Division of Dermatologic and Dental Drug Products on 1/23/98.**

TO: **Jonathan Wilkin, MD., Director**
Division of Dermatologic and Dental Drug Products, HFD-540

This document contains the data on isotretinoin, depression and suicide presented to the Division of Dermatologic and Dental Drug Products on 1/23/98 as requested by Dr. O'Connell.

METHODS

We reviewed the Spontaneous Reporting System database (SRS) in search of isotretinoin reports in which depression, manic depression, manic reaction, depression psychotic, psychosis and suicide attempt were the reported COSTART¹ terms. Hands-on case review was limited to: (1) reports which contained data on patient's response after discontinuation of isotretinoin therapy (dechallenge) as well as their response following reintroduction of the drug (rechallenge), and (2) those in which suicide attempt or suicide were the reported Costart terms. It should be noted that suicide attempt was added to the Costart Manual in 1989. The verbatim terms that were included are shown in table 1.

¹ COSTART - Coding Symbols for Therapeutic Adverse Reaction Terms

AC CUTANE

FDA Memorandum dated 2/23/98

Page 2

Table 1. Reported terms associated with the Costart terms.

REPORTED TERM	COSTART TERM
Depression Suicidal	Depression Psychotic
Suicidal Depression	Depression Psychotic
Suicide	Suicide Attempt
Suicide Attempt	Suicide Attempt
Suicide Gesture	Suicide Attempt

SRS SEARCH RESULTS

I. Depression Reports

There were a total of 506 case reports of depression with isotretinoin. Of these, 185 contained information on the results of dechallenge from isotretinoin. Within this latter group, there were 20 reports indicating the results of rechallenge with isotretinoin. These 20 reports with both dechallenge and rechallenge data were reviewed further and summarized below.

A. Sex distribution

9 males
9 females
2 sex unspecified

B. Age distribution

Mean: 23 years (n=19)
Range: 13 to 36 years
Median: 20 (n=18)

C. Distribution of cases by indication

10 Neurocystic acne
8 Other types of acne
1 Non acne condition (not specified)
1 Hypersecretional skin

D. Distribution of cases by outcome

5 Hospitalized
15 Outcome not listed

E. Past history of psychiatric illness

12 No
5 Yes
3 Not available

ACCUTANE

FDA Memorandum dated 2/23/98

Page 3

Table 2 compares the first and the second treatment courses among the 20 patients with rechallenge to isotretinoin. Of note, the time to onset of depression in each course was about one month, and recovery (cessation of depression symptoms) was quick once isotretinoin was discontinued. Also, the duration of therapy with isotretinoin was shorter during the second course suggesting physician's lower tolerance for symptoms of depression.

Table 2
COMPARISON BETWEEN FIRST AND SECOND TREATMENT COURSES WITH ISOTRETINOIN

	FIRST COURSE	SECOND COURSE
TOTAL DOSE		
Median	50 mg	40 mg
Range	10-60	20-50
N	13	13
DURATION OF THERAPY		
Median	72 days	79 days
Range	4-153	1-125 days
N	14	11
TIME TO ONSET		
Median	31 days	30-35 days
Range	6-102 days	1-125 days
N	12	11
TIME TO RECOVER		
Median	3 days	3 days
Range	1 hour-3 days	1.5 hours-7 days
N	6	6
TOTAL RECOVERED	17 (100%)	11 (100%)

II. Suicide Reports

A total of 81 reports were retrieved for review. Of the total reports, 50 (62%) cases were excluded due to confounding factors. There is a list of the confounding cases excluded in table 3.

Table 3. Confounders

CONFOUNDER	NUMBER
Relevant psychiatric history	16
Relevant personal history	10
Occurred after Accutane therapy*	16
Days after 1-30	3
Days after 31-90	5
Days after 91+	8
Relevant overdose history	6
Unrelated to drug	2
Total	50
Possible Temporal Relationship	31
Grand Total	81

*The average number of days after Accutane therapy was 126 days (±4 months).

ACCUTANE

FDA Memorandum dated 2/23/98

Page 4

A. Overview of Suicide Reports

There were 31 cases of Accutane® therapies where suicide, suicide attempt or suicide ideation was mentioned in association with isotretinoin therapy. Following is a summary of the demographic characteristics of these patients. Table 4 describes the various categories of suicide.

Demographics (n=31):

- Sex: Male 15, Females 14, Unknown 2
- Age (yrs): Range (13-40), Median 17, Average 18
- Outcome: Fatal 12 (39%), Hospitalization 8, Life-threatening 2, None 9
- Major Event: Depression 18 (58%), No signs of Depression 9, Unknown 4
- Indication: Cystic Acne 13(42%), Other acne 18
- Dosage (mg/kg): Range (0.35 -1.6), Average 0.94, N=15
- Onset of Event (days): Range (4 - 222) , Average 81, N=30
- Time to Recover(days): Range (12 - 351), Average 71, Median 41, N=10

Table 4. Categories of suicide

Category	Number
Suicide Fatal	12
Suicide Attempt	11
Suicide Ideation	8

B. Fatal Suicide Reports

The following summarizes information from 12 reports with completed (fatal) suicide. Patients were typically young and male. For the majority, there was no antecedent history of depression and the patients were not noted or known to be depressed in the time period prior to their suicide.

Demographic for Suicide (n=12):

- Sex: Male 9 (75%), Female 2, Unknown 1
- Age (yrs): (range 14-40), Average 20, Median 17
- Onset of Event (days): Range (4 - 214), Average 88, Median 60
- Date of Suicide: 1985 (1), 1987 (2), 1988 (1), 1993 (3), 1994 (2), 1995 (1), 1996 (1), unk (1)
- Source of Report: Foreign (4), Domestic (8)
- Type of Acne: Severe or cystic (7), Acne (3), Unknown (2)
- Major Event: no depression (7) (58%), mood swings (2), unknown (3)

ACCUTANE

FDA Memorandum dated 2/23/98

Page 5

Table 5. Age and sex distribution for fatal suicide (n=12)

Age Group	Female	Male	Unknown	Total
10-19 Years	0	6	1	7
20-29 Years	1	3	0	4
30-39 Years	0	0	0	0
40-49 Years	1	0	0	1
Unknown	0	0	0	0
Total	2	9	1	12

Table 6. Sex distribution by mechanism of suicide (n=12).

Form	Female	Unknown	Male	Total
Firearms	0		5	5
Hanging	0		1	1
Drug Overdose	1		0	1
Unknown	1	1	3	5

C. Non-Fatal Suicide-Related Reports

The following summarizes information available on 19 non-fatal cases with either suicide attempt or ideation reported in association with isotretinoin use. Patients were generally below 30 years of age, and women outnumbered men 1.5:1.

Demographic for Suicide Attempt/Ideation (n=19):

- Sex: Male 7, Female 11 (58%), Unknown 1
- Age (yrs): (range 13-28), Average 17, Median 17
- Outcome: Hospitalization (3) (42%), Life-threatening (2), None (9)
- Onset of Event (days): Range (6-153), Average 77, Median 86
- Date of Suicide: 1985 (1), 1987 (2), 1988 (1), 1989 (2), 1991 (1), 1992 (3), 1993 (3), 1994 (1), 1995 (1), 1996 (3), 1997 (1)
- Time to Recover(days): Range (12-351), Average 71, Median 41
- Source of Report: Foreign (5), Domestic (14)
- Type of Acne: Severe or cystic (11), Acne (7), Unknown (1)
- Major Event: no depression (2), depressive syndrome (13) (68%), Suicidal Thoughts (3), unknown (1)

ACCUTANE

FDA Memorandum dated 2/23/98

Page 6

Table 7. Positive Dechallenge of the Suicide Attempt and Ideation (n=19)

Suicide	Positive Dechallenge	No Dechallenge	Doesn't Apply
Attempt	5	1	5
Ideation	8	0	0

Table 8. Age and Sex Distribution for Suicide Attempt/Ideation (n=19)

Age Group	Female	Male	Unknown	Total
10-19 Years	9	7	0	16
20-29 Years	1	0	0	1
30-39 Years	0	0	0	0
40-49 Years	0	0	0	0
Unknown	1	0	1	2
Total	11	7	1	19

SUMMARY

We identified 20 cases of depression with isotretinoin in which it was reported that depression resolved when isotretinoin was stopped and recurred when its use was resumed. The onset of depression occurred after a median of 31 days (range 9-100 days) following the first course and after a median of 35 days (range 1-426 days) following the second (rechallenge) course of isotretinoin. Recovery occurred within 1-8 days of stopping isotretinoin.

Of 31 suicide-related reports considered to be relatively free of confounding factors, 12 described completed suicides and 19 non-fatal reports described suicidal ideation or attempt. Completed suicides were reported primarily in males and non-fatal events mainly in females. For the majority of patients with completed suicide, symptoms of depression prior to suicide were absent, while for the majority with non-fatal suicidal events, a depressive syndrome had been noted prior to the event.

Roger Goetsch, Pharm.D.
 Roger Goetsch, Pharm.D.

Amarilis Vega, MD, M.P.H.
 Amarilis Vega, MD, M.P.H.

cc: HFD-730/ O'Neill, Lillie
 HFD-733/ Graham, Vega, Chron, DRU
 HFD-735/ Goetsch, Chen, Barash DG 2/23/98
 HFD-540/ O'Connell



MedWatch News
Menu

MEDWATCH

THE FDA MEDICAL PRODUCTS REPORTING PROGRAM

MedWatch News

IMPORTANT NEW SAFETY INFORMATION ABOUT ACCUTANE

Source: 26 February 1998 -- MedWatch Program

Food and Drug Administration

Print Media: 301-827-6242
Broadcast Media: 301-827-3434
Consumer Inquiries: 800-532-4440

MedWatch is the FDA Medical Products Reporting Program for health-care professionals. It provides a pathway through which medical personnel can report serious adverse events and product problems that occur with the use of all medical products, including drugs, biologics, medical devices, and special nutritional formulations (eg, medical foods, dietary supplements, and infant formulas). Pharmaceutical Information Associates, Ltd. and PharmInfoNet are pleased to participate as MedWatch partners.

FDA MedWatch Page

FDA HOME PAGE

FDA today is advising consumers and health care providers of new safety information regarding the prescription anti-acne drug Accutane (isotretinoin) and isolated reports of depression, psychosis and rarely suicidal thoughts and actions.

Accutane was approved in 1982 to treat only a very special type of acne -- severe nodular acne that has not responded to other therapies.

Although the Accutane label already included information regarding depression as a possible adverse reaction, the agency felt health care providers and others needed additional information as a result of adverse event reports the agency has received.

FDA and the drug manufacturer are strengthening this label warning, even though it is difficult to identify the exact cause of these problems. Such problems could already be more common among the patient populations likely to be on the drug.

However, because some patients who reported depression also reported that the depression subsided when they stopped taking the drug and came back when they resumed taking it, the agency and the manufacturer felt the strengthened labeling was warranted as a precautionary measure.


Given the complex nature of depression and suicidal conditions, the new label information will advise health care providers that merely

discontinuing the drug may be insufficient to remedy these adverse events, and that further evaluation may be needed.

In the event of Accutane-related adverse events, health care providers are urged to contact the manufacturer, Roche Laboratories at 1-800-526-6367 or FDA MedWatch at (phone) 1-800-FDA-1088, (fax) 1-800-FDA-0178 or (mail) FDA, HF-2, 5600 Fishers Lane, Rockville, MD 20852.

Consumers seeking the latest safety information about FDA-regulated medical products also can access the Medwatch internet home page at <http://www.fda.gov/medwatch/safety.htm>.

Last modified on .



[PharmInfoNet HomePage](#)



DEPARTMENT OF HEALTH & HUMAN SERVICES

Public Health Service

Food and Drug Administration
Rockville MD 20857

March 5, 1998

TRANSMITTED VIA FACSIMILE

Mr. Patrick J. Zenner
President and CEO
Hoffmann-La Roche, Inc.
340 Kingsland Street
Nutley, NJ 07110-1199

RE: **NDA 18-622**
Accutane (isotretinoin) Capsules
MACMIS ID 6254

WARNING LETTER

Dear Mr. Zenner:

This Warning letter concerns Hoffmann-La Roche, Inc.'s (Roche) advertising and promotional labeling for Accutane (isotretinoin) Capsules including, but not limited to, journal advertisements and promotional labeling pieces.¹ As part of its routine monitoring of prescription drug promotion, the Division of Drug Marketing, Advertising, and Communications' (DDMAC) has reviewed these materials and has determined that they are false or misleading and promote Accutane for an unapproved use in violation of the Federal Food, Drug, and Cosmetic Act, 21 USC §§ 355(a), 352(a), 352(f), 331(a), and 331(d), and applicable regulations. Moreover, Roche's failure to disclose important risk information in its promotional materials raises significant safety concerns.

**Promotion of Unapproved Use, False or Misleading Promotion,
and Failure to Disclose Safety Information**

Roche's promotional materials state or suggest that Accutane is safe and effective in the treatment of what Roche describes as the "psychosocial trauma" and "emotional

¹ One journal advertisement appeared in the January 1998 edition of the Journal of the American Academy of Dermatology. The promotional labeling pieces are identified as booklets 18-002-023-013-086, 18-002-023-002-036, and 18-064-023-002-037. These promotional materials are representative of the violative materials disseminated by Roche in its promotion of Accutane.

Mr. Patrick J. Zenner
Hoffmann-La Roche, Inc.
RE: NDA 18-622
Accutane (isotretinoin) Capsules

Page 2

suffering" associated with acne, including "negative psychosocial effects such as depression and poor self-image." For example:

- One recent journal ad for Accutane states, "Remission can stop the physical scarring-and emotional suffering" and "Effective treatment of severe recalcitrant nodular acne minimizes progressive physical scarring—as well as negative psychosocial effects such as **depression** and poor self-image."² (Emphasis added).
- A booklet suggests that treatment with Accutane will stop the "negative emotional and psychosocial effects include **depression** and poor self-image."³ (Emphasis added).

The statements and suggestions in Roche's promotional materials that Accutane therapy will minimize or improve the patient's psychosocial status, including depression, are false or misleading and promote an unapproved use.

We do not doubt that patients with severe nodular acne who are unresponsive to conventional therapy are greatly disturbed by their condition and may even become clinically depressed because of it. Roche, however, has not systematically studied the ability of Accutane to modify or prevent such illnesses as depression and has presented no basis for asserting that Accutane is effective in improving the psychosocial and emotional well-being of such patients. This claim is particularly troublesome in light of information recently presented in a Dear Doctor letter, that Accutane may cause depression, psychosis, and rarely, suicidal ideation, suicide attempts and suicide.

Roche's promotional claims also contradict or minimize the risk information disclosed in the approved product labeling. The "Adverse Reactions" section of the labeling prior to the recent changes, stated:

Depression has been reported in some patients on Accutane therapy. In some of these patients, this has subsided with discontinuation of therapy and recurred with reinstitution of therapy.

² Journal advertisement appeared in the January 1998 edition of the Journal of the American Academy of Dermatology.

³ Booklet no. 18-002-023-002-036.

Mr. Patrick J. Zenner
Hoffmann-La Roche, Inc.
RE: NDA 18-622
Accutane (isotretinoin) Capsules

Page 3

Thus, Roche misleadingly suggests in its promotional materials that Accutane has a positive effect on psychosocial effects, such as depression, in patients with severe recalcitrant nodular acne. At the same time, Roche fails to disclose in its promotional materials that depression may be associated with the use of Accutane.

Conclusion and Requested Actions

The materials and promotional messages Roche disseminated contain false or misleading information about the safety and effectiveness of Accutane and promote the product for an unapproved use. Accordingly, Roche should propose an action plan to disseminate corrective messages about the issues discussed in this letter to all health care providers, institutions, and organizations who received the violative messages over the last 12 months.

We ask that this corrective plan include:

- A. Immediately ceasing the dissemination of all materials and claims that state, suggest, or imply that Accutane is safe and effective for psychological or emotional suffering, including depression, in the indicated patient population and that contain false or misleading claims of the type discussed in this letter.
- B. A written statement of Roche's intent to comply with "A" above.
- C. A complete listing of all advertising and promotional labeling that will remain in use and those that will be discontinued. Also, provide two copies of all promotional materials for Accutane that Roche intends to continue to distribute.
- D. Within 15 days of the date of this letter, disseminating a message to all Roche sales representatives and marketing personnel involved in the marketing and sales of Accutane, instructing them to immediately cease dissemination of all promotional materials and messages discussed in this letter and providing each person with a copy of this letter.
- E. All new promotional materials should prominently disclose information about the psychiatric disorders described in the Warnings section of the revised labeling in addition to other risk information.

Mr. Patrick J. Zenner
Hoffmann-La Roche, Inc.
RE: NDA 18-622
Accutane (isotretinoin) Capsules

Page 4

Roche's action plan should be submitted to DDMAC for approval. After such approval, the corrective message should be disseminated as quickly as possible.

The violations discussed in this letter do not necessarily constitute an exhaustive list. We are continuing to evaluate other aspects of Roche's campaign for Accutane and we may determine that additional remedial measures will be necessary to fully correct the false or misleading messages resulting from Roche's violative conduct.

Roche's response should be received no later than March 18, 1998. If Roche has any questions or comments, please contact Jean Raymond, Dr. Tracy Acker, or Norman A. Drezin, Esq. by facsimile at (301) 594-6771, or at the Food and Drug Administration, Division of Drug Marketing, Advertising and Communications, HFD-40, Rm 17B-20, 5600 Fishers Lane, Rockville, MD 20857. DDMAC reminds Roche that only written communications are considered official.

In all future correspondence regarding this matter, please refer to MACMIS # 6254 and NDA 18-622.

Sincerely,



Minnie Baylor-Henry, R.Ph., JD
Director
Division of Drug Marketing,
Advertising and Communications

NDA 18-662/S-040
Hoffmann-La Roche Inc.
Attention: Betty Holland, M.S.
Program Director
340 Kingsland Street
Nutley, New Jersey 07110-1199

MAY 1 2000

Dear Ms. Holland:

Please refer to your supplemental new drug application dated January 17, 2000, received January 18, 2000, submitted under section 505(b) of the Federal Food, Drug, and Cosmetic Act for Accutane (isotretinoin) Capsules, 10 mg, 20 mg, and 40 mg.

We acknowledge receipt of your submissions dated January 26, February 18 and 24, and April 6 and 18, 2000.

This supplemental new drug application provides for revisions to the Accutane Pregnancy Prevention Program.

We have completed the review of this supplemental application, as amended, and have concluded that adequate information has been presented to demonstrate that the drug product is safe and effective for use as recommended in the agreed upon enclosed labeling text. Accordingly, this supplemental application is approved effective on the date of this letter.

The final printed labeling (FPL) must be identical to the enclosed labeling (text for the package insert).

Please submit 20 copies of the FPL as soon as it is available, in no case more than 30 days after it is printed to each application. Please individually mount ten of the copies on heavy-weight paper or similar material. For administrative purposes, this submission should be designated "FPL for approved supplement NDA 18-662/S-40." Approval of this submission by FDA is not required before the labeling is used.

If a letter communicating important information about this drug product (i.e., a "Dear Health Care Practitioner" letter) is issued to physicians and others responsible for patient care, we request that you submit a copy of the letter to this NDA and a copy to the following address:

MED WATCH, HF-2
FDA
5600 Fishers Lane
Rockville, MD 20857

NDA 18-662/S-040
Page 2

We remind you that you must comply with the requirements for an approved NDA set forth under 21 CFR 314.80 and 314.81.

If you have any questions, call Kevin Darryl White, Project Manager, at (301) 827-2020.

Sincerely,

Jonathan K. Wilkin, M.D.
Director
Division of Dermatologic and Dental Drug Products
Office of Drug Evaluation V
Center for Drug Evaluation and Research

ACUTANE®
(isotretinoin)
CAPSULES

Avoid Pregnancy

CONTRAINDICATIONS AND WARNINGS: Accutane must not be used by females who are pregnant or who may become pregnant while undergoing treatment. Although not every fetus exposed to Accutane has resulted in a deformed child, there is an extremely high risk that a deformed infant can result if pregnancy occurs while taking Accutane in any amount even for short periods of time. Potentially any fetus exposed during pregnancy can be affected. Presently, there are no accurate means of determining after Accutane exposure which fetus has been affected and which fetus has not been affected.

Accutane is contraindicated in females of childbearing potential unless the patient meets all of the following conditions:

- must have severe disfiguring nodular acne that is recalcitrant to standard therapies (see INDICATIONS AND USAGE for definition)
- must be reliable in understanding and carrying out instructions
- must be capable of complying with the mandatory contraceptive measures required for Accutane therapy and understand behaviors associated with an increased risk of pregnancy
- must have received both oral and written warnings of the hazards of taking Accutane during pregnancy and exposing a fetus to the drug
- must have received both oral and written information on the types of contraceptive methods and warnings about the rates of possible contraceptive failure, and of the need to use two separate, effective forms of contraception simultaneously, unless abstinence is the chosen method, or the patient has undergone a hysterectomy and has acknowledged in writing her understanding of the information and warnings and of the need for using two contraceptive methods simultaneously
- must have had a negative urine or serum pregnancy test with a sensitivity of at least 50 mIU/mL when the patient is qualified for Accutane therapy by the prescriber, and must have had a second negative urine or serum pregnancy test on the second day of the next normal menstrual period or at least 11 days after the last unprotected act of sexual intercourse, whichever is later
- must understand and agree that her prescriber will issue her a prescription for Accutane only

after she has contacted the prescriber to confirm that she has obtained a negative result for the second urine pregnancy test which is to be conducted on the second day of the next normal menstrual period or at least 11 days after the last unprotected act of sexual intercourse, whichever is later

- must have received instruction to join the Accutane Survey and have watched a videotape, provided by Roche to her prescriber, that provides information about contraceptive methods, possible reasons for contraceptive failure, and importance of using effective contraception when taking teratogenic drugs.

Major human fetal abnormalities related to Accutane administration have been documented: CNS abnormalities (including cerebral abnormalities, cerebellar malformation, hydrocephalus, microcephaly, cranial nerve deficit); skull abnormality; external ear abnormalities (including anotia, micropinna, small or absent external auditory canals); eye abnormalities (including microphthalmia); cardiovascular abnormalities; facial dysmorphism; cleft palate; thymus gland abnormality; parathyroid hormone deficiency. In some cases death has occurred with certain of the abnormalities previously noted. Cases of IQ scores less than 85 with or without obvious CNS abnormalities have also been reported. There is an increased risk of spontaneous abortion. In addition, premature births have been reported.

It is strongly recommended that a prescription for Accutane should not be issued by the prescriber until a female patient has had negative results from two urine or serum pregnancy tests, one of which is performed in the prescriber's office when the patient is qualified for Accutane therapy, the second of which is performed on the second day of the next normal menstrual period or 11 days after the last unprotected act of sexual intercourse, whichever is later. It is also recommended that pregnancy testing and counseling about contraception and behaviors associated with an increased risk of pregnancy be repeated on a monthly basis. To assure compliance, the prescriber should not issue a prescription for a female patient, until after the second negative pregnancy test result is obtained. In addition, the prescriber should prescribe no more than a 1-month supply of the drug for all Accutane patients and no automatic refills should be permitted. Roche will supply urine pregnancy test kits for female Accutane patients for the initial, second, and monthly testing during therapy.

Effective contraception must be used for at least 1 month before beginning Accutane therapy, during therapy, and for 1 month following discontinuation of therapy even where there has been a history of infertility, unless due to hysterectomy. The patient must be counseled about and understand the limitations of any chosen contraceptive method. The patient must also understand the risks associated with not using two contraceptive methods, even when one of the chosen methods is a hormonal contraceptive method.

Any birth control method can fail. Therefore, it is critically important that women of childbearing potential use two effective forms of contraception simultaneously, unless absolute abstinence is the chosen method, even when one of the forms is a hormonal contraceptive method. Although hormonal contraceptives are highly effective, there have been reports of pregnancy from women who have used oral contraceptives, as well as injectable/implantable contraceptive products. These reports are more frequent for women who use only a single method of contraception. It is not known if hormonal contraceptives differ in their effectiveness when used with Accutane.

If a pregnancy does occur during treatment, the prescriber and patient should discuss the desirability of continuing the pregnancy. Prescribers are encouraged to report all cases of pregnancy with specific information about the contraceptive forms used during Accutane therapy and for 1 month following therapy, either to the Roche Medical Services @ 1-800-526-6367 or to the Food and Drug Administration MedWatch Program @ 1-800-FDA-1088.

Accutane should be prescribed only by prescribers who have special competence in the diagnosis and

treatment of severe recalcitrant nodular acne, are experienced in the use of systemic retinoids, and understand the risk of teratogenicity if Accutane is used during pregnancy.

Prescribers who prescribe Accutane should use the Pregnancy PreventionSM Program kit provided by Roche for the counseling of patients, should instruct the patient to participate in the Accutane Survey, and should receive medical education sponsored by Roche about effective contraception, the limitations of contraceptive methods and behaviors associated with an increased risk of contraceptive failure and pregnancy.

DESCRIPTION: Isotretinoin, a retinoid, is available as Accutane in 10-mg, 20-mg and 40-mg soft gelatin capsules for oral administration. Each capsule also contains beeswax, butylated hydroxyanisole, edetate disodium, hydrogenated soybean oil flakes, hydrogenated vegetable oil, and soybean oil. Gelatin capsules contain glycerin and parabens (methyl and propyl), with the following dye systems: 10 mg — iron oxide (red) and titanium dioxide; 20 mg FD&C Red No.3, FD&C Blue No. 1, and titanium dioxide; 40 mg — FD&C Yellow No. 6, D&C Yellow No. 10, and titanium dioxide.

Chemically, isotretinoin is 13-*cis*-retinoic acid and is related to both retinoic acid and retinol (vitamin A). It is a yellow-orange to orange crystalline powder with a molecular weight of 300.44. The structural formula is:

CLINICAL PHARMACOLOGY: Isotretinoin is a retinoid, which when administered in pharmacologic dosages of 0.5 to 2.0 mg/kg/day, inhibits sebaceous gland function and keratinization. The exact mechanism of action of Accutane is unknown.

Nodular Acne. - Clinical improvement in nodular acne patients occurs in association with a reduction in sebum secretion. The decrease in sebum secretion is temporary and is related to the dose and duration of treatment with Accutane, and reflects a reduction in sebaceous gland size and an inhibition of sebaceous gland differentiation.¹

Pharmacokinetics: Absorption: Oral absorption of isotretinoin is optimal when taken with food or milk. After administration of a single 80-mg oral dose (two 40-mg capsules) of isotretinoin to 15 healthy male subjects, maximum blood concentrations ranged from 167 to 459 ng/mL (mean 256 ng/mL) and were achieved in 1 to 6 hours (mean 3.2 hours). The oral absorption of isotretinoin is consistent with first-order kinetics and can be described with a linear two-compartment model. Nodular acne does not alter the absorption of the drug: In a 27-day study of isotretinoin in 10 male patients with nodular acne treated with an oral dose of 40 mg bid, the mean peak concentration ranged from 98 ng/mL to 535 ng/mL (mean 262 ng/mL) and occurred at 2 to 4 hours after administration (mean 2.9 hours). In these patients, the mean \pm SD minimum steady-state blood concentration of isotretinoin was 160 \pm 19 ng/mL. The terminal elimination half-life was consistent with that observed in normal subjects.

Distribution: Isotretinoin is more than 99.9% bound to plasma proteins, primarily albumin.

Metabolism: After oral administration of isotretinoin, 4-oxo-isotretinoin is the major metabolite identified in the blood. Maximum concentrations of 4-oxo-isotretinoin (87 to 399 ng/mL) were achieved at 6 to 20 hours after oral administration of two 40-mg capsules; the blood concentration of the major metabolite generally exceeded that of isotretinoin after 6 hours. Isotretinoin also undergoes isomerization to the all-trans isomer,

tretinoin, which is then metabolized to its corresponding 4-oxo-metabolite; both have been detected. Both parent compound kind metabolites are further metabolized into conjugates which are excreted.

Elimination: Following administration of an 80-mg liquid suspension oral dose of ^{14}C -isotretinoin, ^{14}C -activity in blood declined with a half-life of 90 hours. The metabolites of isotretinoin and any conjugates are ultimately excreted in the feces and urine in relatively equal amounts (total of 65% to 83%). The terminal elimination half-life of isotretinoin ranges from 10 to 20 hours. The mean elimination half-life of 4-oxo-isotretinoin is 25 hours (range 17 to 50 hours). After both single and multiple doses, the accumulation ratio of 4-oxo-isotretinoin to parent compound is 3 to 3.5.

INDICATIONS AND USAGE: *Severe recalcitrant nodular acne:* Accutane is indicated for the treatment of severe recalcitrant nodular acne. Nodules are inflammatory lesions with a diameter of 5 mm or greater. The nodules may become suppurative or hemorrhagic. "Severe," by definition,² means "many" as opposed to "few or several" nodules. Because of significant adverse effects associated with its use, Accutane should be reserved for patients with severe nodular acne who are unresponsive to conventional therapy, including systemic antibiotics. In addition, for female patients of childbearing potential, Accutane is indicated only for those females who are not pregnant (see boxed CONTRAINDICATIONS AND WARNINGS).

A single course of therapy for 15 to 20 weeks has been shown to result in complete and prolonged remission of disease in many patients.^{1,3,4} If a second course of therapy is needed, it should not be initiated until at least 8 weeks after completion of the first course, because experience has shown that patients may continue to improve while off Accutane. The optimal interval before retreatment has not been defined for patients who have not completed skeletal growth (see WARNINGS: *Skeletal: Hyperostosis and Premature Epiphyseal Closure*).

CONTRAINDICATIONS: Pregnancy: Category X.
See boxed CONTRAINDICATIONS AND WARNINGS.

Allergic Reactions: Accutane is contraindicated in patients who are hypersensitive to this medication or to any of its components. Accutane should not be given to patients who are sensitive to parabens, which are used as preservatives in the gelatin capsule (see PRECAUTIONS: *Hypersensitivity*).

WARNINGS: *Psychiatric Disorders:* Accutane may cause depression, psychosis and, rarely, suicidal ideation, suicide attempts and suicide. Discontinuation of Accutane therapy may be insufficient; further evaluation may be necessary. No mechanism of action has been established for these events (see ADVERSE REACTIONS: *Psychiatric*).

Pseudotumor Cerebri: Accutane use has been associated with a number of cases of pseudotumor cerebri (benign intracranial hypertension), some of which involved concomitant use of tetracyclines. Concomitant treatment with tetracyclines should therefore be avoided. Early signs and symptoms of pseudotumor cerebri include papilledema, headache, nausea and vomiting, and visual disturbances. Patients with these symptoms should be screened for papilledema and, if present, they should be told to discontinue Accutane immediately and be referred to a neurologist for further diagnosis and care (see ADVERSE REACTIONS: *Neurological*).

Pancreatitis: Acute pancreatitis has been reported in patients with either elevated or normal serum triglyceride levels. In rare instances, fatal hemorrhagic pancreatitis has been reported. Accutane should be stopped if hypertriglyceridemia cannot be controlled at an acceptable level or if symptoms of pancreatitis occur.

Lipids: Elevations of serum triglycerides have been reported in patients treated with Accutane. Marked elevations of serum triglycerides in excess of 800 mg/dL were reported in approximately 25% of patients receiving Accutane in clinical trials. In addition, approximately 15% developed a decrease in high-density lipoproteins and about 7% showed an increase in cholesterol levels. In clinical trials, the effects on

triglycerides, HDL, and cholesterol were reversible upon cessation of Accutane therapy. Some patients have been able to reverse triglyceride elevation by reduction in weight, restriction of dietary fat and alcohol, and reduction in dose while continuing Accutane.

Blood lipid determinations should be performed before Accutane is given and then at intervals until the lipid response to Accutane is established, which usually occurs within 4 weeks. Especially careful consideration must be given to risk/benefit for patients who may be at high risk during Accutane therapy (patients with diabetes, obesity, increased alcohol intake, lipid metabolism disorder or familial history of lipid metabolism disorder). If Accutane therapy is instituted, more frequent checks of serum values for lipids and/or blood sugar are recommended (see PRECAUTIONS: Laboratory Tests).

The cardiovascular consequences of hypertriglyceridemia associated with Accutane are unknown. *Animal Studies:* In rats given 8 or 32 mg/kg/day of isotretinoin (0.7 or 2.7 times the maximum clinical dose after normalization for total body surface area) for 18 months or longer, the incidences of focal calcification, fibrosis and inflammation of the myocardium, calcification of coronary, pulmonary and mesenteric arteries, and metastatic calcification of the gastric mucosa were greater than in control rats of similar age. Focal endocardial and myocardial calcifications associated with calcification of the coronary arteries were observed in two dogs after approximately 6 to 7 months of treatment with isotretinoin at a dosage of 60 to 120 mg/kg/day (15 to 30 times the maximum clinical dose, respectively, after normalization for total body surface area).

Hearing Impairment: Impaired hearing has been reported in patients taking Accutane; in some cases, the hearing impairment has been reported to persist after therapy has been discontinued. Mechanism(s) and causality for this event have not been established. Patients who experience tinnitus or hearing impairment should discontinue Accutane treatment and be referred to specialized care for further evaluation (see ADVERSE REACTIONS: Special Senses).

Hepatotoxicity: Clinical hepatitis considered to be possibly or probably related to Accutane therapy has been reported. Additionally, mild to moderate elevations of liver enzymes have been observed in approximately 15% of individuals treated during clinical trials, some of which normalized with dosage reduction or continued administration of the drug. If normalization does not readily occur or if hepatitis is suspected during treatment with Accutane, the drug should be discontinued and the etiology further investigated.

Inflammatory Bowel Disease: Accutane has been associated with inflammatory bowel disease (including regional ileitis) in patients without a prior history of intestinal disorders. In some instances, symptoms have been reported to persist after Accutane treatment has been stopped. Patients experiencing abdominal pain, rectal bleeding or severe diarrhea should discontinue Accutane immediately (see ADVERSE REACTIONS: Gastrointestinal).

Skeletal: Hyperostosis: A high prevalence of skeletal hyperostosis was noted in clinical trials for disorders of keratinization with a mean dose of 2.24 mg/kg/day. Additionally, skeletal hyperostosis was noted in 6 of 8 patients in a prospective study of disorders of keratinization. Minimal skeletal hyperostosis and calcification of ligaments and tendons have also been observed by x-ray in prospective studies of nodular acne patients treated with a single course of therapy at recommended doses. The skeletal effects of multiple Accutane treatment courses for acne are unknown.

Premature Epiphyseal Closure: There are spontaneous reports of premature epiphyseal closure in acne patients receiving recommended doses, but it is not known if there is a causal relationship with Accutane. In clinical trials for disorders of keratinization with a mean dose of 2.24 mg/kg/day, two children showed x-ray findings suggestive of premature epiphyseal closure. The skeletal effects of multiple Accutane treatment courses for acne are unknown.

Vision Impairment: Visual problems should be carefully monitored. All Accutane patients experiencing visual difficulties should discontinue Accutane treatment and have an ophthalmological examination (see ADVERSE REACTIONS: *Special Senses*).

Corneal Opacities: Corneal opacities have occurred in patients receiving Accutane for acne and more frequently when higher drug dosages were used in patients with disorders of keratinization. The corneal opacities that have been observed in clinical trial patients treated with Accutane have either completely resolved or were resolving at follow-up 6 to 7 weeks after discontinuation of the drug (see ADVERSE REACTIONS: *Special Senses*). **Decreased Night Vision:** Decreased night vision has been reported during Accutane therapy and in some instances the event has persisted after therapy was discontinued. Because the onset in some patients was sudden, patients should be advised of this potential problem and warned to be cautious when driving or operating any vehicle at night.

PRECAUTIONS: Information for Patients and Prescribers: Females of childbearing potential should be instructed that they must not be pregnant when Accutane therapy is initiated, and that they should use effective contraception while taking Accutane and for 1 month after Accutane has been stopped. They should also sign a consent form prior to beginning Accutane therapy. They should be instructed to join the Accutane Survey and to review the patient videotape provided by Roche to the prescriber that provides information about contraception, the most common reasons that contraception fails, and the importance of using effective contraception when taking teratogenic drugs. Female patients should also be seen monthly and have a urine or serum pregnancy test performed each month during treatment to confirm negative pregnancy status (see boxed CONTRAINDICATIONS AND WARNINGS).

- Patients should be informed that they must not share Accutane with anyone else because of the risk of birth defects and other serious adverse events.
- Patients should not donate blood during therapy and for 1 month following discontinuance of the drug because the blood might be given to a pregnant woman whose fetus must not be exposed to Accutane.
- Patients should be informed that transient exacerbation (flare) of acne has been seen, generally during the initial period of therapy.
- Wax epilation and skin resurfacing procedures (such as dermabrasion, laser) should be avoided during Accutane therapy and for at least 6 months thereafter due to the possibility of scarring (see ADVERSE REACTIONS: Skin and Appendages).
- Patients should be advised to avoid prolonged exposure to UV rays or sunlight.
- Patients should be informed that they may experience decreased tolerance to contact lenses during and after therapy.
- Patients should be informed that approximately 16% of patients treated with Accutane in a clinical trial developed musculoskeletal symptoms (including arthralgia) during treatment. In general, these symptoms were mild to moderate, but occasionally required discontinuation of the drug. Transient pain in the chest has been reported less frequently. In the clinical trial, these symptoms generally cleared rapidly after discontinuation of Accutane, but in some cases persisted (see ADVERSE REACTIONS: Musculoskeletal).
- Neutropenia and rare cases of agranulocytosis have been reported. Accutane should be discontinued if clinically significant decreases in white cell counts occur.

Hypersensitivity: Anaphylactic reactions and other allergic reactions have been reported. Cutaneous allergic reactions and serious cases of allergic vasculitis, often with purpura (bruises and red patches) of the extremities and extracutaneous involvement (including renal) have been reported. Severe allergic reaction necessitates discontinuation of therapy and appropriate medical management.

Drug Interactions:

- Because of the relationship of Accutane to vitamin A, patients should be advised against taking vitamin supplements containing vitamin A to avoid additive toxic effects.
- Concomitant treatment with Accutane and tetracyclines should be avoided because Accutane use has been associated with a number of cases of pseudotumor cerebri (benign intracranial hypertension), some of which involved concomitant use of tetracyclines.
- Microdosed progesterone preparations (minipills) may be an inadequate method of contraception during Accutane therapy. Although other hormonal contraceptives are highly effective, there have been reports of pregnancy from women who have used oral contraceptives, as well as injectable/implantable contraceptive products. These reports are more frequent for women who use only a single method of contraception. It is not known if hormonal contraceptives differ in their effectiveness when used with Accutane. Therefore, it is critically important that women of childbearing potential use two effective forms of contraception simultaneously, unless absolute abstinence is the chosen method, even when one of the forms is a hormonal contraceptive method (see boxed CONTRAINDICATIONS AND WARNINGS).

Laboratory Tests:

- *Pregnancy Test:* Female patients of childbearing potential must have negative results from two urine or serum pregnancy tests with a sensitivity of at least 50 mIU/mL before a prescription is given. The first test is to be performed at the office visit when the patient is qualified for Accutane therapy by her prescriber. The second test is to be performed on the second day of her next menstrual cycle or 11 days after her last unprotected act of sexual intercourse, whichever is later. Additional pregnancy tests are to be conducted monthly during treatment.
- *Lipids:* Pretreatment and follow-up blood lipids should be obtained under fasting conditions. After consumption of alcohol, at least 36 hours should elapse before these determinations are made. It is recommended that these tests be performed at weekly or biweekly intervals until the lipid response to Accutane is established. The incidence of hypertriglyceridemia is 1 patient in 4 on Accutane therapy (see WARNINGS: *Lipids*).
- *Liver Function Tests:* Since elevations of liver enzymes have been observed during clinical trials, and hepatitis has been reported, pretreatment and follow-up liver function tests should be performed at weekly or biweekly intervals until the response to Accutane has been established (see WARNINGS: *Hepatotoxicity*).
- *Glucose:* Some patients receiving Accutane have experienced problems in the control of their blood sugar. In addition, new cases of diabetes have been diagnosed during Accutane therapy, although no causal relationship has been established.
- *CPK:* Some patients undergoing vigorous physical activity while on Accutane therapy have experienced elevated CPK levels; however, the clinical significance is unknown.

Carcinogenesis, Mutagenesis and Impairment of Fertility: In male and female Fischer 344 rats given oral isotretinoin at dosages of 8 or 32 mg/kg/day (0.7 or 2.7 times the maximum clinical dose, respectively, after

normalization for total body surface area) for greater than 18 months, there was a dose-related increased incidence of pheochromocytoma relative to controls. The incidence of adrenal medullary hyperplasia was also increased at the higher dosage in both sexes. The relatively high level of spontaneous pheochromocytomas occurring in the male Fischer 344 rat makes it an equivocal model for study of this tumor; therefore, the relevance of this tumor to the human population is uncertain.

The Ames test was conducted with isotretinoin in two laboratories. The results of the tests in one laboratory were negative while in the second laboratory a weakly positive response (less than 1.6 x background) was noted in *S. typhimurium* TAI00 when the assay was conducted with metabolic activation. No dose-response effect was seen and all other strains were negative. Additionally, other tests designed to assess genotoxicity (Chinese hamster cell assay, mouse micronucleus test, *S. cerevisiae* D7 assay, in vitro clastogenesis assay with human-derived lymphocytes, and unscheduled DNA synthesis assay) were all negative.

In rats, no adverse effects on gonadal function, fertility, conception rate, gestation or parturition were observed at oral dosages of isotretinoin of 2, 8 or 32 mg/kg/day (0.2, 0.7, or 2.7 times the maximum clinical dose, respectively, after normalization for total body surface area).

In dogs, testicular atrophy was noted after treatment with oral isotretinoin for approximately 30 weeks at dosages of 20 or 60 mg/kg/day (5 or 15 times the maximum clinical dose, respectively, after normalization for total body surface area). In general, there was microscopic evidence for appreciable depression of spermatogenesis but some sperm were observed in all testes examined and in no instance were completely atrophic tubules seen. In studies of 66 men, 30 of whom were patients with nodular acne under treatment with oral isotretinoin, no significant changes were noted in the count or motility of spermatozoa in the ejaculate. In a study of 50 men (ages 17 to 32 years) receiving Accutane (isotretinoin) therapy for nodular acne, no significant effects were seen on ejaculate volume, sperm count, total sperm motility, morphology or seminal plasma fructose.

Pregnancy: Category X. See boxed CONTRAINDICATIONS AND WARNINGS.

Nursing Mothers: It is not known whether this drug is excreted in human milk. Because of the potential for adverse effects, nursing mothers should not receive Accutane.

ADVERSE REACTIONS: Clinical Trials and Postmarketing Surveillance: The adverse reactions listed below reflect the experience from investigational studies of Accutane, and the postmarketing experience. The relationship of some of these events to Accutane therapy is unknown. Many of the side effects and adverse reactions seen in patients receiving Accutane are similar to those described in patients taking very high doses of vitamin A (dryness of the skin and mucous membranes, eg, of the lips, nasal passage, and eyes).

Dose Relationship: Cheilitis and hypertriglyceridemia are usually dose related. Most adverse reactions reported in clinical trials were reversible when therapy was discontinued; however, some persisted after cessation of therapy (see WARNINGS and ADVERSE REACTIONS).

Body as a Whole: allergic reactions, including vasculitis, systemic hypersensitivity (see PRECAUTIONS: Hypersensitivity), edema, fatigue, lymphadenopathy, weight loss

Cardiovascular: palpitation, tachycardia, vascular thrombotic disease, stroke

Endocrine/Metabolic: Hypertriglyceridemia (see WARNINGS: Lipids), alterations in blood sugar levels (see PRECAUTIONS: Laboratory Tests)

Gastrointestinal: inflammatory bowel disease (see WARNINGS: Inflammatory Bowel Disease), hepatitis (see WARNINGS: Hepatotoxicity), pancreatitis (see WARNINGS: Lipids), bleeding and inflammation of the gums, colitis, ileitis, nausea, other nonspecific gastrointestinal symptoms

Hematologic: allergic reactions (see PRECAUTIONS: Hypersensitivity), anemia, thrombocytopenia, neutropenia, rare reports of agranulocytosis (see PRECAUTIONS: Information for Patients and Prescribers). See PRECAUTIONS: Laboratory for other hematological parameters.

Musculoskeletal: skeletal hyperostosis, calcification of tendons and ligaments, premature epiphyseal closure (see WARNINGS: Skeletal), mild to moderate musculoskeletal symptoms including arthralgia (see PRECAUTIONS: Information for Patients and Prescribers), transient pain in the chest (see PRECAUTIONS: Information for Patients and Prescribers), elevations of CPK (see PRECAUTIONS: Laboratory Tests), arthritis, tendonitis, other types of bone abnormalities

Neurological: pseudotumor cerebri (see WARNINGS: Pseudotumor Cerebri), dizziness, drowsiness, headache, insomnia, lethargy, malaise, nervousness, paresthesias, seizures, stroke, syncope, weakness

Psychiatric: suicidal ideation, suicide attempts, suicide, depression, psychosis (see WARNINGS: Psychiatric Disorders), emotional instability

Of the patients reporting depression, some reported that the depression subsided with discontinuation of therapy and recurred with reinstatement of therapy.

Reproductive System: abnormal menses

Respiratory: bronchospasms (with or without a history of asthma), respiratory infection, voice alteration

Skin and Appendages: acne fulminans, alopecia (which in some cases persists), bruising, cheilitis (dry lips), dry mouth, dry nose, dry skin, epistaxis, eruptive xanthomas⁷, flushing, fragility of skin, hair abnormalities, hirsutism, hyperpigmentation and hypopigmentation, infections (including disseminated herpes simplex), nail dystrophy, paronychia, peeling of palms and soles, photoallergic/photosensitizing reactions, pruritus, pyogenic granuloma, rash (including facial erythema, seborrhea, and eczema), sunburn susceptibility increased, sweating, urticaria, vasculitis (including Wegener's granulomatosis; see PRECAUTIONS: Hypersensitivity), abnormal wound healing (delayed healing or exuberant granulation tissue with crusting; see PRECAUTIONS: Information for Patients and Prescribers)

Special Senses: Hearing: Hearing impairment (see WARNINGS: Hearing Impairment), tinnitus. *Vision:* corneal opacities (see WARNINGS: Corneal Opacities), decreased night vision which may persist (see WARNINGS: Decreased Night Vision), cataracts, color vision disorder, conjunctivitis, dry eyes, eye lid inflammation, keratitis, optic neuritis, photophobia, visual disturbances

Urinary System: glomerulonephritis (see PRECAUTIONS: Hypersensitivity), nonspecific urogenital findings (see PRECAUTIONS: Laboratory for other urological parameters)

Laboratory: Elevation of plasma triglycerides (see WARNINGS: Lipids), decrease in serum high-density lipoprotein (HDL) levels, elevations of serum cholesterol during treatment

Increased alkaline phosphatase, SGOT (AST), SGPT (ALT), GGTP or LDH (see WARNINGS: Hepatotoxicity)

Elevation of fasting blood sugar, elevations of CPK (see PRECAUTIONS: Laboratory Tests), hyperurcemia

Decreases in red blood cell parameters, decreases in white blood cell counts (including severe neutropenia and rare reports of agranulocytosis; see PRECAUTIONS: Information for Patients and Prescribers), elevated sedimentation rates, elevated platelet counts, thrombocytopenia

White cells in the urine, proteinuria, microscopic or gross hematuria

OVERDOSAGE: The oral LD₅₀ of isotretinoin is greater than 4000mg/kg in rats and mice (>300 times the maximum clinical dose after normalization of the rat dose for total body surface area and >150 times the maximum clinical dose after normalization of the mouse dose for total body surface area) and is approximately 1960 mg/kg in rabbits (327 times the maximum clinical dose after normalization for total body surface area). In humans, overdosage has been associated with vomiting, facial flushing, cheilosis, abdominal pain, headache, dizziness, and ataxia. All symptoms quickly resolved without apparent residual effects.

DOSAGE AND ADMINISTRATION: The recommended dosage range for Accutane is 0.5 to 2 mg/kg given in 2 divided doses daily for 15 to 20 weeks. In studies comparing 0.1, 0.5, and 1 mg/kg/day,³ it was found that all dosages provided initial clearing of disease, but there was a greater need for retreatment with the lower dosages.

It is recommended that for most patients the initial dosage of Accutane be 0.5 to 1 mg/kg/day. Patients whose disease is very severe or is primarily manifested on the trunk may require up to the maximum recommended dosage, 2 mg/kg/day. During treatment, the dose may be adjusted according to response of the disease and/or the appearance of clinical side effects — some of which may be dose related.

If the total nodule count has been reduced by more than 70% prior to completing 15 to 20 weeks of treatment, the drug may be discontinued. After a period of 2 months or more off therapy, and if warranted by persistent or recurring severe nodular acne, a second course of therapy may be initiated. The optimal interval before retreatment has not been defined for patients who have not completed skeletal growth (see WARNINGS: Skeletal: Hyperostosis and Premature Epiphyseal Closure).

Contraceptive measures must be followed for any subsequent course of therapy (see boxed CONTRAINDICATIONS AND WARNINGS).

Accutane should be administered with food.

ACCUTANE DOSING BY BODY WEIGHT				
Body Weight		Total Mg/Day		
kilograms	pounds	0.5 mg/kg	1 mg/kg	2 mg/kg
40	88	20	40	80
50	110	25	50	100
60	132	30	60	120
70	154	35	70	140
80	176	40	80	160
90	198	45	90	180
100	220	50	100	200

HOW SUPPLIED: Soft gelatin capsules, 10 mg (light pink), imprinted ACCUTANE 10 ROCHE. Boxes of 100 containing 10 Prescription Paks of 10 capsules (NDC 0004-0 155-49).

Soft gelatin capsules, 20 mg (maroon), imprinted ACCUTANE 20 ROCHE. Boxes of 100 containing 10 Prescription Paks of 10 capsules (NDC 0004-0169-49).

Soft gelatin capsules, 40 mg (yellow), imprinted ACCUTANE 40 ROCHE. Boxes of 100 containing 10 Prescription Paks of 10 capsules (NDC 0004-0156-49). Store at controlled room temperature (59° to 86°F, 15° to 30°C). Protect from light.

REFERENCES:

1. Peck GL, Olsen TG, Yoder FW, et al. Prolonged remissions of cystic and conglobate acne with 13-cis-retinoic acid. *NEnglJMed* 300:329-333, 1979. 2. Pochi PE, Shalita AR, Strauss JS, Webster SB. Report of the

consensus conference on acne classification. *J Am Acad Dermatol* 24:495-500, 1991. 3. Farrell LN, Strauss JS, Stranieri AM. The treatment of severe cystic acne with 13-cis-retinoic acid: evaluation of sebum production and the clinical response in a multiple-dose trial. *J Am Acad Dermatol* 3:602-611, 1980. 4. Jones H, Blanc D, Cunliffe WJ. 13-cis-retinoic acid and acne. *Lancet* 2:1048-1049, 1980. 5. Katz RA, Jorgensen H, Nigra TP. Elevation of serum triglyceride levels from oral isotretinoin in disorders of keratinization. *Arch Dermatol* 116:1369-1372, 1980. 6. Ellis CN, Madison KC, Pennes DR, Martel W, Voorhees JJ. Isotretinoin therapy is associated with early skeletal radiographic changes. *J Am Acad Dermatol* 10:1024-1029, 1984. 7. Dicken CH, Connolly SM. Eruptive xanthomas associated with isotretinoin (13-cis-retinoic acid). *Arch Dermatol* 116:951-952, 1980. 8. Strauss JS, Rapini RP, Shalita AR, et al. Isotretinoin therapy for acne: results of a multicenter dose-response study. *J Am Acad Dermatol* 10:490-496, 1984.

PATIENT CONSENT FORM

To be completed by the patient, her parent/guardian*
and signed by her prescriber.

Please read each item below and initial in the space provided to indicate that you understand each item and agree to follow your prescriber's instructions. **DO NOT SIGN THIS CONSENT AND DO NOT TAKE ACCUTANE IF THERE IS ANYTHING THAT YOU DO NOT UNDERSTAND.** A parent or guardian of a minor patient must also read and understand each item before signing the consent.

1. I, _____,
(Patient's Name)

understand that Accutane is a very powerful medicine with the potential for serious Adverse Effects that is used to treat severe nodular acne that did not get better with other treatments including oral antibiotics.

Initials: _____

2. I understand that I must not take Accutane (isotretinoin) if I am pregnant. I understand that I must not take Accutane if I am able to become pregnant and I am not using the required two separate forms of effective methods of birth control.

Initials: _____

3. I understand from my prescriber that although not every fetus exposed to Accutane has resulted in a deformed child, there is an extremely high risk that my unborn baby could have severe birth defects if I am pregnant or become pregnant while taking Accutane in any amount even for short periods of time. Potentially any fetus exposed during pregnancy can be affected.

Initials: _____

4. I understand that I must avoid pregnancy during the entire time of my treatment and for 1 month after the end of my treatment with Accutane.

Initials: _____

5. I understand that if I am able to become pregnant and unless I absolutely and consistently abstain from sexual intercourse, I must use two separate, effective forms of birth control (contraception) AT THE SAME TIME.

Initials: _____

6. I understand from discussions with my prescriber that birth control pills and injectable/implantable birth control products are the most effective forms of birth control. I understand that there have been reports of pregnancy from women who have used birth control pills, as well as women who have used injectable/implantable birth control products and I understand that pregnancies occur more often when only a single method of birth control is used. Therefore, I understand that it is essential that I use two different methods, even if one of the methods I choose is birth control pills or injectable/implantable birth control products.

Initials: _____

7. I understand that the following are considered effective forms of contraception:

Primary: Tubal ligation, partner's vasectomy, birth control pills, injectable/implantable birth control products, and an RJD

Secondary: Diaphragms, latex condoms, and cervical caps; each must be used with a spermicide.

I understand that at least one of my two chosen methods of birth control must be a primary method, and that any birth control method can fail, even when two forms are used at the same time.

Initials: _____

8. I understand that I may receive free initial contraceptive counseling and pregnancy testing from a consulting physician or family planning center. I understand that my Accutane prescriber can provide me with an Accutane Patient Referral Form for this consultation.

Initials:

9. I understand that I must begin actively avoiding pregnancy as described above at least 1 month before taking the first dose of Accutane, throughout treatment with Accutane and for 1 month after I have completed Accutane treatment.

Initials:

10. I understand that I cannot receive a prescription for Accutane unless I have 2 negative pregnancy test results. The first pregnancy test should be during the office visit when my prescriber decides to prescribe Accutane. The second test should be on the second day of my next menstrual cycle or 11 days after the last time I had unprotected sexual intercourse, whichever is later. I understand that I will have additional pregnancy testing, monthly, throughout my Accutane therapy.

Initials:

11. I understand that I should not start Accutane until I am sure that I am not pregnant and have negative results from 2 pregnancy tests.

Initials:

12. I have read and understand the materials my prescriber has given to me, including the brochure *Important Information Concerning Your Treatment with Accutane® (isotretinoin)*. I have watched and understand the Roche video provided to me by my prescriber about contraception. I have also been told about a confidential counseling line that I may call for additional information about birth control and I have received information on emergency contraception.

Initials:

13. I understand that I must not share my medication with anyone else and that I should not give blood until 1 month after taking my last dose of Accutane, because if I do, someone else's unborn baby may be exposed to Accutane.

Initials: _____

14. I understand that I must immediately stop taking Accutane and inform my prescriber if I become pregnant, miss my menstrual period, or stop using birth control.

15. I have been given information about the confidential Accutane Survey by my prescriber and he/she has explained to me how important it is to join the Accutane Survey.

Initials: _____

My prescriber has answered all my questions about Accutane and the Accutane information provided to me. I understand all the information I have received and that avoiding pregnancy during Accutane treatment is my responsibility.

Initials: _____

I now authorize my prescriber _____ to begin my treatment with Accutane.

Patient signature: _____ Date: _____

Parent/guardian signature: _____ Date: _____

Please print: Patient name and address _____ Telephone (area code) _____

I have fully explained to the patient, _____, the nature and purpose of the treatment described above and the risks to females of childbearing potential. I have asked the patient if she has any questions regarding her treatment with Accutane and have answered those questions to the best of my ability.

Prescriber signature: _____ Date: _____

*if patient is a minor under the age of 18.

Roche Laboratories Inc.
340 Kingsland Street
Nutley, New Jersey 07110-1199

27897043-0400

Revised: April 2000 Printed in USA

Copyright © 2000 by Roche Laboratories Inc. All rights reserved.

ACUTANE SERIOUS ADVERSE EVENTS 1998-2000

Year	Suicides	Other Deaths	Suicide Attempts	Suicide Ideation	Hospitalization
2000	7	4	9	39	48
1999	15	2	22	42	63
1998	32	0	20	30	49
Totals	54	6	51	111	160

EXPLANATION OF ADVERSE EVENTS STATISTICS COMPILATION

The adverse events statistics were derived from the Food and Drug Administration's Adverse Event Reporting System (AERS) as of August 3, 2000.

Background on the AERS

The AERS database is a computerized system for storing adverse events reported by health professionals and others. AERS relies on health professionals to detect new clinical events, to attribute the appearance of the clinical event to the administration of a drug, and to report that clinical event. The health professional may choose to report the adverse reaction to the FDA or to a drug firm, who must, by law, report to the FDA. Ninety percent of the FDA's reports are received from drug manufacturers. Data from all reports are then entered into AERS. It is possible that the same event could receive multiple reports if it is reported to the FDA by both the Health Practitioner and the consumer in addition to the manufacturer. More information on the AERS can be accessed at <http://www.fda.gov/cder/aers/index.htm>.

Statistics on Adverse Events

The adverse event statistics were compiled from the AERS database records from January 1, 1998 to August 1, 2000 for adverse events reported for Accutane and Roaccutane. The adverse events compilation narrows the statistics to the AERS adverse event records of suicide, deaths not related to suicides, suicide attempts, suicide ideations and hospitalizations. Where more than one such event was listed in a single record, the most serious event was used as the noted event. For instance, where an event included both suicide attempt and suicide ideation, the event was recorded in the compilation as a suicide attempt. Where an event contained both a hospitalization and a suicide ideation, the event was catalogued as a suicide ideation. Any event listing suicide was recorded as a suicide. If an event resulted in a hospitalization, without the occurrence of any other category, it was counted simply as a hospitalization.

This cataloguing system recognizes each report as unique, and no report would be counted in more than one category. It is not possible from the AERS data provided to determine if one event was reported more than once. However, it is important to remember that the FDA believes the AERS undercounts adverse events, because it is a voluntary reporting system.

The accompanying compilation of events includes the date of report, the ISR number (unique FDA identifier), report source and type, the age and sex of the individual and the company report number. Each event can be cross checked in the database. The following abbreviations were used:

Report source

Con	Consumer
Dir	Direct
For	Foreign
HP	Health Professional
Lit	Literature
Other	Other

Report Type

Dir.	Direct
Exp.	Expedited
Per.	Periodic

170

2000

SUICIDES

Date	ISR Number	Report Source	Report Type	Age/Sex	Company Report
3/10/00	3473773-2	FOR/LIT/HP/OTHER	EXP	21/M	83462
5/30/00	3506399-2	FOR/LIT/HP	EXP	17/M	920500422001
6/9/00	3516278-2	OTHER	PER	19/M	207538
6/9/00	3516301-5	HP	PER	17/M	208136
6/9/00	3519144-1	OTHER	PER	20/M	205135
6/9/00	3519150-7	OTHER	PER	M	230702
6/9/00	3519370-1	HP	PER	19/M	227955

171

2000

OTHER DEATHS

Date	ISR Number	Report Source	Report Type	Age/Sex	Company Report
2/15/00	3458461-0	LIT/HP	EXP	M	227780
3/20/00	3478284-6	HP/OTHER	EXP	16/M	93625
6/9/00	3519096-4	OTHER	PER	16/M	233229
6/27/00	3520219-1	CON	DIR	M	

172

2000

SUICIDE ATTEMPTS

Date	ISR Number	Report Source	Report Type	Age/Sex	Company Report
3/20/00	3478290-1	CON/HP/OTHER	EXP	14/F	97850
6/9/00	3516247-2	CON	PER	30/M	205766
6/9/00	3516283-6		PER	22/M	207778
6/9/00	3516312-X	HP	PER	26/M	208620
6/9/00	3517352-7	HP	PER	18/F	97451
6/9/00	3517360-6	OTHER	PER	14/F	95402
6/9/00	3519164-7	CON	PER	17/M	230298
6/9/00	3519375-0	HP	PER	M	227536
6/9/00	3519383-X	HP	PER	16/M	227700

2000

SUICIDAL IDEATION/DEPRESSION SUICIDAL

Date	ISR Number	Report Source	Report Type	Age/Sex	Company Report
1/12/00	3443466-6	FOR/OTHER	EXP	17/F	215867
2/3/00	3451611-1	HP/OTHER	EXP	16/M	216377
2/15/00	3458434-8	HP/OTHER	EXP	16/M	216377
4/6/00	3484858-9	CON/OTHER	EXP	16/F	232575
4/13/00	3488406-9	CON/OTHER	EXP	16/F	232575
4/26/00	3493498-7	CON/OTHER	EXP	16/F	232575
5/5/00	3496981-3	CON/HP/OTHER	EXP	16/F	232575
5/8/00	3498235-8	CON	EXP	44/F	234822
5/16/00	3501251-0	CON/HP	EXP	10/F	235626
6/12/00	3512002-8	CON/HP	EXP	10/F	235626
6/12/00	3512126-5	CON/HP	EXP	44/F	234822
6/9/00	3516346-5	CON	PER	27/F	209802
6/9/00	3516348-9		PER	24/M	209927
6/9/00	3516763-3	HP/OTH	PER	28/F	219277
6/9/00	3516790-6	HP	PER	17/F	220639
6/9/00	3516795-5	CON	PER	19/M	220914
6/9/00	3517464-8	HP	PER	17/M	200150
6/9/00	3517490-9	CON	PER	24/F	202222
6/9/00	3517501-0	CON/HP	PER	F	203250
6/9/00	3517507-1	HP	PER	25/F	203730
6/9/00	3518942-8	COMPANY REP	PER	M	222824
6/9/00	3518951-9	CONS/OTHER	PER	15/F	223649
6/9/00	3519007-1	OTHER	PER	14/M	221299
6/9/00	3519011-3	CONS	PER	20/F	224284
6/9/00	3519095-2	CONS	PER	22/M	227353
6/9/00	3519100-3	HP	PER	F	232008
6/9/00	3519108-8	OTHER	PER	36/F	232571
6/9/00	3519115-5	CONS	PER	31/F	233167
6/9/00	3519118-0	CONS/HP/OTHER	PER	24/F	204242
6/9/00	3519127-1	CONS	PER	35/F	204725
6/9/00	3519146-5	OTHER	PER	15/M	205219
6/9/00	3519160-X	HP	PER	F	229813
6/9/00	3519187-8	HP	PER	14/M	231211
6/9/00	3519196-9	CON	PER	15/M	231487
6/9/00	3519257-4	CON	PER	16/M	216765

6/9/00	3519396-8	HP	PER	40/F	228346
6/9/00	3519414-7	CON/OTHER	PER	36/F	229011
6/27/00	3520145-8		DIR	39/F	
7/18/00	3531196-1	CON/OTHER	EXP	44/F	234822

2000

HOSPITALIZATIONS

Date	ISR Number	Report Source	Report Type	Age/Sex	Company Report
1/28/00	3448134-2	CON/OTHER	EXP	16/F	223642
2/11/00	3457295-0	CON/OTHER	EXP	17/F	227340
2/17/00	3459462-9	HP	EXP	20/M	220614
2/24/00	3462603-0	CON	EXP	20/F	228998
2/29/00	3465884-2	CON	EXP	19/F	229400
3/1/00	3466587-0	CON	EXP	F	222433
3/8/00	3471112-4	HP	EXP	20/M	220614
3/9/00	3472118-1	CON/OTHER	EXP	17/F	227340
3/9/00	3472594-4	HP	EXP	17/M	228989
3/14/00	3475559-1	CON	EXP	34/F	222433
3/15/00	3476304-6	HP	EXP	13/M	230859
3/21/00	3478193-2	HP	EXP	17/M	228989
3/28/00	3480831-5	CON/HP/OTHER	EXP	14/F	97850
3/30/00	3482155-9	CON	EXP	15/M	232009
4/4/00	3483866-1		DIR	15/M	
4/3/00	3484059-4	OTHER	EXP	16/F	210608
4/11/00	3486893-3	CON/HP	EXP	15/M	232009
4/18/00	3489907-X	CON/HP	EXP	15/M	232009
4/27/00	3493659-7	CON	EXP	35/F	PRIUSA2000001841
5/5/00	3497185-0		DIR	12/F	
5/8/00	3498542-9	HP	EXP	16/F	92720
5/8/00	3498544-2	CON/OTHER	EXP	16/F	223642
5/10/00	3498990-7	HP	EXP	15/M	231499
5/16/00	3051281-9	HP	EXP	13/M	230859
5/19/00	3502063-4	HP	EXP	17/M	235788
5/17/00	3502346-8	CON/HP/OTHER	EXP	15/F	223642
5/31/00	3506617-0	HP	EXP	17/M	235788
6/12/00	3512123-X	CON/HP	EXP	15/M	232009
6/13/00	3512660-8	CON	EXP	35/F	PRIUSA2000001841
6/14/00	3515210-5	CON/HP/OTHER	EXP	F	222459
6/9/00	3516244-7	OTHER	PER	14/M	205605
6/9/00	3516852-3	CON/HP/OTHER	PER	20/F	210580
6/9/00	3516864-X	CON/HP/OTHER	PER	20/F	210590
6/9/00	3518952-0	OTHER	PER	F	223668
6/9/00	3519145-3	OTHER	PER	21/F	205149

6/9/00	3519186-6	OTHER	PER	19/F	214220
6/9/00	3519192-1	HP	PER	21/F	214322
6/9/00	3519193-3	HP	PER	19/M	231417
6/9/00	3519199-4	OTHER	PER	F	215197
6/9/00	3519212-4	OTHER	PER	F	216387
6/9/00	3519275-6	CON/HP	PER	14/M	217403
6/26/00	3520788-1	HP	EXP	17/M	235788
7/5/00	3524243-4	CONS/HP	EXP	15/M	232009
7/11/00	3527625-X	HP	EXP	18/M	227868
7/11/00	3527632-7	CON/OTHER	EXP	15/F	239876
7/18/00	3531302-9	FOR/HP	EXP	26/F	240501
7/21/00	3534070-X	OTHER	EXP	18/F	240657
7/24/00	3534241-2	FOR/OTHER	EXP	17/M	240222

177

1999

SUICIDES

Date	ISR Number	Report Source	Report Type	Age/Sex	Company Report
2/8/99	3193332-9		Direct	17/M	
2/24/99	3206436-9	Consumer	Direct	16/M	
6/7/99	3285615-9	HP/Other	Per.	18/F	97629
6/7/99	3285711-6	HP	Per.	17/M	103319
6/7/99	3285723-2	HP	Per.	20/F	106552
6/7/99	3285727-X	Other	Per.	17/M	106930
6/7/99	3285782-7	Other	Per.	M	107928
6/7/99	3285804-3	HP	Per.	18/M	96545
6/7/99	3285886-9	HP/Other	Per.	15/M	200724
6/7/99	3285901-2	HP	Per.	16/M	201250
6/7/99	3285908-5	HP	Per.	17/M	112182
6/7/99	3285937-1	HP	Per.	21/M	113200
7/15/99	3304614-1	For/HP/Other	Exp.	21/M	83462
7/13/99	3315065-8	HP/Other	Exp.	32/M	USA010108
10/4/99	3363699-7	For/HP/Other	Exp.	21/M	83462

178

1999

OTHER DEATHS

Date	ISR Number	Report Source	Report Type	Age/Sex	Company Report
6/2/99	3275556-5	For/HP	Exp.	21/F	200462
9/28/99	3361731-8	Literature/HP	Exp.	43/F	860102175001

179

1999

SUICIDE ATTEMPTS

Date	ISR Number	Report Source	Report Type	Age/Sex	Company Report
6/2/99	3275437-7	Other	Exp.	16/M	202989
6/7/99	3284595-X	Con/HP	Per.	28/F	201530
6/7/99	3285618-4	HP/Other	Per.	14/F	97850
6/7/99	3285651-2	HP	Per.	16/M	98557
6/7/99	3285660-3	Con/HP	Per.	13/F	99025
6/7/99	3285669-X	Con	Per.	30/F	99261
6/7/99	3285681-0	Con	Per.	M	100090
6/7/99	3285684-6	Other	Per.	17/M	100509
6/7/99	3285687-1	HP	Per.	16/F	100742
6/7/99	3285692-5	HP	Per.	15/F	100854
6/7/99	3285713-X	Other	Per.	13/F	103491
6/7/99	3285716-5	Other	Per.	15/F	104463
6/7/99	3285762-1	HP	Per.	15/F	109641
6/7/99	3285785-2	HP	Per.	18/M	108198
6/7/99	3285801-8	HP	Per.	23/F	96273
6/7/99	3285807-9	HP	Per.	17/F	96992
6/7/99	3285810-9	HP	Per.	18/M	97450
6/7/99	3285811-0	HP	Per.	18/F	97451
6/7/99	3285867-5	Con/HP	Per.	22/F	200131
9/10/99	3345418-3	For/HP	Exp.	15/F	112379
10/28/99	3384820-0	HP	Exp.	18/F	218289
12/21/99	3426814-2	HP	Exp.	18/F	218289

1999

SUICIDAL IDEATION/DEPRESSION SUICIDAL

Date	ISR Number	Report Source	Report Type	Age/Sex	Company Report
2/4/99	3192344-9	Con/HP/Other	Exp.	45/F	108188
3/12/99	3219002-6	Con/Other	Exp.	42/F	90195
5/4/99	3253941-5	Con/HP	Exp.	39/M	204304
6/7/99	3284600-0	Con	Per.	24/F	202222
6/7/99	3284616-4	HP	Per.	25/F	203730
6/7/99	3285612-3	Con/HP	Per.	47/F	97604
6/7/99	3285616-0	HP	Per.	18/M	97744
6/7/99	3285622-6	HP	Per.	16/M	98042
6/7/99	3285623-8	Other	Per.	18/M	98112
6/7/99	3285668-8	HP	Per.	17/M	99252
6/7/99	3285671-8	HP/Other	Per.	15/F	99308
6/7/99	3285674-3	HP	Per.	17/M	99346
6/7/99	3285675-5	Other	Per.	26/F	99399
6/7/99	3285679-2	HP	Per.	37/F	99993
6/7/99	3285682-2	Other	Per.	16/M	100372
6/7/99	3285688-3	Other	Per.	21/M	100773
6/7/99	3285703-7	Con	Per.	23/F	102033
6/7/99	3285706-2	Other	Per.	17/M	102067
6/7/99	3285721-9	Con/HP	Per.	17/F	106302
6/7/99	3285729-3	Con/Other	Per.	16/F	110768
6/7/99	3285732-3	HP	Per.	45/F	110965
6/7/99	3285734-7	HP	Per.	38/F	111046
6/7/99	3285742-6	HP	Per.	41/F	111716
6/7/99	3285773-6	HP	Per.	17/M	107586
6/7/99	3285774-8	HP/Other	Per.	37/F	107679
6/7/99	3285775-X	Other	Per.	25/M	107680
6/7/99	3285778-5	HP	Per.	32/F	107754
6/7/99	3285779-7	HP	Per.	30/F	107768
6/7/99	3285786-4	Other	Per.	17/M	108271
6/7/99	3285870-5	HP	Per.	17/M	200150
6/7/99	3285875-4	HP	Per.	16/F	200298
6/7/99	3285879-1	HP/Other	Per.	17/F	200327
6/7/99	3285888-2	HP	Per.	18/M	200762
6/7/99	3285896-1	HP	Per.	M	201089
6/7/99	3285898-5	HP/Other	Per.	32/F	201149

6/7/99	3285922-X	Con/Other	Per.	40/F	112837
6/7/99	3285927-9	Con	Per.	21/F	940202353001
9/8/99	3343170-9	HP/Other	Exp.	19/M	214251
10/8/99	3369232-8	HP/Other	Exp.	16/M	216377
10/13/99	3371540-1	HP/Other	Exp.	19/M	214251
10/14/99	3372795-X	HP/Other	Exp.	16/M	216377
10/21/99	3378758-2	HP	Dir.	M	

1999

HOSPITALIZATIONS

Date	ISR Number	Report Source	Type	Report	Age/Sex	Company Report
2/9/99	3194531-2	Other		Exp.	15/M	112192
2/16/99	3199591-0	HP		Exp.	16/F	200082
2/19/99	3203414-0	Other		Exp.	16/F	200193
3/11/99	3218114-0	For/HP/Other		Exp.	16/M	109510
3/12/99	3218994-9	For/HP	Exp.		18/M	111144
3/17/99	3222169-7	HP		Exp.	16/F	200082
3/19/99	3223855-5	Other		Exp.	16/F	200193
4/2/99	3244710-0	HP		Exp.	25/F	202854
5/4/99	3253946-4	For/Other		Exp.	16/M	204662
5/12/99	3260058-2	For/Other		Exp.	15/M	110489
5/13/99	3261087-5	HP		Exp.	18/M	201521
5/14/99	3262580-1	HP		Exp.	16/F	200082
6/4/99	3276911-X	Con/HP		Exp.	M	87288
6/8/99	3277993-1	HP/Other		Exp.	F	112585
6/7/99	3285652-4	Con/HP		Per.	34/F	98586
6/7/99	3285667-6	Other		Per.	17/M	99251
6/7/99	3285690-1	HP		Per.	21/F	100778
6/7/99	3285691-3	HP		Per.	17/M	100782
6/7/99	3285693-7	HP		Per.	16/F	100996
6/7/99	3285697-4	Con		Per.	47/F	101428
6/7/99	3285744-X	HP		Per.	27/F	111802
6/7/99	3285747-5	HP		Per.	32/F	111894
6/7/99	3285766-9	Con/HP		Per.	36/F	110346
6/7/99	3285795-5	HP		Per.	18/F	95856
6/7/99	3285797-9	HP		Per.	43/F	95944
6/7/99	3285909-7	Other		Per.	16/M	112306
6/7/99	3286919-6	Other		Per.	16/M	98422
6/17/99	3288335-X	Other		Exp.	31/F	208256
7/1/99	3297269-6	HP/Other		Exp.	14/F	97850
7/6/99	3298115-7	For/HP	Exp.		38/M	208050
7/12/99	3301939-0	Other		Exp.	F	112585
8/10/99	3322541-0	HP		Exp.	18/M	201521
8/10/99	3322748-2	Con/Other		Exp.	27/F	211463
8/25/99	3335345-X	HP/Other		Exp.	M	213286
8/26/99	3335369-2	For/HP	Exp.		35/F	213108

9/1/99	3339145-6	HP/Other	Exp.	M	213286
9/3/99	3342522-0	Con/HP/Other	Exp.	27/F	211463
9/8/99	3343367-8	HP	Exp.	37/M	214389
9/8/99	3343421-0	Other	Exp.	33/F	214256
9/20/99	3352438-1	HP	Exp.	19/M	214774
9/22/99	3354985-5	HP	Exp.	15/M	215403
9/23/99	3357546-7	For/HP/Other	Exp.	38/M	208050
9/30/99	3361789-6	Other	Exp.		216188
10/4/99	3363707-3	Other	Exp.		216188
10/4/99	3363794-2	Con/Other	Exp.	36/F	216399
10/4/99	3363873-X	For/HP	Exp.	35/F	213108
10/12/99	3368636-7		Dir.	16/M	
10/13/99	3371538-3	HP	Exp.	37/M	214389
10/26/99	3382631-3	HP	Exp.	37/M	214389
10/27/99	3383816-2	Con/HP	Exp.	F	112764
10/28/99	3384844-3	Con/Other	Exp.	36/F	216399
11/19/99	3402815-5	Other	Exp.	F	112585
11/29/99	3409743-X	HP/Other	Exp.	M	213286
11/24/99	3409908-7	HP	Exp.	37/M	214389
11/26/99	3410148-6	HP	Exp.	20/M	220614
12/3/99	3413772-X	HP	Exp.	20/M	220614
12/6/99	3415083-5	HP	Exp.	19/F	216931
12/14/99	3421131-9	Other	Exp.		216188
12/14/99	3421204-0	Con	Exp.	35/F	221924
12/20/99	3425788-8	Con	Exp.	35/F	221924
12/23/99	3430498-7	HP	Exp.	4/F	222691
12/23/99	3430540-3	Con	Exp.	F	222433
12/28/99	3432761-2	Con	Exp.	35/F	221924

1998

SUICIDES

Date	ISR Number	Report Source	Type	Report	Age/Sex	Company Report
1/21/98	3017873-X	HP		Exp.	18/M	92735
2/10/98	3026743-2	Other		Exp.	22/M	93458
2/10/98	3026744-4	HP/Other		Exp.	16/M	93625
2/12/98	3030587-5	HP		Exp.	14/M	91720
2/18/98	3032237-0	HP		Exp.	16/M	93625
3/4/98	3050493-X	HP		Exp.	17/M	
3/10/98	3054664-8	HP		Exp.	20/F	95304
3/17/98	3055879-5	Other		Exp.	17/M	860200853001
3/17/98	3055884-9	HP		Exp.	20/F	95304
3/16/98	3055928-4	Con/HP		Exp.	37/M	920200145001
3/16/98	3055942-9	Other		Exp.	27/M	95384
3/16/98	3056036-9	Other		Exp.	18/M	95333
3/16/98	3056037-0	Other		Exp.	18/M	95333
3/24/98	3059463-9	For/Lit	Exp.		17/M	910700071001
3/24/98	3059494-9	HP		Exp.	13/F	91903
3/24/98	3059572-4	Other		Exp.	17/M	860200853001
3/31/98	3063222-0	Con		Dir.	16/M	
5/13/98	3075587-4			Dir.	19/M	
6/3/98	3088094-X			Dir.	27/M	
6/2/98	3088349-9	HP/Other		Exp.	27/M	95384
7/23/98	3107876-9	HP		Exp.	M	102836
8/25/98	3122075-2	For/HP	Exp.		21/M	83462
9/4/98	3126024-2	HP		Exp.	M	102836
9/16/98	3131046-1	For/HP	Exp.		21/M	83462
10/21/98	3144336-3			Dir.	17/M	
11/4/98	3151855-2			Dir.	19/M	
6/5/98	3174691-X	HP		Per.	17/M	96545
6/5/98	3174693-3	HP		Per.	18/M	96628
6/9/98	3175417-6	HP		Per.	18/M	96124
6/9/98	3175419-X	HP		Per.	17/M	96152
6/9/98	3177972-9	Other		Per.	15/M	95857
6/9/98	3178981-6	Other		Per.	19/M	94154

185

1998

SUICIDE ATTEMPTS

Date	ISR Number	Report Source	Report Type	Age/Sex	Company Report
3/5/98	3050346-7		DIR	16/F	
3/4/98	3050470-9		DIR	18/F	
3/10/98	3054593-X	CON	EXP	19/M	95291
3/10/98	3054597-7	OTHER	EXP	17/M	91162
3/10/98	3055040-4	HP	EXP	15/M	95293
3/26/98	3060376-7	HP	EXP	15/M	95293
4/3/98	3060778-9	FOR/LIT	EXP	18/M	870103027001
7/30/98	3111493-4	HP/OTHER	EXP	21/M	920201380001
8/6/98	3113964-3	FOR/HP	EXP	15/M	103137
6/5/98	3174686-6	HP	PER	16/F	96364
6/5/98	3174698-2	HP	PER	17/F	96992
6/5/98	3175320-1	HP	PER	M	97450
6/5/98	3175322-5	HP	PER	18/F	97451
6/5/98	3175324-9	HP	PER	13/?	97530
6/5/98	3175325-0	CONS/HP	PER	24/F	97601
6/9/98	3177424-6	OTHER	PER	M	95386
6/9/98	3177865-7	OTHER	PER	14/F	95399
6/9/98	3177866-9	OTHER	PER	14/F	95402
6/9/98	3177869-4		PER		
6/9/98	3177960-2	OTHER	PER	16/M	95583

1998

SUICIDAL IDEATION/DEPRESSION SUICIDAL

Date	ISR Number	Report Source	Report Type	Age/Sex	Company Report
3/10/98	3054939-2	OTHER	EXP	16/M	95296
3/10/98	3055037-4	CON	EXP	42/F	90195
3/16/98	3055855-2	OTHER	EXP	M	95265
3/16/98	3055962-4	OTHER	EXP	17/M	95341
3/12/98	3059142-8		DIR	15/F	
3/24/98	3060187-2	HP/OTHER	EXP	13/F	94423
4/30/98	3073944-3		DIR	F	
5/6/98	3080757-5		DIR	F	
5/22/98	3082515-4	OTHER	EXP	14/M	99250
6/2/98	3087606-X		EXP	16/M	99478
6/3/98	3088115-4		DIR	16/M	
6/16/98	3094924-8	OTHER	EXP	16/M	95296
6/22/98	3097288-9	FOR/CON	EXP	F	100402
7/17/98	3106189-9	CON	EXP	29/F	102074
7/16/98	3108491-3		DIR	16/M	
7/29/98	3110654-8	CON	EXP	29/F	101693
7/29/98	3110781-5	CON	EXP	29/F	102074
8/24/98	3121305-5		DIR	37/M	
9/16/98	3131049-7	FOR/OTHER	EXP	16/F	105468
9/30/98	3136408-4	OTHER	EXP	18/M	96185
12/11/98	3169581-2	CON/HP/OTHER	EXP	45/F	108188
6/5/98	3174690-8	OTHER	PER	17/M	96499
6/9/98	3175414-0	OTHER	PER	26/M	96073
6/9/98	3175420-6	HP	PER	15/M	96223
6/9/98	3177933-X	CON/HP	PER	32/F	86911
6/9/98	3177958-4	HP	PER	26/F	95581
6/9/98	3177959-6	OTHER	PER	17/M	95582
6/9/98	3177961-4	OTHER	PER	32/F	95585
6/9/98	3177962-6	HP/OTHER	PER	16/F	95587
6/9/98	3178600-9	OTHER	PER	15/M	93566

1998

HOSPITALIZATIONS

Date	ISR Number	Report Source	Report Type	Age/Sex	Company Report
1/8/98	3016841-1	FOR/OTHER	EXP	38/F	92130
1/21/98	3017887-X	FOR/HP	EXP	16/M	88218
1/27/98	3019417-5	CON	EXP	32/F	93114
1/27/98	3019460-6	LIT/HP	EXP	16/M	93035
2/18/98	3031267-2	CON/HP	EXP	32/F	92114
2/19/98	3032263-1	CON/HP	EXP	32/F	93114
2/27/98	3037624-2	HP	EXP	F	94721
3/2/98	3038633-X	HP	EXP	F	94721
3/19/98	3057827-0	OTHER	EXP	18/M	95976
3/24/98	3058987-8	FOR/HP	EXP	21/M	95864
3/24/98	3059391-9	HP	EXP	F	96389
3/24/98	3059554-2	HP	EXP	26/F	96110
3/24/98	3059577-3	HP	EXP	F	94721
4/3/98	3060773-X	HP	EXP	23/F	96389
4/7/98	3061694-9	FOR/HP	EXP	18/M	96343
4/30/98	3071514-4	HP	EXP	23/F	96389
4/30/98	3071521-1	HP	EXP	F	98139
4/30/98	3073227-1		DIR	16/M	
5/5/98	3073795-X	HP/OTHER	EXP	F	98139
5/4/98	3073952-2	FOR/HP	EXP	41	68417
5/15/98	3079361-4	HP/OTHER	EXP	20/F	98139
5/20/98	3080382-6		DIR	M	
5/22/98	3081748-0	HP	EXP	26/F	96110
6/9/98	3091176-X	FOR/HP	EXP	18/M	99374
6/12/98	3091845-1	FOR/HP/OTHER	EXP	37/M	93367
6/30/98	3100307-4	OTHER	EXP	19/F	101424
7/2/98	3101702-X	CON/HP	EXP	32/F	93114
7/7/98	3102757-9	HP	EXP	16/M	101476
7/13/98	3104604-8	HP	EXP	15/M	96303
7/24/98	3108870-4	FOR	EXP	21/M	102871
8/30/98	3112251-7	OTHER	EXP	16/F	101537
8/4/98	3113215-X	CON/HP	EXP	28/F	87288
8/5/98	3113448-2	OTHER	EXP	16/F	101537
8/11/98	3115186-9	CON/HP	EXP	28/F	87288
8/11/98	3115188-2	HP	EXP	23/F	96389

8/19/98	3118878-0	HP	EXP	18/F	103250
9/16/98	3130882-5	FOR/HP/OTHER	EXP	16/M	104837
9/17/98	3132040-7	CON/HP	EXP	28/F	87288
9/23/98	3134990-4	HP	EXP	18/F	103250
9/25/98	3135496-9	FOR/OTHER	EXP	14/F	105963
10/15/98	3142306-2	HP	EXP	35/M	96256
11/10/98	3155770-X	HP	EXP	20/F	106667
11/18/98	3159505-6	CON/HP	EXP	28/F	87288
12/17/98	3171634-X	FOR/OTHER	EXP	15/M	110489
6/5/98	3174696-9	HP	PER	17/M	96941
6/9/98	3177425-8	OTHER	PER	17/M	95388
6/9/98	3177970-5	OTHER	PER	13/F	95804
6/9/98	3177971-7	HP	PER	18/F	95856
6/9/98	3178579-X	HP	PER	14/F	91589

From: Nightwine, Carson
Sent: Wednesday, September 06, 2000 3:07 PM
To: Macklin, Gil; Mackey, John; Long, Kevin
Subject: Colombia

COLOMBIAN AID BREAKDOWN

- **\$516.7 million** - Colombian Military and Interdiction Support for Colombian Efforts
- **\$181.1 million** - Colombian Police and Administration of Justice
- **\$162.5 million** - Economic Development, Human Rights, Displaced Persons, Peace Process
- **\$248.8 million** - U.S. Agency Support
- **\$180 million** - Andean Ridge Support

\$1.289 million Total

AC CUTANE
Accutane Roche 20mg

Page 1



**FEMALE PATIENTS
 AVOID PREGNANCY**

20 mg

WARNING TO FEMALE PATIENTS

- YOU MUST HAVE A BLOOD OR URINE TEST DONE BY YOUR DOCTOR WHICH SHOWS YOU ARE **NOT** PREGNANT BEFORE YOU START TAKING ACCUTANE**
- YOU MUST WAIT UNTIL THE 2ND OR 3RD DAY OF YOUR PERIOD TO START TAKING ACCUTANE**
- YOU MUST USE TWO FORMS OF EFFECTIVE BIRTH CONTROL FOR AT LEAST ONE MONTH BEFORE, DURING, AND FOR ONE MONTH AFTER TAKING ACCUTANE**
- YOU MUST SEND IN THE FORM INSIDE THE MEDICATION PACKAGE TO SIGN UP FOR THE CONFIDENTIAL FOLLOW-UP SURVEY**

 **ROCHE LABORATORIES INC.**
 Nutley, New Jersey 07110

ACCUTANE

Accutane Roche 20mg

Page 2

WARNING TO FEMALE PATIENTS

YOU MUST NOT TAKE ACCUTANE IF YOU ARE PREGNANT OR MAY BECOME PREGNANT DURING TREATMENT. Severe birth defects are known to occur in babies of females taking Accutane in any amount even for short periods during pregnancy. There is an extremely high risk that a deformed baby will result if you become pregnant while taking Accutane; many babies have died. Potentially any exposed baby can be affected. There is also an increased risk of miscarriage. Premature births have occurred. The possibility that you may be pregnant must be ruled out by you and your doctor before you start Accutane therapy. Wait until the second or third day of your next normal menstrual period before beginning Accutane therapy.

Effective contraception (birth control) should be discussed with your doctor. Two forms of reliable contraception must be used simultaneously for at least one month before beginning therapy and during therapy, and must be continued for one month after Accutane treatment has stopped. It is recommended that you either abstain from sexual intercourse or use two reliable kinds of birth control at the same time. Birth control must be used even if you think you cannot become pregnant unless you have had a hysterectomy; immediately stop taking Accutane if you become pregnant while you are taking the drug. If you become pregnant while on Accutane therapy at during the month after treatment has stopped, immediately contact your physician to discuss the desirability of continuing the pregnancy.



Line drawing representing some common birth defects associated with Accutane use during pregnancy. These include forward deformed or absent ears, wide-set eyes, depressed bridge of nose, enlarged head and skull cap. More severe defects than those can occur including mental retardation. This picture does not show the severe internal defects that may occur including those of the brain, heart, glands and nervous system.

This package provides important facts about Accutane, but it does not contain all information about this medication. If there is anything else you want to know or if you have any questions, talk to your doctor. Accutane is a medicine used to treat severe nodular acne which has not gotten better after other treatments. Before

you decide to take Accutane, you must have discussed with your doctor the types of deformed babies that can occur if you are pregnant or may become pregnant while taking Accutane. For your own health, safety and well-being, please read the following information carefully and be certain that you understand what your doctor told you.

Before Your Treatment Begins

For Female Patients

- You must read, understand, and sign a consent form before you take Accutane; contact your doctor if you have not signed this form.
- You must not take Accutane until you are sure you are not pregnant. (Please see **WARNING TO FEMALE PATIENTS**.)
- You must use effective contraception (birth control) for at least one month before beginning Accutane therapy.
- You must have a urine or urine test done by your doctor that shows that you are not pregnant within one week before beginning Accutane.
- You must wait until the second or third day of your next normal menstrual period before beginning Accutane therapy.
- You must not take Accutane if you cannot avoid pregnancy.
- You should not take Accutane if you are a nursing mother.

For All Patients

- Blood tests should be necessary before and periodically during treatment to check your body's response to Accutane.
- If you have a family or personal history of medical conditions such as diabetes, liver disease, heart disease or depression, please inform your doctor.
- Accutane is related to vitamin A. Therefore, you should avoid taking vitamin supplements containing vitamin A because they may add to the unwanted effects of Accutane. Check with your doctor or pharmacist if you have any questions about vitamin supplements.
- Tell your doctor if you are sensitive to parabens, since they are used in Accutane capsules.
- Advise your doctor if you are planning to undergo vigorous physical activity during treatment.

During Your Treatment




For Female Patients

ACCUTANE

Accutane Roche 40mg

Page 1



**FEMALE PATIENTS
AVOID PREGNANCY**

40 mg

WARNING TO FEMALE PATIENTS

- YOU MUST** HAVE A BLOOD OR URINE TEST DONE BY YOUR PRESCRIBER THAT SHOWS YOU ARE **NOT** PREGNANT AT THE TIME YOUR PRESCRIBER DECIDES TO PRESCRIBE ACCUTANE FOR YOU
- YOU MUST** WAIT UNTIL YOU HAVE THE RESULTS OF A SECOND URINE OR BLOOD TEST THE 2ND DAY OF YOUR PERIOD OR 11 DAYS AFTER YOUR LAST UNPROTECTED SEXUAL INTERCOURSE, WHICHEVER COMES LATER, THAT SHOWS YOU ARE NOT PREGNANT BEFORE YOUR PRESCRIBER WILL GIVE YOU A PRESCRIPTION TO START TAKING ACCUTANE
- YOU MUST** USE TWO SEPARATE, EFFECTIVE FORMS OF BIRTH CONTROL SIMULTANEOUSLY FOR AT LEAST 1 MONTH BEFORE, DURING, AND FOR 1 MONTH AFTER TAKING ACCUTANE
- YOU MUST** SEND IN THE FORM INSIDE THE MEDICATION PACKAGE TO SIGN UP FOR THE CONFIDENTIAL FOLLOW-UP SURVEY

YOU MUST NOT TAKE ACCUTANE IF YOU ARE PREGNANT OR MAY BECOME PREGNANT DURING TREATMENT. PLEASE SEE COMPLETE WARNING TO FEMALE PATIENTS ON OTHER SIDE OF CARD.

ACCUTANE

Accutane Roche 40mg

Page 2

WARNING TO FEMALE PATIENTS

YOU MUST NOT TAKE ACCUTANE IF YOU ARE PREGNANT OR MAY BECOME PREGNANT DURING TREATMENT. Serious birth defects are known to occur in babies of females taking Accutane, in any amount, even for short periods during pregnancy. There is an extremely high risk that a pregnant baby will be born if you become pregnant if you take Accutane, even doses much lower than those of any exposed baby can be affected. There is also an increased risk of miscarriage. Premature births have occurred. The possibility that you may be pregnant must be ruled out by you and your prescriber before you start Accutane therapy. You must have a urine or blood pregnancy test done while you are in your prescriber's clinic that shows you are not pregnant. A second urine or blood test to confirm that you are not pregnant must be done within one to seven days of your next menstrual cycle. If you take your last menstrual period, whichever comes later. Then your prescriber will give you a prescription so you can begin your Accutane therapy. Effective contraception (birth control) should be discussed with your prescriber. The separate, effective forms of contraception must be used simultaneously for at least 1 month before beginning therapy and during therapy, and must be continued for 1 month after Accutane treatment has stopped. Any form of birth control can fail. Even through oral contraceptives (birth control pills) and injectable reproductive contraceptive products are highly effective, they have been known to fail. Therefore, it is

strongly suggested that you use two separate, effective forms of contraception simultaneously, even when one is a

hormonal contraceptive method, unless you are reliably and consistently assessed and supervised. If the method may be used even if you think you cannot become pregnant unless you have had a hysterectomy. If you become pregnant while you are taking the drug, if your prescriber prescribes an Accutane therapy or during the month after treatment has stopped, immediately contact your prescriber to discuss the desirability of continuing the pregnancy.



Life drawing representing some common birth defects associated with Accutane use during pregnancy. These include low-set ears, cleft lip, cleft palate, cleft eye, cleft lip and palate, cleft lip and palate, cleft lip and palate, cleft lip and palate. More severe defects than these can occur including neural tube defects. This picture does not show the severe neural tube defects that may occur including those of the brain, heart, spine, and nervous system.

This package provides important facts about Accutane, but it does not contain all information about the medication. If there is anything else you want to know or if you have any questions, ask your prescriber. Accutane is a medicine used to treat severe acne, which has not improved with other treatments. Before you decide to take Accutane, you must have

discussed with your prescriber the types of abnormal births that can occur if you are pregnant or may become pregnant while taking Accutane. For your own health, safety and well-being, please read the following information carefully and be certain that you understand what your prescriber tells you.

Before Your Treatment Begins

For Female Patients

- You must read, understand and sign a consent form before you take Accutane; contact your prescriber if you have not signed this form.
- You must not take Accutane until you are sure you are not pregnant. (Please see **WARNING TO FEMALE PATIENTS**.)
- You must use effective contraception (birth control) for at least 1 month before beginning Accutane therapy.
- You must have a blood or urine test done by your prescriber that shows that you are not pregnant at the time your prescriber decides to prescribe Accutane for you.
- You must have a second urine or blood test done that shows you are not pregnant, either on the second day of your next menstrual cycle or 7 days after your last menstrual period, whichever comes later. Then your prescriber will give you a prescription so you can begin your Accutane therapy.
- You must not take Accutane if you cannot avoid pregnancy.
- You should not take Accutane if you are or may become pregnant.

For All Patients

- Your prescriber will take blood tests before and periodically during treatment to check your body's response to Accutane.
- Inform your prescriber if you have a family or personal history of medical conditions such as depression (mood swings, suicidal thoughts or suicide attempts), diabetes, obesity, alcoholism, liver disease or blood disease.
- Avoid taking vitamin supplements containing vitamin A because they may add to the unwanted effects of Accutane. Check with your prescriber or pharmacist if you have any questions about vitamin supplements.
- Tell your prescriber if you are sensitive to paraffins, since they are used in Accutane capsules.
- Advise your prescriber if you are planning to undergo vigorous physical activity during treatment.

During Your Treatment

For Female Patients

- You must continue to use two separate, effective forms of contraception (birth control)



ACCUTANE

Recommendations to Improve Patient Safety

1. CONCLUSIVE RESEARCH

- Roche should commit to underwriting all necessary independent controlled studies on Accutane's risks of depression, suicidal ideation, suicide and other psychiatric disorders. Such studies should be designed in collaboration with the Food and Drug Administration (FDA) and be conducted by independent investigators.
- Congress should secure additional funding for post-market research and surveillance at FDA and at the Agency for Health Research and Quality (AHRQ).

2. BETTER INFORMATION

Until conclusive research has been completed —

- All Accutane patients should receive and sign an informed consent form clearly warning of Accutane's risks of depression, suicide and other psychiatric disorders every time the physician prescribes the drug.
- FDA should immediately ensure that Accutane labeling and boxes display the same warnings as the physician package insert of Accutane's risks of birth defects and of depression, suicide and other psychiatric disorders.
- FDA should immediately issue a patient "MedGuide" with clear and prominent warnings of Accutane's risks of birth defects and of depression, suicide and other psychiatric disorders.
- Roche should make immediate public disclosure of all U.S. and international serious Accutane adverse drug reactions (ADRs), and commit to sharing all future serious Accutane ADRs with the FDA and the public within 21 days of their receipt.
- Roche should immediately notify FDA of any international regulatory action (e.g. new warnings).

3. MORATORIUM ON DIRECT-TO-CHILDREN ADVERTISING

Until conclusive research has been completed —

- Roche should commit to refraining from direct-to-consumer (DTC) and direct-to-children Accutane advertising, or agree to

prominently disclose Accutane's risks of birth defects and depression, suicide and other psychiatric disorders in all such print and electronic advertising.

- **FDA should investigate whether Accutane is being over-prescribed and determine the impact of direct-to-children advertising on any such prescribing.**

If FDA does not have the authority to take any of these actions, they should immediately request the authority from Congress.

[Homepage](#) | [Welcome Message](#) | [About Bart](#) | [Bart's News Stand](#) | [1st District Information](#) | [Visiting the Nation's Capital](#)
[How To Get In Touch](#) | [Constituent Services](#) | [Service Academy Nominations](#) | [Michigan's Higher Education](#) | [1st District Web Links](#)

AC CUTANE CHRONOLOGY

1971

Hoffman La-Roche (Roche) develops Accutane, but chooses not to pursue marketing because of its risk of birth defects.

June 1982

The Food and Drug Administration (FDA) approves Accutane for the treatment of severe cystic acne which is unresponsive to other treatments. Shortly after marketing, FDA and Roche receive reports of Accutane-related birth defects.

September 1983

Public Citizen, a consumer advocacy group, petitions FDA for warning labels on Accutane's risk of birth defects and other side effects.

March and October 1984

FDA requires stronger warnings and physician mailings on Accutane's risk of birth defects.

June 1985

Roche amends Accutane's package insert under 'Adverse Reactions' to state:

"The following CNS reactions have been reported and may bear no relationship to therapy - seizures, emotional instability including depression, dizziness, nervousness, drowsiness, malaise, weakness, insomnia, lethargy and paresthesias."

August 1986

Roche amends Accutane's package insert to state:

"Depression has been reported in some patients on Accutane therapy. In some of these patients, this has subsided with discontinuation and recurred with reinstatement of therapy."

February 1988

A 1988 FDA memo concludes that Roche "had not acted in good faith to truly and accurately answer questions relating to Accutane use in women and pregnancy exposure." The memo recommends "active consideration of removal of Accutane from the market."

The memo also concludes that: "Given all the pieces of evidence available, it is difficult to avoid the conclusion that Accutane can adversely affect the adult human brain in clinically significant ways and that Accutane use is associated with severe psychiatric disease in some patients."

In response to calls to withdraw Accutane, Roche proposes more intensive patient education on the drug's risks of birth defects, including patient materials and informed consent forms.

May 1988

FDA requires stronger warnings and physician mailings on Accutane's risk of birth defects. FDA also requires additional studies, including follow-up patient surveys. Disregarding an advisory committee recommendation, FDA does not restrict prescribing of Accutane to board-certified dermatologists. Industry contends that FDA lacks the statutory authority to require all such conditions on Accutane's distribution.

1990

In a 1990 memo, FDA concluded that as a result of Accutane's risks of birth defects, "The magnitude of injury and death has been great and permanent, with 11,000 to 13,000 Accutane-related abortions and 900 to 1,100 Accutane-related birth defects."

1996

FDA initiates a MedGuide program to provide patients with drug information leaflets (also known as "patient package inserts" or PPIs). In the past, FDA had established PPIs through independent regulations or through voluntary manufacturer agreement. Where public health warranted, MedGuide would have permitted FDA to develop PPIs without manufacturer consent.

In response to industry objections, Congress enacts an appropriations rider limiting the MedGuide program. Congress permits FDA to develop MedGuides for 40 drugs with serious side-effects, including Accutane.

Roche unsuccessfully seeks in Federal court in New Jersey to suppress public availability of extensive Accutane documents, including adverse event reports, marketing plans and clinical data, relating to Accutane's risk of birth defects.

According to a 1996 press account of FDA documents, "More than 90 percent of females treated with Accutane did not have severe cystic acne."

March 3, 1997

Based on a 1992-94 French study of Accutane's association with depression, French health authorities require Roche to add "suicide attempt" to Accutane's side effects. Roche does not inform the FDA.

May 1997

FDA initiates discussions with Roche concerning reports of serious psychiatric disorders associated with Accutane. FDA is unaware of the new French warning.

August 1997

FDA issues a warning letter to Roche for failing to submit serious adverse event reports in a timely manner. Roche claims its computer systems are responsible for delays of up to eight years in complying with the law.

February 25, 1998

FDA requires Roche to add the following new bold-face warning to Accutane's physician package insert. FDA is still unaware of the new French warning.

"WARNINGS - Psychiatric Disorders: Accutane may cause depression, psychosis and, rarely, suicidal ideation, suicide attempts and suicide. Discontinuation of Accutane therapy may be insufficient; further evaluation may be necessary. No mechanism of action has been established for these events.

"ADVERSE REACTIONS - In the postmarketing period, a number of patients treated with Accutane have reported depression, psychosis and rarely, suicidal, ideation, suicide attempts and suicide. Of the patients reporting depression, some reported that the depression subsided with discontinuation of therapy and recurred with reinstatement of therapy."

In its press release, Roche claims there is no proof of causation and that "teenagers are at particular risk for depression."

March 1998

The U.K. and Ireland require warnings of Accutane's risk of psychiatric disorders which are similar to those in the U.S.

March 5, 1998

Just two weeks after Roche is compelled to strengthen warnings of Accutane's risks of "depression, psychosis and, rarely, suicidal ideation, suicide attempts and suicide," the FDA is forced to issue a warning letter requiring Roche to cease "false and misleading" advertisements which promote Accutane as an "effective treatment of severe acne... [that] minimizes negative psychosocial effects such as depression and poor self-image."

FDA adds, "This claim is particularly troublesome in light of information recently presented in a Dear Doctor letter that Accutane may cause depression, psychosis, and rarely, suicidal ideation, suicide attempts and suicide."

FDA charges Roche to "prominently disclose information about the psychiatric disorders described in the warnings section of the revised labeling" in Accutane advertisements.

July 1998

FDA becomes aware that French authorities had already required the addition of an Accutane "suicide attempt" warning in 1997, of the 1992-94 French study associating Accutane with depression, and of Roche's failure to disclose this information to the agency.

December 21, 1999

Roche prepares a "Psychiatric Disorder Issue Work-Up" for FDA, concluding:

"Psychotic Disorders: There are a very small number (3) of reported cases that imply causality between a described psychotic disorder and Accutane administration... Suicidal Behavior: There are no reports amongst the 168 reviewed that would imply causality between suicidal behavior and Accutane."

May 1, 2000

Roche changes the warnings on the package label to include:

"...DEPRESSION, AND RARELY SUICIDAL THOUGHTS, SUICIDE ATTEMPTS AND SUICIDE..."

This is the first time that the actual packaging contains the full psychiatric warnings.

September 18-19, 2000

FDA's Dermatologic and Ophthalmic Drug Advisory Committee holds a meeting on Accutane's risks of birth defects and psychiatric disorders. FDA concludes that from 1982 to May, 2000, Accutane is associated with 147 suicides and hospitalizations for depression.

The Advisory Committee determines that further research is needed to establish Accutane's risks of birth defects and of depression, suicide and other psychiatric disorders – but fails to specifically recommend that FDA require such studies. FDA suggests that such research should be conducted, but does not commit to requiring them.

Roche claims, "The number of suicides observed in the U.S. in the Accutane-exposed cohort is much less than would have been predicted... There is plainly no excess of observed suicides in the Accutane-exposed population (32) compared to what would be predicted in the age-matched general population."

[Homepage](#) | [Welcome Message](#) | [About Bart](#) | [Bart's News Stand](#) | [1st District Information](#) | [Visiting the Nation's Capital](#)
[How To Get In Touch](#) | [Constituent Services](#) | [Service Academy Nominations](#) | [Michigan's Higher Education](#) | [1st District Web Links](#)

Russell H. EITSON, M.D.
Vice President, Medical Affairs



Pharmaceuticals

By Hand

October 6, 2000

The Honorable Bart Stupak
United States House of Representatives
2348 Rayburn House Office Building
Washington, DC 20515-2201

Dear Representative Stupak:

First and foremost, on behalf of Roche, I want to express the deepest sympathy for your family's loss, and that of any family who endures the profound tragedy of a young person's suicide. We believe it is both necessary and understandable that any possible cause of such an event must be considered.

Roche is a responsible and ethical company, and the safety of our products is of paramount importance. Throughout the past eighteen years we have remained committed to carefully monitoring the use of Accutane. We have always worked closely with the Food and Drug Administration, the dermatologic community, and other health professionals to assure the safe and effective use of this important prescription medication.

As you may know, Roche recently presented a comprehensive analysis of the psychiatric adverse events in the Accutane-treated patient population to the Food and Drug Administration's Dermatologic and Ophthalmic Drugs Advisory Committee. We would appreciate the opportunity to review this information with you at your earliest convenience. We would also be prepared to discuss our current efforts and ongoing plans to address this complex scientific issue.

I will contact your office today to discuss the scheduling of such a meeting. It is our hope that we can create a dialogue through which we can address your concerns and questions about the safety of Accutane.

Sincerely,

REH/cds

Roche Laboratories Inc. 340 Kingsland Street Tel: 973-862-2380
Molteno, New Jersey 07118-1180 Fax: 973-252-4679

JPEG image 622x810 pixels

http://www.house.gov/stupak/accutano_itr_001011ellison.jpg

BART STUPAK
18 WEST C. HERRICK
2245 FORTUNE BULVARD
WASHINGTON, DC 20518
PHONE: 202-225-1326
FAX: 202-225-4344
EMAIL ADDRESS: stupak@mail.house.gov

Congress of the United States
House of Representatives
Washington, DC 20515-2201

COUNCIL
COMMITTEE
SUBCOMMITTEE
FRONT PANEL
FRANKS AND
HAWKINS
OFFICE OF THE
CLERK
LEGISLATIVE
COUNSEL
LAW ENFORCEMENT
REGIONAL GROUP

October 11, 2000

Russell H. Ellison, M.D.
Vice President, Medical Affairs
Roche Pharmaceuticals
340 Kingsland Street
Nutley, NJ 07110-1199

Dear Dr. Ellison:

Thank you for your letter offering to meet with me to discuss your company's views regarding its analysis of adverse events prepared for the Food and Drug Administration's (FDA) advisory committee meeting. I appreciate your willingness to discuss this issue and the sympathy you expressed regarding the loss of my son.

Today, I along with seven other members of Congress wrote to Patrick Zenger, President and CEO of Hoffman-La Roche, presenting specific recommendations Roche and the FDA should take regarding Accutane (Isotretinoin). I have enclosed a copy of the letter for your information.

I do not believe it would be appropriate to meet, until Mr. Zenger responds to the recommendations made by the Members of Congress that signed the letter. After we have received a response to our recommendations, it may be appropriate for all the co-signers of the letter to meet with representatives of Hoffman La-Roche. I believe this process will allow for the most constructive discussions of future actions regarding the information and marketing of Accutane.

Once again, I look forward to the prompt reply of Mr. Zenger to our letter.

Sincerely,

BART STUPAK
Member of Congress

BTS/nib

Enclosure

Washington, DC
 224 W. Washington
Washington, DC 20540
202-225-4344
 501 Independence Street
Baltimore, MD 21202
410-528-4500
 515 E. Madison
Baltimore, MD 21201
410-528-4500
 1128 East North Street
Suite D
Baltimore, MD 21202
410-528-4500
 111 N. Calverton
Annapolis, MD 21403
410-326-6600
 2 South 10th Street
Suite 2
Baltimore, MD 21202
410-528-4500
Fax: (202) 225-4344
www.house.gov/stupak

Congress of the United States
Washington, DC 20515

October 11, 2000

Patrick J. Zenner
President and CEO
Hoffmann-La Roche Inc.
340 Kingsland Street
Nutley, New Jersey 07110

Dear Mr. Zenner:

We are very concerned about the recent reports of Accutane's (Isotretinoin) possible link to severe psychiatric side effects. We have written to Commissioner Henney asking her to take a series of actions with regard to Accutane and have enclosed this letter for your review. However, Hoffman La-Roche can voluntarily take these actions without action by the Food and Drug Administration (FDA). We urge you to take swift action on a number of steps to protect the public health.

As the *700ky* show segment that aired last week proved, the public has not received adequate information regarding the serious adverse psychiatric effects that may be associated with Accutane. In order to immediately increase public awareness, Hoffman La-Roche should:

- require all Accutane patients receive and sign an informed consent form clearly warning of Accutane's risks of depression, suicide and other psychiatric disorders every time the physician prescribes the drug; and
- immediately ensure that Accutane labeling and boxes display the same warnings as the physician package insert of Accutane's risks of birth defects and of depression, suicide and other psychiatric disorders.

In addition, we are very concerned about the lack of post market studies regarding Accutane and its link to suicide, suicide attempts, suicidal ideation and depression. Your company should immediately fund research on this urgent issue. Please work with the FDA to select and ensure independent studies are conducted in a valid scientific manner.

Letter to Patrick J. Zenner
October 11, 2000
Page Two

Finally, we are asking Hoffman La-Roche to cease all Direct to Consumer advertising targeted at children, until the link between Accutane and its link to suicide, suicide attempts, suicidal ideation and depression have been studied. It is irresponsible to market this very powerful drug to children without having a better scientific evidence of its effects.

We urge you to take swift action on this matter. We await your prompt reply.

Sincerely,

Congress of the United States
Washington, DC 20515

October 11, 2000

The Honorable Jane Henney
Commissioner
Parklawn Building
5600 Fishers Lane
Rockville, MD 20857

Dear Commissioner Henney:

We are very concerned about the recent reports of Accutane's (isotretinoin) possible link to severe psychiatric side effects. We urge you to take swift action on a number of steps to protect the public health.

As the *Toddy* show segment that aired last week proved, the public has not received adequate information regarding the serious adverse psychiatric effects that may be associated with Accutane. In order to immediately increase public awareness, the FDA should:

- require all Accutane patients receive and sign an informed consent form clearly warning of Accutane's risks of depression, suicide and other psychiatric disorders every time the physician prescribes the drug;
- immediately ensure that Accutane labeling and boxes display the same warnings as the physician package insert of Accutane's risks of birth defects and of depression, suicide and other psychiatric disorders; and
- immediately issue a patient "MedGuide" with clear and prominent warnings of Accutane's risks of birth defects and of depression, suicide and other psychiatric disorders.

In addition, we are urging Hoffman La-Roche to take a number of steps and we ask that you use any resources available to the FDA to ensure its cooperation. First, we are very concerned about the lack of post market studies regarding Accutane and its link to suicide, suicide attempts, suicidal ideation and depression. Please work with Hoffman La-Roche to select and ensure independent studies are conducted in a valid scientific manner.

Letter to Commissioner Henney
October 11, 2000
Page Two

Finally, we are asking Hoffman La-Roche to cease all Direct to Consumer advertising targeted at children, until the link between Accutane and its link to suicide, suicide attempts, suicidal ideation and depression have been studied. It is irresponsible to market this very powerful drug to children without having a better scientific evidence of its effects.

We urge you to take swift action on this matter. We await your prompt reply.

Sincerely,

JPEG image 622x1210 pixels

http://www.house.gov/stupak/accutane_lr_001011henney.jpg

Congress of the United States
Washington, DC 20515

October 11, 2000

The Honorable Jane Henney
Commissioner
Parklawn Building
5600 Fishers Lane
Rockville, MD 20857

Patrick J. Zenner
President and Chief Executive Officer

By Hand

October 17, 2000

The Honorable Bart Stupak
United States House of Representatives
2348 Rayburn House Office Building
Washington, DC 20515-2201

Dear Representative Stupak:

Thank you for your October 11, 2000, letter to me expressing specific concerns relative to Accutane (isotretinoin). I wanted to respond to your letter as quickly as possible. The safe and appropriate use of prescription medicines, including Accutane, is of paramount importance to Roche.

Since the launch of Accutane in 1982, we have remained committed to carefully monitoring and helping to manage the appropriate use of Accutane. We have worked closely with the Food and Drug Administration (FDA), the dermatologic community, and other health professionals to assure the safe use of this important drug. In many respects, our current risk management program for Accutane is unprecedented in the pharmaceutical industry.

We recently presented a comprehensive analysis of the psychiatric adverse events in the Accutane-treated patient population to the FDA's Dermatologic and Ophthalmic Drugs Advisory Committee. Although the Committee did not conclude that there is proof of a causal relationship between Accutane and psychiatric conditions, it recommended that additional study and risk management steps would be appropriate given the serious nature of this issue. We are working closely with the FDA to develop and to implement effective responses to the Advisory Committee's recommendations, as follows:

1. We will provide the FDA with a proposed Medication Guide (MedGuide) on Accutane before the end of the month. This document will include warnings of birth defects as well as a discussion of psychiatric events consistent with the professional label.
2. At the same time, we will provide FDA with a revised informed consent form incorporating the psychiatric information in the current labeling.
3. As recognized by the FDA Advisory Committee, designing a scientifically sound approach to studying this matter raises complex methodological issues from both a scientific as well as social perspective. We are committed to working with FDA to design a feasible approach to study this issue and to fund that effort.

-2-

In addition to these actions, I have committed the Company to take additional steps:

1. We are exchanging packages in the market to assure that they have current labeling. We have requested a meeting with the FDA on the implementation of our plans.
2. As of today, we are discontinuing televised non-branded acne education messages directed to young people until further risk management steps, including those outlined above, have been addressed. For clarification, however, Roche does not discriminate branded direct-to-consumer advertising for Accutane to any patient population. We have conducted acne educational programs that were seen by consumers of all ages, including adults and young people. These programs do not include references to Accutane.

Patrick J. Zenner
President and Chief Executive Officer

By Hand



October 17, 2000

The Honorable Bart Stupak
United States House of Representatives
2348 Rayburn House Office Building
Washington, DC 20515-2201

Dear Representative Stupak:

Thank you for your October 11, 2000, letter to me expressing specific concerns relative to Accutane (isotretinoin). I wanted to respond to your letter as quickly as possible. The safe and appropriate use of prescription medicines, including Accutane, is of paramount importance to Roche.

Since the launch of Accutane in 1982, we have remained committed to carefully monitoring and helping to manage the appropriate use of Accutane. We have worked closely with the Food and Drug Administration (FDA), the dermatologic community, and other health professionals to assure the safe use of this important drug. In many respects,

Patrick J. Zenner
President and Chief Executive Officer

By Hand



October 17, 2000

The Honorable Bart Stupak
United States House of Representatives
2348 Rayburn House Office Building
Washington, DC 20515-2201

Dear Representative Stupak:

Thank you for your October 11, 2000, letter to me expressing specific concerns relative to Accutane (isotretinoin). I wanted to respond to your letter as quickly as possible. The safe and appropriate use of prescription medicines, including Accutane, is of paramount importance to Roche.

Since the launch of Accutane in 1982, we have remained committed to carefully monitoring and helping to manage the appropriate use of Accutane. We have worked closely with the Food and Drug Administration (FDA), the dermatologic community, and other health professionals to assure the safe use of this important drug. In many respects, our current risk management program for Accutane is unprecedented in the pharmaceutical industry.

We recently presented a comprehensive analysis of the psychiatric adverse events in the Accutane-treated patient population to the FDA's Dermatologic and Ophthalmic Drugs Advisory Committee. Although the Committee did not conclude that there is proof of a causal relationship between Accutane and psychiatric conditions, it recommended that additional study and risk management steps would be appropriate given the serious nature of this issue. We are working closely with the FDA to develop and to implement effective responses to the Advisory Committee's recommendations, as follows:

1. We will provide the FDA with a proposed Medication Guide (MedGuide) on Accutane before the end of the month. This document will include warnings of birth defects as well as a discussion of psychiatric events consistent with the professional label.
2. At the same time, we will provide FDA with a revised informed consent form incorporating the psychiatric information in the current labeling.
3. As recognized by the FDA Advisory Committee, designing a scientifically sound approach to studying this matter raises complex methodological issues from both a scientific as well as social perspective. We are committed to working with FDA to design a feasible approach to study this issue and to fund that effort.

-2-

In addition to these actions, I have committed the Company to take additional steps:

1. We are exchanging packages in the market to assure that they have current labeling. We have requested a meeting with the FDA on the implementation of our plans.
2. As of today, we are discontinuing televised non-branded acne education messages directed to young people until further risk management steps, including those outlined above, have been addressed. For clarification, however, Roche does not disseminate branded direct-to-consumer advertising for Accutane to any patient population. We have conducted acne educational programs that were seen by consumers of all ages, including adults and young people. These programs do not include references to Accutane.

Patrick J. Zerner
President and Chief Executive Officer

By Hand



October 17, 2000

The Honorable Bart Stupak
United States House of Representatives
2048 Rayburn House Office Building
Washington, DC 20515-2201

Dear Representative Stupak:

Thank you for your October 11, 2000, letter to me expressing specific concerns relative to Accutane (isotretinoin). I wanted to respond to your letter as quickly as possible. The safe and appropriate use of prescription medicines, including Accutane, is of paramount importance to Roche.

Since the launch of Accutane in 1982, we have remained committed to carefully monitoring and helping to manage the appropriate use of Accutane. We have worked closely with the Food and Drug Administration (FDA), the dermatologic community, and other health professionals to assure the safe use of this important drug. In many respects

Congress of the United States
Washington, DC 20515

October 11, 2000

The Honorable Jane Henney
Commissioner
Parklawn Building
5600 Fishers Lane
Rockville, MD 20857

Dear Commissioner Henney:

We are very concerned about the recent reports of Accutane's (Isotretinoin) possible link to severe psychiatric side effects. We urge you to take swift action on a number of steps to protect the public health.

As the *Today* show segment that aired last week proved, the public has not received adequate information regarding the serious adverse psychiatric effects that may be associated with Accutane. In order to immediately increase public awareness, the FDA should:

- require all Accutane patients receive and sign an informed consent form clearly warning of Accutane's risks of depression, suicide and other psychiatric disorders every time the physician prescribes the drug;
- immediately ensure that Accutane labeling and boxes display the same warnings as the physician package insert of Accutane's risks of birth defects and of depression, suicide and other psychiatric disorders; and
- immediately issue a patient "MedGuide" with clear and prominent warnings of Accutane's risks of birth defects and of depression, suicide and other psychiatric disorders.

In addition, we are urging Hoffman La-Roche to take a number of steps and we ask that you use any resources available to the FDA to ensure its cooperation. First, we are very concerned about the lack of post market studies regarding Accutane and its link to suicide, suicide attempts, suicidal ideation and depression. Please work with Hoffman La-Roche to select and ensure independent studies are conducted in a valid scientific manner.

Letter to Commissioner Henney
October 11, 2000
Page Two

Finally, we are asking Hoffman La-Roche to cease all Direct to Consumer advertising targeted at children, until the link between Accutane and its link to suicide, suicide attempts, suicidal ideation and depression have been studied. It is irresponsible to market this very powerful drug to children without having a better scientific evidence of its effects.

We urge you to take swift action on this matter. We await your prompt reply.

Sincerely,

JPEG image 622x1210 pixels

http://www.house.gov/stupak/accutane_itr_001011henney.jpg

Congress of the United States
Washington, DC 20515

October 11, 2000

The Honorable Jane Henney
Commissioner
Parkview Building
5600 Fishers Lane
Rockville, MD 20857

Congress of the United States
Washington, DC 20515

October 11, 2000

Patrick J. Zenner
President and CEO
Hoffmann-La Roche Inc.
340 Kingsland Street
Nutley, New Jersey 07110

Dear Mr. Zenner:

We are very concerned about the recent reports of Accutane's (Isotretinoin) possible link to severe psychiatric side effects. We have written to Commissioner Henney asking her to take a series of actions with regard to Accutane and have enclosed this letter for your review. However, Hoffman La-Roche can voluntarily take these actions without action by the Food and Drug Administration (FDA). We urge you to take swift action on a number of steps to protect the public health.

As the *Today* show segment that aired last week proved, the public has not received adequate information regarding the serious adverse psychiatric effects that may be associated with Accutane. In order to immediately increase public awareness, Hoffman La-Roche should:

- require all Accutane patients receive and sign an informed consent form clearly warning of Accutane's risks of depression, suicide and other psychiatric disorders every time the physician prescribes the drug; and
- immediately ensure that Accutane labeling and boxes display the same warnings as the physician package insert of Accutane's risks of birth defects and of depression, suicide and other psychiatric disorders.

In addition, we are very concerned about the lack of post market studies regarding Accutane and its link to suicide, suicide attempts, suicidal ideation and depression. Your company should immediately fund research on this urgent issue. Please work with the FDA to select and ensure independent studies are conducted in a valid scientific manner.

Letter to Patrick J. Zenner
October 11, 2000
Page Two

Finally, we are asking Hoffman La-Roche to cease all Direct to Consumer advertising targeted at children, until the link between Accutane and its link to suicide, suicide attempts, suicidal ideation and depression have been studied. It is irresponsible to market this very powerful drug to children without having a better scientific evidence of its effects.

We urge you to take swift action on this matter. We await your prompt reply.

Sincerely,

JPEG image 620x1189 pixels

http://www.house.gov/stupak/accutane_itr_00101/zenner.jpg

Congress of the United States
Washington, DC 20515

October 11, 2000

Patrick J. Zenner
President and CEO
Hoffmann-La Roche Inc.
340 Kingsland Street
Nutley, New Jersey 07110

BART STUPAK
137 SOUTHWEST BUILDING
2245 FORTNEY BUILDING
WASHINGTON, DC 20515
PHONE: 202-225-7245
FAX: 202-225-4741
EMAIL: BOSTUPAK@mail.house.gov

Congress of the United States
House of Representatives
Washington, DC 20515-2201

COMMITTEE
ON
COMMERCE
SUBCOMMITTEE
ON
TRANSPORTATION,
INFRASTRUCTURE,
AND
HOMELAND SECURITY
CONSUMER PROTECTION
AND
SAFETY
LEGISLATION
CONGRESSIONAL
LAW ENFORCEMENT CAUCUS
REGULATORY WORK

October 11, 2000

Russell H. Ellison, M.D.
Vice President, Medical Affairs
Roche Pharmaceuticals
340 Kingsland Street
Nutley, NJ 07110-1159

Dear Dr. Ellison:

Thank you for your letter offering to meet with me to discuss your company's views regarding its analysis of adverse events prepared for the Food and Drug Administration's (FDA) advisory committee meeting. I appreciate your willingness to discuss this issue and the sympathy you expressed regarding the loss of my son.

Today, I along with seven other members of Congress wrote to Patrick Zenner, President and CEO of Hoffman-LaRoche, presenting specific recommendations Roche and the FDA should take regarding Accutane (Isotretinoin). I have enclosed a copy of the letter for your information.

I do not believe it would be appropriate to meet, until Mr. Zenner responds to the recommendations made by the Members of Congress that signed the letter. After we have received a response to our recommendations, it may be appropriate for all the co-signers of the letter to meet with representatives of Hoffman-LaRoche. I believe this process will allow for the most constructive discussions of future actions regarding the information and marketing of Accutane.

Once again, I look forward to the prompt reply of Mr. Zenner to our letter.

Sincerely,

BART STUPAK
Member of Congress

BTS/mb

Enclosure

- Please Reply To: 225 W. Washington, Washington, DC 20540
 - 360 Locomotive Street, Escondido, CA 92025
 - 616 Shields, Redondo Beach, CA 90591
 - 1718 East Fwy., Suite 2, Covington, LA 70420
 - 111 E. Corporate, Aurora, IL 60007
 - 2 Square One Street, Suite 2, Columbia Falls, GA 30528
- Phone: (800) 855-8899 FAX: (202) 225-4741

Russell H. Ellison, M.D.
Vice President, Medical Affairs



Pharmaceuticals

By Hand

October 6, 2000

The Honorable Bart Stupak
United States House of Representatives
2348 Rayburn House Office Building
Washington, DC 20515-2201

Dear Representative Stupak:

First and foremost, on behalf of Roche, I want to express the deepest sympathy for your family's loss, and that of any family who endures the profound tragedy of a young person's suicide. We believe it is both necessary and understandable that any possible cause of such an event must be considered.

Roche is a responsible and ethical company, and the safety of our products is of paramount importance. Throughout the past eighteen years we have remained committed to carefully monitoring the use of Accutane. We have always worked closely with the Food and Drug Administration, the dermatologic community, and other health professionals to assure the safe and effective use of this important prescription medication.

As you may know, Roche recently presented a comprehensive analysis of the psychiatric adverse events in the Accutane-treated patient population to the Food and Drug Administration's Dermatologic and Ophthalmic Drugs Advisory Committee. We would appreciate the opportunity to review this information with you at your earliest convenience. We would also be prepared to discuss our current efforts and ongoing plans to address this complex scientific issue.

I will contact your office today to discuss the scheduling of such a meeting. It is our hope that we can create a dialogue through which we can address your concerns and questions about the safety of Accutane.

Sincerely,

REH/eds

Roche Laboratories, Inc. 340 Kingsland Street Tel: 973-862-2380
Hoboken, New Jersey 07110-1159 Fax: 973-335-4579

OPENING REMARKS

Janice Myrella
12.5.00

I want to begin by thanking Chairman Burton and Ranking Member Waxman for bringing this issue in front of the Committee today. There is nothing that we do in this Committee room that is more important than ensuring that the medication given to individuals, especially children, is safe and effective. I cannot imagine any pain more grievous than finding out that the medicine prescribed to your child or family member actually caused them significant pain or even led to their death.

Today's hearing will hopefully enlighten all of us on the efficacy of Accutane and whether its side effects lead to depression and suicide. I know the witnesses that come before us will elucidate both the positive and negative outcomes of Accutane. This drug, which has helped thousands of individuals who had serious acne problems, may also have dangerous psychological side effects. It is essential that we look at all facets of this issue before any decision is rendered. Preventing others from benefitting from Accutane without ample evidence to the contrary would be just as pernicious as continuing to prescribe the drug if we knew it was dangerous. In the end, our objective today must be to ensure that all available information is passed onto families and patients about all possible side effects. ~~If one more individual is harmed due to lack of information then we, as a committee, would have failed in our duty.~~

and in discerning an appropriate role for our Committee

I look forward to hearing the testimony today and I yield back the balance of my time.

January 5, 2001

Office of Congresswoman Constance Morella
228 Rayburn House Office Building
Washington, D.C. 20515



BRANDON

JAN 9 2001

Dear Ms. Boepple:

Thank you so much for your call today and your concern. As I said on the telephone, my card to Congresswoman Morella was written but not sent. As you suggested, I will add to the note my concerns for the submission to the Congressional Hearing and Accutane.

As parents, we feel as the other parents on the panel felt:

1. How does the FDA track the depression/suicide cases? Do they know about our Brandon? Our doctor reported Brandon's suicide to the drug company (Roche). How is this information interpreted by (Roche) and passed on to the FDA? Will it contain all the pertinent facts? We don't think so, as noone called us about any information regarding Brandon's his life or his death. We have not contacted the FDA to report Brandon's case however, we would encourage someone from the Congressional panel to find out what information, if any has been reported and when.
2. No one has contacted us for any information other than the University of Maryland Psychiatric Research Center. Brandon's brain tissue was submitted for research. Their interests were not of the Accutane use, but more interest of Brandon's moods.
3. Brandon's life does not fit the pattern of the young female teenager who testified at the hearing. It would be wrong for the Congressional panel, FDA, and Roche to assume all parents and patients should not worry about the use of Accutane until a drastic change takes place in the patient's life.
4. Is the use of Accutane suppose to be for only severe cases of acne? Brandon's did not seem to be a "severe case." Should other treatments be tried first, and Accurate as a last resort?

This is all so painful, but we are so appreciative to all of you for your effort to get the word to others so they have a better chance to be informed, understand and save a precious life.

Please do not hesitate to call me if you have any questions. (o) (301) 951-5010
(h) (301) 654-1326

With Our Sincere Appreciation,

Jim and Aracely Troppman

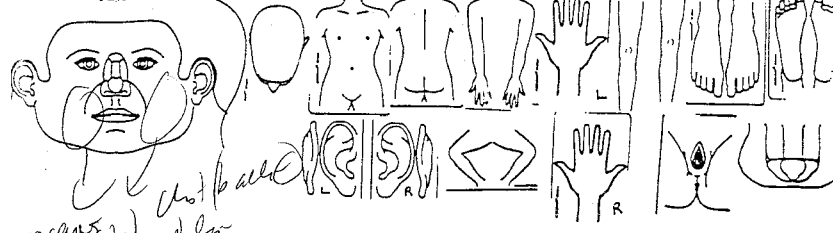
MM
INITIAL CONSULTATION

DATE: SEP 16 1999 NAME: Brandon Stoppman ACCT# IROBR-000
 CONSULTATION REQUESTED BY: Dr. G. Hallick
 Age: 18 years. Sex: M / F
 Race: Caucasian; Negro; Oriental; Middle Eastern; Other
 Chief Complaint: " acne using Accutane"
 Duration: _____ Days _____ Weeks _____ Months _____ Years
 History: _____

Previous Treatments: accutane used twice over the hands, getting scarring, pustul purpled, post x 1 year

Review of Systems: noncontributory / contributory: pmh (+)
 Skin: History of similar lesion(s) ? _____
 History of " Precancers " _____ H/O Radiation Rx: N / Y:
 History of BCC ? _____ Where ? R / L _____ When ? _____
 History of SCC ? _____ Where ? R / L _____ When ? _____
 History of Melanoma ? _____ Where ? R / L _____ When ? _____
 Atypical Nevi ? _____ Where ? R / L _____ When ? _____
 Suntan Parlor Use ? Y / N Sunscreen Use: Y / N / Occasional
 Extensive Sun Exposure ? Y / N Sunburns ? Y / N Fitzpatrick Skin Type: _____

Medicines: _____
 Illness: None; CAD; HTN; CVA; Thyroid; Diabetes; Renal; Other:
 Allergies: None; PCN; Cephalosporins; Sulfa; TCN; Erythro; Codeine; Other:
 Reactions: _____
 Family History ? Psoriasis; Seb Derm; Rosacea; Eczema; Hay Fever; Asthma
 Melanoma; Who; Nonmelanoma Skin Cancer; Atypical Nevi
 No Dermatological Disease; Other disease: _____
 Social History: Occupation; Indoor / Outdoor Tobacco: Y / N



Impression: scarring & severe cystic acne - accutane

Plan: Accutane 400mg po qd
SPF
Pls 5 week follow up
7/1/00

ABCD'S, etc DWP in Detail: Y / N Mohs Micrographic Surgery DWP in Detail: Y / N
 Sunscreens DWP in detail: Y / N
 Patient instructed to return to the office immediately for any New, Changing, Symptomatic, or Irregular lesions: Y / N
 Otherwise, return to the office in _____ days / _____ weeks / _____ months / _____ prn / _____ or schedule surgery
 Letter to patient's physician dictated ? Y / N SIGNATURE: [Signature]

PROGRESS NOTES

NAME <u>Brandon Troppman</u>		PHONE NUMBER
ADDRESS <u>MM</u>		SHEET NUMBER <u>TR0 BR-000</u>
DATE / PROBLEMS (Number and Brief Description)	FINDINGS (S = Subjective, O = Objective)	TESTS ORDERED and/or PLANNED
<u>9-28-99</u>	<u>Quest 9-25-99 lab report OK</u> <u>(M) VFT - Wt 16.5</u>	
<u>OCT 20 1999</u>		
<u>11/17/99</u>	<u>Quest 11/6/99 lab report OK</u> <u>OK</u>	
<u>DEC 03 1999</u>	<u>In home, sitting room #3 furniture</u> <u>flu</u> <u>accidents</u> <u>FE dysfunction greater</u> <u>in motion at the</u> <u>check</u> <u>Inf Home Valparaiso</u> <u>Inf: Furniture 10/99 bid</u> <u>Mrs. [unclear]</u> <u>for ins</u> <u>Value - [unclear]</u> <u>(M)</u>	
	<u>At. decreased / suicide 12/99 - DW Roche a father of</u> <u>no h/o depression</u> <u>⊖ signs of suicidal thoughts</u> <u>⊖ FH depression</u>	



1901 Sulphur Spring Road • Baltimore, Maryland 21227-0580
 Main Laboratory 410-547-9100 • D.C. Area 301-621-9900 • Outside Maryland 1-800-LAB-XCEL

ROBERT R.L. SMITH, M.D.
 Medical Director

FRAN ROTTER, M. D. (R-49441)
 FRAN ROTTER, M. D. (N2, C)
 8301 ARLINGTON BLVD. T-5
 FAIRFAX, VA 22031-0000

TROPPMAN, BRANDON
 4007 EAST WEST HWY
 BETHESDA, MD 20815
 13016541326

SPECIMEN COLLECTED: 09/25/1999 09:59
 COMPLETED REPORT: 09/27/1999 08:03

PATIENT NAME	DATE	AGE	SEX	LAB NUMBER	LAB REPORT
TROPPMAN, BRANDON	09/25/1999	15	M	Q99703517	

HEMATOLOGY:

RBC-----	4.76	M/CMM	(4.50-5.30)
HEMOGLOBIN-----	14.6	GM/DL	(13.0-17.0)
HEMATOCRIT-----	43.1	%	(37.0-49.0)
MCV-----	90	FL	(78-96)
MCH-----	30.6	PG	(25.0-35.0)
MCHC-----	33.8	G/DL	(31.0-36.0)
WBC-----	4.6	K/CMM	(4.5-13.0)
PLATELET COUNT-----	275	K/CMM	(140-440)
MPV-----	7.8	FL	(6.3-10.3)
RDW-----	12.9	%	(11.5-14.5)

CHEMISTRY:

AST-----	23	IU/L	(8-45)
ALT-----	10	IU/L	(0-45)
ALKALINE PHOSPHATASE-----	167	IU/L	(30-450)
BILIRUBIN, TOTAL-----	0.6	MG/DL	(0.2-1.5)
BILIRUBIN, DIRECT-----	0.2	MG/DL	(0.0-0.5)
ALBUMIN-----	4.5	G/DL	(3.7-5.2)

Robert R.L. Smith, M.D.

(COMPLETED)

09/27/1999 08:03

SIGNATURE
 The above laboratory studies were performed by Quest Diagnostics, Inc., 1901 Sulphur Spring Road, Baltimore, MD 21227

DATE REPORTED
 200001 (4/98)



1901 Sulphur Spring Road • Baltimore, Maryland 21227-0580
 Main Laboratory 410-247-9100 • D.C. Area 301-921-0900 • Outside Maryland 1-800-LAB-XCEL

ROBERT R.L. SMITH, M.D.
 Medical Director

FRAN ROTTER, M.D. (R-49441)
 FRAN ROTTER, M.D. (N2, C)
 8301 ARLINGTON BLVD. T-5
 FAIRFAX, VA 22031-0000

TROPPMAN, BRANDON
 4007 EAST WEST HWY
 BETHESDA, MD 20815
 13016541326

SPECIMEN COLLECTED: 11/15/1999 16:29
 COMPLETED REPORT: 11/16/1999 06:41

PATIENT NAME	DATE	AGE	SEX	LAB NUMBER	LAB REPORT
TROPPMAN, BRANDON	11/15/1999	15	M	U99384788	

HEMATOLOGY:

*RBC-----	4.30	M/CMM	(4.50-5.30)
HEMOGLOBIN-----	13.8	GM/DL	(13.0-17.0)
HEMATOCRIT-----	38.8	%	(37.0-49.0)
MCV-----	90	FL	(78-96)
MCH-----	32.0	PG	(25.0-35.0)
MCHC-----	35.4	G/DL	(31.0-36.0)
WBC-----	6.4	K/CMM	(4.5-13.0)
PLATELET COUNT-----	256	K/CMM	(140-440)
MPV-----	8.5	FL	(6.3-10.3)
RDW-----	13.3	%	(11.5-14.5)

CHEMISTRY:

AST-----	18	IU/L	(8-45)
ALT-----	8	IU/L	(0-45)
ALKALINE PHOSPHATASE-----	120	IU/L	(30-450)
BILIRUBIN, TOTAL-----	0.4	MG/DL	(0.2-1.5)
BILIRUBIN, DIRECT-----	0.1	MG/DL	(0.0-0.5)
ALBUMIN-----	4.5	G/DL	(3.7-5.2)

RESULTS WERE FAXED ON: 11/16/1999 06:43

Robert R.L. Smith, M.D.

SIGNATURE

(COMPLETED)

11/16/1999 07:19

DATE REPORTED

GONZAGA COLLEGE HIGH SCHOOL

19 EYE STREET, N.W.
 WASHINGTON, D.C. 20001
 (202) 336-7131
 FAX (202) 336-7132



REFLECTIONS ON BRANDON

It is a privilege to share with you some of the memories and recollections of Brandon by his classmates at Gonzaga High School. The Counseling staff gathered these reflections in classroom discussions, individual and small group meetings, and during informal talks with students. It is apparent that Brandon made an amazing impression on the people he met here and in a number of different ways. We have tried to organize these memories and descriptions in a way that reflects how Brandon was seen by his classmates. We came up with four descriptions of your son that, hopefully, will give you a sense of the way he is remembered and appreciated by his friends at Gonzaga:

Fun Lover

Brandon seemed to have an incredible gift for lifting people's spirits by using his sense of humor and his capacity to have fun in whatever situation he found himself. We heard over and over stories of how people loved his self-deprecating sense of humor. Students mentioned how occasionally he would fake falling down steps and playfully enjoy his classmates' reactions. It was mentioned that Brandon went out for the freshman football team and at practice one day was asked to play the front line. As you know, Brandon did not have a lineman's build. Some of the boys, who also were trying out for the team, observed that Brandon kept getting knocked down, but he kept getting up and he seemed to revel in the humorous possibilities of this experience. Even when he was cut from the team, he came to games to encourage the players. Another time it was reported by some students that Brandon had pressed his face up against the glass part of a metro train door to the delight and entertainment of his buddies who were watching from the other side. A metro security guard came along and interrupted the fun, but Brandon was able to disengage himself in humorous way without being disrespectful to the guard. A description of Brandon that was repeated again and again was his skill at using his wonderful sense of humor without putting anyone down. Many students marveled at and respected this gift.

Bridge Builder

Brandon was seen as a bridge builder between all types of students. He seemed to be able to connect to the similarities rather than the differences in people. It didn't seem to matter where they lived, whether they were into athletics or not, or what their racial background was, Brandon had a capacity to relate with all kinds of people. At some point

in the beginning of his freshman year at Gonzaga, Brandon had filled out a part of a form in which he wondered whether it would be difficult to make friends at a new school. Considering the fact that we heard over and over again about how many students knew Brandon and how well liked he was, we wonder if Brandon ever realized how much he touched people while he was here. He is remembered as a catalyst who had the ability to bring people from diverse backgrounds together.

Caregiver

Many of Brandon's classmates have described his generous spirit. We heard a number of stories where Brandon had lent his friends lunch money or had shared his lunch with someone. On one occasion, a student called Brandon at home because he needed money for a metro fare and Brandon got on his bike and rode to the station to give the money to his friend in need. We got the feeling from our conversations with many students that Brandon had an intuitive sense of when someone needed a lift and he was more than willing to try to raise a classmate's spirits through his humor, his ability to listen, and his uncanny knack for making the most of the moment.

Social Director

As has been already mentioned Brandon had an unusual ability to entertain or find entertainment in a variety of situations. Whether he was in our cafeteria, on the football field, riding metro, kibitzing on a ski slope and/or ski lift, at a mall, taking a friend to the Asian festival, or staying over night at a friend's house, he seemed to relish getting people to laugh and enjoy themselves. He was known for doing the unpredictable in a way that would help his friends relax and have fun.

All of us have been amazed by the number of people Brandon touched in the relatively short period of time he spent at Gonzaga. The comments and observations we received were exceedingly positive. Brandon will live on in a meaningful way in the memories of his many friends here. As the Easter season approaches we have the shared hope for your family that the memories of Brandon will bring you light, peace, and consolation. Brandon is dearly missed and we continue to pray for him and your family. It truly has been honor to hear the countless words of care and concern that members of our Gonzaga student community have spoken on behalf of your son and your entire family.

**Supplemental Submission
To the Record**

Hoffmann-La Roche Inc.

**Hearing on
“Accutane: Is this Acne Drug Treatment
Linked to Depression and Suicide?”**

December 18, 2000

Committee on Government Reform

U.S. House of Representatives

Hoffmann-La Roche Inc.
Supplemental Submission to the Record
December 5, 2000 Hearing
Government Reform Committee

Attachment	Topic
1	<p>Communications to Prescribers and Patients Regarding Accutane and Psychiatric Issues</p> <p><i>Overview of Roche communications to Accutane prescribers and patients regarding psychiatric events reported while on Accutane therapy. Attachments include a listing of specific changes in physician and patient labeling (Attachment 1-A), and Dear Doctor letter (Adobe Acrobat File, Attachment 1-B).</i></p>
2	<p>Educational Efforts From Roche Pharmaceuticals</p> <p><i>Overview of Roche's educational efforts for Accutane pertaining to pregnancy prevention and psychiatric events, including planned efforts with respect to the upcoming revised informed consent form and Medication Guide.</i></p>
3	<p>Accutane Indications for Use / Patient Population</p> <p><i>Response to assertions that a significant percentage of the Accutane patient population does not have the labeled indication, severe recalcitrant nodular acne.</i></p>
4	<p>Hypervitaminosis A - A Review of Central Nervous System Effects</p> <p><i>Overview of Hypervitaminosis A and important distinctions between Vitamin A (retinol) and isotretinoin.</i></p>
5	<p>Roche Comments on Testimony</p> <p><i>Responses to certain inaccuracies in the testimony of James O'Donnell, Pharm.D. regarding acne and psychiatric events.</i></p>

**Attachment 1
Roche Submission**

**COMMUNICATIONS TO
PRESCRIBERS AND PATIENTS
REGARDING ACCUTANE AND PSYCHIATRIC ISSUES**

Roche communicated directly with prescribers of Accutane as information became available concerning psychiatric events reported in patients on Accutane therapy. The attached outline (Attachment 1-A) sets forth the contents of the package insert changes regarding psychiatric events, as well as changes to the patient brochure relating to psychiatric events. It also describes Dear Doctor letters sent in conjunction with certain package insert changes. All of these changes and communications were developed and implemented by Roche in full cooperation with the Food and Drug Administration (FDA).

Prescribers

As explained by FDA, the physician package insert “is intended to provide physicians with a clear and concise statement of the data and information necessary for the safe and effective use of the drug.” 44 Fed. Reg. 37434, 37435 (June 29, 1979). It is not intended as a primary vehicle for communicating information to patients. Rather, “the information provided to patients concerning the use of a drug is often determined by the medical judgment of the attending physician.” *Id.* The physician makes that judgment based not only on the information in the package insert but on the totality of the physician’s professional expertise and familiarity with the individual patient under his or her care.

Roche sent Dear Doctor letters to prescribers to highlight specific changes and updates in the package insert. Frequently, Roche sales representatives provide package inserts to healthcare providers on whom they call. In addition, the current version of the prescribing information is published in the Physicians’ Desk Reference, a widely available volume often consulted by physicians for pharmaceutical prescribing information.

In June, 1985 Roche sent prescribers a Dear Doctor letter articulating the changes made to its package insert in June, 1985, including the addition of reports of CNS effects such as depression, to the Adverse Reactions section of the label. Also, in February 1998, Roche distributed a Dear Doctor letter to prescribers pointing out the addition of new language on depression and suicide to its package insert. In order to provide updated information to the medical profession, this letter was sent to physicians in the United States with specialties in the areas of dermatology, psychiatry, general practice, internal medicine, family practice, osteopathy, as well as emergency room physicians, although Roche representatives only called on dermatologists in 1998.

Patients

Roche has also provided patient brochures through physicians and other healthcare providers since the early years Accutane was on the market. The information contained in the patient brochure is designed to supplement the information provided by physicians to their patients and are written in consumer-friendly language. These brochures are intended to be taken home and reviewed by the patient.. As testified to at the December 5 hearing, Roche and FDA will shortly finalize a Medication Guide for Accutane, which will be made available to patients after the first of the year. The Medication Guide will contain a spectrum of information on the risks associated with Accutane therapy, including information on psychiatric events, in clear terms and an easy to comprehend format.

Attachment 1-A
Roche Submission

ATTACHMENT TO
“COMMUNICATIONS TO PRESCRIBERS AND PATIENTS
REGARDING ACCUTANE AND PSYCHIATRIC ISSUES”

I. Prescribers:

- June 1985 package insert adds under **ADVERSE REACTIONS**:

“The following CNS reactions have been reported and may bear no relationship to therapy—seizures, emotional instability including depression, dizziness, nervousness, drowsiness, malaise, weakness, insomnia, lethargy and paresthesias.”

“Dear Doctor” letter issued, including CNS effects.

- July 1986 package insert revises and adds under **ADVERSE REACTIONS**:

“The following CNS reactions have been reported and may bear no relation to therapy—seizures, emotional instability, dizziness, nervousness, drowsiness, malaise, weakness, insomnia, lethargy and paresthesias.

Depression has been reported in some patients on Accutane therapy. In some of these patients, this has subsided with discontinuation of therapy and recurred with reinstitution of therapy.”

- February 1998 package insert adds under **WARNINGS** (in bold-faced type):

“*Psychiatric Disorders*: Accutane may cause depression, psychosis, and, rarely, suicidal ideation, suicide attempts and suicide. Discontinuation of Accutane therapy may be insufficient; further evaluation may be necessary. No mechanism of action has been established for these events (see ADVERSE REACTIONS).”

Adverse Reaction language on CNS effects and depression amended as follows:

“*Psychiatric*: suicidal ideation, suicide attempts, suicide, depression, psychosis (see WARNINGS: *Psychiatric Disorders*), emotional instability. Of the patients reporting depression, some reported that the depression subsided with discontinuation of therapy and recurred with reinstitution of therapy.”

Dear Doctor letter alerts prescribers to the label change.

II. Patients:

Patient Brochure 1987:

In caps:

YOU SHOULD BE AWARE THAT ACCUTANE (isotretinoin/Roche) MAY CAUSE SOME LESS COMMON BUT MORE SERIOUS SIDE EFFECTS. BE ALERT FOR ANY OF THE FOLLOWING EARLY SYMPTOMS OF THESE CONDITIONS:

- HEADACHE, CHANGES IN MOOD, BLURRED VISION OR OTHER VISUAL DISTURBANCES, NAUSEA AND VOMITING.

.

THESE SYMPTOMS MAY BE EARLY SIGNS OF CONDITIONS WHICH, IF LEFT UNTREATED, COULD POSSIBLY RESULT IN PERMANENT EFFECTS.

IF YOU EXPERIENCE ANY OF THESE SYMPTOMS OR ANY OTHER UNUSUAL OR SEVERE PROBLEM, DISCONTINUE TAKING ACCUTANE (isotretinoin/Roche) AND CHECK WITH YOUR DOCTOR AS SOON AS POSSIBLE.

Patient Brochure 1997:

Under “**For All Patients**”:

- If you have a family or personal history of medical conditions such as diabetes, liver disease, heart disease or depression, please inform your doctor.

In caps:

• YOU SHOULD BE AWARE THAT ACCUTANE MAY CAUSE SOME LESS COMMON, BUT MORE SERIOUS, SIDE EFFECTS. BE ALERT FOR ANY OF THE FOLLOWING:

- HEADACHES, NAUSEA, VOMITING, BLURRED VISION
- CHANGES IN MOOD

.....

IF YOU EXPERIENCE ANY OF THESE SYMPTOMS OR ANY OTHER UNUSUAL OR SEVERE PROBLEMS, DISCONTINUE TAKING ACCUTANE AND CHECK WITH YOUR DOCTOR IMMEDIATELY. THEY MAY BE THE EARLY SIGNS OF MORE SERIOUS SIDE EFFECTS WHICH, IF LEFT UNTREATED, COULD POSSIBLY RESULT IN PERMANENT EFFECTS.

Patient Brochure 2000:

Under “**For All Patients**”

- Inform your prescriber if you have a family or personal history of medical conditions such as depression (mood swings, suicidal thoughts or suicide attempts), diabetes, obesity, alcoholism, liver disease or heart disease.

In caps:

IMPORTANT INFORMATION

YOU SHOULD BE AWARE THAT CERTAIN SERIOUS, UNWANTED EVENTS HAVE BEEN REPORTED IN ACCUTANE PATIENTS. THE EVENTS INCLUDE:

- CHANGES IN MOOD, DEPRESSION, AND RARELY SUICIDAL THOUGHTS, SUICIDE ATTEMPTS AND SUICIDE

.....

IF YOU EXPERIENCE ANY OF THESE EVENTS OR ANY OTHER UNUSUAL OR SEVERE PROBLEMS, DISCONTINUE TAKING ACCUTANE AND CHECK WITH YOUR PRESCRIBER IMMEDIATELY. THEY MAY BE THE EARLY SIGNS OF MORE SERIOUS MEDICAL PROBLEMS WHICH, IF LEFT UNTREATED, COULD POSSIBLY RESULT IN PERMANENT EFFECTS.



Dear Doctor:

Please be advised of important changes to the prescribing information for ACCUTANE® (isotretinoin).

The information pertaining to Adverse Experience reports of depression, which has appeared in the ADVERSE REACTIONS section of the prescribing information, will now also appear in the WARNINGS section. The following revisions will be made:

- The WARNINGS section will now begin with the following paragraph in bold type:
"Psychiatric Disorders: Accutane may cause depression, psychosis and, rarely, suicidal ideation, suicide attempts and suicide. Discontinuation of Accutane therapy may be insufficient; further evaluation may be necessary. No mechanism of action has been established for these events."
- The paragraph on depression in the ADVERSE REACTIONS section will become paragraph 5 of that section and will be revised as follows:
"In the post-marketing period, a number of patients treated with Accutane have reported depression, psychosis and, rarely, suicidal ideation, suicide attempts and suicide. Of the patients reporting depression, some reported that the depression subsided with discontinuation of therapy and recurred with reinstatement of therapy."

It is important to note that reports of these Adverse Experiences are uncommon but, because of their potential consequences, clinicians should be attentive to any new behavioral signs and symptoms.

Please consult the revised complete product information for Accutane, which is enclosed. If you have any questions about Accutane, we encourage you to call the toll-free number for Roche Medical Services at 1-800-526-6367. Also, if you are aware of any serious Adverse Experiences potentially associated with the use of Accutane, please report such information to Roche at the above number or to the Food and Drug Administration MedWatch program at 1-800-FDA-1088.

Sincerely,

A handwritten signature in cursive script, appearing to read "Russell H. Ellison".

Russell H. Ellison, MD
Vice President
Medical Affairs

16-004-023-016-028

Roche Laboratories Inc.

340 Kingsland Street
Nutley, New Jersey 07110-1199

Attachment 2
Roche Submission

EDUCATIONAL EFFORTS FROM ROCHE PHARMACEUTICALS

Pregnancy Prevention

In response to the Food and Drug Administration's (FDA's) 1988 request for additional warnings regarding Accutane's risk of birth defects, Roche Pharmaceuticals created and adopted a comprehensive Pregnancy Prevention Program (PPP) Kit to address the educational needs for women taking Accutane. This program consists of a kit for prescribers which contains:

- Patient Qualification Checklist
- Information for Patients (Patient Brochure)
- Patient Alertline Information
- Contraception Information
- Referral Document to OB/GYN
- Physician's Guide to Consent
- Patient Self-Evaluation Test
- Consent and Survey Enrollment Form
- Reorder Forms For Patient Elements

This kit was sent out from 1988 through 1997 to every dermatologist as well as any prescriber who had written at least one prescription for Accutane.

Roche also added the "Avoid Pregnancy" Logo and a Female Informed Consent to the Accutane package insert in 1988.

During 1997, in response to dermatologists' requests, Roche developed individual patient folders that contain all of the above elements. Additionally, a reorder mechanism through a 1-800 telephone number is implemented, as well as creation of a journal advertisement for nurses and physicians focusing on the availability of the Pregnancy Prevention Program and the 1-800 telephone number.

Beginning in 1996, to supplement the Pregnancy Prevention Program, Roche instituted "Pregnancy Prevention Month" for the month of July for each year thereafter. During this month, all Roche dermatology sales representatives visit every dermatology residency program (approximately 100) in their territory and provide an overview of the Pregnancy Prevention Program and how to implement it in their offices. Additionally, a video was created in 1998 for the physician to keep which details how to utilize the program.

Psychiatric Events

In February 1998, Roche agreed to change the language regarding depression and suicide in the Accutane label. A Dear Doctor letter was mailed to all dermatologists, general practitioners, family practitioners, osteopaths and psychiatrists in the U.S. describing the label.

Further, the Roche dermatology sales representatives received instructions to destroy specific promotional materials, which contained out-dated labeling information.

MedGuide and Informed Consent for All Patients

Upon approval by the FDA of a MedGuide and Informed Consent for All Patients, Roche will issue a Dear Doctor and a Dear Pharmacist letter. This mailing will include over 350,000 physicians, 130,000 pharmacists and 55,000 pharmacies. Additionally, each physician and pharmacist will receive multiple copies of the MedGuide and Informed Consent for All Patients. A brief overview of the narrative for each follows:

- **“Dear Doctor”** -- detail of what information is included in the MedGuide and Informed Consent for All Patients; instructions that the Informed Consent is divided into two sections, one for females only and one for all patients
- **“Dear Pharmacist”** -- information highlighting the fact that a MedGuide and Informed Consent for All Patients has been issued for Accutane; explanation that all patients should receive a MedGuide at the time Accutane is dispensed; and explanation that all patients who have received a prescription for Accutane will have necessarily signed an Informed Consent relating all of the adverse event information for Accutane in the physician’s office.

Roche Pharmaceutical’s dermatology sales force will contact each dermatology office, as well as other Accutane prescribers in their territory, to deliver additional supplies of the MedGuide and Informed Consent and will provide an opportunity to answer any questions relating to these documents.

**Attachment 3
Roche Submission**

ACCUTANE INDICATIONS FOR USE/PATIENT POPULATION

The package insert for Accutane specifies that the indication for Accutane is for patients with severe recalcitrant nodular acne. Testimony presented at the December 5, 2000 Committee on Government Reform hearing on Accutane implied that a significant percent of the prescriptions for Accutane are for patients that do not have this indication. This inference is speculative and not supported by the data.

Misconceptions regarding the Accutane patient population may arise from a 1990 Food and Drug Administration (FDA) memorandum based on an earlier analysis by David Graham, Ph.D. (an FDA epidemiologist) presented at an FDA Advisory Committee meeting on April 26, 1988 as well as the FDA Advisory Committee meeting on June 20, 1990. The analysis presented was disputed in 1988 and 1990 on the basis that the assumptions made were erroneous.

The memorandum from Dr. Graham calculating the number of patients with severe recalcitrant nodular acne drew inferences to estimate multiple variables, extrapolated estimates from only part of the information in survey databases and then performed scientifically unsound manipulations. First, the data were based on an epidemiological incidence study of dermatological patients called the National Health and Nutritional Examination Survey (NHANES) conducted in 1971-1974 that included a skin examination of a sample of about 20,000 U.S. residents. The calculation presented in the memo used a top-level summary of the data based on just one diagnostic code. However, the survey data collected had more detail on not only the diagnosis of severe acne but also documented how many patients had acne cysts (nodules), and how many had acne scars or both cysts and scars. Based on these 1974 NHANES calculations, (Stern et al. 1992) the number of US residents in 1974 that had a sufficiently serious indication of acne, which included acne cysts and scars, that would potentially be treatable with Accutane, is 0.8 million women and 1.3 million men. This number significantly exceeds the number of patients treated with Accutane currently. The prevalence of severe acne was estimated by NHANES and other epidemiological sources to be approximately 1.9% of the US population (see FDA Advisory Committee Briefing Document dated September 18, 2000).

In the calculation for prevalence, Dr. Graham used several other assumptions that were subsequently disputed (see Briefing documents supplied to FDA Advisory Committees convened on April 26, 1988 and May 21, 1990). The extrapolation for the population size was drawn from 1973 data and did not allow for population growth from 1973 to 1988 when he developed his calculations. Secondly, Graham assumed that severe acne had a 10-year chronicity based on publications that did not in fact measure the chronicity in 29 patients. Since the prevalence rate is dependent on how long the disease is evident in a population, the inaccurate use of chronicity affects the prevalence calculation. There

is a considerable variation in the duration of acne based on gender, age and other factors. Thus, modeling of incidence based on a defined chronicity is highly arbitrary. Thirdly, Graham based his calculations on the number of males and females that have been observed to suffer from severe acne in clinical trials and not on observations of the population. Using a calculation from a clinical trial is incorrect, as the people in a clinical trial may not be precisely representative of the population with the relevant disease.

A corrected epidemiological analysis on the prevalence of acne has been published¹. In addition, in the briefing document for the FDA Dermatology Advisory Committee for September 18, 2000, Roche presented epidemiological evidence, survey results and additional information showing that about 85% of the prescriptions for Accutane are for severe recalcitrant nodular acne. A small percentage of the prescriptions are for oncological indications and others are for less severe acne.

In summary, there is no direct evidence that Accutane is being prescribed in a significant number of patients for indications other than that for severe recalcitrant nodular acne. Moreover, given that Accutane is indicated for recalcitrant acne -- meaning acne that has been previously treated unsuccessfully -- physicians should not be prescribing Accutane on the patient's first visit. We know from two Federal surveys, the National Ambulatory Medical Care Survey and the National Hospital Ambulatory Medical Care Survey, that less than 10% of patients receive Accutane on their first visit to a dermatologist for acne, and female patients are 3.5 times more likely to receive antibiotics over Accutane at any visit to a dermatologist.

When Roche surveyed dermatologists as to the indication for which they prescribe Accutane, dermatologists responded that they prescribed Accutane only 56% of the time to their severe acne patients. For the remaining patients with severe acne, the dermatologists surveyed treat with other modalities such as antibiotics. Female Accutane patients who enrolled in the Slone survey were asked what type of acne they thought they had. Of those that replied to the survey, approximately 85% reported they had severe acne. The information available indicates that the predominate use of Accutane is within the parameters of the disease prevalence, appropriate medical management and appropriate prescribing practices.

Only those patients that have severe recalcitrant nodular acne should receive Accutane. The professional product label fully defines this indication as follows:

“INDICATIONS AND USAGE: *Severe recalcitrant nodular acne*: Accutane is indicated for the treatment of severe recalcitrant nodular acne. Nodules are inflammatory lesions with a diameter of 5 mm or greater. The nodules may become supportive or hemorrhagic. “Severe,” by definition, means “many” as opposed to “few or several” nodules. Because of significant adverse effects associated with its use, Accutane should be reserved for patients with severe nodular acne who are unresponsive to conventional therapy.”

¹ Robert Stern. 1992. The prevalence of acne on the basis of physical examination. J. Amer. Acad. Dermatol. 26; 931-935.

including systemic antibiotics. In addition, for female patients of childbearing potential, Accutane is indicated only for those females who are not pregnant (see boxed CONTRAINDICATIONS AND WARNINGS).”

The Accutane Medication Guide and the Informed Consent for Accutane Patients that will be released shortly will also indicate in appropriate terms that Accutane should only be used in severe nodular acne patients that have previously been treated with other medications such as antibiotics.

**HYPERVITAMINOSIS A
A REVIEW OF CENTRAL NERVOUS SYSTEM EFFECTS****Introduction**

Vitamin A (retinol) is a fat-soluble vitamin that is essential for the proper functioning of vision, reproduction and maintenance of epithelial tissues, including the skin. Nutritional deficiencies of vitamin A induce skin changes that indicate its importance in normal skin functioning. The recommended daily allowance (RDA) of vitamin A for individuals over 11 years of age is 5000 IU for men and 4000 IU for women.

Retinol is produced by reduction of the retinaldehyde that is the product of cleavage of β -carotene. Vitamin A metabolites such as retinoic acid or isotretinoin (*13-cis*-retinoic acid) cannot be converted back to retinaldehyde (and then to retinol) by reduction *in vivo* (in the body). Retinoic acid appears to be one of the active metabolites responsible for many of the genomic effects of vitamin A but it cannot replace retinol as a visual pigment precursor (retinaldehyde) or substitute for retinol in the support of reproduction.¹

The exact mechanism of action of retinol is unknown, although its action likely involves its lipid properties and the unique pattern of metabolites formed. The majority of the metabolites of retinol are either retinyl esters or retinoids of which small minorities such as retinoic acid (*all-trans*-retinoic acid or tretinoin) are biologically active through a mechanism of action mediated by retinoid receptors. Although retinoids are similar to retinol, the biological activity, the metabolism and mechanisms of action differ.

Vitamin A Distinguished from Isotretinoin

Since vitamin A (retinol) cannot be produced from isotretinoin or other retinoic acids, it cannot contribute to the side effects of isotretinoin. In addition, the metabolic pathways of Vitamin A and isotretinoin are distinct. Consequently, the therapeutic effects of these molecules are also distinct. Thus, it is scientifically misleading to directly compare the effects of excessive vitamin A ingestion to the effects seen from therapeutic dosing with isotretinoin.

It is particularly important to note that vitamin A (retinol) cannot be substituted to produce the effect that isotretinoin has on severe recalcitrant nodular acne. Isotretinoin produces a pattern of active metabolites that bind to retinoic acid receptors and are responsible for its unique therapeutic benefits. These patterns of isotretinoin metabolites differ significantly from that of Vitamin A. The labeling of Accutane is thus based not on that of retinol, but on the observations of effects and reactions that are observed during the original clinical trials and during post-marketing surveillance. In the original clinical trials with isotretinoin there were only a small number of reports of symptoms of

depression. As indicated in the files from the original NDA, there were no significant CNS effects of isotretinoin reported when it was administered at 30 times the expected therapeutic doses outside of marginal stimulation. Evaluation at higher doses in mice is not possible due to toxicity.

Hypervitaminosis A

The condition resulting from excess ingestion of vitamin A (hypervitaminosis A) can be acute or chronic. In both cases, the mechanism appears to be the effect of free or loosely bound retinol on cell membranes. Retinol is normally bound to a specific carrier protein in serum, RBP (retinol binding protein) in which form it has no surface-active properties. However, in situations of retinol excess over RBP, the excess retinol is only loosely bound to other serum lipoproteins, and in this form it has potential toxic effects on cell membranes.

The earliest reports of the health effects of hypervitaminosis A were among Arctic explorers who reportedly consumed polar bear livers and suffered dramatic, though nonfatal, consequences, including hysteria (for a review, see Landy²). It is known that polar bear livers contain up to 25,000 IU/g of vitamin A, so that 100g in a meal would provide a poisonous dose of 2.5 million IU of vitamin A.³ There are, however, other potential explanations for these reports of hysteria including lead poisoning from the solder used in the explorers' canned foods, alternative toxins in the bear livers, tryptophan poisoning or stress-induced issues.

Hypervitaminosis A typically presents with multiple symptoms. Central nervous system (CNS) effects reportedly observed in patients treated for skin diseases or oncological indications with extremely high amounts of vitamin A included drowsiness, irritability, and severe headaches. It is not clearly established whether these CNS effects were a primary result of hypervitaminosis A, or whether they were psychiatric symptoms that followed secondarily from the chronic -- and at times extreme -- changes in the skin, hair, nails, bones etc. and other debilitating effects. More importantly, there are no well-documented pharmacological properties of vitamin A that would point to a causal connection to diagnosed psychiatric conditions.

A clearer picture of hypervitaminosis A has emerged since high doses of the vitamin began to be utilized in clinical settings. A summary of signs of acute hypervitaminosis A are presented in Table 1.⁴

Table 1: Acute Hypervitaminosis A

• Skin changes	• Anorexia
-Dryness	• Nausea
-Scaling	• Vomiting
-Brittle nails	• Increase CSF pressure
• Ataxia	-Papilledema
• Lethargy	-Headache
• Visual disorientation	-Drowsiness

In general, although the reported incidence of hypervitaminosis A has remained fairly constant over the last five decades, significantly higher incidences were recorded in the period 1950-1959 with the widespread use of a high potency infant prescription formula and again in the 1970s when high doses of vitamin A were used as therapy for dermatological disorders (excess amounts were found to have some therapeutic advantage in skin diseases, such as psoriasis and other disorders of keratinization, and some skin cancers such as basal cell carcinomas).⁵ Since vitamin A was replaced by synthetic retinoids for treating dermatoses, the majority of reports of hypervitaminosis A have resulted from overuse of supplements or, rarely, by excess dietary intake.

The toxic effects of chronic hypervitaminosis A are readily reversible when the intake of vitamin A is reduced or stopped.

In general, intakes of five times the RDA over short periods (2-3 weeks) can raise serum vitamin A levels outside the normal range (0.7 to 2.79 $\mu\text{mol/L}$). When the extra intake is discontinued the levels return rapidly to normal. The most common symptoms of chronic hypervitaminosis A, in addition to the hepatic effects such as hepatomegaly, portal hypertension, splenomegaly and cirrhosis, are summarized in Table 2.⁴

Table 2: Chronic Hypervitaminosis A

• Skin changes	• Gastrointestinal symptoms
-Cheilosis	• Anorexia
-Desquamation	• Cirrhosis
-Alopecia	• Bone and muscle pain
• Confusion	• Teratogenic effects
• Irritability	• Hypercalcemia
• Headache	• Hyperlipemia
• Intracranial pressure	• Weight loss

As mentioned previously, the incidence of chronic hypervitaminosis A remains fairly constant despite wide dissemination of information on the hazards of excessive intake of

the vitamin. Doses involved vary widely. For example, in a retrospective study of 41 patients with hepatotoxicity,⁶ the precise daily intake, in IU, was known for 27 cases and ranged from 20,000 to 400,000 with a mean of $95,800 \pm 17,200$. The duration of use ranged from 0.2 to 15 years with a mean of 7.17 ± 1.21 . The mean total dose was $229 \pm 57.7 \times 10^6$ IU. In certain individuals, 25,000 IU (about 5 times the RDA), daily over a period of 6 years (total about 55×10^6) led to cirrhosis. Thus a dose of only 5-fold greater than the RDA can have toxic consequences if taken for a sufficiently long time. These findings point to the total accumulated dose of vitamin A as the critical factor. The response to vitamin A is extremely variable even under the strict conditions of clinical trials for advanced cancer. Twelve patients receiving 200,000 IU/m²/day (about 40 times RDA) of retinol reported CNS effects such as confusion (4%), headaches (3%), depression (3%) and dizziness, hallucination, seizures, papilledema, and nausea (all 1%). The mean onset was 12 days but the range was very large (1 to 240 days). All symptoms resolved within 2 weeks of stopping treatment.⁷ In another trial in which five patients were treated for advanced cancer with 240,000 to 350,000 IU/m²/day (about 45 to 70 times RDA) of retinol, neuropsychiatric adverse events reported in three patients were: occasional but persistent headaches, emotional lability with easy irritability, bouts of depression, and anxiety. There was no symptomatic evidence of intracranial hypertension. No causal relationship was established between Vitamin A and these CNS effects, which could have resulted from the underlying disease or other treatments. The CNS effects reversed in all three patients within 4 weeks of retinol discontinuation.⁸ In other clinical trials at similarly high doses, CNS effects were relatively rare, e.g., less than 5% reporting headache on treatment with 300,000 IU/day retinyl palmitate for lung cancer chemoprevention⁹ and 3 of 13 patients with headache and one with emotional lability/depression during combination treatment with 300,000 IU/day retinyl acetate and tamoxifen (10 mg TID) for metastatic breast cancer.¹⁰

In literature reviews of individual anecdotal reports of vitamin A/retinoid toxicity, the most consistently cited CNS side effect is headache, which is sometimes a precursor to benign intracranial hypertension (pseudotumor cerebri).^{11,12,13,14}

In case reports, chronic vitamin A toxicity similarly presents as a very heterogeneous condition. The reports in the literature are by their very nature unreliable, and vary greatly in terms of dosing, time of relationship to onset of adverse events, severity and duration of events, and patient history. It is difficult to draw concrete scientific conclusions from reports of this type.

A critical review of the literature on hypervitaminosis A can be found in Bauerfiend.¹⁵ Between 300 and 400 published reports exist. Evaluation of these reports is complicated by (a) a great deal of redundancy in that the same case may appear in several publications; (b) uncertainty about the dose of vitamin A ingested due to the reticence on the part of the self-medicating patient or dosing parent to admit actual intakes; (c) inaccurate diagnosis by the physician; (d) confounding factors such as concomitant ingestion of high levels of vitamin D, in many cases described in children, so that the toxic effects cannot be ascribed solely to one or the other vitamin; (e) lack of information about the possible presence of additional risk factors for psychiatric diseases. Nevertheless, one can conclude that the CNS effects of excess levels of vitamin A are

tolerable in the vast majority of cases given the lengthy periods of time over which they continue to self-medicate. There appear to be no cases of chronic hypervitaminosis A where suicidal ideation or suicide was involved.¹⁶ Effects are also readily reversible. In light of the presumed association between hypervitaminosis A and intracranial hypertension it is reasonable to conclude that the most common CNS side effect, headache, is a precursor to the more serious condition. A basis for other reported neuropsychiatric adverse events, confusion, irritability, depression, which are very rare, is unknown and a plausible biological mechanism does not exist. There are, furthermore, many cases where no CNS effects have been reported despite overt signs of vitamin A intoxication.

Conclusion

There are multiple case reports of hypervitaminosis A in the literature. Sufficient clinical evidence also exists to distinguish the important differences between retinol and retinoids such as isotretinoin. Although there has been no plausible mechanism of action proposed for either retinol or isotretinoin with respect to an association with psychiatric events, these compounds are quite different, and one cannot extrapolate from one compound to the other in assessing such events.

REFERENCES

-
- ¹¹ Dowling JE, Wald G. The biological function of vitamin A acid. *Proc Natl Acad Sci* 1960;46:587-608.
- ² Landy D. Pibloktoq (hysteria) and Inuit nutrition: possible implication of hypervitaminosis A. *Soc Sci Med* 1985;21:173-185.
- ³ Rodahl K. Toxicity of polar bear liver. *Nature* 1949;164:530.
- ⁴ Leo MA, Lieber CS. Hypervitaminosis A: A liver lover's lament.
- ⁵ Bendich A, Langseth L. Safety of vitamin A. *Am J Clin Nutr* 1989;49:358-371.
- ⁶ Geubel AP, De Galocsy C, Alves N, Rahier J, Dive C. *Gastroenterology* 1991;100:1701-1709.
- ⁷ Goodman GE. Phase II trial of retinol in patients with advanced cancer. *Cancer Treat Rep* 1986;70:1023-1024.
- ⁸ Goodman GE, Alberts DS, Earnst DL, Meyskens FL. Phase I trial of retinol in cancer patients. *J Clin Oncol* 1983;1:394-399.
- ⁹ Pastorino U, Chiesa G, Infante M, Soresi E, Clerici M, Valente M, Belloni PA, Ravasi G. Safety of high-dose vitamin A. Randomized trial on lung cancer chemoprevention. *Oncology* 1991;48:131-137.
- ¹⁰ Resasco M, Canobbio L, Trave F et al. Plasma retinol levels and side effects following high-dose retinyl acetate in breast cancer patients. *Anticancer Res* 1988;8:1319-1324.
- ¹¹ David M, Hodak E, Lowe NJ. Adverse effects of retinoids. *Med Toxicol* 1988;3:273-288.
- ¹² Snodgrass SR. Vitamin neurotoxicity. *Molec Neurobiol* 1992;6:41-73. *Hepatology* 1988;8:412-417.
- ¹³ Lombaert A, Carton H. Benign intracranial hypertension due to A-hypervitaminosis in adults and adolescents. *Eur Neurol* 1976;14:340-350.
- ¹⁴ Olsen JA. Adverse effects of large doses of vitamin A and retinoids. *Seminars in Oncology* 1983;10:290-293.
- ¹⁵ Bauernfeind JC. The safe use of vitamin A. A report of the International Vitamin A Consultative group (IVACG). Washington DC: The Nutrition Foundation, 1980.
- ¹⁶ Bush ME, Dahms BB. Fatal hypervitaminosis A in a neonate. *Arch Pathol Lab Med* 1984;108:838-842.

Attachment 5
Roche Submission

The following discussion reviews Roche's analysis of the testimony of James O'Donnell, Pharm.D., entitled, "Accutane – Is this Acne Drug Treatment Linked to Depression and Suicide?", delivered to the Congress of the United States, House of Representatives, Committee on Government Reform, Tuesday, December 5, 2000.

Acne

The description of the pathogenesis of acne is inaccurate. There are many reviews in the literature on disorders of the pilosebaceous unit (see reference by Pochi¹) that are more clinically precise, widely accepted and informative in the context of the questions leading to this hearing. In addition, there is no mention of the disfiguring and scarring aspects of severe nodular acne in the testimony.

Hypervitaminosis A

In testimony regarding hypervitaminosis A, there were important inaccuracies in the interpretation of the scientific literature. Included in this submission is a literature review of hypervitaminosis A. By definition, only retinol, and by extension retinyl esters, qualify as being "Vitamin A". "Retinoids" refers to molecules, such as retinaldehyde and retinoic acid and include the several thousand related synthetic compounds, which have varying degrees of activity. Central Nervous System (CNS) effects resulting from hypervitaminosis A are typically minor with the exception of pseudotumor cerebri, the high incidence of which in patients that consume excess amounts of vitamin A makes a causal connection possible. While these conditions are described in case reports in the Vitamin A literature, such mentions are rare and, in most cases, no CNS effects are described in these reports despite overt signs of hypervitaminosis A-related toxicity. The claim by the witness of "biological plausibility," therefore, is not justified based on a scientific review of the literature.

Schizophrenia

The relationship posited in testimony between retinoids and schizophrenia based on the analysis of work by A. Goodman is highly speculative and is unsupported by a careful review of the literature. According to these hypotheses, the proposed connection between retinoids and schizophrenia is based on the speculation that schizophrenia is a neurodevelopmental disorder that can be modulated by retinoids. Currently, the most widely respected hypothesis concerning the pathogenesis of schizophrenia is that

¹ Pochi PE Annu Rev Med 1990;41:187-98 The pathogenesis and treatment of acne.

neurological changes during embryonic development are only one of the many possible but as yet unproven components of the etiology of the disease. In addition, there is no evidence that a disease whose origins are in the midgestational period of development should be affected by vitamin A or retinoids in the adult. A second hypothesis presented during the testimony posits that the close proximity on the chromosome of retinoid receptor genes and genes associated with schizophrenia may lead to these genes being components of the same signaling pathway. Retinoic acid cascade genes and schizophrenia candidate genes should not be presumed to be related simply by their chromosomal contiguity, a hypothesis that has been disproved as a result of molecular biological techniques. The third hypothesis presented in testimony is that there is some physiological relationship between the congenital defects induced by retinoids and the symptomology of schizophrenia patients. While retinoid congenital defects do affect normal brain development due to their effects on homeobox and HOX genes during embryonic development, there is no connection between these genes and those of schizophrenia. These genes are no longer active in adult brains and, thus, cannot be activated by retinoids in adult brains.

Testimony concerning schizophrenia contained numerous other inaccuracies. For example:

- The referenced Kapur 1996 paper contains no mention of RXR or dopaminergic neurons in mice.
- The assertion that “among the many genes shown to be targets of retinoic acid are dopamine and serotonin, both of which have been proposed as candidate schizophrenia genes” is scientifically inaccurate. Retinoic acid can modulate dopamine receptor levels in artificial systems such as, organ cultures of neural tissue or in transgenic mice models without retinoid receptors, but this does not establish an interaction among these components in the adult brain.
- The argument that “retinoic acid affects dopaminergic systems and dopamine is involved in diseases such as, Parkinsonism and schizophrenia”, and therefore, “retinoic acid, or its dysregulation, is a possible cause of these diseases” is logically flawed. The simple assertion of this logic does not establish a scientifically valid causality².

Accutane and Depression

The section of testimony implying an association between Accutane use and depression is highly problematic. The first paragraph alone, cites 24 published cases of “psychological distress” and relates that data with the “...emergence of depression with features similar

² In the paragraph on pharmacokinetics, the reference (Nulman I, Berkovitch M, Klein J.

Pediatrics 1998;38:926-930) was incorrect. The reference did not contain the information cited in the sentence.

to that of hypervitaminosis A.” Psychological distress or mood disorder is transitory, involves a situational response, and is the least serious psychological condition cited in the DSM4r. Depression is a continuous feeling of helplessness characterized by exacerbation and remissions that are cyclical in nature requiring medical intervention. Using the terms interchangeably inevitably leads to inaccurate scientific conclusions.

At no point does the testimony refer to the relationship between severe acne and depression. Any balanced discussion of severe acne, therapies for severe acne and depression/suicide is incomplete without a consideration of that relationship (e.g., Gupta & Gupta *Br J Dermatol* 1998;139:846-50; Kellett & Gawkrödger *Br J Dermatol* 1999;140:273-82). In addition, peer reviewed literature strongly supports the alleviating effect that successful acne therapy has on depression (e.g., Rubinow et al. *J Am Acad Dermatol* 1987;17:25-32). Any discussion between acne and depression must also be considered against the extremely high background prevalence of mood disorders such as depression in the treated population. The analysis of Dr Robert Nelson presented at the Food and Drug Administration (FDA) Dermatology Advisory Committee on September 19, 2000, for example, illustrated that the signals for depression or suicide cannot be clearly distinguished from this background. In addition, a recently published study by Jick et al. (*Arch Dermatol.* 2000;136:1231-1236) showed no evidence that use of isotretinoin is associated with an increased risk of depression, suicide, or other psychiatric disorders.

Adverse Drug Reaction Reports

This section of the testimony refers to a pharmacoepidemiological analysis of Accutane conducted by Dr. Middlekoop and published in a book edited by Dr. O'Donnell.³ In the testimony, a comparison of psychiatric adverse drug reactions is made between various antibiotic therapies and Accutane. This comparison can be criticized on a number of grounds. First, in analyzing adverse event reports, quantitation (percent of total use) is not a scientifically accepted method of comparison. It is the content of these reports and not the absolute number of reports that provides the greatest value in analyzing adverse drug reactions. The adverse drug reaction data presented is derived from the World Health Organization (WHO), the United Kingdom Medicines Control Agency, and Roche. The WHO data is tertiary (e.g. extracted from secondary sources, all of which has been edited previously) and is submitted to them periodically by regulatory authorities. At least with respect to the FDA, data is sent to WHO with no narrative and is therefore of low interpretive value. Without any narrative or further description, characterizing headache, dizziness, and fatigue as psychiatric events without case review is problematic and likely to result in misclassification. There are also numerous issues that complicate any analysis of adverse events on commonly used drugs, including the number of described manifestations that are likely to be reported on any commonly used drug that has been available on the market for over 18 years.

With respect to the comparisons made in the testimony between Accutane and antibiotic treatment, with the exception of a single case, it is impossible to differentiate antibiotics

³ Middlekoop, T. *Drug injury, Liability, Analysis and Prevention*; Lawyers and Judges Publishers, Tuscon,

used for acne as compared to antibiotics used for any other indication. Moreover, the antibiotics listed and reported in the WHO data were not differentiated by prescriptive use or patient population which compromises both the analysis and any conclusions drawn from the analysis conducted by Dr. Middlekoop.

Dr. Middlekoop's data was drawn from a biased database, which significantly reduces the validity of her analysis. Spontaneous reports by their very nature were never intended to be used in an epidemiological interpretation of relative risk. Adverse drug reaction reports are not valid numerators and the prescription estimations in the tables cited are not valid denominators. Therefore, any approach using this methodology of comparison is invalid. There are more appropriate and scientific methodologies such as; internal proportionality testing that could be used to compare adverse drug reactions between therapies.

The psychiatric issues reported as being associated with Accutane use are very difficult to analyze, not only because of the emotional issues involved, but also because there are so many potential and credible competing causes. Accurate analysis of psychiatric conditions such as depression is further confounded when the condition studied is relatively common.

Even though no causal relationship has been established between Accutane use and psychiatric symptoms, any potential relationship has to be taken extremely seriously. Dr. Middlekoop's analysis, therefore, is particularly problematic because it serves to distract attention from a more rigorous scientific review of valid data. The report does provide a reference to a 1983 article on methods of analysis of adverse event reports and states that not much has changed in 20 years. Again this is a misleading statement since, with the advent of computers, the availability of large patient databases, the development of new methods of epidemiological analysis and structured reporting systems, vast improvements have been made. Roche has also analyzed epidemiological information available on databases in two major epidemiological studies: (1) Prescription Symmetry Analysis presented at the September 19, 2000 FDA advisory committee meeting; and (2) Jick et al. 2000 Archives of Dermatology 136; 1231 - 1236). In addition, Roche is committed to continue to study any potential relationship between Accutane use and psychiatric symptoms in conjunction with FDA and the National Institutes of Health.

CAROLINA

PRIMARY & URGENT CARE

1503 East Broad Street • Statesville, North Carolina 28677
 (704) 871-9731 • Fax (704) 871-1105

Steven F. Wolfe, M.D., FAAD, ABD

Board Certified - Dermatology

TO: Congressional Hearings on Accutane
RE: A dermatologist's view of Accutane
FROM: Steven F. Wolfe, M.D., dermatologist
DATE: 7 February 2001

I am aware of the issues regarding accutane both in the lay press and in congressional hearings. My understanding of the issue is that a senator's son, who was taking accutane, committed suicide and the suicide is being attributed to accutane. Further, I am aware of the package warning of the potential issue of psychiatric disturbance and the risk of suicide that has been on the labeling for accutane since 1998.

As a practicing dermatologist who has prescribed accutane since 1993, this drug has had some of the best results of any drug used in all of dermatology and for that matter in all of medicine. In fact, I can attest to the hundreds of lives that I have helped in immeasurable ways. These were lives ravaged by the devastating effect of chronic, severe, scarring acne. Now, the majority of these patients live acne free, a virtual miracle in their minds.

While it is tragic that there have been reports of suicide and psychiatric disturbance in patients receiving accutane they remain just that reports. If a family driving a red station wagon had their car stall on a train track and they were killed, one could not necessarily conclude that driving a red station wagon increases ones chance of being killed. Coincidence and cause and effect are not necessarily the same. Let me point out that suicide is the number three killer in people between the ages of 15 and 24.

Thus, one would expect that someone between these ages were at risk of suicide, irrespective of taking accutane, aspirin, or penicillin.

I am aware of testimonials presented during the congressional hearings attesting to the supposed cause and effect of accutane and psychiatric disturbance. I am unaware, however, of any data being presented. Please let me bring to your attention the study published in the Archives of Dermatology Vol 136, October 2000 issue, pages 1233-1236 entitled: "Isotretinoin use and risk of depression, psychotic symptoms, suicide, and attempted suicide." In comparing roughly 7500 patients who received accutane to a matched group of almost 15000 acne patients not treated with accutane, the authors concluded: "this study provides no evidence that use of isotretinoin is associated with an increased risk for depression, suicide, or other psychiatric disorders."

I agree that this matter deserves attention. However, that should not amount to politicians with little or no medical knowledge judging the scientific merits of the risk of a medication. The idea of politicians imposing restrictions on the reasonable practice of prescribing medicine is abhorrent. Further, when those politicians have been either unwilling or unable to discover pertinent medical information (i.e., the study above) their interpretation of the purported facts becomes jaded. Emotions must be set aside, as tragedy does not always have to cause fingerpointing. I feel it would be best that in the face of tragedy grieving rather than blaming be done. There is insufficient data to suggest that accutane causes psychiatric disturbance or suicide.



Steven F. Wolfe, M.D.
Dermatologist

Suicide: A Multi-Factorial Event – Adolescent

Table 1

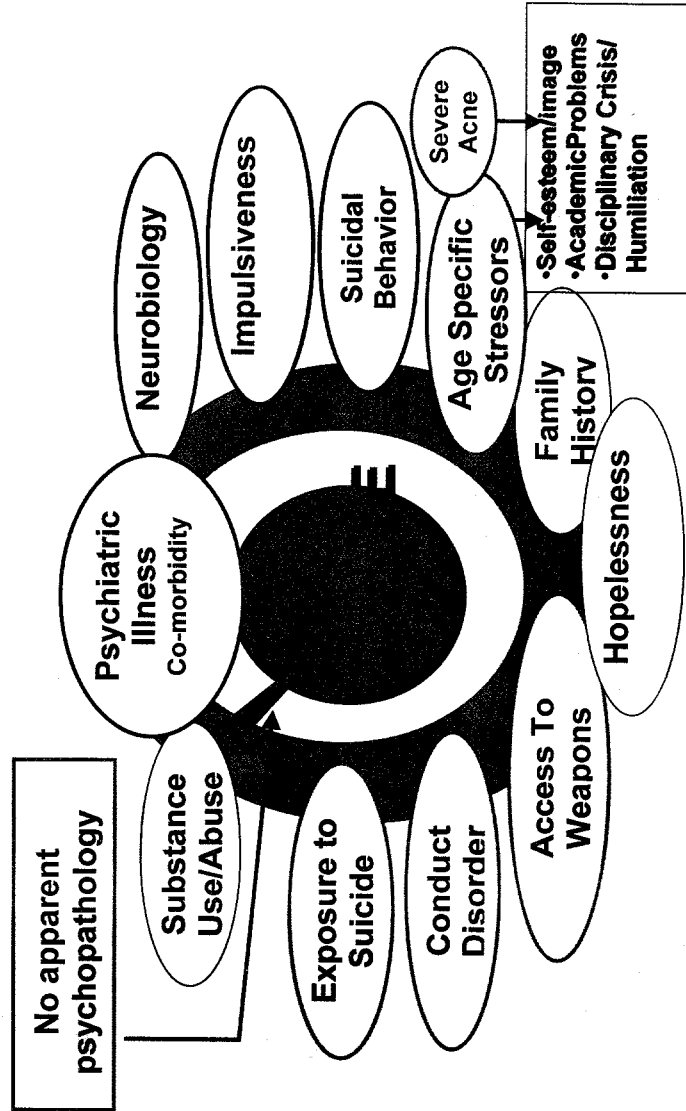


Table 2:
Criteria for Depression

- Depressed Mood
- Loss of interest or pleasure in activities
- Weight loss or gain without dieting or changes in appetite
- Changes in sleeping patterns
- Psychomotor agitation or retardation
- Fatigue or loss of energy
- Feelings of worthlessness or guilt
- Inability to concentrate, indecisiveness
- Thoughts of death or dying

6-28-00

Last night my son Joel was looking at pictures taken during the last year and a half. He held up a picture from his freshman homecoming and asked me, "Mom, what happened to me—how did I get so ugly?" What do I say to my 16 1/2 year old son, whom I love with all my being and would give up my life if it would save his? What answer or excuse or reason do I give my son to explain why he has gained 40+ pounds in less than 4 months, why he doesn't see the need or remember to bathe each day and put on clean clothes, get a haircut or brush his teeth twice a day? He tells me his facial features are diminished, "probably because he is so fat now". No words I say can take away his dislike of his appearance or lessen the isolation and lack of self-esteem he feels each day. Everyday he "hides" in a jacket or sweatshirt even as the temperature rises past 90 degrees and the sweat pours off his brow and down his neck. His hair hangs in uncombed curls and tangles as he hasn't had a haircut since early January. Rarely is it washed more than once a week after his dad and I prompt, bribe or gently coerce Joel to shower.

Recently it took 2&1/2 hours for Joel to clean up prior to going out to eat with his family in Springfield. We were at Joel's sister's apartment where she lives with 2 other girls and he refused to shower and wanted to go home immediately. His dad, Anna, Emily, and I all tried various ways to convince Joel that he needed to clean his body and put on clean clothes before we could go out to eat. I even gave him a choice to make: take a shower and go out to eat or chose to stay at Anna's apartment while we go out and I gave him 30 minutes to decide. After 30-40 minutes went by, Tod again tried to reason with Joel and was so frustrated he took a walk, I was trying to figure out what might be going on in Joel's mind. I tried to reassure him that it was ok to shower at Anna's and that he could lock the door so no one would interrupt him and I would tell her roommates that he was in the bathroom. No way, Joel just wanted to go home, NOW! So, I told him that he choose to stay at Anna's by refusing to shower and the girls and I would go out to eat as planned. I went outside to bring the van around front and waited for the girls; in the meantime Joel was following me but I wouldn't let him get in the van. He plastered his 6 ft. 2ln. body against the passenger door preventing the girls entry or me from driving the van. After about 10 minutes Tod came back from his walk and talked with Joel. I parked the van and we waited and waited. Anna's roommates left and Joel finally took a shower. I asked Joel the next day at home why he took so long to get ready to go out to eat. He had no explanation. This is life with my son today.

Prior to September 16, 1999 Joel used to bathe twice a day, especially if he had

a game or practice or was getting together with friends. He loved to buy new clothes and chose them with care so he would look just right. His hair was clean and neatly groomed with just the right amount of gel. Joel liked to look "cool" and always smelled good, often adding a touch of cologne before going to school or out with friends. With his tall, good looks and dimpled smile others noticed Joel wherever he went. He was very social and friendly to everyone. He liked to make people laugh and had a quick wit.

Last summer our entire family went to Colorado for vacation. We had a wonderful time exploring the mountains and being together. Joel often would entertain us during the long drive with his voice impersonations and funny monologues. Some were original and others from memory of movies he had seen. Joel has always had an incredible memory; I took him to see the movie "Home Alone" when he was very young and he came home and told his dad about the funny movie he had just seen. Joel had almost memorized the entire script word for word, including impersonations of the 2 bumbling thieves. I was amazed. In second grade Joel finished his schoolwork faster than the other students so he would read the classroom encyclopedias. During family dinners he would share what he had read and learned that day. I remember when Joel was 2&1/2 and our family was driving in the neighborhoods and looking at Christmas lights. He said, "Mommy, look at those green lights in that rectangle window." I couldn't believe my ears, but as time passed on Joel continued to astound us with his mathematic abilities. He tested very highly in 7th grade pre-algebra test which enabled him to take algebra in 8th grade. School had always been easy for Joel, so much that as he grew older he was often bored with the routine daily work and often didn't see the need to turn it all in. He would often get A's on his tests but his grades didn't reflect this because he failed to turn in the daily paperwork. [My second daughter, Emily, also went through this during school but now just finished her freshman year studying architecture with a 3.5 grade average.]

Joel played basketball and baseball during his freshman year at Blair Oaks. It was his first year in this school district and within the first week Joel came home with new friends almost every day. Our house was a gathering place for young people on the weekends, too. Joel also played baseball and basketball last summer. He had a girlfriend and was enjoying his life and looked forward to the new school year. He told me he was going to go for it all- good grades and sports- so he could earn scholarships for college after graduation. He was a kind, gentle young man who had the world of opportunity in front of him. His deceased granddad called him "little Hoss". Joel was a typical teenager who would sometimes take risks but would usually listen to us and his older sisters as

we encouraged his independence with responsibilities and consequences. We would disagree at times but after a "cooling down" period, Joel would compromise or accept my/our decision. He could admit he was wrong and we could talk about many things. Joel had empathy and compassion for those less fortunate than him. I remember the spring of 99, he stayed up one night watching movies with his older brother. I had asked Joel to go to bed because he had a basketball game the next day. He came upstairs and talked to me about his concern for William. He wanted to keep William company because William didn't see friends or go to school and Joel felt he needed companionship from his own age. Joel asked me if we could find a school that wasn't too taxing on William so he could be with other kids his age. Joel cried that night for his brother and then went downstairs to be with him. I was so proud of my young son who was blessed with good health, intelligence and athletic gifts but especially for his empathy and compassion for his older brother. [William was diagnosed with congestive heart failure at 5 weeks. He was dying but God gave him back to us. He then endured numerous surgeries until he was 19 months old. It took years for William to gain strength and be able to sleep. He was always smaller and weaker than Joel but they followed each other as though they were twins. Many times Joel protected William from others who would bully him. William had rheumatic fever at age 12 $\frac{1}{2}$, just when he was stronger and healthier than he had ever been in his entire life. He had complications of arthritis and constant infections and his sleep disorder returned. Homebound school became necessary for the next 2 $\frac{1}{2}$ years. It has taken William 5 years to recover from the ravages of rheumatic fever and arthritis.]

Around the middle of August last year, Joel started to change. At first it was small changes that would come and go: headaches, nausea, sleeping more and tardiness to first hour class, and a quiet distance with his friends when they were at our house. Sometimes there were outbursts of anger and profanity towards me that were not typical of Joel's behavior. I thought these signs and symptoms were related to adolescence and viruses that were going through schools. Early September was usually a time when Joel would start telling us what he wanted for his birthday, but not this year. There was an apathy surrounding Joel that had never been present and it's grip was taking hold of him despite support from family, friends and school. He didn't want anything for his birthday, he didn't want to play basketball any more, he had trouble more and more waking and getting to school on time and he didn't think his parents liked him anymore.

During this time Joel was taking 40mg of Accutane twice a day. He never missed a dose and I didn't have to remind him. He started the acne medication the first week in August, just before our family went to Colorado. I couldn't figure out

4

why Joel didn't want anything for his 16th birthday or didn't want to play basketball. I asked Joel "Why" but he didn't have any answers. Sixteenth birthdays were a special event in our family and Joel was the last child. He had played some kind of organized sport since he was 5 years old. His favorite toy as a baby was a ball, any size. He cried when he found he had to be 5 before he could play soccer and t-ball.

Joel's life and ours took a devastating dive on his 16th birthday. The morning wasn't going well as I couldn't get Joel up to get ready for school. His dad tried and Joel said he didn't feel well so we let him sleep for another 30 minutes. Once again, I asked Joel to get ready for school but he wouldn't talk to me. I became frustrated and sad because he wouldn't talk or get up. He had already missed more school than usual and had so many tardies to first hour that we had a meeting scheduled the next morning with his principals and teachers. I was stressed and hated feeling that way, especially on his birthday. Crying, I called my daughters at college for their help. Emily was the only one there and I asked her to speak to Joel and try to find out what was wrong. She told me that Joel didn't feel well and was sad all the time. He told her that he didn't think we (his parents) didn't like him anymore. I apologized to Joel and told him I loved him. He didn't respond which was unusual. Joel stayed home that day and still didn't want anything for his birthday. I bought him a stereo system but he refused to unwrap his present. That night Joel was delusional and out of touch with reality. I had never seen my son like this and it was very frightening. He didn't sleep much that night and neither did I.

We took him to school for a 7:30am meeting and learned that Joel was flunking 6 out of 7 classes and was close to out of school suspension for too many tardies. School had only been in session for only 22 days. I was stunned with this news and asked Joel what had he been doing. He had no answers and seemed as surprised as we were that he was failing school. Several of Joel's teachers said he wouldn't look at them for the past 2 weeks and often stared into space during class time. He was doing the same thing that morning; he had a flat affect and wouldn't make eye contact with anyone, including us. The entire staff said he wasn't a behavior problem and were willing to work with Joel if he was. He said he would start making up his work that day and seek extra help if needed. Tod and I left Joel at school and went to work thinking he had plan and would meet his obligations. I was concerned, though with his affect and lack of eye contact that morning but thought perhaps he was just really tired.

Tod left for a fishing trip that afternoon and Joel came home from school and took a nap. That evening Joel refused to go to bed and was very agitated.

Again his conversation wasn't making sense, he mouthed words without sounds, he chained smoked in front of me(I had never seen Joel smoke prior to this night), he constantly looked at his hands and made weird movements with them, he said he was talking to Jim Morrison and that he wasn't dead, he paced back forth for hours, and didn't sleep at all that night. The next 2 days and nights only got worse for Joel. He became very paranoid and accused me of stealing his Accutane and eating it. He also threatened me many times and said he was going to hit me or that "I should be beaten by a man". Joel also threatened to run away and never come back; he threatened to kill himself on the 21st and often pointed his finger to the side of his head and acted like he was pulling a trigger; he said he had reached nirvana and that he was God. I could write more but it would take too long.

Looking back, I don't know how I managed to keep Joel safe at home those 3 days and nights. He didn't sleep and was increasingly agitated and psychotic. My son, William, helped me out sat. night as Joel became more paranoid and threatening to me. He convinced Joel to leave my room at 4:30 am and go downstairs to watch tv with him. I locked my bedroom door because I feared Joel would carry out his repeated threats to hit or beat me. I was exhausted after little sleep for the past 3 days and extremely frightened and worried about my son. Tod came home sun. evening and I immediately had tell him what was going on. I told him I had talked to Joel's pediatrician and our HMO about possible hospitalization. In my mind I knew my son was very ill and he was only getting worse. I feared that he would either run away or kill himself so I told Tod that we would probably take him to the hospital very soon. I also told Tod that I suspected Accutane as a cause for Joel's illness. Sunday afternoon, I noticed a info sheet on Accutane that I received from the pharmacy with Joel's refill; it talked about mood changes and I immediately hid the remaining prescription and told Joel that he wouldn't be taking Accutane any more because it may be causing his symptoms. He was so psychotic by then that he accused me of eating his Accutane and that there was nothing wrong with him.

This was the start of a nightmare that hasn't stopped since September 16, 1999. It is now July 10, 2000. Tonight, I had to call Joel's psychiatrist because he is not doing well. He hasn't slept much for the last 3 nights and has increasingly become more agitated and obsessive. He is starting to look at his hands and look in the mirror more. His speech is pressured and he gets stuck on one thought for hours. Today, he asked me for an Ativan so he could sleep. He has NEVER asked for this med before and I know he knows things aren't the same for him even though he can't tell me what is going on inside his brain. He said I would be better off if he were dead and that he could put a gun in his mouth and

kill himself. I told Joel that I love him and would be sad forever if he did that and then tried to reassure him that he would feel better. He also asked me to take him shopping "to buy things" as that might make him feel better. I asked him what kind of things but he didn't know. I told him we could go shopping or fishing but he didn't want to go anywhere; he just wanted to sleep. We are going to MN this weekend to see his cousins who are the same age as Joel. We talked about what the boys are doing now and Joel isn't too sure if he wants to see them. He not the same as them anymore and not always comfortable around others.

Do you know what it is like to hear your son threaten to kill himself? Do you know what it feels like to hear your son say "I could kill you, mom?" He's holding his hands around my neck or holding a 3# pointed piece of iron-steel above my head and says "if I drop this on your head I could kill you, mom". I've heard these threats too many times since Joel became ill that I don't even fear my own death. The only thing I fear is that someday he may be so depressed and desperate that he will carry out his threat to kill himself or that he may kill me and not succeed in killing himself. If this would happen, who would take care of my young son and love him the way I do? Who would have the patience, love and determination to seek the best treatment so he could recover and regain his life? I pray to God to let me live long enough to see Joel through this terror and turmoil that his brain goes through.

I cried myself to sleep last night; I was saddened that I had to put to put my son BACK on the anti-psychotic med that I just slowly weaned him off of over the last month. It breaks my heart to see my son suffer and I wished I had never taken him to the dermatologist and consented to Accutane treatment. It has been several months since I've seen him so sad, angry, agitated and thinking that we would be better off if he were dead. Now, I'm back to not wanting to leave him alone and have to listen and watch for signs that he might harm himself. How long will this nightmare last???

I'm very angry that a drug is being prescribed to teenagers and young adults in the prime of their lives that can destroy their mental stability, self-esteem, education, social life, and want them to end their life rather live with this kind of pain and suffering, not knowing whether they will ever find their true self again. I'm a nurse and have dedicated my life to helping others who are ill and suffering. I know that not all illnesses are curable but EACH and EVERY PERSON has the right to live with dignity and have quality of life. Because of Accutane's toxicity to my son's brain he no longer has the quality of life he once had. He now has to take 3 powerful brain medications just so he can stay home with his

family and not be hospitalized in an isolation ward. Without these meds Joel would probably be dead or institutionalized to protect himself from harm. This is what Accutane has done to my son's life and our family. I hope and pray that some day Joel's brain will heal so he can reclaim himself and his life, but I don't know when or if this will happen. I continue to search for more effective treatment and encourage Joel each day. I try not to let him see the grief, anger, pain and worry that I feel each day. Every once and a while I see a glimpse of the real Joel, not the symptoms of his illness and I feel joy, happiness and renewed hope for awhile. Some day these feelings will be more than just a moment in time.

Postscript:

I failed to talk about the isolation that accompanies this illness and the person who must live with it and their family. Initially, we chose to tell no one but our immediate family that Joel was inpatient on a psych unit in order to protect his privacy and protect him from those who might hurt him because of their ignorance of brain disorders. When Joel came home from the hospital, he was still very ill and very vulnerable, almost childlike. The symptoms and behaviors of this kind of illness are not socially acceptable or easily understood and as time went by Joel became isolated from his friends and his extended family. He wasn't able to connect with others because he was living in another reality most of the time. We couldn't go anywhere with for months at a time because he refused to leave the house. His friends went on with their life and activities as he was unable to join them. This isolated us from other families and friends. We no longer went to school activities and ball games or family gatherings. Seeing Joel's friends became a painful reminder of whom he was before taking Accutane and all he had lost. My closest friend didn't understand Joel's illness and was very distant at a time when I needed her support the most. This didn't happen when my son William was ill as a baby or when he had rheumatic fever.

This summer we are trying to go somewhere each weekend with Joel to get him out of the house and socialize with other people. Some times it works and other times it is very stressful but we continue, in hopes that these interactions will help our son to recover.

Postscript as of December 18, 2000:

Joel should be a junior in high school and playing basketball right now. He's not. Instead, he stays home every day and takes 3 medicines twice a day. He sleeps, watches tv and some times looks up cars on the internet. He hasn't been able to study long enough to get his driver's permit; his friends rarely call or visit him

any more. They are living and moving on with their lives while my son is in limbo, waiting for recovery of his brain and mind so he too may one day be a part of life. It's been sixteen months since my son took Accutane and became ill. I don't know if he will ever fully recover or be able to go to school, work, drive, have a girlfriend again or be able to stop taking psychotropic meds without becoming suicidal again. This is what Accutane has done to my son and many more young people that may not even know what has caused their illnesses or deaths. How can this be?? Are we a nation that doesn't care about it's youth or our future generations?? Please stop this killing and maiming of our young people with this drug Accutane. My son's doctor knew nothing about these adverse effects until I asked her to read the PDR. The label said nothing about these effects. I would have NEVER, NEVER AGREED TO GIVE MY SON THIS MEDICINE IF I HAD BEEN TOLD OF THE PSYCHIATRIC RISKS.

Cinda Hudson
6222 Rt. B
Jefferson City, MO 65101

OVERVIEW OF EXISTING RESEARCH AND INFORMATION LINKING
ACUTANE (ISOTRETINOIN), DEPRESSION, PSYCHOSIS AND SUICIDE

PRESENTATION TO THE
CONGRESS OF THE UNITED STATES
HOUSE OF REPRESENTATIVES
COMMITTEE ON GOVERNMENT REFORM

Hearing Title: "Accutane - Is this Acne Drug
Treatment Linked to Depression and Suicide?"

Tuesday, December 5, 2000
1 p.m.

Room 2154 Rayburn House Office Building

Presentation by:

James O'Donnell PharmD MS ABCP FACN CNS
Assistant Professor of Pharmacology
Rush Medical College
Chicago

Biographical Sketch

I, James O'Donnell, earned Bachelor's and Doctorate degrees in Pharmacy from the Universities of Illinois and Michigan respectively, and earned a Master's degree in Clinical Nutrition from the Rush University. I completed a residency in Clinical Pharmacy at the University of Illinois Research Hospitals. I am an Assistant Professor of Pharmacology at the Rush Medical College and a Lecturer in the Department of Medicine at the University of Illinois College of Medicine. I have served as a consultant to the Drug Enforcement Administration, Illinois Department of Public Health, Illinois Department of Mental Health, and several Public Defender's and State's Attorneys offices, all in the areas of pharmacology, drug effects and drug use. I am the Founding Editor of the Journal of Pharmacy Practice. I am a Diplomate of the American Board of Clinical Pharmacology, a Diplomate of the Board of Nutritional Specialties, and a Fellow in the American College of Nutrition, and member of several professional societies. I have consulted to government agencies and pharmaceutical companies in matters related to research, evaluation of adverse event reports, and preparation of technical material supporting marketing and sales. I am a co-editor of Pharmacy Law: Litigating Pharmacy Cases (L&J, 1995) and the editor of Drug Injury: Liability, Analysis, and Prevention (L&J, 2000). A copy of my Curriculum Vitae is attached. I have not received any Federal Government grants and contracts.

Disclosure	3
Objective	3
Introduction	3
Mechanism Of Action	5
Chemistry, Terminology and Metabolism	5
Adverse Effects Of Accutane	5
Hypervitaminosis A	6
Psychiatric Adverse Events	7
Pseudotumor Cerebri (PTC)	8
Retinoids Implicated in Schizophrenia	9
Accutane and Depression	9
Adverse Drug Reaction Reports	10
FDA Meeting of the Dermatologic and Ophthalmic Drugs Advisory Committee Accutane Associated Psychiatric Events September 19, 2000	12
Submission Of ADR Reports	15
Revised Label Warning	16
FDA's Battle With Accutane	16
INDICATIONS FOR USE - Failure to comply	17
SUMMARY AND RECOMMENDATIONS	17
Table 1. Worldwide Psychiatric ADR Reports (WHO)	19
Table 2. UK ADR data (source: MCA)	20
Table 3. Prescription Data (England 1982-97)	20
REFERENCES	21

Disclosure

I have testified as a witness for plaintiffs in product liability suits against Roche; however, I am not here in the capacity of an expert witness, and am not being compensated for my time associated with this Committee presentation.

Objective

My objective today is to provide information describing the association of Accutane to depression, psychosis, and suicide to the Committee. That information comes from a variety of sources, including my experience and training as a pharmacist, pharmacologist, and nutritionist:

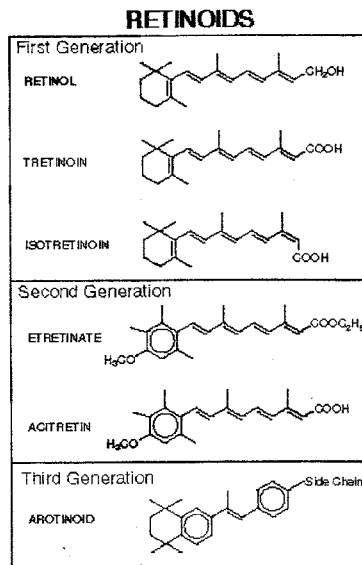
- Basic pharmacology and toxicology of Vitamin A and Retinoids
- Accutane clinical research
- Published literature describing Hypervitaminosis A as well as Accutane
- Adverse reaction Reports (US and Europe)
- Expert Analysis of Causation
- My own personal assessment and recommendations.

Introduction: Vitamin A and Retinoids

Since early this century animal research revealed modifications of epithelial structure such as increased epidermal keratinization and squamous metaplasia of the mucous membrane, under conditions of vitamin A deficiency. The finding that these defects could be corrected by administering vitamin A led to the emergence of vitamin A as an anti-keratinizing factor. The first synthesis of vitamin A fifty years ago opened a new era into the chemical synthesis of vitamin A derivatives, collectively known as retinoids.

First synthesized in 1955 Accutane (Ro 4-3780, isotretinoin), a first generation retinoid, was shown to be highly efficacious in the therapy of disorders of keratinization (e.g., Darier's disease, ichthyosis). Peck *et al.* (1978) were the first investigators to demonstrate this drug's value in the treatment of severe acne and in September 1982 it was approved for use in the USA by the Food and Drug Administration (FDA). From 1993 to 1997, prescriptions in the US jumped 52% (to 1.5 million).

Figure 63-1 from
Goodman & Gillman's
The Pharmacological Basis of Therapeutics, 9th Edition, 1996



Mechanism Of Action

Acne is due to an interaction of the normal skin bacteria with the patients abnormal type of sebaceous lipids (Cunliffe, 1998) and is associated with an increased sebum production and ductal cornification. The acne bacteria, *Propionibacterium acnes*, reside on the surface of the skin in quite high numbers, especially in oil-rich areas. If they colonize the pilosebaceous duct in the presence of comedones (blackheads and whiteheads), then inflammation is likely to be triggered resulting in papules, pustules and if inflammation is more expansive, nodules. Although the exact mechanism of the anti-acne action of isotretinoin is unknown it is unique in its ability to affect, albeit not to the same degree, all the known etiological factors of acne; reduction of sebum production, lessening of comedogenesis, decreases surface and ductal colonization by *Propionibacterium acnes* (Cunliffe, 1997).

Chemistry, Terminology and Metabolism

Although the term vitamin A has been used to denote specific chemical compounds, such as retinol or its esters, this term now is used more as a generic descriptor for compounds that exhibit the biological properties of retinol. Retinoid refers to the chemical entity retinol or other closely related naturally occurring derivatives. Retinoids also include structurally related synthetic analogs, which need not have retinol-like (vitamin A) activity. (Marcus, 1996)

Isotretinoin is a metabolic product of the dietary vitamin A and provitamin A carotenoids. Retinol (vitamin A) is absorbed from the gastrointestinal tract and metabolized in the liver, into retinal. Retinal is then irreversibly oxidized into retinoic acids, which reversibly interconvert into each other. The 2 isomers (retinoic acid and 13-retinoic-acid) have an identical chemical structure. Isotretinoin and retinoic acid are further metabolized into oxo-isotretinoin and oxo-retinoic acid, respectively, where interconversion again takes place between both metabolites (Wiegand, 1998). The elimination half-life of isotretinoin and its 4-oxo metabolite are 29 and 22 hours, respectively (Nulman, 1998).

Adverse Effects Of Accutane

Over the years Accutane has proven its excellence in the treatment of severe recalcitrant acne. However it is associated with a long list of side-effects which are frequent, varied and at times severe. The most commonly occurring adverse reactions are those involving the skin and mucous membranes, which occur in all patients treated with Accutane. Other side effects reported include skin fragility, pyogenic granuloma-like lesions and epidermal blistering, paronychia and alopecia (Bigby, 1988). Gastrointestinal intolerance occurs in 20% of patients treated (Bigby, 1988). Muscular or joint pain, are quite common with Accutane use. Myalgia and arthralgias occur in 16% of patients treated, which usually abate when the medication is discontinued (Orfanos, 1997).

Blepharitis and conjunctivitis associated with Accutane use were recognized well before it's marketing. Corneal opacities and acute myopia have been reported in government publications and in the ophthalmologic literature. Other ocular reactions include optic neuritis, cataracts, decreased night vision, blurred vision and photosensitivity. Pseudotumor cerebri (PTC) and headaches are also associated with the drug. In common with other retinoids at pharmacological doses, Accutane causes elevation of serum lipids particularly triglycerides.

Hypervitaminosis A

Hypervitaminosis A is the condition resulting from an excess of retinol in the body.

Vitamin A is an essential factor in physiological growth, visual function, epithelial cell differentiation and reproduction and is believed to exert its influences at the DNA level where it plays an important role in regulating transcription of a number of genes.

An intake of retinoids greatly in excess of requirement results in a toxic syndrome known as hypervitaminosis A. Some or all of the symptoms of hypervitaminosis A also are the major toxic effects that are manifest during the therapeutic use of natural and synthetic retinoids in the treatment of skin disorders. Accutane (Isotretinoin), being an analog of vitamin A, shares many of the side effects experienced with vitamin A. Vitamin A (retinol) is ingested in the diet as retinyl esters, which are transported to the liver and hydrolyzed in hepatic parenchymal cells. Excess retinol is converted to retinyl esters again and stored in the liver. Retinol binds to Retinol Binding Protein (RBP). When the amount of vitamin A present exceeds the capacity of RBP to bind to it the excess retinol binds to lipoproteins, and in this form it has toxic effects (Bendich, 1989).

There are two types of Hypervitaminosis A, acute and chronic. Acute hypervitaminosis A results from ingestion of a very high dose of vitamin A over a short period of time. Typical symptoms include bulging fontanelles in infants and headache in adults, nausea, vomiting, fever, vertigo and visual disorientation. Peeling of the skin may also occur. Chronic hypervitaminosis A is more common than the acute form and results from continued ingestion of high doses for months or even years. Symptoms include anorexia, dry itchy skin, alopecia, increased intracranial pressure, fatigue, irritability, somnolence pronounced craniotabes and occipital edema, skin desquamation, fissuring of the lips, pain in the legs and forearms, neurologic disturbances and lethargy. Elevated blood lipids are also common. (Wilson, 1996) This reads just like the Accutane package insert.

Most frequently, high intakes in children are the result of overzealous prophylactic vitamin therapy on the part of parents. Toxicity in adults has resulted from extended self-medication or food fads, as well as from the use of retinoids for the therapy of acne or other skin lesions. The toxicity of retinol depends on the age of the patient, the dose, and the duration of administration. Although vitamin A toxicity is uncommon in adults who consume less than 30 mg of retinol per day, mild symptoms of chronic retinoid intoxication have been detected in individuals whose

intake was about 10 mg per day for 6 months (see Bendich and Langseth, 1989). In infants, the daily consumption of as little as 7.5 to 15 mg of retinol for 30 days has induced toxicity. The acute consumption of more than 500 mg of retinol in an adult, 100 mg in a young child, or 30 mg in an infant frequently results in poisoning. Acute and sometimes fatal poisoning in human beings also is known to follow the ingestion of polar bear liver, which contains up to 12 mg of retinol per gram. The Food and Nutrition Board of the National Research Council (1980) has warned that the ingestion of more than 7.5 mg of retinol daily is ill advised. Nevertheless, almost 5% of users of vitamin A in the United States exceed that amount.

Signs and symptoms of acute poisoning include drowsiness, irritability or irresistible desire to sleep, severe headache due to increased intracranial pressure, dizziness, hepatomegaly, vomiting, papilledema, and, after 24 hours, generalized peeling of the skin. (Guzzo, 1996)

Psychiatric Adverse Events

Vitamin A intoxication resulting in generalized as well as Central Nervous System (CNS) symptoms, was first alluded to in 1856 by Elisha Kane (Kane, 1856), the arctic explorer. He recorded symptoms of vertigo, headache, drowsiness and irritability following ingestion of polar bear liver, which was later found to contain a high concentration of vitamin A. Over the succeeding 140 years, case reports of the occurrence of acute schizophrenia or remitting psychosis associated with either hypervitaminosis A (Halter, 1991; Haupt, 1977; Landy, 1985) or vitamin A deficiency (Olver, 1986) have appeared in the literature. These provide literature precedent and biologic plausibility to the causation analysis.

In 1972, Restak reported a case of toxic psychosis in a patient following vitamin A treatment (50,000 IU 2/3 times daily) for acne, which required hospitalization. About six months after initiating vitamin A therapy, the patient experienced the onset of prolonged depression, bouts of elation alternated with despondency, disturbed sleep, insomnia and loss of appetite. Twelve months later, while on holidays, she became more agitated and depressed, and lost weight. She also developed blurred vision, hyperacusis, vertigo, strong feelings of ego alienation, and lethargy. Following psychiatric referral, total remission occurred over 6 months of close observation and anti-depressant therapy. The authors cautioned the "use of the vitamins as preventatives for such benign entities as acne." (Middelkoop, 2000)

In 1992, a case report described a patient, with no previous psychiatric history, who presented with a 1-year history of depressed mood and poor concentration (McCance-Katz, 1992). Medication included only a multivitamin preparation of 25,000 IU of vitamin A per day, for 2 years. Hamilton Depression Ratings confirmed full cessation of depressive symptoms after stopping treatment. Other reports of lethargy, loss of interest in surroundings, insomnia, listlessness, profound daily fatigue, anorexia and irritability, in association with vitamin A, have been documented (Stimson, 1961; Shaw, 1953; Oliver, 1958; Bifulco, 1957; Elliot, 1965).

Pseudotumor Cerebri (PTC)

First described by Gerber *et al.*, in 1954, PTC (benign intracranial hypertension) has long been associated with Vitamin A administration (Lombaert, 1976; Siegel, 1972). PTC is accompanied by symptoms such as papilledema, vision problems, nausea and severe headaches. PTC occurs in 30% to 50% of patients with hypervitaminosis A (Selhorst, 1984) and is characterized clinically by 3 criteria (Spector, 1984; Marcus, ; DiGiovanna et al, 1986):

Neurologic and ocular symptoms and signs of increased intracranial pressure, which may include headache, nausea, transient visual obscurations, sixth-nerve palsies and papilledema.
Radiologically demonstrable normal or small-sized cerebral ventricles
Elevated Cerebrospinal fluid.

PTC has been associated with isotretinoin therapy (Lee, 1995; Roytman, 1988) and the retinoid, etretinate (Bonnetblanc, 1983) and combination therapy with tetracyclines may increase the risk for it occurring.

I testified In the case of Wagner v. Roche Laboratories (decided Nov. 13th 1996), a consumer brought a products liability action against Roche, alleging that the defendant failed to adequately warn of the association of Accutane with PTC and of the dangers of concomitant use of Accutane and certain antibiotics such as Minocin (minocycline), a tetracycline derivative. Ms. Wagner was prescribed Accutane on Nov 8th 1982 for acne in addition to Minocin which the patient had previously been on. Six weeks later the a neurologist diagnosed papilledema and PTC. Steroids were prescribed to treat the PTC and as a result, the appellant experienced avascular necrosis. Appellant underwent several surgeries to replace both hip joints and a shoulder joint. The appellants theory of recovery at trial was premised on her presentation of expert testimony by myself that (a) "Accutane is so similar chemically to Vitamin A that appellees either were aware, or should have been aware, that Accutane also had the potential to cause PTC", and (b) "that because the two antibiotics the appellant was receiving were both associated with PTC, the combination of the two increased that risk." Dr. Elias, one of the physician investigators who participated in the clinical trials of Accutane, testified that the testing done by the appellees prior to FDA approval, was deficiently designed because it failed to monitor for neurological toxicity, and that because of the similarity with vitamin A, Roche should have predicted the same association of Accutane with PTC. In addition, I testified that even in the absence of specific instances of PTC in clinical trials, Roche should have predicted an association and should have warned of this possible effect. In fact, the Investigational Drug Brochure", dated March 20th 1978, which contains an extensive listing of abnormalities in its "Precautions and Warnings" section, reported in patients with "chronic vitamin A intoxication. "Papilledema with increased intracranial hypertension" was one of the reported associated abnormalities listed. The same document also stated "A review of the clinical studies discussed in this brochure indicates that the adverse reactions seen with the use of orally administered Accutane are essentially those of hypervitaminosis A".

Retinoids Implicated in Schizophrenia

Goodman has recently proposed retinoid dysregulation as a possible cause of schizophrenia (Goodman, 1995). Schizophrenia is now considered to be a neurodevelopmental disorder with first evidence of the disorder occurring in the midgestational period, the time when fetal brain is actively developing. Vitamin A which is essential in gene regulation and expression, is particularly active in brain neurodevelopment at this time. Goodman has put forward three lines of evidence for an association. The first is the resemblance of symptom presentations of retinoid toxicity to the stigmata of schizophrenia e.g., thought disorder, mental deficit, enlarged ventricles, microcephaly and congenital malformations. The second line of evidence comes from the finding that specific gene loci which have been suggestively linked to schizophrenia, are known loci of genes within the retinoid signaling system. Retinoids are handled in the body by a complex genetic cascade necessary for the metabolism of retinol to retinoic acids. The major genes in the retinoid cascade are the nuclear retinoid receptors RAR and RXR. The loci of two of the genes involved in the regulation of this cascade, RXR β and RAR β , have been suggestively linked to schizophrenia. It has recently been found that RXR is necessary for the expression of dopaminergic neurons in the midbrain region in mice, which have been implicated by numerous studies as abnormal in schizophrenia (Kapur, 1996). The third line of evidence shows schizophrenia genes as targets of retinoid regulation. Retinoic acid binds to RARs and RXRs and this complex then binds specific regions of target genes and in this way regulate the expression of multiple target genes. Among the many genes shown to be targets of retinoic acid are dopamine and serotonin, both of which have been proposed as candidate schizophrenia genes. (Middelkoop, 2000)

Alteration of neurotransmitters is a classic hallmark of the psychoses. Recent work has shown that retinoic acid is a major regulator of several of the genes involved in neurotransmission (Berrard, 1993).

Accutane and Depression Literature Reports

Depression associated with Accutane therapy has, in the past, been described as idiosyncratic. Increasing reports of depression associated with its use show it is not the rarity it was once considered to be. Between 1982 and 1998 24 cases of psychological distress associated with the use of this drug were reported in the literature. Most of these cases reported the subsequent emergence of depression with features similar to that of hypervitaminosis A. (Middelkoop, 2000) Other authors have published case reports of Vitamin A poisoning. (Nagai, 1999; Aggarwal, 1996; Grisson, 1996; Alemayehu, 1995; Fishbane, 1995; Lewin, 1994; Drouet, 1998; Sharieff, 1996; Gerber 1954; Pasquariello, 1977; Rose, 1967; Braun, 1962)

Systemic side effects are generally less significant if therapy is short-term. Transitory abnormal elevations in serum transaminases occur rarely. Acute idiosyncratic hepatitis has not been seen with isotretinoin as it has with etretinate. Hyperlipidemia is frequent, with 25% of patients developing increased triglyceride levels and, less frequently, increased cholesterol and low-density lipoproteins and decreased high-density lipoproteins (Bershad et al., 1985). Myalgia and arthralgia are common complaints. Headaches occur and rarely are a symptom of pseudotumor cerebri. Occasionally, patients have drug-associated depressive episodes. Long-term therapy may produce skeletal side effects, including diffuse idiopathic skeletal hyperostoses, extraskkeletal ossification,

particularly at tendinous insertions, and, in children, premature epiphyseal closure (DiGiovanna et al., 1986; Marcus, 1996).

In 1983, one year after market release, Hazen *et al.* (1983) reported 5.5% (6/110) of patients with acne experienced depressive symptoms, manifested by malaise, crying spells and forgetfulness, within 2 weeks of commencing isotretinoin therapy. Meyskens also noted similar psychological changes in patients with cancer treated with 3mg/kg/d isotretinoin. The ADRRS of the American Academy of Dermatology, received reports of 104 suspected adverse reactions to isotretinoin, between October 1982 and June 1985, of which CNS Disorders represented 22.1% (23/104), second to Skin and Mucous membrane reactions (27.9%) (29/104) (Bigby, 1988). These CNS reactions included headache, depression, dizziness and personality disorder. Scheinman (1990) reported 1% of patients treated developed depressive symptoms with oral isotretinoin, which were diagnosed by a psychiatrist and which the severity of symptoms interfered with their normal functioning. In this particular report, the relationship of depression to isotretinoin therapy was confirmed by rechallenge. This was also confirmed by Villalobos' (1989) patient, who reported the onset of hallucinations and paranoia on day 11 of isotretinoin therapy, which subsided when drug intake was stopped and recurred shortly after resumption of isotretinoin. Gatti in Italy (1991), reported a case of suicide which happened 2 months after stopping isotretinoin therapy. Bravard *et al.* (1993) described 3 case reports of depression where none had a prior history. One of these patients attempted suicide during the 4th month of isotretinoin therapy, and one committed suicide 3 months after cessation of therapy. (Middelkoop, 2000)

Cessation of depressive symptoms does not always occur upon withdrawal of the drug. Byrne *et al.* (1995) described three patients who presented with severe depression, which required active treatment. In all three cases, the patients moods improved with anti-depressant therapy. Despite the recurrence of one of the patients acne, follow-up showed no depressive symptoms, confirmed by a score of 5 on the Hamilton Depression Rating Scale.

Adverse Drug Reaction Reports

Middelkoop conducted a pharmacoepidemiologic analysis of Accutane and other drugs used to treat acne and reports of suicide, depression, and other psychiatric adverse drug effects.

Among the many products available, Dianette, doxycycline, minocycline, oxytetracycline and tetracycline are five most commonly prescribed anti-acne treatments. Based on available information, there are more reports of psychiatric adverse events and suicide worldwide from isotretinoin than from the use of the other 5 acne therapies combined (Table 1, World Health Organization). Worldwide 1830 reports of psychiatric events attributable to the 6 medications, are identified, of which isotretinoin was implicated in 59.8% (1095/1830). Second to this was minocycline, implicated in 14.2% (261/1830). 47 and 56 cases of suicide and suicidal ideation were reported in association with the use of Accutane, respectively, with none being reported for the other medications. Of 75 cases of attempted suicide reported, 89.3% (67/75) were associated with the use of isotretinoin, with 4% (3/75) associated with the use of both Dianette and tetracycline, and 2.6% (2/75) for minocycline. ADR data for the UK (Table 2, Medicines Control Agency (MCA)) reflect a similar pattern, with 51.9% (135/262) of psychiatric ADRs attributed to isotretinoin. In addition, all cases of suicide/suicide attempt/suicide ideation were associated with the use of this medication. The source for this data relies on

voluntary reporting and probably represents significant underreporting as not all serious ADR's are reported. (Middelkoop, 1999; 2000)

Isotretinoin, an acne drug used by more than 8 million people, has been associated with severe depression and even suicidal behavior that may remit when the drug is withheld. A definite cause and effect relationship between isotretinoin use and depression has not been established, and it is not surprising that the presence of severe acne itself may predispose teenagers and young adults to depression. Nonetheless, this possible side effect of isotretinoin should be kept in mind whenever the drug is prescribed. (Hauser, 1998)

Table 3 shows the number of prescription items dispensed in England from 1982 to 1997. Isotretinoin, while attracting the largest percentage of psychiatric ADRs, had the lowest number of prescriptions issued (12,400). During this period 1,214,600 prescriptions were dispensed for Dianette, of which the indication for 184,200 prescriptions was acne. Dianette was implicated in only 1.9% (5/262) of psychiatric ADRs.

Minocycline is used extensively in the treatment of acne vulgaris (8,802,000 prescriptions issued between 1982-97. Between 1970-97, 6.5 million patients (Shapiro et al., 1997) were treated with minocycline in the UK. A total of 45 psychiatric adverse events were received by the MCA between 1973 and 1997. Accutane has a UK patient exposure of 50,000 (8 million worldwide, PharmFocus data) and has received reports of 135 psychiatric adverse events. Based on these figures, the incidence rates of psychiatric adverse reactions for Accutane and Minocycline are 270 and 0.692 per 100,000 people treated, respectively. These medications, (with the exception of Accutane) are used to treat conditions other than acne. As patient exposure data for these medications, where the indication was acne, was unobtainable the frequency of psychiatric reactions attributable to these medications, in the population of acne patients, remains unknown. Middelkoop concluded that Accutane is several hundred times more likely to cause depression than the five other acne.

A major component of the evaluation of reports of suspected adverse drug reactions, or events in a clinical trial, can be a judgment about the degree to which any reported event is, in fact, causally associated with the suspected, or investigational drug. In reality, a particular event is associated or is not associated with a particular drug, but the current state of information almost never allows a definitive determination of this dichotomy. (Jones 1994)

The analysis of causality and association in adverse drug events has not changed in the last 20 years. Riddell (1983) describes the "ways and means" of confirming or denying the possibility of an ADR which constitute a validation process that removes suspected cases from the merely anecdotal category. They are:

1. Temporal eligibility - drug must be administered at some interval of time before the reaction occurs.
2. Latent period - There is an interval from the time at which a drug is first administered to the beginning of the ADR.
3. Exclusion - are any other drugs or existing conditions responsible. This method is not applicable in all cases of possible ADR, either because of insufficient data or because

of simultaneous eligibility of more than one drug.

4. De-challenge - condition improves on discontinuation of the drug, and
5. Re-challenge - condition reoccurs upon re-exposure to the drug (usually not deliberately, since a suspicion of an association with an adverse event would preclude intentional re-exposure of a patient to the same adverse event.
6. Singularity of the drug - Is there something unique about the adverse reaction experience that is not consistent with any other drug taken or any existing disease condition.
7. Pattern - ADR been described in the literature with this drug or another in the same pharmacologic class, or it may refer to a morphologic pattern in a target organ that suggests an association with a particular drug or group of drugs. (Prior history with Hypervitaminosis A provides a literature precedent, a biological plausibility).
8. Drug Identification (qualitative or quantitative) - a major utility in overdose cases.

Causality assessments were usually expressed in terms of a qualitative probability scale, for example "definite" vs. "probably" vs. "possible" vs. "doubtful" vs. "Unrelated." (Hutchinson 1989)

**FDA Meeting of the Dermatologic and Ophthalmic Drugs Advisory Committee
Accutane Associated Psychiatric Events September 19, 2000**

Several experts from Roche as well as FDA addressed the issue of Accutane and depression and suicide.

Dr. Russell Ellison (Roche) stated:

"We had a signal (psychiatric events) which had yet to be confirmed, and stated that Roche has been very diligent in trying to evaluate and trying to confirm this signal." He and his consultants (Drs. Nelson and Jacobs) opined that there was insufficient evidence to attribute causality to the Accutane psychiatric toxicity reports. "We believe that the evidence from these investigations does not support a causal association between Accutane and psychiatric events, including suicide. That is, the signal has not been confirmed by these investigations."

Dr. Robert Nelson (Roche, Pharmacoepidemiological Analysis) provided his analysis and opinions.

"Suicide attempts and completed suicides. Suicidal ideation is under DSM-IV as a depressive case. There were a total -- and this is worldwide total -- of 168 reports before the data lock point. 104 were attempts; 64 were completed suicides. My overall conclusions. Given no clear biological plausibility, no consistent pattern in the data that I reviewed, complex environment of background symptoms, very high background rates of disease, very high background rates of alternative risk factors, I conclude that there is no evidence in these data to support a causal relationship between Accutane administration and psychiatric disorders."

Dr. Mills, and epidemiologist, commented and criticized Middelkoop's data (slide presented by Liam Grant):

"If I remember the slide correctly, 1,400,400 prescriptions for one of the antibiotics with no suicides, no suicidal ideation. Now, you tell me that there's a population of a million and a half people anywhere in this country where nobody has any of those problems. It's a classic case of poor reporting. I personally would make absolutely nothing out of the data there for that simple reason, that you're just not getting accurate reporting at all."

Lawyer Richard Josephson who has represented Roche on Regulatory and other matters, pleaded the Advisory Committee for a scientific review.

"In law and in science we have adopted your methodologies. After years of not considering the scientific method in courts, we now have adopted from science the scientific method. If you look just briefly at the scientific method, they ask on the question of the contention of whether Accutane causes psychiatric reactions, the extent to which the theory has been assessed based on scientific valid reasoning and methodology, whether the theory has been subjected to peer review, case reports versus peer-reviewed studies, whether the theory is only based on subjective belief or speculation, whether there is a potential rate of error in this case in the adverse drug reports, and whether the underlying theory or technique has been generally accepted as valid by the scientific community.

I merely ask you to consider the fact that you now have a label, which under the scientific method, no one here can conclude that Accutane causes those effects. As you consider what remedial action, if any, is needed or additional action is needed, I only ask that you keep that in mind."

Dr. Alan Byrne (FDA), stated:

"Therefore, in relation to isotretinoin, my clinical observations have been that this agent can influence mood in certain individuals. My feeling is that the effects on mood may be very persistent, and obviously anything that can precipitate a depressive illness may be life-threatening because there is a significant risk of suicide with depressive illness.

Dr. Marilyn Pitts (FDA, Case Review) offered the following comments:

"The top 10 adverse events for Accutane include depression, ranked number 6. By contrast, we looked at tetracycline, which is another agent used for less severe acne. We have 8 cases of depression and 2 deaths, and we looked at Claritin in the AERS database where we have 10 cases of depression and 2 deaths.

In 1998, OPDRA analyzed spontaneous adverse drug event reports of positive dechallenge/rechallenge cases of depression, mania, psychosis, and suicide attempt. The 2998 case series supported the Accutane labeling change, which included a warning concerning psychiatric disorders. The warning stated that Accutane may cause depression, psychosis, and rarely, suicidal ideation, suicide attempts, and suicide.

In summary, we have 41 Accutane associated dechallenge/rechallenge cases. 76 percent were without a reported psychiatric history. The median time to onset of symptoms during the first course of Accutane was 30 days, and a median recovery time of 4.5 days. During the second course, or the rechallenge course, the time to onset of symptoms was shorter in the cases that provided the information. Also, after

the second course of Accutane, depression persisted in some patients after discontinuation of Accutane and/or medical intervention. There was a possible dose-response to Accutane observed in 6 patients.

In conclusion, dechallenge/rechallenge cases provide strong evidence to support a link between a drug and an observed adverse event. We have presented 41 cases of positive dechallenge/rechallenge which provide further evidence to support a relationship between Accutane and depressive symptoms.

Dr. Wysowski (FDA, Postmarketing Experience Suicide and Depression), provided the following analysis: "Over the 18-year period of marketing, the FDA received reports of 37 U.S. patients who committed suicide, 24 on Accutane and 13 after stopping the drug. Twenty two (22) percent of suicide cases were reported to have a psychiatric history. About 57 percent had other possible contributing factors for depression. In addition to the suicides, the FDA received reports of 110 U.S. Accutane users hospitalized for depression, suicidal ideation, and suicide attempt, 85 on Accutane and 25 after stopping the drug.

About a third of patients had positive dechallenges with psychiatric treatment, and nearly a third experienced persistent depression after drug discontinuation. One person had a positive rechallenge, while three others were rechallenged and were able to continue on Accutane with alcohol abstinence, dose lowering, and continued use of an antidepressant.

As of May 2000, the FDA received reports of 284 U.S. Accutane users with non-hospitalized depression. 45 percent were received in 1998 after depression and suicide were added as a warning to the labeling. About half of the non-hospitalized patients reported accompanying side effects such as dry mucous membranes, headaches, hair loss, and joint and muscle pain. About 50 percent of reports were from consumers and relatives, a higher proportion compared with most reports for most drugs.

The top 10 adverse events reported for Accutane include depression that ranks number 6. Of course, the degree of under-reporting is unknown and may be quite substantial.

There are several pieces of evidence supportive of a possible association between Accutane and depression and suicide. These include the relatively large number of reports of serious depression, more than for most drugs in the FDA's database, the temporal association between use of Accutane and onset of depression, positive dechallenges in individuals who felt better once Accutane was discontinued and psychiatric care was obtained, and positive rechallenges in individuals who experienced symptoms again after restarting the drug.

So, in summary, the FDA has received reports of suicide and serious depression in U.S. Accutane-treated patients. The case reports are suggestive of an association with Accutane, but do not allow definitive determination as to whether Accutane causes depression and suicide in treated patients."

Dr. Kathryn O'Connell (FDA, Biological Plausibility and Risk Management):

"The first item that I mentioned was we ask ourselves, do we see psychiatric adverse events? Have they been reported with distinct substances that bind to the same physiologic receptor? Dr. Byrne and

several other people have already referred to the fact that it is known that high dose vitamin A, hypervitaminosis A, has been associated with psychiatric adverse events. If you look in the published cases about time to offset, the most useful data -actually the paper has already been referred to I think by Dr. Byrne and perhaps by the sponsor as well that was published by Scheinman, et al. in 1990, I want to emphasize that this was not a trial done to examine the psychiatric adverse events of Accutane. This was just 700 patients – I believe it was an NIH trial that had received Accutane for various indications. It wasn't even all acne. 7 patients in that group had enough psychiatric problems to come to attention. Let's put it that way. But of those 7 patients that they reported in this paper, it's notable that the symptoms in all 7 of them resolved within 1 week of stopping Accutane, and 1 of the patients was rechallenged and did have a positive rechallenge.

For Accutane, the central nervous system, interestingly, ranks second only to psychiatric in the highest percentage of serious adverse events – serious adverse events – in the Hoffmann-LaRoche postmarketing database for Accutane. So, I think it's clear that Accutane affects the central nervous system.

We don't know a mechanism for the psychiatric adverse events observed with any of the retinoids...

Dr. Miller recommended improvements in asking Accutane patients appropriate question to evaluate them from a psychiatric point of view.

“What would help me and make my practice much easier would be to have a specific form that would be dealt with with each patient that would include the pregnancy contraceptive issues, that would include the appropriate questions that I would ask from a psychiatric standpoint because I don't know what those questions are, but those questions that the psychiatrists feel are appropriate. And upon completion of that form, I would then be able to write a prescription for a patient. But the fulfillment of the recommendations would be the sine qua non for my writing the prescription for Accutane. I think this would help.”

On the second question before the committee regarding what kinds of future studies are both desirable and feasible:

Would further studies help clarify the relationship between Accutane use and psychiatric events? Yes: “Intervention”; Basic science studies; retrospective epidemiological studies.

Submission Of ADR Reports

ADR reports often paint an incomplete picture as the cases which are filed each year represent only a fraction of actual cases. According to the UK MCA only 10-15% of serious ADRs are ever reported. A FDA MedWatch Continuing Education article (Goldman et al 1996)describes significant underreporting in the United States. He cited estimates that rarely more than 10% of serious ADRs, and 204% of non-serious reactions are reported to the British spontaneous reporting program. A similar estimate is that FDA receives direct reports oless than 10% of suspected serious ADRs This means that cases spontaneously reported to any surveillance program, which comprise the numerator, generally represent only a small portion of the number that have actually occurred. The effect of underreporting can be somewhat lessened if submitted reports, irrespective of number,

are of high quality.

Under regulations a pharmaceutical company must submit all ADR reports to the FDA periodically (at least annually) or on an expedited basis within 15 days of receipt. The FDA, on January 5th 1998, sent a warning letter to Hoffman-LaRoche (New Jersey) for failing to submit a number of adverse drug experience reports that were both serious and unexpected, within 15 working days as required by regulations (21 CFR 314.80 (c)(1)) as recently as October 1997 (with some dating back to 1989)(Scrip 1998). The letter documented, among others, two ADR reports for Accutane which were received by the manufacturers on 9/04/91 and 7/24/91. Both reports were not received by the FDA until 10/8/97 (FDA/Middelkoop personal communication). In one case, for Tigason, the company reported the adverse drug event almost 11 years after receiving the information. Thus, although regulations require it, sometimes even the companies do not report in a timely basis, if at all. (Middelkoop, 2000)

Revised Label Warning

On February 25th 1998, the FDA issued a Talk Paper declaring new safety information regarding isotretinoin, as a result of adverse event reports the agency received. The revised information leaflet, now reads "*Psychiatric disorders: Accutane may cause depression, psychosis and, rarely, suicide ideation, suicide attempt and suicide. Discontinuation of Accutane therapy may be insufficient; further evaluation may be necessary. ...Of the patients reporting depression, some reported that the depression subsided with discontinuation of therapy and recurred with reinstitution of therapy*". Earlier information leaflets read "*depression has been reported in some patients on Accutane therapy. In some of these patients, this has subsided with discontinuation of therapy and recurred with reinstitution of therapy*". Thus, FDA has spoken: Accutane is linked to depression, psychosis, and suicide.

Almost one year prior to this revision, the French product label was altered on March 3rd 1997, to include 'suicide attempt' as a side effect of isotretinoin therapy, and reads "*In rare occasions, neuropsychological problems have been recorded (behavioral difficulties, depression, convulsions and suicide attempts)*" (French Product License, 1997). This revision was introduced in France following a prospective national inquiry (1993-94) in which Roche and more than 2000 state dermatologists participated. This inquiry followed a paper presentation, which reported on a suicide associated with isotretinoin therapy (Bravard, 1993). The results of this inquiry were presented at the 3rd Forum of the National and Provincial Journal of Dermatology at Mont Pellier (March 14-17 1996) but were never published. It was almost one year later, before this warning was introduced in any other country. According to The Star-Ledger (11/16/98) "Roche never informed the FDA of this new label change, who did not learn of the French label warning until this summer [1998]". Revised warnings have now been introduced in Ireland (May 1998) and UK (April 1998). Many have asked why French physicians and their parents were given a stronger and more explicit warning than their counterparts in the U.S., UK, and Ireland.

FDA's Battle With Accutane

During the 1980s and early 1990s FDA officials debated options to control and prevent the occurrence of

Accutane-exposed pregnancies, including its removal from the market. The Columbus Dispatch (07/14/1996) documented David Grahams' (section chief of the FDA's epidemiology branch) investigation of the situation and detailed several documents and memos which showed the FDA battling itself and Hoffman-LaRoche. Such documents revealed that between 1982 and 1987 approximately 1.2 million people were treated with Accutane. 560,000 were women of which 427,000 were between the ages of 12 and 44, and more than 90% of females treated did not have severe cystic acne. In a 1990 memo Graham wrote "The magnitude of injury and death has been great and permanent with 11,000 to 13,000 Accutane-related abortions and 900-1,100 Accutane-related birth defects. There is no alternative to immediate withdrawal". This analysis by Graham provides strong evidence that the overwhelming use of Accutane is not for severe acne.

INDICATIONS FOR USE - Failure to comply

The package insert approved indication for Accutane states that "Accutane is indicated for the treatment of severe recalcitrant nodular acne... Because of significant adverse effects associated with its use, Accutane should be reserved for patients with severe nodular acne who are unresponsive to conventional therapy including systemic antibiotics."

Despite the plethora of serious side-effects associated with Accutane therapy and the high number of exposed pregnancies which occur every year due to poor compliance with prescription guidelines, there is evidence of prescription outside of the specified indication. Published accounts document high rates of use in non-severe acne patients, and many authors endorse its use in mild and moderate acne, claiming an excellent safety profile. Clearly, teenagers with acne benefit from improvement of their disease. However, to ignore the serious reports of depression and other psychiatric toxicities is to continue to place this population at risk.

SUMMARY AND RECOMMENDATIONS

While the future may hold interesting possibilities for the therapeutic uses of the retinoids, the present ambiguity about therapeutic versus potential hazardous side-effects of these retinoids, shows that a greater level of scrutiny needs to be given to adverse reactions. Given the increasing reports of depression and suicide associated with Accutane, special care must be exercised in prescription and in monitoring.

An FDA memo of February 1998 stated that for a majority of the evaluable cases of suicide, suicide attempt or suicide ideation associated with Accutane, for the majority, there was no antecedent history of depression, and the patients were not noted or known to be depressed in the time period prior to their suicide. As a result of underreporting, the actual number of suicides could be 10 times greater than the number of reports.

Clearly, Roche's and FDA's and Middelkoop's numbers differ and vary greatly. Any study, any case evaluation, any reporting system can be faulted, criticized, subject to bias and misinterpretation.

The numbers are alarming. The price is death and destruction of our children and young adults.

We don't need absolute scientific proof in order to recognize a signal and act on it. Indeed, the mechanism of action of Accutane in treating acne is unknown! In fact, the FDA rarely has more than signal before significant

warning changes and sometimes drug withdrawal occurs.

In my opinion, we have sufficient evidence to be very concerned and take some corrective steps. The link between Vitamin A toxicity, including CNS toxicity, and Accutane is indisputable. This gives us literature precedent and biologic plausibility. Opponents claim that the teenage population is at high risk for suicide. All the more reason to be cautious when prescribing Accutane, a drug which is suspected of causing psychiatric toxicity even though causality has not been proven. The link between retinoids and schizophrenia is biologically plausible.

I'm not suggesting that Accutane be withdrawn from the market. Clearly, for patients with severe acne, it has an important place in therapy. However, the drug is overwhelmingly prescribed for minor and moderate conditions, despite existing warnings to the contrary in the package insert.

Patient registries, independent epidemiologic studies, and scientific research documenting the pathophysiological basis of Accutane psychiatric toxicity are needed. A consumer education campaign via FDA consumer alerts, encouraging prescribers to limit prescriptions in non-severe patients and use whatever consent forms are developed can help inform the public and prescribers, and thus limit the toxicity. Clear patient package information, describing and informing of the psychiatric risks is important so that the patient and their family make a decision to accept the risk, and if so, to be vigilant for signs of toxicity, so that the drug can be stopped and the patient monitored. Since an informed consent is already designed to warn of pregnancy risks, the psychiatric toxicities could easily be added.

Table 1. Worldwide Psychiatric ADR Reports (WHO)

Medication	Extract period	Psychiatric ADRs (% of total)	Suicide	Suicide Attempt	Suicidal Ideation
*Roaccutane	1982-98	1095 (59.8)	47	67	56
Minocycline	1971-98	261 (14.2)	0	2	0
Doxycycline	1965-98	213 (11.6)	0	0	0
Tetracycline	1964-98	169 (9.2)	0	3	0
†Dianette	1980-98	55 (3.0)	0	3	0
Oxytetracycline	1965-98	37 (2.0)	0	0	0

*Roche data cut-off date May 1998

†Values for Dianette include data for ethinylestradiol and cyproterone

Table 2. UK ADR data (source: MCA)

Medication	Psychiatric ADRs (% of total)	Extract Period	Suicide	Suicide Attempt	Suicidal Ideation
Roaccutane	135 (51.5)	1982-99	9	8	6
Minocycline	45 (17.1)	1973-98	0	0	0
Tetracycline	32 (12.2)	1964-98	0	0	0
Oxytetracycline	23 (8.7)	1965-98	0	0	0
Doxycycline	22 (8.3)	1965-98	0	0	0
Dianette	5 (1.9)	1987-98	0	0	0

Table 3. Prescription Data (England 1982-97)

Medication	*Prescriptions (x1000)	Indication Acne
Tetracycline	147237.0	NA
Oxytetracycline	31301.7	NA
Doxycycline	13650.0	NA
Minocycline	8802.9	NA
Dianette	1214.6	184.2
Isotretinoin	12.4	12.4

*Data provided by Dept. of Health, Statistics Division 1E, Prescription Cost Analysis System

REFERENCES

- Aggarwal A: Acute toxicity of vitamin A administered with measles immunization [letter; comment]. *Comments Comment on: Indian Pediatr* 1996 Dec;33(12):1053-5 *Indian Pediatrics*. 34(5):456-7, 1997 May
- Alenayehu W: Pseudotumor cerebri (toxic effect of the "magic bullet"). *Source Ethiopian Medical Journal*. 33(4):265-70, 1995 Oct.
- Bendich A, Langseth L: Safety of vitamin A. *Am J Clin Nutr* 1989;49:358-371.
- Berrard S, Faucon BN, Houhou L, Lamouroux A, Mallet J. Retinoic acid induces cholinergic differentiation of cultured newborn rat sympathetic neurons. *J Neurosci Res* 1993;35:382-89.
- Bifulco MH: The relation of vitamin A intake to cerebrospinal fluid pressure. *J Mount Sinai Hosp NY* 1957;24:713-719.
- Bigby M, Stern RS: Adverse reactions to isotretinoin. *J Am Acad Derm* 1988;18:543-552.
- Bornetblanc JM, Hugon J, Dumas M: Intracranial hypertension with etretinate. *Lancet* 1983;22:974.
- Braun I: Vitamin A excess, deficiency, requirements, metabolism, and misuse. *Pediatr Clin North Am* 1962;9:935.
- Bravard P, Krug M, Rzeznick JC: Isotretinoin et depression: soyons vigilants. *Nouv Dermatol* 1993;12:215.
- Byme A, Costello M, Greene E et al: Isotretinoin therapy and depression - Evidence for an association. *Ir J Psych Med* 1998;15(2):58-60.
- Comments Comment in: *Rev Neurol (Paris)* 1998 Nov;154(11):784-5
- Cunliffe WJ: Optimum treatment of acne: a mechanistic approach to a good clinical outcome. *Mod Med Ireland* 1998;28(7/8):31-34.
- Cunliffe WJ, van de Kerkhof PCM, Caputo R: Roaccutane treatment guidelines: Results of an international survey. *Dermatology* 1997;194:351-357.
- Drouet A and Valance J:[Benign intracranial hypertension and chronic hypervitaminosis A (see comments)]. [French]
- Elliot RA, Dwyer CG: Hypervitaminosis A: Report of a case in an adult. *JAMA* 1965;161:1157-1159.
- Fishbane S, Frei GL, Finger M, et al: Hypervitaminosis A in two hemodialysis patients. *American Journal of Kidney Diseases*. 25(2):346-9, 1995 Feb.

- Gatti S, Seri F: Acute depression from isotretinoin (letter). *J Am Acad Derm* 1991;25:132.
- Gerber A, Raab AP, Sobel AE: Vitamin A poisoning in adults: With description of a case. *Am J Med* 1954;16:729-745.
- Goldman SA, Kennedy DL, Graham DJ, Gross TP, Kapit RM, Love LA, and White GG: The Clinical Impact of Adverse Event Reporting, Staff College, Center for Drug Evaluation and Research, Food and Drug Administration, October, 1996.
- Goodman AB: Chromosomal locations and modes of action of genes of the retinoid (Vitamin A) system support their involvement in the etiology of schizophrenia. *Am J Med Gen* 1995;60:335-348.
- Goulden V, Layton AM, Cunliffe WJ: Current indications for isotretinoin as a treatment for Acne vulgaris. *Dermatology* 1995;190:284-287.
- Grissom LE, Griffin GC and Mandell GA: Hypervitaminosis A as a complication of treatment for neuroblastoma. *Pediatric Radiology*. 26(3):200-2, 1996.
- Guzzo CA, Lazarus GS, and Werth VP: Chapter 64 Dermatological Pharmacology in Goodman & Gillman's *The Pharmacological Basis of Therapeutics*, 9th Edition, 1996.
- Halter U: Der fall aus der Praxis (224). Akuter exogener reaktionstypus (Delirium) nach einnahme von Tigason. *Schweizerische Rundschau für Medizin Praxis* 1991;80:883-884.
- Haupt R: Acute symptomatic psychosis in vitamin A intoxication (authors translation) [German]. *Nervenarzt* 1977;48:91-95.
- Hauser SL: Isotretinoin May Be Implicated in Severe Depression. Update to Chapter 385: Mental Disorders and Chapter 55: Eczema, Psoriasis, Cutaneous Infections, Acne, and Other Common Skin Disorders in *Harrison's Principles of Internal Medicine*, 14th Edition, 1998
- Hazen PG, Carney JF, Walker AE et al: Depression - a side-effect of 13-cis retinoic acid therapy. *J Am Acad Derm* 1983;9(2):278-279.
- Hutchinson TA, Lane DA. Assessing methods for causality assessment. *J Clin Epidemiol* 1989, 42: 5-16.
- Jones JK. Determining Causation from Case Reports, in Strom BL, *Pharmacoepidemiology*, Second Edition, Wiley, New York, 1994, at page 365.
- Kane EK: Artie explorations in the years 1853, 1854, 1855. Philadelphia. Childs and Peterson Pub 1856;1:392.
- Kapur S: High levels of dopamine D2 receptor occupancy with low-dose haloperidol treatment: A PET study. *Am J Psychiatry* 1996;153(7):948-950.

- Landy D: Pibloktoq (hysteria) and inuit nutrition: Possible implication of hypervitaminosis A. *Soc Sci Med* 1985;21:173-185.
- Layton AM: Long-term safety and efficacy of oral isotretinoin in less severe acne. *Retinoids Today and Tomorrow* 1996;43:6-7
- Lee AG: Pseudotumor cerebri after treatment with tetracycline and isotretinoin. *Cutis* 1995;55:165-168.
- Lewin AH, Bos ME, Zusi, et al: Evaluation of retinoids as therapeutic agents in dermatology. *Pharmaceutical Research*. 11(2):192-200, 1994 Feb.
- Lombaert A, Carton H: Benign intracranial hypertension due to hypervitaminosis A in adults and adolescents. *Eur Neurol* 1976;14:340-350.
- Marcus R and Coulston AM: Chapter 63, Fat-Soluble Vitamins, Vitamin A, K, and E; Vitamin A, in Goodman & Gillman's *The Pharmacological Basis of Therapeutics*, 9th Edition, 1996.
- McCance-Katz EF, Price LH: Depression associated with vitamin A intoxication. *Psychosomatics* 1992;33(1):117-118.
- Meyskens, F.L. Jr. Short clinical reports. *J Am Acad Derm*, 6:732, 1982.
- Middelkoop T: Accutane: Focus on Psychiatric Toxicity and Suicide, Chapter in O'Donnell JT: *Drug Injury, Liability, Analysis and Prevention*, Lawyers & Judges Publishers, Tucson, AZ, 2000
- Nagai K, Hosaka H, Kubo et al: Vitamin A toxicity secondary to excessive intake of yellow-green vegetables, liver and laver. *Journal of Hepatology*. 31(1):142-8, 1999 Jul.
- Nulman I, Berkovitch M, Klein J: Steady-state pharmacokinetics of isotretinoin and its 4-oxo metabolite: Implications for fetal safety. *Pediatrics* 1998;38:926-930.
- Oliver TK and Havener WH: Eye manifestations of chronic vitamin A intoxication. *Arch Ophthalmol* 1953;60:19-22.
- Olver J: Keratomalacia on a "healthy diet". *Br J Ophthalmol* 1986;70:357-360.
- Orfanos CE, Zouboulis CC, Almond-Roesler B, Geilen CC: Current use and future potential role of retinoids in dermatology. *Drugs* 1997;53(3):358-388.
- Ortonne JP: Oral isotretinoin treatment policy. Do we all agree? *Dermatology* 1997;195(suppl 1):34-37.
- Pasquariello PS, Schut L, Borns P: Benign increased intracranial hypertension due to chronic vitamin A overdosage in a 26-month-old child. *Clin Pediatr* 1977;16:379-382.

Peck GL, et al: Treatment of Darier's disease, lamellar ichthyosis, pityriasis rubra pilaris, cystic acne and basal cell carcinoma with oral 13-cis-retinoic acid. *Dermatologica* 1978;157 (Suppl.):11.

Revue Neurologique. 154(3):253-6, 1998 Apr.

Riddell RH, ed. *Pathology of Drug-Induced and Toxic Diseases*. Churchill Livingstone, New York, 1982 (3-9).

Rose A, Matson D: Benign intracranial hypertension in children. *Pediatrics* 1967;39:227

Roytman M, Frumkin A, Bohn TG: Pseudotumor cerebri caused by isotretinoin. *Cutis* 1988;42:399-400.

Scheinman PL, Peck GL, Rubinow DR et al: Acute depression from isotretinoin. *J Am Acad Derm* 1990;22(6):1112-1114.

Scrip Magazine: French tighten rules on Roaccutane. *Scrip* 1996;2159:21.

Selhorst JB, Jennings S, et al: Liver lover's headache: Pseudotumor cerebri and vitamin A intoxication. *JAMA* 1984;252(24):3365.

Shapiro LE, Knowles SR, Shear NH: Comparative safety of tetracycline, minocycline and doxycycline. *Arch Dermatol* 1997;133:1224-30.

Sharieff GQ: Pseudotumor Cerebri and Hypercalcemia Resulting From Vitamin A Toxicity [Case Report]. *Volume 27(4) April 1996 pp 518-521*

Shaw EW, Niccoli JZ: Hypervitaminosis A: Report of a case in an adult male. *Ann Intern Med* 1953;39:131-134.

Siegel NJ, Spackman TJ: Chronic hypervitaminosis A with intracranial hypertension and low cerebrospinal fluid concentration of protein. *Clin Pediatr (Phila)* 1972;11:580-584.

Spector RH, Carlisle J: Pseudotumor cerebri caused by a synthetic vitamin A preparation. *Neurology* 1984;34:1509-1511.

Stimson WH: Vitamin A intoxication in adults: Report of a case with a summary of the literature. *New Eng J Med* 1961;265:369-373.

Villalobos D, Ellis M and Snodgrass WR: Isotretinoin (Accutane)-associated psychosis. *Vet Human Toxicol* 1989;31(4):231.

Wiegand UW, Chou RC: Pharmacokinetics of oral isotretinoin. *J Am Acad Derm* 1998;39(suppl. pt 3):S8-S12

Wilson JD: Chapter 79, Vitamin Deficiency and Excess. Vitamin Excess, Vitamin A and Carotenes in Harrison's Principles of Internal Medicine, 14th Edition, 1998

Adverse Medication Events

Roaccutane (Isotretinoin) and the Risk of Suicide: Case Report and a Review of the Literature and Pharmacovigilance Reports

Tzarina Middelkoop, PhD*

INTRODUCTION

Approved for use by the U.S. Food and Drug Administration (FDA) in 1982, Roaccutane (isotretinoin, 13-*cis* retinoic acid), a member of the family of compounds called retinoids, is well recognized as an effective therapy for the treatment of severe recalcitrant acne. In addition, clinical use of the retinoids has demonstrated their effectiveness in acneiform eruptions, disorders of keratinization, and neoplasia.¹

The mechanism of the anti-acne action of isotretinoin is unknown. It is unique in its ability to affect, albeit not to the same degree, all the known etiological factors of acne: reduction of sebum production, lessening of comedogenesis, decreased surface and ductal colonization by *Propionibacterium acnes* and significantly diminished monocyte chemotaxis.²

Therapeutic response to isotretinoin is usually excellent. Unfortunately, it is not free of side effects. It is a well-known and potent teratogen. Other common side effects (more than 50% of patients) include

Disclosure: This investigation was funded by Liam Grant, the father of the young man reported as a suicide case described herein. A wrongful death lawsuit against the manufacturer of Roaccutane was filed after the submission of this article.

*At the time of manuscript preparation and investigation of this matter, Dr. Middelkoop was a PhD student at the University College Dublin (UCD).

Tzarina Middelkoop, PhD, Geneticist, Serology Ltd., c/o 30 Boyne Court, Harold's Cross Rd., Dublin 6W, Ireland.

cheilitis, xerostomia, epistaxis, facial erythema, headache, conjunctivitis, ocular irritation, alopecia, dizziness, arthralgias, and apathy. Less common side effects associated with and reported in temporal relation to the use of isotretinoin include pseudotumor cerebri (PTC), paronychia, inflammatory bowel disease, bone changes, corneal opacities, seizures, and cataracts. In common with other retinoids at pharmacological doses, isotretinoin causes elevation of serum lipids, particularly triglycerides.

The Irish license (package insert) for Roaccutane states the drug is indicated for severe nodulocystic acne that is nonresponsive to conventional therapy including systemic antibiotics and is available only as a hospital-only prescription. However, many dermatologists believe it is time to reduce these restrictions to include use of isotretinoin for mild and moderate acne and advise early use of isotretinoin irrespective of the severity of the complaint.²⁻⁴ At the General Infirmary at Leeds, between 1983 and 1986, severe acne was the main indication for isotretinoin (79% of patients), which contrasts with current figures of 74% of patients with mild or moderate acne and only 16% with severe acne.³ Use of oral retinoids for other than the specified indication has been reported as well as prescription by unauthorized doctors.

HYPERVITAMINOSIS A

Isotretinoin, being an analog of Vitamin A (retinol), shares many of the side effects experienced with Vitamin A. Hypervitaminosis A is the condition resulting from an excess of retinol in the

body. Retinol binds to Retinol Binding Protein (RBP). When the amount of retinol present exceeds the capacity of RBP to bind to it, the excess retinol is bound by lipoprotein, and in this form, it has toxic effects.⁵ Typical symptoms of hypervitaminosis A include irritability, headache, fatigue, myalgia, vomiting, dry skin, and after prolonged exposure, PTC may occur.

The central nervous system (CNS) manifestation of Vitamin A intoxication was first described in 1856 by Elisha Kane, the Arctic explorer.⁶ Following ingestion of polar bear liver (later found to contain a high concentration of Vitamin A), he recorded symptoms of vertigo, headache, drowsiness, and irritability. Over the succeeding 140 years, case reports of the occurrence of acute schizophrenia or remitting psychosis associated with hypervitaminosis A^{7,8} have appeared in the European and U.S. literature. First described by Gerber et al. in 1954,⁹ PTC has long been documented to occur in association with Vitamin A administration.^{10,11} PTC has also been documented in association with isotretinoin therapy^{12,13} and with the use of the retinoid, etretinate.¹⁴ In 1972, Restak et al. reported a case of toxic psychosis in a patient following Vitamin A treatment (50,000 IU 2-3 times daily) for acne.¹⁵ Other reports of depression,¹⁶ lethargy and loss of interest in surroundings,¹⁷ insomnia and listlessness,¹⁸ profound daily fatigue,¹⁹ and irritability²⁰ in association with Vitamin A have been recorded.

CASE REPORT

A 21-year-old male was seen by his general practitioner (GP) in 1996. Acne

was present on his chin and shoulders and was graded as 0.5 (scale of 0-5). He was prescribed topical Clindamycin (Clindamycin—U.S.). One month later, an improvement in his acne was recorded and he was prescribed Minocin SA 100 mg/d for two months. At his request, he was referred to a dermatologist. His only concurrent medication was a Flixotide inhaler for asthma, which he had been using for a number of years. The dermatologist graded his acne at 2 (scale of 1-10), prescribed Roaccutane 60 mg/d and asked him to return in a month. While on treatment, he developed the usual side effects of cheilitis, xerostomia, facial peeling, and mild photophobia.

Prior to starting isotretinoin therapy, the patient was outgoing and happy. He had no personal history of depression, and there was no family history of affective disorders. During his consultations with the dermatologist, on no occasion did he report that the acne was causing him anxiety. However, beginning with the second month of treatment, his family and friends noticed a change in his personality and behavior. He became withdrawn and solitary, which was unusual for him. His family reported to the GP that they thought his appetite had decreased, he had lost interest in his usual activities, and he tired more easily than usual. He was not however, seen by his GP during this period. While on treatment, he was seen on two occasions by his dermatologist. During his fourth month of treatment, he committed suicide.

A coroner's court was convened 13 months after the patient's demise. The conclusion of the court was that the cause of death was suicide. A rider to the coroner's conclusion was added suggesting that more emphasis be placed on isotretinoin patient information and that further research should be carried out into these effects of isotretinoin.

ADVERSE DRUG REACTION REPORTS

Following the case reported above, the family of the decedent commissioned an investigation into the adverse experiences of isotretinoin. The author was a

part of the investigative team. A review of the literature and reported adverse reactions (ADRs) to this drug was carried out to discover whether other cases with similar features had been described in the literature.

A MEDLINE search of isotretinoin therapy and its effects on mood (1980-1998) revealed 24 cases of psychological distress associated with the use of this drug.²¹⁻²⁹ Many of these cases reported the subsequent emergence of depression with features similar to that of hypervitaminosis A. Suicide²² and attempted suicide²³ in association with isotretinoin therapy have also been reported.

A study in 1983 showed 5.5% (6/110) of patients with acne experienced depressive symptoms, as evidenced by the occurrence of malaise, crying spells, and forgetfulness within two weeks of commencing isotretinoin.²⁴ Meyskens also noted similar psychological changes in patients with cancer treated with 3 mg/kg/d isotretinoin.²⁵ The ADR Reporting System of the American Academy of Dermatology received reports of 104 suspected adverse reactions to isotretinoin between October 1982 and June 1985,²⁶ of which CNS represented 22.1% (23/104), second only to skin and mucous membrane reactions (27.9%, 29/104). These CNS reactions included headache, depression, dizziness, and personality disorder. The relationship of depression to isotretinoin therapy was confirmed by rechallenge (Scheinman et al.²⁷) that reported that 1% (7/700) of patients treated with oral isotretinoin developed depressive symptoms, the severity of which interfered with their normal functioning. This relationship was also confirmed by Villalobos et al.²⁸ Byrne et al.²⁹ described the persistence of depressive symptoms that required active treatment in three patients following cessation of isotretinoin. Despite the recurrence of acne in one of the patients, follow-up showed no depressive symptoms.

Concerns about the safety of isotretinoin have been raised in the past. In 1998, reports surfaced in the media associating this drug with suicides (one in Ireland; two in the UK; two in the U.S.A.)

and attempted suicides (one in the UK; one in the U.S.A.).

In addition to Roaccutane, ADRs for five of the most commonly prescribed anti-acne treatments (Dianette, doxycycline, minocycline, oxytetracycline, and tetracycline) were reviewed. ADR data was obtained from the World Health Organization (WHO), UK Medicines Control Agency (MCA), and the manufacturer, Roche. The search for ADRs listed under Dianette included searches carried out under its active ingredients (ethinylestradiol and cyproterone).

Based on the available information, there were more reports of psychiatric adverse events and suicide from isotretinoin than from the use of the other five acne therapies combined (Table 1). Worldwide, 1,830 reports of psychiatric events attributable to these six medications were identified, of which isotretinoin was implicated in 59.8% (1095/1830). Second to this was minocycline, implicated in 14.2% (261/1830). Forty-seven and 56 cases of suicide and suicidal ideation were reported in association with the use of Roaccutane, respectively, with none being reported for the other medications. Of 75 cases of attempted suicide reported, 89.3% (67/75) were associated with the use of isotretinoin, with 4% (3/75) associated with the use of both Dianette and tetracycline, and 2.6% (2/75) for minocycline. ADR data for the UK (Table 2) reflect a similar pattern, with 51.5% (135/262) of psychiatric ADRs attributed to isotretinoin. In addition, all cases of suicide/suicide attempt/suicide ideation were associated with the use of this medication. The source for this data relies on voluntary reporting and probably represents significant underreporting.

Table 3 shows the number of prescription items dispensed in England from 1982 to 1997. Isotretinoin, while attracting the largest percentage of psychiatric ADRs, had the lowest number of prescriptions issued (12,400). During this period, 1,214,600 prescriptions were dispensed for Dianette. The indication in 184,200 cases was given as acne. Dianette was implicated in only 1.9% (5/262) of psychiatric ADRs.

Table 1. Worldwide Psychiatric ADR Reports

Medication	Extract Period	Psychiatric ADR's (% of total)	Suicide	Suicide Attempt	Suicidal Ideation
Roaccutane ^a	1982-1998	1095 (59.8%)	47	67	56
Minocycline ^b	1971-1998	261 (14.2%)	0	2	0
Doxycycline ^b	1985-1998	213 (11.6%)	0	0	0
Tetracycline ^b	1964-1998	169 (9.2%)	0	3	0
Dianette ^b	1980-1998	55 (3%)	0	3	0
Oxytetracycline ^b	1965-1998	37 (2%)	0	0	0

^aRoche Laboratories Ltd, Ireland, cutoff date May 31, 1998.

^bWHO Data, cutoff date August 1998.

Table 2. UK ADR Data (Source: MCA)

Medication	Psychiatric ADR's (% of total)	Extract Period	Suicide	Suicide Attempt	Suicidal Ideation
Roaccutane ^a	135 (51.5%)	1963-1999	9	8	6
Minocycline	45 (17.1%)	1973-1998			
Tetracycline	32 (12.2%)	1964-1998			
Oxytetracycline	23 (8.7%)	1965-1998			
Doxycycline	22 (8.3%)	1965-1998			
Dianette	5 (1.9%)	1987-1998			

^aData for Roaccutane, cutoff date July 1999.

Table 3. Prescription Data (England 1982-1997)

Medication	Prescriptions ^a (x1000)	Indication, Acne
Tetracycline	147,237.0	
Oxytetracycline	31,301.7	
Doxycycline	13,650.0	
Minocycline	8,802.9	
Dianette	1,214.6	184.2
Isotretinoin	12.4	12.4

^aData provided by Dept. of Health, Statistics Division 1E, Prescription Cost Analysis System.

Minocycline is used extensively in the treatment of acne vulgaris (8,802,000 prescriptions issued between 1982-1997). Between 1970-1997, 6.5 million patients³⁰ were treated with minocycline in the UK. A total of 45 psychiatric adverse events were received by the MCA between 1973 and 1997. Roaccutane has a UK patient exposure of 50,000 (8 million worldwide, PharmaFocus data) and has received reports of 135 psychiatric adverse events. Based on these figures, the incidence rates of psychiatric adverse reactions for Roaccutane and Minocycline are 270 and 0.692 per 100,000 people treated, respectively. These medications (with the exception of Roaccutane) are used to treat conditions other than acne. As it was not possible to obtain patient exposure data for these medications where the indication was acne, the frequency of psychiatric reactions attributable to these medications, in the population of acne patients, could not be calculated.

Other authors have suggested that the association between isotretinoin and psychiatric morbidity is unlikely to be causal, attributing the depressive symptoms to the presence of acne. Cotterill and Cunliffe³¹ suggest that dermatological patients are at greater risk of suicide and suggest early use of isotretinoin to reduce this risk. However, their findings are open to an alternative interpretation. All but one of the cases they described had long-standing psychiatric illness (manic depression, alcoholism) or other risk factors for psychiatric morbidity (recently bereaved) prior to being seen by the authors.

REVISED LABEL INFORMATION

On February 25, 1998, the FDA issued a Talk Paper declaring new safety information regarding isotretinoin, as a result of adverse event reports the agency had received. The revised information leaflet now reads "Psychiatric disorders: Accutane may cause depression, psychosis and, rarely, suicide ideation, suicide attempt and suicide. Discontinuation of Accutane therapy may be insufficient; further evaluation may be necessary. . . .

Of the patients reporting depression, some reported that the depression subsided with discontinuation of therapy and recurred with reinstitution of therapy." Earlier information leaflets read "depression has been reported in some patients on Accutane therapy. In some of these patients, this has subsided with discontinuation of therapy and recurred with reinstitution of therapy."

Almost one year prior to this U.S. package insert revision, the French product label was altered on March 3, 1997, to include "suicide attempt" as a side effect of isotretinoin therapy,³² and reads, "In rare occasions, neuropsychological problems have been recorded (behavioral difficulties, depression, convulsions and suicide attempts)." This revision was introduced in France as a result of the findings of a prospective national inquiry (1993-1994) in which Roche and more than 2,000 state dermatologists participated. The inquiry was initiated following a paper presentation that reported on a suicide associated with isotretinoin therapy.³³ The results of the inquiry were presented at the Third Forum of the National and Provincial Journal of Dermatology at Montpellier (March 14-17, 1996) but were never published. Revised warnings have now been introduced in Ireland (May 1998) and the UK (April 1998).

SUMMARY AND RECOMMENDATIONS FOR PRACTITIONERS

In view of the increasing concerns regarding the potential of this compound to cause depression, further research is required to allow this association to be fully evaluated. Dermatologists and other prescribing physicians should be well aware of this potential life-threatening adverse event, drug indications should be adhered to (don't use when less toxic drugs will suffice), and patients should be thoroughly screened and evaluated for signs of depression on a frequent and regular basis during therapy. Pharmacists should include this important warning in their counseling of patients who use isotretinoin and their families.

ACKNOWLEDGEMENTS

The author acknowledges the assistance and counsel of Professor Brian Leonard, Department of Pharmacology, University College, Galway, Ireland.

REFERENCES

1. Claudy, A.L., Rouchouse, B., Boucheron, S. and Le Petit, J.C. Treatment of cutaneous lymphoma with Euretinate. *Br J Derm.* 109:49-56, 1983.
2. Cunliffe, W.J., van de Kerhof, P.C.M. et al. Roaccutane Treatment Guidelines: Results of an international survey. *Dermatology*, 194: 351-357, 1997.
3. Goulden, V., Layton, A.M. and Cunliffe, W.J. Current indications for isotretinoin as a treatment for acne vulgaris. *Derm.* 190:284-287, 1995.
4. Layton, A.M. Long term safety and efficacy of oral isotretinoin in less severe acne. *Retinoids Today and Tomorrow*, 43:6-7, 1996.
5. Basemirfend, J.C. The safe use of vitamin A: a report of the International Vitamin A Consultative Group, Washington, DC: The Nutrition Foundation, 1980.
6. Kane, E.K. Arctic explorations in the years 1853, 1854, 1855. Philadelphia: Childs & Peterson Pub. 1:392, 1856.
7. Halter, U. Der Fall aus der Praxis (224). Akuter exogener reaktionstypus (delirium) nach einnahme von tigason. *Schweizerische Rundschau für Medizin Praxis*, 80:883-884, 1991.
8. Haupt, R. Acute symptomatic psychosis in vitamin A intoxication (author's translation) [German]. *Nervenarzt*, 48:91-95, 1977.
9. Gerber, A., Raab, A.P. and Sobel, A.E. Vitamin A poisoning in adults with description of a case. *Am J Med*, 16:729-745, 1954.
10. Lombaert, A. and Carton, H. Benign intracranial hypertension due to hypervitaminosis A in adults and adolescents. *Eur Neurol*, 14:340-350, 1976.
11. Siegel, N.J. and Spackman, T.J. Chronic hypervitaminosis A with intracranial hypertension and low cerebrospinal fluid concentration of protein. *Clin Pediatr (Phila)*, 11:580-584, 1972.
12. Lee, A.G. Pseudotumor cerebri after treatment with Tetracycline and Isotretinoin. *Cutis*, 55:165-168, 1995.
13. Rojzman, M., Frumkin, A. and Bohn, T.G. Pseudotumor cerebri caused by isotretinoin. *Cutis*, 42:399-400, 1988.
14. Bonnetblanc, J.M., Hugon, J. and

Bei PK
check -
year?
1972

- Dumas, M. Intracranial hypertension with etretinate. *Lancet*, October 22: 974, 1983.
15. Restak, R.M. Pseudotumor cerebri, psychosis, and hypervitaminosis A. *J Nerv Ment Dis*, 155(1):72-75, 1972.
16. McCaico-Katz, E.F. and Price, L.H. Depression associated with Vitamin A intoxication. *Psychosomatics*, 33(1):117-118, 1992.
17. Stinson, W.H. Vitamin A intoxication in adults: report of a case with a summary of the literature. *New Engl J Med*, 265:369-373, 1961.
18. Bifulco, M.H. The relation of Vitamin A intake to cerebrospinal fluid pressure: A review. *J Mount Sinai Hosp NY*, 24:713-719, 1957.
19. Elliot, R.A. and Dyer, C.G. Hypervitaminosis A: Report of a case in an adult. *JAMA*, 161:1157-1159, 1965.
20. Oliver, T.K. and Havener, W.H. Eye manifestations of chronic vitamin A intoxication. *Arch Ophthalmol*, 60:19-22, 1958.
21. Duke, E.E. and Guenther, L. Psychiatric reactions to the retinoids. *Can J Derm*, 5(4):467, 1993.
22. Gasti, S. and Senni, F. Acute depression from isotretinoin (letter). *J Am Acad Derm*, 25:132, 1991.
23. Bravard, P., Krug, M. and Rzeznick, J.C. Isotretinoin et depression: soyens vigilants. *Nouv Dermatol*, 12:215, 1993.
24. Hazen, F.G., Carney, J.F., Walker, A.E. and Stewart, J.J. Depression—a side effect of 13-cis-retinoic acid therapy. *J Am Acad Derm*, 9(2):278-279, 1983.
25. Meyskens, F.L. Jr. Short clinical reports. *J Am Acad Derm*, 6:732, 1982.
26. Bigby, M., Stern, R.S. Adverse reactions to isotretinoin. *J Am Acad Derm*, 18:543-552, 1988.
27. Scheinman et al. Acute Depression from isotretinoin. *J Am Acad Derm*, 22(6):1112-1114, 1990.
28. Villalobos, D., Ellis, M. and Snodgrass, W.R. Isotretinoin (Accutane)-associated psychosis. *Vet Human Toxicol*, 31(4), 131, August 1989.
29. Byrne, A., Costello, M., Greene, E. and Zibin, T. Isotretinoin therapy and depression: evidence for an association. *Ir J Psych Med*, 15(2):58-60, 1998.
30. Shapiro, L.E., Knowles, S.R. and Shear, N.H. Comparative safety of tetracycline, minocycline and doxycycline. *Arch Dermatol*, 133:1224-1230, 1997.
31. Cotterill, J.A. and Cautelle, W.J. Suicide in dermatological patients. *Br J Derm*, 137:246-250, 1997.
32. French Product License Data Sheet. B.I.A.M. 03/03/1997.

Six space
on ref.

AC CUTANE

FDA Memorandum dated 2/23/98

Page 1

MEMORANDUM **DEPARTMENT OF HEALTH AND HUMAN SERVICES**
PUBLIC HEALTH SERVICE
FOOD AND DRUG ADMINISTRATION
CENTER FOR DRUG EVALUATION AND RESEARCH

DATE: FEB 23 1998

FROM: Roger Goetsch, PharmD.
Postmarketing Safety Evaluator, HFD-735

 Amariys Vega, MD., M.P.H.
 Medical Officer, HFD-733

THROUGH: Ralph Lillie, R.Ph., M.P.H., Acting Director *Delegation for Lillie's office*
Division of Pharmacovigilance and Epidemiology, HFD-730

SUBJECT: Isotretinoin and Depression: Spontaneous reports data presented to the Division of
Dermatologic and Dental Drug Products on 1/28/98.

TO: Jonathan Wilkin, MD., Director
Division of Dermatologic and Dental Drug Products, HFD-540

This document contains the data on isotretinoin, depression and suicide presented to the Division of Dermatologic and Dental Drug Products on 1/28/98 as requested by Dr. O'Connell.

METHODS

We reviewed the Spontaneous Reporting System database (SRS) in search of isotretinoin reports in which depression, manic depression, manic reaction, depression psychotic, psychosis and suicide attempt were the reported COSTART¹ terms. Hands-on case review was limited to: (1) reports which contained data on patient's response after discontinuation of isotretinoin therapy (dechallenge) as well as their response following reintroduction of the drug (rechallenge), and (2) those in which suicide attempt or suicide were the reported Costart terms. It should be noted that suicide attempt was added to the Costart Manual in 1989. The verbatim terms that were included are shown in table 1.

¹ COSTART - Coding Symbols for Theasaurus of Adverse Reaction Terms

[Back to FDA Memorandum date 2/23/98](#)

ACUTANE

FDA Memorandum dated 2/23/98

Page 2

Table 1. Reported terms associated with the Costart terms.

REPORTED TERM	COSTART TERM
Depression Suicidal	Depression Psychotic
Suicidal Depression	Depression Psychotic
Suicide	Suicide Attempt
Suicide Attempt	Suicide Attempt
Suicide Gesture	Suicide Attempt

SRS SEARCH RESULTS**I. Depression Reports**

There were a total of 506 case reports of depression with isotretinoin. Of these, 185 contained information on the results of dechallenge from isotretinoin. Within this latter group, there were 20 reports indicating the results of rechallenge with isotretinoin. These 20 reports with both dechallenge and rechallenge data were reviewed further and summarized below.

A. Sex distribution

9 males
9 females
2 sex unspecified

B. Age distribution

Mean: 23 years (n=19)
Range: 13 to 36 years
Median: 20 (n=19)

C. Distribution of cases by indication

10 Nodulocystic acne
8 Other types of acne
1 Non acne condition (not specified)
1 Hypersecretorial skin

D. Distribution of cases by outcome

5 Hospitalized
15 Outcome not listed

E. Past history of psychiatric illness

12 No
5 Yes
3 Not available

[Back to FDA Memorandum date 2/23/98](#)

AC CUTANE

FDA Memorandum dated 2/23/98

Page 3

Table 2 compares the first and the second treatment courses among the 20 patients with rechallenge to isotretinoin. Of note, the time to onset of depression in each course was about one month, and recovery (cessation of depression symptoms) was quick once isotretinoin was discontinued. Also, the duration of therapy with isotretinoin was shorter during the second course suggesting physician's lower tolerance for symptoms of depression.

Table 2

	FIRST COURSE	SECOND COURSE
TOTAL DOSE		
Median	50 mg	40 mg
Range	20-80	20-80
N	12	12
DURATION OF THERAPY		
Median	72 days	59 days
Range	4-153	1-126 days
N	14	11
TIME TO ONSET		
Median	31 days	35.5 days
Range	7-100 days	1-126 days
N	12	12
TIME TO RECOVER		
Median	3 days	3 days
Range	1 hour-8 days	15 hours-7 days
N	6	6
TOTAL RECOVERED	19 (19/19)	11 (10/10)

II. Suicide Reports

A total of 81 reports were retrieved for review. Of the total reports, 50 (62%) cases were excluded due to confounding factors. There is a list of the confounding cases excluded in table 3.

Table 3. Confounders

CONFOUNDER	NUMBER
Relevant psychiatric history	16
Relevant personal history	10
Occurred after Accutane therapy*	16
Days after 1-30	3
Days after 31-90	8
Days after 91+	5
Relevant overdose history	6
Unrelated to drug	2
Total	50
Possible Temporal Relationship	31
Grand Total	81

*The average number of days after Accutane therapy was 126 days (= 4 months).



[Back to FDA Memorandum date 2/23/98](#)

treatment for depression, under the theory that it could help people who were suffering from depression and poor self-image as a result of their acne. The FDA warning letter to Roche stated that this promotion was false and misleading, and that Accutane had never been approved for treatment of depression. In fact, quite the opposite was true, as you will read in the warning letter which is enclosed in the press packet. In pertinent part, the FDA states:

Roche, however, has not systematically studied the ability of Accutane to modify or prevent such illnesses as depression and has presented no basis for asserting that Accutane is effective in improving the psychosocial and emotional well-being of such patients. This claim is particularly troublesome in light of information recently presented in a Dear Doctor letter, that Accutane may cause depression, psychosis, and rarely, suicidal ideation, suicide attempts and suicide.

As parents, Laurie and I took the information we had found very seriously. As I said earlier, BJ had not shown signs of depression, and if we had known that this drug could cause depression, suicide ideation, or suicide, BJ would never have come into contact with Accutane. The warnings on BJ's Accutane package contained none of these risks. The only warnings contained on the package were for the side effects of : headaches, nausea, vomiting, blurred vision, changes in mood, severe stomach pain, diarrhea, rectal bleeding, persistent feeling of dryness of the eyes, and yellowing of the skin or eyes and/or dark urine. Nothing about depression, suicide ideation or suicide.

All Accutane package labeling currently state that before a woman takes Accutane she must read, understand, and sign a consent form.

As a parent, I would have wanted to know of the risk of depression, suicide ideation and suicide, before allowing my child to take this drug. As a legislator, I believe that the public has a right to know of all risks associated with prescription drugs. There needs to be a thorough study implemented to determine the connection between Accutane, depression, suicide ideation and suicide. The study should be conducted by an independent third party, not by the FDA or Roche.

I am speaking out now because of my concern raised by the information I discovered. I believe the public needs to make its own informed decision about the risks associated with Accutane.

I can say that what Laurie and I turned up on our own caused us concern that there appeared to be a link. The MedWatch in 1998 indicates that the FDA had enough concern regarding a link to advise the inclusion of an additional warning. In mid-September the FDA provided an Advisory Panel with a figure of 37 suicides attributed to the use of Accutane since 1983. The FDA raised their figure to 44 suicides over the same period after Roche corrected the FDA's number. My staff and I have painstakingly gone through the FDA's Adverse Event Reports connected with Accutane, and we found 54 suicides since 1998, the same year the FDA issued its MedWatch. Another 30 deaths that are most probably suicides occurred between 1983-1997, a time where the record-keeping was a little less precise. A total of 84 suicides and BJ's is not part of the adverse event reports. The compilation of

ACCUTANE

Background Information

Accutane/Roaccutane (Isotretinoin)

**Manufacturer: Hoffman-Roche, a Swiss Co.
Roche in U.S., Nutley N.J.**

Roche submitted its "new" drug application in July 1981 and the FDA approved it less than a year later on May 21, 1982.

1982-1988 - Thousands of women were warned only that the drug caused birth defects in animals, and no precautions were taken. "Between 1982-1988, more than 1000 babies were born missing ears, major organs and portions of the brain. Others were stillborn. Still others were aborted."

March 3, 1997 - France - French studies showed users of Accutane/Roaccutane suffered from severe depression and suicidal ideation. French equivalent of FDA ordered warning to consumers.

Accutane is Hoffman-Roche's second-largest-selling drug, bringing in \$800 million in sales in 1998.

[Homepage](#) | [Welcome Message](#) | [About Bart](#) | [Bart's News Stand](#) | [1st District Information](#) | [Visiting the Nation's Capital](#)
[How To Get In Touch](#) | [Constituent Services](#) | [Service Academy Nominations](#) | [Michigan's Higher Education](#) | [1st District](#)
[Web Links](#)

- **FDA should investigate whether Accutane is being over-prescribed and determine the impact of direct-to-children advertising on any such prescribing.**

If FDA does not have the authority to take any of these actions, they should immediately request the authority from Congress.

[Homepage](#) | [Welcome Message](#) | [About Bart](#) | [Bart's News Stand](#) | [1st District Information](#) | [Visiting the Nation's Capital](#)
[How To Get In Touch](#) | [Constituent Services](#) | [Service Academy Nominations](#) | [Michigan's Higher Education](#) | [1st District](#)
[Web Links](#)

ACCUTANE

Recommendations to Improve Patient Safety

*before my
seeing
in my
report*

1. CONCLUSIVE RESEARCH

- o Roche should commit to underwriting all necessary independent controlled studies on Accutane's risks of depression, suicidal ideation, suicide and other psychiatric disorders. Such studies should be designed in collaboration with the Food and Drug Administration (FDA) and be conducted by independent investigators.
- o Congress should secure additional funding for post-market research and surveillance at FDA and at the Agency for Health Research and Quality (AHRQ).

2. BETTER INFORMATION


Until conclusive research has been completed —

- All Accutane patients should receive and sign an informed consent form clearly warning of Accutane's risks of depression, suicide and other psychiatric disorders every time the physician prescribes the drug.
- FDA should immediately ensure that Accutane labeling and boxes display the same warnings as the physician package insert of Accutane's risks of birth defects and of depression, suicide and other psychiatric disorders.
- FDA should immediately issue a patient "MedGuide" with clear and prominent warnings of Accutane's risks of birth defects and of depression, suicide and other psychiatric disorders.
- Roche should make immediate public disclosure of all U.S. and international serious Accutane adverse drug reactions (ADRs), and commit to sharing all future serious Accutane ADRs with the FDA and the public within 21 days of their receipt.
- Roche should immediately notify FDA of any international regulatory action (e.g. new warnings).

3. MORATORIUM ON DIRECT-TO-CHILDREN ADVERTISING

Until conclusive research has been completed —

- Roche should commit to refraining from direct-to-consumer (DTC) and direct-to-children Accutane advertising, or agree to prominently disclose Accutane's risks of birth defects and depression, suicide and other psychiatric disorders in all such print and electronic advertising.



Articles Cited

in prepared

Congressional

Testimony

12/5/01

Joseph Donnell

Interlibrary Loan/Document Delivery Service
 Library of Rush University
 600 South Paulina, Suite 575
 Chicago, Illinois 60612

ARTICLE REQUEST

JAN 17 2001

This service is available only to RPSLMC faculty, staff and students registered to use Library services. Requests for articles may be placed in the Library using this form, or they may be faxed to (312) 942-3143. Use one form for each request.

\$6.00 (Regular)
 Average delivery within 10 business days

\$8.00 (Urgent)
 Delivery within 2 business days
 \$6.00 if after 2 business days

BILLING

Bill my department _____ Cost Center _____ Fund _____

Invoice me at the address below
 (Monthly invoices are payable upon receipt)

YOUR INFO

Name dr DR. JAMES O'DONNELL PHARM D

Address 1792 pPRESTWICK DRIVE INVERNESS,
IL 60067

Phone 991-4433

Pager _____ Fax _____

Faculty
 Student
 Staff

Nursing
 Medicine
 Allied Health
 Other

Call me when article arrives Fax article to me

Send to the above address

ARTICLE

11. Cunliffe WJ: Optimum treatment of acne: a mechanistic approach to a good clinical outcome. Mod Med Ireland 1998;28(7/8):31-34. *NOT*

Volume _____ Number _____ Date _____ pages _____ *Art A*

Author(s) _____

Modern Medicine of Ireland

► ILL: 5028628 :Borrower: IDL :ReqDate: 20010118 :NeedBefore: 20010201
 :Status: PENDING 20010118 :RecDate: :RenewalReq:
 :QCLC: 6718267 :Source: OCLCILL :DueDate: :NewDueDate:
 :Lender: *BRI,BRI,BRI

By signing this request, you agree to the conditions described on the back of this form. **Requests without a signature will be signed by the library.**

Only the British Library cares this, but not the year, Sci of

SIGNATURE _____ *Beate*

WARNING CONCERNING COPYRIGHT RESTRICTIONS

The Copyright Law of the United States (Title 17, United States Code) governs the making of photocopies or other reproduction of copyrighted material. Under certain conditions specified in the law, libraries and archives are authorized to furnish a photocopy or other reproduction. One of these specified conditions is that the photocopy or reproduction is not to be "used" for any purpose other than private study, scholarship, or research. If a user makes a request for, or later uses, a photocopy or reproduction, the user assumes the responsibility to obtain any necessary copyright permission for any further copying.

Interlibrary Loan/Document Delivery Service
 Library of Rush University
 600 South Paulina, Suite 575
 Chicago, Illinois 60612

ARTICLE REQUEST

This service is available only to RPSLMC faculty, staff and students registered to use Library services.
 Requests for articles may be placed in the Library using this form, or they may be faxed to (312) 942-3143. Use one form for each request.

\$6.00 (Regular)
 Average delivery within 10 business days

\$8.00 (Urgent)
 Delivery within 2 business days
 \$6.00 if after 2 business days

BILLING	<input type="checkbox"/> Bill my department _____ Cost Center _____ Fund _____
	<input checked="" type="checkbox"/> Invoice me at the address below (Monthly invoices are payable upon receipt)

JAN 17 2001

YOUR INFO	Name	dr DR. JAMES O'DONNELL PHARM D	<input checked="" type="checkbox"/> Faculty <input type="checkbox"/> Student <input type="checkbox"/> Staff <input type="checkbox"/> Nursing <input type="checkbox"/> Medicine <input type="checkbox"/> Allied Health <input type="checkbox"/> Other
	Address	1792 PRESTWICK DRIVE INVERNESS, IL 60067	
	Phone	991-4433	
	Pager	Fax	

Call me when article arrives

Fax article to me

Send to the above address




ARTICLE	57. Villalobos D, Ellis M and Snodgrass WR: Isotretinoin (Accutane)-associated psychosis. Vet Human Toxicol 1989; 31(4):231. _____ rages _____ ISSN _____
	Author(s) _____
	Article Title _____

▶ ILL: 4979644 :Borrower: IDL :ReqDate: 20010117 :NeedBefore: 20010216
 :Status: PENDING 20010117 :RecDate: :RenewalReg:
 :OCLC: 2765341 :Source: OCLCILL :DueDate: :NewDueDate:
 :Lender: *IAX, KLG, HLG, PPC, DRU

*Dr. O'Donnell, This one came back unfilled
 Sent out to Subject Librarian SIGNATURE no one could fill sorry*

WARNING CONCERNING COPYRIGHT RESTRICTIONS

The Copyright Law of the United States (Title 17, United States Code) governs the making of photocopies or other reproduction of copyrighted material. Under certain conditions specified in the law, libraries and archives are authorized to furnish a photocopy or other reproduction. One of these specified conditions is that the photocopy or reproduction is not to be "used" for any purpose other than private study, scholarship, or research. If a user makes a request for, or later uses, a photocopy or reproduction in violation of the copyright law, the user may be subject to criminal sanctions. This institution reserves the right to refuse to accept copying requests that, in its judgment, may result in excessive copying.

	<input type="checkbox"/> Yes	ate Requested: 1/17/01
	<input type="checkbox"/> No	
	<input type="checkbox"/> Conditional	Due Date:
ILL: 4976068	Borrower: IDL	Shipped:
IAB,IAX,*JFU,INM,PPC	Clio Status: InProcess	Future Date:
Maxcost: 50.00	Call Number:	
OCLC Number: 1644609	Copyright CCG	
Verified: OCLC ISSN: 0099-9695	Compl:	
Fax:		
Patron: O'Donnell,J		
Title: Journal of the Mount Sinai Hospital, New York		
Author: Mount Sinai Hospital (New York, N.Y.)		
Edition: Imprint: Baltimore, Committee on Medical Education and Publ		
Article: The relation of vitamin A intake to...		
Vol: 24	No.:	Pages: 713-719
Date: 1957		
Borrowing DO NOT SEND ILDS - WE ARE NOT ON ILDS ROUTE		
Notes:		
		

Return To:

Loyola University Health Sciences Library
 Interlibrary Loan
 2160 S. 1st Ave.
 Maywood, IL 60153

Ship To:**ILL**

Rush University Library
 600 S. Paulina
 Chicago, IL 60612



ILL: 4976068

Borrower: IDL

Req Date: 1/17/01

OCLC #: 1644609

Patron: O'Donnell,J

Author: Mount Sinai Hospital (New York, N.Y.)

Title: Journal of the Mount Sinai Hospital, New

Article: The relation of vitamin A intake to...

Vol.: 24

No.:

Date: 1957

Pages: 713-719

Maxcost: 50.00

Due Date:

Lending Notes:

Bor Notes: DO NOT SEND ILDS - WE ARE NOT ON
 ILDS ROUTE

to Dr. Donald N. Adler, resident in obstetrics and gynecology at Harbor Hospital, for collaboration in the studies of umbilical-cord blood and placentas.

REFERENCES

1. Gitlin, D., and Craig, J. M. Nature of hyaline membrane in asphyxia of newborn. *Pediatrics* 17:64-71, 1956.
2. van Breezen, V. L., Neustein, H. B., and Bruns, P. D. Pulmonary hyaline membranes studied with electron microscope. *Am. J. Path.* 33:769-789, 1957.
3. Lendrum, F. C. "Pulmonary hyaline membrane" as manifestation of heart failure in newborn infant. *J. Pediat.* 47:149-156, 1955.
4. Gruenzwald, P. Significance of pulmonary hyaline membranes in newborn infants. *J.A.M.A.* 168:621-623, 1958.
5. Shanklin, D. R. Cardiovascular factors in development of pulmonary hyaline membrane. *Arch. Path.* 58:49-57, 1959.
6. James, L. S. Physiology of respiration in newborn infants and in respiratory distress syndrome. *Pediatrics* 24:1069-1101, 1959.
7. Rudolph, A. M., et al. Studies on circulation of infants with hyaline membrane disease. *J. Di. Child.* 98:630, 1959.
8. Dronbaugh, J. E., Rudolph, A. J., Auld, P. A. M., Cherry, R. B., and Smith, C. A. Clinical observations on the cardiopulmonary status of infants with hyaline membrane disease. *J. Di. Child.* 98:663, 1959.
9. Smith, C. A. Circulatory factors in relation to idiopathic respiratory distress (hyaline membrane disease) in newborn. *J. Pediat.* 58:605-611, 1960.
10. Phillips, L. L., and Skrodele, V. Comparison of fibrinolytic enzyme system in maternal and umbilical-cord blood. *Pediatrics* 22:715-726, 1958.
11. Lieberman, J. Clinical syndromes associated with deficient lung fibrinolytic activity. I. New concept of hyaline-membrane disease. *New Eng. J. Med.* 260:519-525, 1959.
12. Lieberman, J., and Kelloff, F. Deficiency of pulmonary fibrinolysis in hyaline-membrane disease. *New Eng. J. Med.* 262:999-1004, 1960.
13. Quis, F. G., and Wannamaker, L. W. Plasminogen-plasmin system of newborn infants: investigation of nature and persistence of deficiency of this system in human infants. *J. Di. Child.* 100:836-843, 1960.
14. Astrup, T., and Permin, P. M. Fibrinolysis in animal organism. *Nature (London)* 183:681, 1947.
15. Astrup, T., and Stage, A. Isolation of soluble fibrinolytic activator from animal tissue. *Nature (London)* 170:329, 1952.
16. Macfarlane, R. G., and Pilling, J. Cited by Macfarlane, R. G., and Biggs, R. Fibrinolysis: its mechanism and significance. *Blood* 3:1167-1187, 1948.
17. Albrechtsen, O. K. Fibrinolytic agents in saline extracts of human tissues. *Scandinav. J. Clin. & Lab. Invest.* 10:91-96, 1958.
18. Lieberman, J. Clinical syndromes associated with deficient fibrinolytic activity of lung. II. Cystic fibrosis of pancreas. *Pediatrics* 25:418-431, 1960.
19. Astrup, T., and Mülleritz, S. Fibrin plate method for estimating fibrinolytic activity. *Arch. Biochem.* 40:345-351, 1952.
20. Fleming, W. H., and Norman, P. S. Non-enzymatic lysis of fibrin *in vivo* by bile. *Proc. Soc. Exper. Biol. & Med.* 104:636-638, 1960.
21. Astrup, T., and Albrechtsen, O. K. Estimation of plasminogen activator and trypsin inhibitor in animal and human tissues. *Scandinav. J. Clin. & Lab. Investigation* 9:225-243, 1957.
22. Editorial. Pulmonary syndrome in newborn. *Lancet* 1:1234, 1959.
23. Cohen, M. M., Weintraub, D. H., and Lilienfeld, A. M. Relationship of pulmonary hyaline membrane to certain factors in pregnancy and delivery. *Pediatrics* 28:42-50, 1960.
24. Fleming, W. H., Szakacs, J. E., Hartney, T. C., and King, E. R. Hyaline membrane following total body radiation: relation to lung plasminogen activator. *Lancet* 2:1010, 1960.
25. Page, E. W., Glendonig, M. B., and Parkinson, C. Cyclic biochemical changes in human endometrium: with special reference to fibrinolytic enzyme. *Am. J. Obst. & Gynec.* 85:1100-1103, 1961.
26. Albrechtsen, O. K. Fibrinolytic activity of human endometrium. *Acta endocrinol.* 23:207-218, 1956.
27. *Idem*. Fibrinolytic activity in organism. *Acta physiol. Scandinav.* 47 (Suppl. 153): 1-112, 1959.
28. Whitehead, W. H., Windle, W. F., and Becker, R. F. Changes in lung structure during aspiration of amniotic fluid and during breathing at birth. *Anat. Rec.* 83:253-263, 1942.
29. Reynolds, S. R. Source of amniotic fluid in lamb: naso-pharyngeal and buccal cavities. *Nature (London)* 172:307, 1953.
30. Setnikar, I., Argostoni, E., and Taglietti, A. Fetal lung: source of amniotic fluid. *Proc. Soc. Exper. Biol. & Med.* 101:843-845, 1959.

VITAMIN A INTOXICATION IN ADULTS

Report of a Case with a Summary of the Literature

WILLIAM H. STIMSON, M.D.*

SEATTLE, WASHINGTON

PREVIOUS summaries have considered the symptoms of vitamin A excess in children and adults together. Most of them have been published in pediatric journals. Because of the striking uniformity of the major symptoms in adults it seems worth while to analyze them alone even though only 6 cases have previously been reported. Although the symptoms are quite troubling to the patient they are often so mundane that the physician does not readily pursue them to a diagnosis. It is hoped that with broader awareness the phenomenon may be recognized earlier and its future occurrence prevented. Two distinct types exist, acute and chronic. The acute, which is usually due to a large single dose, is self-limited and results in spontaneous recovery. The chronic may be unrecognized for years. Cases summarized here were all of the chronic type.

CASE REPORT

On January 5, 1960, a 32-year-old homemaker, a former nurse, was referred to the Clinic in Internal Medicine at the United States Public Health Service Hospital with a puzzling picture of intermittent abdominal pain and tenderness, anorexia, nausea, easy fatigability, low-back, right-hip and tibial pain, hepatosplenomegaly and leukopenia.

*Medical director and chief, Medical Service, United States Public Health Service Hospital.

In May, 1958, she had been seen at this hospital because of the onset of nausea and right-lower-quadrant pain and tenderness. The white-cell count was 7100, and she was thought to have subsiding acute appendicitis. Two weeks later she was again seen with the same symptoms and a feverish feeling. The temperature was 99.6°F. The right lower quadrant of the abdomen was tender, with slight guarding but no rebound tenderness. The white-cell count was 4900, with a normal differential. A plain film of the abdomen and a gall-bladder series were normal. About 1 year later she was seen because of epigastric and subcostal discomfort, which tended to migrate to the right lower quadrant of the abdomen. In addition, she had noted malaise and easy fatigability and had acquired the habit of taking afternoon naps. Mild anorexia had caused her to omit occasional meals. Again right-lower-quadrant tenderness was present. The spleen had become palpable just below the left costal margin. The white-cell count was 3200, with 5 per cent band forms, 47 per cent neutrophils, 33 per cent lymphocytes, 9 per cent monocytes, 5 per cent eosinophils and 1 per cent basophils. Abdominal symptoms and signs subsided over the next few days, but malaise and lethargy persisted. In September, 1959, mild aching developed in the right sacroiliac and hip regions. In December she returned because of urinary frequency and urgency and a sensation of pressure in the suprapubic area. The spleen and liver were readily palpable, and there was tenderness in the right lower quadrant of the abdomen. Urinalysis was negative. The white-cell count was 4500, with 3 per cent band forms, 38 per cent neutrophils, 54 per cent lymphocytes, 2 per cent monocytes and 3 per cent eosinophils. The hemoglobin was 14 gm. per 100 ml., and the sedimentation rate (Westergren technic) 9 mm. in 1 hour. Two tests for L.E. cells were negative.

She specifically denied taking medication of any nature, including vitamins. Physical examination revealed a well

developed and well nourished woman of about the stated age who appeared somewhat tired. The hair was sparse over the anterior central crown. The eyes were prominent, and on comparison with a picture taken 10 years previously she thought that they had become more prominent. Exophthalmometric readings were 18.5 mm, the upper limit of normal. Anterior and posterior cervical lymph nodes varied from 0.5 to 2 cm. across and were soft and freely movable. Mild tenderness in the right lower quadrant of the abdomen was elicited on deep palpation. The liver and spleen were palpable 3 cm. below the respective costal margins, and the liver was tender. Urinalysis, white-cell and differential counts, hemoglobin, hematocrit, sedimentation rate, platelets, sternal bone marrow, serum bilirubin, cephalin flocculation, thymol turbidity, bromsulfalein and serum albumin and globulin were all within normal limits. Heterophi-antibody agglutination was negative.

Three weeks later, on her 3d visit, the patient continued to complain of persistent lethargy and lack of interest in her daily activities. She continued to note dull pain in the right hip and sacroiliac regions, and pain and tenderness had developed in the right clavicle. She stated that her husband thought that she should tell me she had been taking vitamin A for 5 years. One hundred thousand units daily had originally been prescribed by a dermatologist for acne. She had continued it without prescription, at first somewhat irregularly but daily for the 2 years before being seen in January, 1960. On direct questioning she thought that her hair had been coming out rapidly. She had noted frequent bouts of painful lumps on the margin of the tongue, and the lips had required creams and lipstick to keep them moist.

original literature. It has often been necessary to take slight liberties with the various authors' words to group the findings more readily, but an attempt has been made to avoid a change in meaning. Table 1 identifies and lists the basic facts of each case. It will be noted that the smallest dose to produce symptoms was 50,000 units of vitamin A daily for eighteen months. Some larger doses caused symptoms earlier, but there was always a latent period before they developed. Partial relief, particularly of general and musculoskeletal symptoms, was very prompt in all cases upon withdrawal of vitamin A. Essentially complete recovery occurred in all cases in a matter of months.

Table 2 lists the symptoms in the 7 cases of chronic vitamin A intoxication in adults. Totals have been listed to show the relative occurrence in this small group. Future experience may significantly alter some of these. As one can see, the list has been deliberately inclusive because of the present state of ignorance. Nevertheless, certain features are relatively constant and warrant further discussion.

TABLE 1. Cases of Hypervitaminosis Thus Far Reported.

CASE NO.	SOURCE OF DATA	AGE	SEX	REASON FOR MEDICATION	DAILY DOSE	DURATION OF MEDICATION	DURATION OF TREATMENT BEFORE ONSET SYMPTOMS	INTERVAL BETWEEN WITHDRAWAL & RELIEF
		yr.			I.U.		days	
1	Subberger & Lazar ¹	44	F	Radio advertisement for dry throat & colds	600,000	18 mo.	12 mo.	10
2	Shaw & Niccoli ²	25	M	Not stated	275,000	2 mo.	6 wk.	9
3	Bifulco ³	32	F	Dry, fissured skin	100,000	4 yr.	12 mo.	7
4	Geiber et al. ⁴	38	F	Echthyma	500,000	8 yr.	15 mo.	17
5	Bleck ⁵	54	M	Eczema of legs	50,000	3 yr.	18 mo.	7
6	Elliot & Dryer ⁶	21	F	Acne	>150,000	7 mo.	5 mo.	10
7	Present report	32	F	Acne	100,000	5 yr.	3½ yr.	5

The liver was palpable 5 cm. below the right costal margin, and the tip of the spleen was also palpable. Tenderness was still present in the right lower quadrant of the abdomen. Percussion over the right tibia produced tenderness. The serum vitamin A level was 250 I.U. (normal, 50 to 200 I.U.). The serum calcium, phosphorus and alkaline phosphatase were normal. X-ray films of the long bones were normal.

Vitamin A was abruptly stopped, and within 3 days the patient noted marked improvement and no longer required daily naps. She felt renewed interest in her activities. The hip and back pain disappeared. She continued to note mild subcostal discomfort for 6 weeks. At that time the liver was still palpable at the right costal margin, but the spleen could no longer be felt. The white-cell count had returned to normal. Three months after stopping vitamin A she felt entirely well. The liver and spleen were palpable. The lips no longer required special care for dryness. The serum vitamin A had fallen to 104 I.U. She was still feeling entirely well 7 months after stopping vitamin A and had noted none of her previous symptoms. The liver was palpable 4 cm. below the right costal margin. Exophthalmometric readings were 18 mm. in both eyes — no change from those while on vitamin A.

COMPILATION OF CASES AND DISCUSSION OF SYMPTOMS AND SIGNS

All cases retain the same numbers throughout Tables 1-3 so that one may readily refer to the

General symptoms were present in all patients, but by far the most significant in frequency and severity was a feeling of fatigue. Some patients found it necessary to take daily naps to permit them to perform their tasks whereas others were eventually forced to give up their chores entirely. Lack of interest in surroundings was described in 2 cases and was implied in others. Women frequently noted shortening or cessation of the menstrual flow.

All patients had musculoskeletal symptoms, usually manifested by dull bone or joint pain, with occasionally severe pain. Usually, they complained of low-back ache that sometimes prevented sleep. Joint pain and sometimes stiffness, with little or no evidence of inflammatory involvement, was prominent. Occasionally, the pain seemed to be in the long bones, especially those of the legs, and was often aggravated by percussion. Clavicular pain and tenderness were present in 1 case. One prominent feature of all musculoskeletal symptoms was their tendency to wax and wane, with occasional periods of complete cessation. X-ray changes were present in only 1 case and

Except for 1 case neurologic symptoms were not prominent in adults, in contrast to children and infants. In adults the only frequent neurologic symptom was headache.

Hematologic findings were irregular. Mild anemia was found in 3 cases, leukocytosis in 2, and neutropenia in 1. Hemorrhage was a prominent symptom in 1 case and probably present in another.

headaches, dizziness, sluggishness, irritability and a strong desire to sleep coming on a few hours after ingestion. This is followed in a day or so by generalized peeling of the skin and full recovery.

Chronic toxicity in human beings, a much more recent phenomenon, depends upon concentrated vitamin preparations. In 1938 Clausen⁹ pointed out much suggestive evidence of clinical toxicity in

TABLE 3. Laboratory Findings.

Case No.	HEMOGLOBIN	RED-CELL COUNT	WHITE-CELL COUNT	CALCIUM	PHOSPHORUS	ALKALINE PHOSPHATASE	SERUM VITAMIN A ^a	SERUM LIPIDS	LIVER FUNCTION
	gm./100 ml.	$\times 10^6$	$\times 10^3$	mg./100 ml.	mg./100 ml.	units	per 100 ml.	mg./100 ml.	
1	14.0	4.2	13.0	9.2	3.5	4 (Bodansky)	60 blue units	893	—
2	12.0	3.9	(Normal)	13.3	3.1	7†	103 microgm.	—	Normal
3	10.5	3.5	6.9	—	—	—	—	—	—
4	31%	4.0	10.7	9.4	—	3.3 (Bodansky)	2000 I.U.	419	Normal
5	15.2	—	17.2	—	—	—	89 microgm.‡	(29 units)	Normal
6	14.6	4.4	7.3	—	—	2.2 (King-Armstrong)	832 microgm.	802	Normal
7	14.0	3.2	3.2	11.0	4.1	5 (King-Armstrong)	256 I.U.	652	Normal

^a1 microgm. equivalent to 3.3 USP or international units of vitamin A.

†Method not stated.

‡Performed 2 mo. after vitamin A stopped.

Prominence of the eyes, which was the one finding that did not regress on withdrawal of vitamin A, was found in 3 cases. Ulcerophlebitis, with bleeding, occurred in 1 case. Choked disks, diplopia and nystagmus were present in another.

Laboratory data are presented in Table 3. The only constant finding was elevation of the serum vitamin A, which in some cases was tremendous. There seems to be some positive correlation between the level and the severity of symptoms and also the length of time required to return to normal. Anemia has been mentioned. Since it is a common finding experimentally in animals it is probably related to the hypervitaminosis. Liver-function tests were within normal limits in all cases in which the liver was enlarged. Likewise, there was no abnormality of the bleeding, clotting or prothrombin time in the case with definite hemorrhage. Serum calcium, phosphorus and alkaline phosphatase were normal in all cases in which they were measured except for 1 case, in which the calcium was 13.3 mg. per 100 ml.

DISCUSSION

It has been common knowledge among Arctic peoples that liver from certain Arctic animals, especially the polar bear, was poisonous. One of the earliest written descriptions of toxicity (1596) is cited by Nieman and Klein Obbink.⁷ Rodahl and Moore⁸ in 1943, found polar-bear liver to contain from 13,000 to 18,000 I.U. of vitamin A per gram of wet tissue and were able to produce evidence of vitamin A toxicity in rats fed this. Symptoms of acute toxicity from a single dose are uniformly described as abdominal pain, nausea, vomiting, severe

human beings. Josephs¹⁰ described the first clinical case in 1944 in a three-year-old child. Oliver¹¹ summarized 36 cases, 27 in young children and infants, 3 in older children and 6 in adults. Morrice and his associates¹² recently reported 3 cases in adolescents.

Numerous animal experiments have demonstrated the toxic effects of large doses of vitamin A (Moore¹³ and Moore and Wang¹⁴). Nieman and Klein Obbink⁷ have nicely summarized the toxic effects in animals. Cohlman^{15,16} has shown that numerous congenital anomalies can be produced in the offspring of rats by administration of large doses of vitamin A.

Hillman¹⁷ induced symptoms of poisoning in a forty-year-old physician on two occasions, using doses of approximately 1,000,000 units daily for fourteen and twenty-five days, respectively. These were remarkably similar to those in the 7 reported cases. Frey and Schoch,¹⁸ in treating 9 patients for psoriasis with large doses of vitamin A, produced similar symptoms in 5. From the foregoing data it seems that there is reasonable experimental evidence that the symptoms found in the 7 clinical cases tabulated in this paper could all have been due to vitamin A toxicity. It is of interest, however, to note that the great majority of these symptoms are also present in vitamin A deficiency in animals, as tabulated by Moore.¹³

When one tries to explain the various symptoms one is immediately struck by the great lack of understanding of the actions of vitamin A. Nieman and Klein Obbink⁷ suggest that excess of vitamin A may produce secondary hypovitaminoses by displacement. Knudson and Rothman¹⁹ discuss clinicochemical correlation. Hepatomegaly is considered most probably

revealed calcification in the pericapsular, ligamentous, tendinous and subperiosteal tissues. in 1 case. Although pruritus occurred in only 2 cases it was a prominent symptom.

Most cases showed some change in the epithelial system. Loss of hair was most frequent and was often in 1 case. Although pruritus occurred in only 2 cases it was a prominent symptom. Gastrointestinal symptoms of anorexia and weight loss were relatively mild but could usually be obtained

TABLE 2. *Symptoms and Signs.*

SYSTEM & SYMPTOM OR SIGN PRESENT	NO. OF CASES	CASE NO.						
		1	2	3	4	5	6	7
General:								
Fatigue	5		X	X		X	X	X
Insomnia	3			X	X		X	
Decreased menstruation	3	X		X	X			
Fever, mild	1					X		
Night sweats	1	X						
Musculoskeletal:								
Bone or joint pain	7	X	X	X	X	X	X	X
Bone tenderness	3		X				X	X
Intermittent pain	3	X					X	X
X-ray changes	1				X			
Epithelial:								
Loss of hair	5	X	X	X	X			X
Desquamation or fissuring of lips	4	X	X	X	X			X
Desquamation, generalized	4	X	X	X	X		X	
Pigmentation or rash	4	X	X	X	X			
Sore tongue or mouth	3		X				X	X
Pruritus	2	X			X			
Oily skin	2		X				X	
Dry skin	1	X						
Gastrointestinal:								
Anorexia	4		X	X	X			X
Weight loss	3		X	X	X			
Nausea	2				X			X
Polydipsia	1		X					
Abdominal pain	1							X
Vague symptoms	1					X		
Reticuloendothelial:								
Hepatomegaly	5		X		X	X	X	X
Splenomegaly	2				X			X
Lymph-node enlargement	1							X
Hematologic:								
Anemia	3		X	X	X			
Leukocytosis	2	X				X		
Hemorrhage	2			X		X?		
Neutropenia	1							X
Genitourinary:								
Frequency	3				X		X	X
Urgency	2				X			X
Incontinence, nocturia, enuresis	1				X			
Polyuria	1		X					
Neurologic:								
Headache	3			X	X	X		
Diplopia, nystagmus, internal strabismus, choked disks	1				X			
Increased cerebrospinal-fluid pressure	1				X			
Eye:								
Prominence	3	X		X				X
Irritation & bleeding	1			X				

preceded by dryness and difficulty in grooming. It was usually manifested by general thinning on the scalp, but in some cases there was also loss of eyebrows and lashes and general body hair, including axillary and pubic. Dryness of the lips, frequently with desquamation and fissuring, particularly at the angles, occurred in over half the cases. The mouth and margins of the tongue were sore in 3 cases, and 2 patients described blisters on the edge of the tongue. Generalized desquamation and often dusky pigmentation were common, and a rash was described

either voluntarily or on questioning. Although it was present in only 1 case pain in the right upper and lower quadrants of the abdomen was an early and chief complaint, subsiding promptly on withdrawal of vitamin A.

Hepatomegaly was definite in 5 of the 7 cases and in 1 was variable from week to week. Splenomegaly was present in only 2 cases. Mild lymph-node enlargement was observed in 1 case and partially subsided after withdrawal of vitamin A.

Mild urinary frequency occurred in 3 and urgency in 2 cases and likewise subsided on withdrawal.

due to large deposits of vitamin A in the liver.⁷ It is of interest that Logan,²⁰ upon administration of 50,000 units of vitamin A to human beings for three weeks or more, reduced the I¹³¹ uptake. Still, none of these mechanisms are proved, and the literature is replete with contradictions.

Children and adolescents comprise the great majority of clinical cases of toxicity. They may have any of the manifestations of vitamin A intoxication seen in adults. They are much more apt to have increased intracranial pressure with concurrent neurologic signs and may even show bulging of the fontanels and papilledema. Bone changes are prominent, with swelling and tenderness over the long bones of the upper and lower extremities. In infants and toddlers x-ray study may reveal cortical hyperostosis, mottling or osteoporosis.

The adult daily requirement for optimum nutrition according to the National Research Council is 5000 units. During pregnancy and lactation the requirements are probably 50 per cent greater. Hume and Krebs²¹ found that 1 male subject experimentally depleted of vitamin A gradually regained dark adaptation on 1300 units of vitamin A daily, but the blood level did not rise to normal until this was increased to 2600 units daily. As can be seen, there is real danger of toxicity from protracted use of large doses, and when one deviates from the officially recommended dose one must watch for this.

SUMMARY

A case of chronic vitamin A intoxication in an adult is added to the 6 previously reported. All patients took at least 50,000 units of vitamin A daily for a protracted time. There was a latent period of weeks or months before the onset of symptoms somewhat inversely related to the size of the daily dose. Principal symptoms were bone or joint pain that tended to be intermittent, fatigue and insomnia, loss of hair, dryness and fissuring of the lips and other

epithelial involvement, anorexia and weight loss and hepatomegaly. Several other symptoms regarded as probably due to vitamin A intoxication were less common. Relief was prompt and nearly complete on withdrawal of vitamin A. The only diagnostic laboratory finding was an elevation of the serum vitamin A. The literature is reviewed for its clinical application.

REFERENCES

1. Sulzberger, M. B., and Lazar, M. P. Hypervitaminosis A: report of case in adult. *J.A.M.A.* 146:788-793, 1951.
2. Shaw, E. W., and Niccoli, J. Z. Hypervitaminosis A: report of case in adult male. *Ann. Int. Med.* 39:151-154, 1953.
3. Bittalo, E. Vitamin A intoxication: report of case in adult. *New Eng. J. Med.* 248:690-692, 1953.
4. Gerber, A., Rado, A. E., and Sobel, A. E. Vitamin A poisoning in adults with description of case. *Am. J. Med.* 16:729-745, 1954.
5. Bloch, H. S. Chronic hypervitaminosis A: report of probable case in man. *Minnesota Med.* 58:527-532, 1955.
6. Elliott, R. A., Jr., and Dewey, R. L. Hypervitaminosis A: report of case in adult. *J.A.M.A.* 181:1137-1139, 1956.
7. Nieman, C., and Klein Oboink, H. J. Biochemistry and pathology of hypervitaminosis A. *Vitamin & Hormones* 12:69-99, 1954.
8. Rodahl, K., and Moore, T. Vitamin A content and toxicity of bear and seal liver. *Biochem. J.* 27:166-168, 1943.
9. Clausen, S. W. Pharmacology and therapeutics of vitamin A. *J.A.M.A.* 111:144-154, 1938.
10. Joseph, H. W. Hypervitaminosis A and carotenemia. *Am. J. Dis. Child.* 67:33-43, 1944.
11. Oliver, T. K., Jr. Chronic vitamin A intoxication: report of case in older child and review of literature. *J. Dis. Child.* 85:57-68, 1958.
12. Motrice, G., Jr., Havener, W. H., and Kuperansky, F. Vitamin A as cause of spontaneous abortion. *J.A.M.A.* 173:1095-1093, 1959.
13. Moore, T. *Vitamin A*, 645 pp. Princeton: Van Nostrand, 1957.
14. Moore, T., and Wang, Y. L. Hypervitaminosis A. *Biochem. J.* 29:222-226, 1945.
15. Cohlan, S. Q. Excessive intake of vitamin A as cause of congenital anomalies in rat. *Science* 117:333, 1953.
16. *Ibid.* Congenital anomalies in rat produced by excessive intake of vitamin A during pregnancy. *Federation* 12:596-567, 1954.
17. Hillman, R. W. Hypervitaminosis A: experimental induction in human subject. *Am. J. Clin. Nutrition* 4:503-508, 1956.
18. Frey, J. R., and Schoch, M. A. Therapeutische Versuche bei Phosking mit Vitamin A, zugleich ein Beitrag zur A-Hypervitaminose. *Dermatologische* 104:80-88, 1952.
19. Knaudson, A. G., Jr., and Rothman, F. E. Hypervitaminosis A: review with discussion of vitamin A. *Am. J. Dis. Child.* 85:516-534, 1952.
20. Logan, J. Thyroid depression following high doses of vitamin A. *New Zealand M. J.* 56:249, 1957.
21. Hume, E. M., and Krebs, H. A. *Vitamin A Requirements of Human Adults: Experimental study of vitamin A deprivation in man.* (Med. Research Council, Spec. Rep. Series No. 264.) 145 pp. London: His Majesty's Stationery Office, 1949.

ADDITIONAL REFERENCES

- Breiau, R. C. Hypervitaminosis A. *Arch. Pediat.* 74:139-152 and 178-197, 1957.
- Jeghers, H., and Marnett, H. Hypervitaminosis A: its broadening spectrum. *Am. J. Clin. Nutrition* 5:335-339, 1959.
- Morton, R. A. *Vitamin A. Lect. Scient. Basis of Med.* (London) 5: 145, 1955-1956.
- Review. Action of Vitamin A. *Nutrition Rev.* 17:22-24, 1959.



Benign Increased Intracranial Hypertension Due to Chronic Vitamin A Overdosage in a 26-Month-Old Child

*The Increased Intracranial Pressure Subsided Promptly with
Steroid Therapy and Cessation of Vitamin A*

Patrick S. Pasquariello, Jr., M.D.,* Luis Schut, M.D.,† Patricia Borns, M.D.‡

THAT BENIGN increased intracranial hypertension may result from vitamin A toxicity is well known among those who take care of children and adolescents.^{1,2}

Vitamin A in its purified form is accessible "over-the-counter" or may be purchased in combination with other vitamins especially vitamin D. The use of large doses of vitamin A in the care of skin conditions, the increasing use of megavitamin therapy in certain psychiatric disorders, and the growing tendency toward food and vitamin faddism, should keep the physician alert to the possibility of encountering toxic symptoms due to an overdose of this vitamin.

Here is the description of a child who was given large doses of vitamin A and of the therapeutic dilemma encountered.

From the Children's Hospital of Philadelphia, Philadelphia, PA.

* Senior Physician.

† Senior Surgeon.

‡ Senior Radiologist.

Correspondence to: Patrick S. Pasquariello, Jr., M.D., The Children's Hospital of Philadelphia, 1 Civic Center Boulevard, Philadelphia, PA 19104.

Case Report

This 26-month-old white girl was admitted to Children's Hospital of Philadelphia for the first time on June 6, 1973 because of increasing irritability, listlessness, and vomiting. Three weeks earlier she had had an upper respiratory infection followed by diarrhea and occasional vomiting. She responded to symptomatic therapy and was well until one week before hospitalization when vomiting recurred, accompanied by listlessness. At this time, she began to scratch her skin vigorously and pull her hair. Her mother had noted no rashes. The listlessness increased, and she became progressively irritable. There was a strong history of pica. Just prior to admission, she had been found eating paint chips from the floor.

She had suffered two head injuries 6 months prior but at neither time did she lose consciousness. On one occasion a skull x-ray was taken and was interpreted as being normal. Scratching had been noted, and the skin was described as being dry in the diaper area and on the shoulders. Psychomotor development was normal.

At admission she was very irritable, crying even when being held by her mother. The head appeared large and measured 50 cm in circumference. The hair was thin and coarse. She had bossing of the frontal bones, and the scalp veins were dilated. Percussion of the head elicited a cry of pain, and bruits were audible over the left parietal and entire frontal region. Both the

coronal and the sagittal sutures were separated and easily palpable. The pupils were equal and reacted normally to light. Funduscopic examination revealed sharp disc margins. Deep tendon reflexes were active in all extremities, and no abnormal reflexes were elicited. The remainder of the neurologic examination was normal. The skin was dry, with a papulo-erythematous rash at the base of the neck posteriorly and over the dorsal surface of both upper extremities.

Skull x-rays showed separation of the cranial sutures. There were no evidences of bone destruction or abnormal calcification. A flat plate of the abdomen did not reveal any radio-opaque particles. The ends of the long bones at the wrists showed increased densities in the regions of the metaphyses, resembling those of chronic lead intoxication. Admission hemoglobin level was 11.8 gm; hematocrit 32 per cent; and the WBC 10,900 with a normal differential.

Dexamethasone was given, 3 mgm intravenously every 6 hours, because of the signs of increased intracranial pressure. The day after admission, an arteriogram revealed displacement of the right superior cerebellar artery upwardly and medially, suggesting the possibility of a space-taking lesion in the posterior fossa.

The use of large doses of vitamin A in the care of skin conditions, the increasing use of megavitamin therapy in certain psychiatric disorders, and the growing tendency toward food and vitamin faddism, should keep the physician alert to the possibility of encountering toxic symptoms due to an overdose of this vitamin.

Also, on the day after admission, we learned from the mother that the child had been given 5,000 IU of vitamin A, 4 times a day in the form of cold liver oil plus one teaspoonful a day of a multi-vitamin syrup that contained 10,000 IU of vitamin A per teaspoon. These 2 vitamin preparations had been given regularly for the previous 6 months. The mother explained that she understood that her child would be healthier if given higher doses of vitamins than prescribed. Additional laboratory studies revealed normal levels of calcium, phosphorus, alkaline phosphatase, aminolevulinic acid dehydrogenase (ALAD) and serum electrolytes. No coproporphyrins in the urine were demonstrable.

Pneumoencephalography performed on the 6th hospital day was normal. Spinal fluid obtained during the procedure had a protein level of 18 mg%, and glucose at 63 mg%. Serum lead level

at the time of admission was reported at 42 mcg%. Serum vitamin A level was reported at being 269.5 mcg% (normal: 13-60 mcg%). No carotene was present in the serum.

Her hospital course was one of steady improvement. On the 2nd day after initiation of steroid therapy, the cranial bruits disappeared. Lethargy and listlessness decreased and her appetite improved.

She was discharged on the 14th hospital day and steroids were tapered over the ensuing weeks.

X-rays of the skull taken one month after discharge showed no signs of increased intracranial pressure and the densities at the ends of the radius and ulna had disappeared. The child was happy and alert. Her head measured 49.5 cm in circumference, and her skin was moist without any rashes. Her hair was thick and full. The excess vitamins were of course no longer being taken.

Discussion

The customary American diets for individuals of all ages contain adequate quantities of vitamin A and carotenoid pigments, but do not provide sufficient excess to produce symptoms of toxicity. The minimum daily requirement (MDR) of vitamin A in infants under 1 year is 1,500 IU; in children 1 to 12 years, 2,000 IU.³

Vitamin A has been accessible over the counter in varied doses, but restrictions⁴ of the Food and Drug Administration (FDA) have limited the strength of vitamin A tablets to 10,000 IU each. The "minimum daily requirements" have been changed recently by the FDA to the U.S. "recommended daily allowance" (RDA) for each of the 19 vitamins and minerals recognized as "essential" by the agency. These recommended allowances are generally higher than the minimum daily requirements they replace, and are "sufficient to meet the nutritional needs of essentially any healthy individual." The accepted RDA for vitamin A since January, 1974 has been 5,000 IU per day. Any vitamin or mineral preparation containing 150 per cent of this RDA will have to be sold as a drug, bearing a label stating that it should be taken for therapeutic purposes only. Because of the toxicity of vitamin A, the FDA is proposing to limit high doses to prescription-only status.

Vitamin A toxicity occurs in two forms. The acute form follows the acute accidental ingestion of massive amounts of any substance

VITAMIN A INTOXICATION

containing large amounts of vitamin A, such as cod liver oil (60,000 u/ml).⁵ Such toxicity was seen in Arctic explorers who ingested vitamin-rich polar bear liver as a savory delicacy. The chronic form develops with prolonged ingestion of substances with a high content of vitamin A, such as the oils cited above or any vitamin A concentrate. This form is often seen with individuals who have continued taking vitamin preparations originally prescribed by physicians for longer periods of time than was prescribed, or when a patient increases the dosage by his own volition, or when overdosing accompanies food and vitamin faddism.

Three main organ systems become affected by vitamin A toxicity: the central nervous system, the integumentary system, and the osseous system. A latent period of weeks or months exists between the onset of ingestion of overdoses and the onset of toxic symptoms. Factors responsible for this latent period may be due to individual variation in absorption or utilization or excretion, though it is known that the liver must become saturated with Vitamin A before toxic symptoms arise. This explains the hepatomegaly seen in most instances of vitamin A intoxication.

Central nervous system involvement leads to symptoms of increased intracranial pressure. In the case presented, cranial bruits were audible, and these disappeared in 2 days after initiation of steroid therapy. The changes were coincidental with improvement of the patient and apparent decrease in intracranial pressure. The history of pica for lead paint chips raised the possibility of lead encephalopathy, but the absence of anemia, the negative urine coproporphyrins, the normal ALAD level and the absence of radioopaque substances in the intestine outweighed the suggestive findings of possible heavy-metal intoxication in the ends of the long bones. Hence, contemplated treatment with BAL and EDTA was postponed until the serum lead level was obtained, and this proved only slightly elevated.

When any child is seen with signs of increased intracranial pressure, investigation should be started immediately. Skull films,

brain scan, arteriography, and pneumoencephalography should be performed as needed. Coincidentally, the past history should be explored in great detail, and tests done for other causes of increased intracranial pressure. When no evidence of a mass is found, conditions producing benign increased intracranial pressure should be investigated. Some of the conditions known to produce this syndrome are hypophosphatasia,⁶ tetracycline therapy,⁷ vitamin A deficiency,⁸ steroid therapy,⁹ head trauma,¹⁰ Addison's disease,¹¹ thrombosis of the dural sinuses,¹² galactosemia,¹³ hypoparathyroidism¹⁴ and bacterial and viral infections.¹⁵ These syndromes may be diagnosed with appropriate history and chemical studies.

Integumentary involvement includes such changes as fissuring of the lips, dryness and pruritis of the skin, desquamation of the palms and soles, seborrheic-like eruptions, and coarseness of the hair with alopecia.⁴ The skin findings in our patient, which were minimal, disappeared soon after cessation of the vitamin A intake.

The most consistent skeletal changes that occur in vitamin A intoxication are those of cortical thickening, especially in the small bones of the hands and feet and the ulnas. The thickening is seen in the cortex of the shaft of the bones, and it usually stops short of the ends of the shaft. The metaphyses and epiphyseal ossification centers are characteristically normal. These changes are manifest, clinically, by tenderness at the site of the involvement, and the consequent weakness that accompanies the tenderness. Cranio-tabes may be elicited in infants secondary to demineralization of the bones of the skull.

Hypercalcemia as a complication is rare in children, but when it is present one must consider the diagnosis of hyperparathyroidism. Frame *et al.*¹⁶ reported such a case and pointed out that the presence of periosteal calcifications are inconsistent with the diagnosis of hyperparathyroidism.

In our patient the roentgen findings in the bones were atypical in that they resembled those seen in heavy metal poisoning. That they had disappeared one month after the ex-

cessive vitamin A intake was stopped indicates their relationship to the vitamin toxicity, since the changes which accompany heavy metal deposits remain demonstrable as transverse lines for years.

Final Comments

Intoxication from vitamin A is a preventable disease, and strict preventive measures are now being taken to restrict its overuse. This is necessary since food faddism is becoming more and more popular, and the needed intake of vitamin A is being multiplied many times. Clausen,¹⁷ who studied the subject thoroughly, has questioned whether healthy children require any vitamin A supplement after they begin to eat vegetables.

The physician must be cognizant that children may be unknowing victims of the idiosyncrasies and whims of their parents and must be protected. It is most important that he be aware of the mores and customs of the families in his practice. Whenever indicated, specific questioning is advisable if one is to uncover specific information regarding eating habits, peculiar appetites, and food supplements.

References

1. Joseph, H. W.: Hypervitaminosis A and carotenemia. *Am. J. Dis. Child.* 67: 33, 1944.
2. Marie, J., and See, G.: Acute hypervitaminosis A of infants; its clinical manifestations with benign acute hydrocephalus and pronounced bulge of fontanel. *Clinical and Biological Study. Am. J. Dis. Child.* 87: 731, 1954.
3. Joint Committee Statement, Committees on Drugs and on Nutrition: The use and abuse of vitamin A. *Pediatrics* 48: 655, 1971.
4. Federal Register, August 1, 1973.
5. Braun, I.: Vitamin A excess, deficiency, requirements, metabolism and misuse. *Pediatr. Clin. North Am.* 9: 935, 1962.
6. Fraser, D.: Hypophosphatasia. *Am. J. Med.* 22: 730, 1957.
7. Fields, J. P.: Bulging fontanel: A complication of tetracycline therapy in infants. *J. Pediatr.* 58: 74, 1961.
8. Bass, M. H., and Caplan, J.: Vitamin A deficiency in infancy. *J. Pediatr.* 47: 690, 1955.
9. Dees, S. C., and McKay, H. W., Jr.: Occurrence of pseudotumor cerebri (benign intracranial hypertension) during treatment of children with asthma by adrenal steroids. *Pediatrics* 23: 1143, 1959.
10. Martin, J. P.: Signs of obstruction of superior longitudinal sinus following closed head injuries (traumatic hydrocephalus). *Brit. Med. J.* 2: 467, 1955.
11. Walsh, B.: Papilledema associated with increased intracranial pressure in Addison's disease. *Arch. Ophthalmol.* 47: 36, 1952.
12. Ray, B. S., and Dunbar, H. S.: Thrombosis of dural venous sinuses as cause of pseudotumor cerebri. *Ann. Surg.* 134: 376, 1951.
13. Huhnelocher, P. P., Hillman, R. E., and Hsia, Y. E.: Pseudotumor cerebri in galactosemia. *J. Pediatr.* 76: 502, 1970.
14. Saphin, A., Albright, and McCune, D. J.: Five cases, three in siblings, of idiopathic hypoparathyroidism associated with moniliasis. *J. Clin. Endocrinol.* 3: 625, 1925.
15. Rose, A., and Matson, D.: Benign intracranial hypertension in children. *Pediatrics* 39: 227, 1967.
16. Frame, B., Jackson, C. E., Reynolds, W. A., and Umphrey, J. E.: Hypercalcemia and skeletal effects in chronic hypervitaminosis A. *Ann. Intern. Med.* 80: 44, 1974.
17. Clausen, S. W.: Unpublished data quoted in editorial: Toxicity of vitamin A. *J. Pediatr.* 37: 942, 1950.

The patient was discharged eight days after entry into the hospital and continued to convalesce at home. He rapidly regained the lost weight. About two months after the onset of his symptoms he was clinically well.

DISCUSSION

The essential differences in this case from the similar case in an adult female previously reported are that our patient did not present pruritus, skin pigmentation, exophthalmos or sexual alterations, but did demonstrate hepatomegaly and a greasy odorous skin. Features presented common to cases previously reported in infants and children included bone and joint pain, skin rash, alteration of the mucous membranes of the lips, asthenia, weight loss, anorexia and hepatomegaly.

Factors other than the mere ingestion of large amounts of vitamin A may be involved in the pathogenesis of this condition. Josephs,¹ for example, cited the observation of an eight month old infant who received 500,000 units of vitamin A daily over a period of four months, with no symptoms of toxicity and with a normal blood vitamin A level. All authors have reported complete recovery from this syndrome following withdrawal of vitamin A. Several have repeated experimentally the clinical syndrome after the symptoms had subsided by re-administering high doses of vitamin A.

Rodahl⁴ in excellent monographs has reviewed the subject of the toxic effect of polar bear liver and hypervitaminosis A, and has contributed interesting observations on experimental animals. He states that it has been known for centuries among Eskimos and Arctic travelers that the ingestion of polar bear liver by men or dogs causes severe illness. Acute symptoms of severe headache, dizziness, irritability, vomiting and diarrhea occur following the ingestion of polar bear liver. After about a week or more, peeling of the skin and some loss of hair may occur. Rodahl demonstrated by feeding experiments with rats that the large amounts of vitamin A in polar bear liver were responsible for these toxic symptoms.

CONCLUSION

A case of hypervitaminosis A in an adult male is reported. The patient presented anorexia, weight loss, asthenia, skin rash, loss of hair, polydipsia, polyuria, soreness and fissuring of the lips, bone and joint pain, hepatomegaly and tachycardia. He made a prompt recovery following cessation of vitamin A ingestion. The similarities and differences between this case and the others reported are discussed.

BIBLIOGRAPHY

1. Josephs, H. W.: Hypervitaminosis A and carotinemia, *Am. J. Dis. Child.* 67: 33 (Jan.) 1944.
2. (a) Toomey, J. A., and Morissette, R. A.: Hypervitaminosis A, *Am. J. Dis. Child.* 73: 473 (April) 1947.
- (b) Rothman, P. E., and Leon, E. E.: Hypervitaminosis A, *Radiology* 51: 368, 1948.
- (c) Dickey, L. B., and Bradley, E. J.: Hypervitaminosis A: case report, *Stanford M. Bull.* 6: 345, 1948.
- (d) Fried, C. T., and Grand, M. J. H.: Hypervitaminosis A, *Am. J. Dis. Child.* 79: 475 (March) 1950.
- (e) Caffey, J.: Chronic poisoning due to excess of vitamin A, *Pediatrics* 5: 672, 1950.

- (f) Bair, G.: Chronic vitamin A poisoning: report of a case, *J. A. M. A.* 146: 1573 (Aug. 25) 1951.
- (g) Gribetz, D., Silverman, S. H., and Sobel, A. E.: Vitamin A poisoning, *Pediatrics* 7: 305 (March) 1951.
- (h) Rineberg, I. E., and Gross, R. J.: Hypervitaminosis A with infantile cortical hyperostosis, *J. A. M. A.* 146: 1222 (July 28) 1951.
- (i) Wyatt, T. C., Carabello, C. A., and Fletcher, M. E.: Hypervitaminosis A, report of a case, *J. A. M. A.* 144: 304 (Sept. 23) 1950.
- (j) Mouriguard, A. G.: Overdosage with vitamin A, *Presse méd.* 56: 737 (Oct. 24) 1948.
- (k) Caffey, J.: Chronic poisoning due to excess of vitamin A, *Am. J. Roentgenol.* 65: 12 (Feb.) 1951.
- (l) Naz, J. F., and Edwards, W. M.: Hypervitaminosis A, *New England J. Med.* 246: 87 (Jan. 17) 1952.
- 3. Sulzberger, M. B., and Lazar, M. P.: Hypervitaminosis A. Report of a case in an adult, *J. A. M. A.* 146: 788 (June 30) 1951.
- 4. Rodahl, K.: The toxic effect of polar bear liver, *Skrifter Nr. 92, Norsk Polarinstitut* and *Ibid.*, Hypervitaminosis A, a study of the effect of excess of vitamin A in experimental animals, *Skrifter Nr. 93, Norsk Polarinstitut*.

ACUTE *LEPTOSPIRA POMONA* ARTHRITIS AND MYOCARDITIS *

By W. D. SUTLIFF, M.D., ROBERTA SHEPARD, M.D., and
WOLCOTT B. DUNHAM, M.D., *Memphis, Tennessee*

A case is reported below of acute arthritis and myocarditis associated with specific serologic reactions of leptospirosis due to *Leptospira pomona*, which resembled rheumatic fever sufficiently closely to require specific diagnostic methods for differentiation. The case presented symptomatology not heretofore described in leptospirosis, and increased the number of clinical pictures that suggest the possibility of leptospiral etiology.

The leptospiroses are a group of illnesses caused by spirochetes of a number of immunologically distinct strains. *Leptospira icterohaemorrhagiae*, the cause of Weil's disease, and *Leptospira canicola*, the cause of canicola fever, were comparatively well known in the United States before 1951. Evidence of human infection with *Leptospira pomona* was first recognized in the United States in 1951.¹ Reports of other cases of *L. pomona* infection soon followed,² as well as reports of cases of infection with other strains, namely, *Leptospira autumnalis*,³ and *Leptospira grippityphosa*.⁴ Fourteen different specific leptospirae were recognized by Gsell⁵ as a result of studies of the strains of leptospirae and reports of cases and epidemics of illness from all parts of the world. The infections caused two main groups of clinical manifestations. The first group comprised infections that were sometimes severe and often associated with jaundice. They

* Received for publication January 5, 1953.

From the Infectious Disease Section of the Medical Service and the General Research Laboratory, Veterans Administration, Medical Teaching Group Hospital, Memphis, Tennessee.

13. Goodman, M. J.: Periarthritis with recovery: report of unusual case apparently due to sensitivity to sulfonamide, *Ann. Int. Med.* 28: 181, 1948.
14. Clark, E., and Kaplan, B. I.: Endocardial, arterial and other mesenchymal alterations associated with serum sickness, *Arch. Path.* 24: 458 (Oct.) 1937.
15. Wadsworth, G. H., and Brown, C. H.: Serum reaction complicated by acute carditis, *J. Pediat.* 17: 801 (Dec.) 1940.
16. Fox, T. T., and Messeloff, Cr. R.: Electrocardiographic changes in a case of serum sickness due to tetanus antitoxin, *New York State J. Med.* 42: 152, 1942.
17. McKinley, C. A.: Allergic carditis, pericarditis and pleurisy; report of case of serum sickness with predominant cardiac manifestation and symptomatic recovery, *Journal Lancet* 68: 61 (Feb.) 1948.

HYPERVITAMINOSIS A: REPORT OF A CASE IN AN ADULT MALE *

By ERNEST W. SHAW, Captain, USAF (MC), *Travis Air Force Base, California*,
and JUAN Z. NICCOLI, M.D., *San Diego, California*

THE syndrome of hypervitaminosis A has been described in at least 17 infants and young children since Josephs' original article in 1944.^{1,2} Sulzberger and Lazar³ described similar toxic symptoms which occurred in an adult female who took large amounts of vitamin A in an attempt to prevent colds. Rodahl⁴ has described the toxic symptoms of hypervitaminosis A resulting from polar bear liver ingestion.

The present report is of an adult male with this syndrome and demonstrates several interesting features.

CASE REPORT

Present Illness: A 25 year old Mexican drug store clerk was first seen by us on March 3, 1952. He complained of marked asthenia, a 10 pound weight loss, anorexia, polydipsia, polyuria, a skin rash, excessive loss of the hair of the entire body, soreness and fissuring of the lips, and pain in the area of the shoulder joints, ribs, tibia and ankles. All of his symptoms were of about two weeks' duration. He and his family believed that he was very seriously ill.

Questioning revealed that for about two months the patient had been taking three to four vitamin A capsules daily (50,000 U.S.P. or international units per capsule), and two to three multivitamin capsules daily, each of which contained 25,000 units of vitamin A. He had also taken three ampuls of vitamin C and four or five 1 mm. injections of liver during that period. The patient would often omit a meal and take vitamin capsules in lieu of eating. Shortly after the onset of the above symptoms the patient was seen by a physician in Tijuana, Mexico, who prescribed three injections of cortisone, three ampuls of 2 ml. each of vitamin B complex, and three injections of a sodium salicylate-colchicine, sodium iodide preparation. The patient discontinued vitamin A and all other medications about one week before entering the hospital.

Past History: The patient had been in good health and had had no previous serious illness. He had never had any known liver disorder. Family history was noncontributory.

* Received for publication January 30, 1953.
Permanent address of senior author: 1870 4th Ave., San Diego, Calif.

Physical Examination: The patient was a well developed, alert, coöperative white male looking his stated age of 25. He appeared acutely ill. The significant findings were the following:

1. A patchy alopecia. The hair of the scalp or any part of the body could be pulled out with ease. The patient's pillow-slip and bed linen were always littered with his hair. There were oval areas of alopecia on the legs.
2. A maculopapular rash on the chest, oiliness of the skin on all areas of the body, desquamation of the skin over both heels, and a strong odor emanating from the skin.
3. Slight faucial injection and marked desquamation of the buccal mucous membrane.
4. A sinus tachycardia (rate 100 to 110), though the blood pressure, heart size and sounds were normal.
5. Liver enlarged by palpation three fingerbreadths below the right costal margin, nontender.
6. Marked tenderness over many bones, particularly the left clavicle, the lower ribs and both tibiae.

Laboratory Studies: *March 3, 1952:* Complete blood count, normal. Fasting blood glucose, 110 mg. per cent. *March 5, 1952:* Red blood count, 3.97 million. Hemoglobin, 12 gm., 84 per cent. White blood count and differential, normal. Total proteins, 7.0 gm. Serum albumin, 3.81 gm. Serum globulin, 3.19 gm. Cholesterol (total), 162. Alkaline phosphatase, 7.0 units. Bromsulfalein, 1.5 per cent retention in 45 minutes. Icterus index, 16. Cephalin flocculation, 1 plus in 48 hours. Bilirubin, 1.6 mg. per cent. Calcium, 13.6 mg. per cent (normal, 9 to 11.5). Phosphorus, 3.1 mg. per cent. Kline and Kahn, negative. *March 10, 1952:* Blood prothrombin time, 14 seconds (control, 17 seconds); concentration, 156 per cent. Blood carotenoids, 23 micrograms per cent (normal, 100 to 225). Blood vitamin A alcohol, 183 micrograms per cent (normal, 20 to 60). *March 18, 1952:* Blood carotenoids, 82 micrograms per cent. Blood vitamin A alcohol, 237 micrograms per cent. Serum calcium, 12.7. *March 28, 1952:* Blood carotenoids, 69 micrograms per cent. Vitamin A alcohol, 153 micrograms per cent. Urine: *March 3, 1952:* Routine urinalysis, normal. *March 5, 1952:* Bence-Jones protein determination, negative. *March 8, 1952:* Sulkowitch test, "milky reaction" (strongly positive). *March 10, 1952:* Sulkowitch test, normal. *March 18, 1952:* Sulkowitch test, normal.

X-Rays (*March 3, 1952*): X-rays of the chest, abdomen and skull were completely normal. There was no evidence of osteoporosis or cortical hyperostosis. Electrocardiogram (*March 3, 1952*): Normal except for slight tachycardia (rate, 104).

Course: The patient received no therapy other than withdrawal of vitamin A and modified bed-rest. He was advised to restrict the intake of butter and cream. The symptomatic improvement was rapid. Two days after he entered the hospital the bone and joint pain disappeared, the appetite returned to normal, and the asthenia was replaced by a sense of well being. The skin rash and the desquamation of the buccal mucous membranes cleared rapidly. The hair continued to fall out and to be coarse and brittle for about three weeks, then it began to grow back and to lose its brittleness. Much of the hair of the eyebrows and eyelashes fell out about two weeks after he entered the hospital.

The liver enlargement decreased gradually. Two weeks after his entry into the hospital the liver was palpable two fingerbreadths below the right costal margin; three weeks after entry it was one fingerbreadth below the right costal margin.

The pulse rate returned to normal about three days after his admission to the hospital.



ILL record updated to IN PROCESS
Record 16 of 20

alpha

ILL pe Record 15 of 20
 CAN YOU SUPPLY ? YES NO COND FUTUREDATE
 :ILL: 4976905 :Borrower: IDL :ReqDate: 20010117 :NeedBefore: 20010216
 :Status: IN PROCESS 20010117 :RecDate: :RenewalReq:
 :OCLC: 1587974 :Source: OCLCILL :DueDate: :NewDueDate:
 :Lender: *IAB, IAV, JFG, JFU, INM
 :CALLNO:
 :TITLE: The New England journal of medicine.
 :IMPRINT: Boston, Massachusetts Medical Society.
 :ARTICLE: Vitamin A intoxication in adults: Report of a case.
 :VOL: 265 :NO: :DATE: 1961 :PAGES: 369-373
 :VERIFIED: OCLC ISSN: 0028-4793
 :PATRON: O'Donnell, J

:SHIP TO: ILL
 Rush University Library
 600 S. Paulina
 Chicago, IL 60612

Recip

:BILL TO: Same
 :SHIP VIA: Library Rate :MAXCOST: 30.00 :COPYRT COMPLIANCE: CCG
 :BORROWING NOTES: DO NOT SEND ILDS - WE ARE NOT ON ILDS ROUTE
 :LENDING CHARGES: :SHIPPED: :SHIP INSURANCE:
 :LENDING RESTRICTIONS:
 :LENDING NOTES:
 :RETURN TO:
 :RETURN VIA:

NOTICE: THIS MATERIAL MAY BE PROTECTED
BY COPYRIGHT LAW (TITLE 17 U.S. CODE)

THE RELATION OF VITAMIN A INTAKE TO CEREBROSPINAL
FLUID PRESSURE: A REVIEW

MURRAY H. BASS, M.D.

New York, N. Y.

In this brief review I wish to call attention to the peculiar relationship between the intake of vitamin A and the cerebrospinal fluid pressure. Clinically this relationship is of particular interest to pediatricians as the condition of the fontanelle in the infant is so simple a guide in estimating intracranial fluid pressure, whereas in older individuals this pathological condition may be entirely overlooked. What makes a study of this relationship very fascinating is that increased pressure of the cerebrospinal fluid may appear both as a result of the intake of excessive amounts of vitamin A and also as a symptom of vitamin A deficiency.

INCREASED CEREBROSPINAL FLUID PRESSURE IN VITAMIN A DEFICIENCY

Vitamin A deficiency is not a commonly encountered condition in this country where the average diet includes milk which contains enough of the vitamin, rendering supplementation unnecessary. However, with the increasing frequency of the diagnosis "milk allergy," many infants are kept on vitamin A free diets, and if vitamin addition is neglected, the symptoms of avitaminosis A may appear. These symptoms result in a bizarre clinical syndrome including the following signs:

- Retardation of mental and physical growth.
- Anemia with or without splenomegaly.
- Tendency to infection (skin and respiratory tract).
- Epithelial metaplasia
 - In the eye: xerophthalmia and keratomalacia.
 - In the urinary tract: hematuria.
 - In the vagina: cornified epithelium.
 - In the digestive and respiratory tracts.
- Endocrine disturbance: gynecomastia.
- Increased cerebrospinal pressure with markedly bulging fontanelle.
- Cranial nerve injury: facial paralysis.

As long ago as 1933 Blackfan and Wolbach (1) in a clinical and pathologic study of vitamin A deficiency described a 6½ month infant, allergic to cow's milk, on a diet containing no vitamin A, who showed marked apathy and keratomalacia. "The neck was retracted and the sutures of the skull showed some separation." With vitamin A therapy, the infant recovered but remained blind. This is the first description of a human infant showing evidence of increased cerebrospinal fluid pressure due to vitamin A deficiency.

Cornfeld and Cooke (2) in 1952 and Bass and Caplan (3) in 1955 published cases of vitamin A deficiency including symptoms of markedly increased cere-

From the Department of Pediatrics, The Mount Sinai Hospital, New York, N. Y.

brospinal fluid pressure. The following is a brief summary of Bass and Caplan's case:

A previously healthy infant at the age of a month developed severe generalized eczema for which he was put on a soy bean preparation, receiving in addition vitamin D (Drisdol) and vitamin C. He developed slowly so that at five months he weighed only 11 $\frac{3}{4}$ pounds. At seven months in the course of a mild upper respiratory infection with slight fever, he developed hematuria, for which he was hospitalized. Examination revealed severe anemia (hemoglobin 6.7 gms.), numerous minute corneal ulcerations, lethargy and complete anorexia. On the eleventh day extreme bulging of the fontanelle was noted with nuchal rigidity and rise in temperature to 104.2 degrees. Lumbar tap revealed normal fluid which rapidly reaccumulated. Skull X-ray, subdural and intraventricular taps proved negative.

The combination of anemia, corneal ulcers, hematuria and acute hydrocephalus led to the diagnosis of vitamin A deficiency. It was learned that the child had had no other food but Mull Soy, banana, peaches and rice. Vitamin A in large doses was given by intramuscular injection with dramatic results. The symptoms rapidly disappeared and the child made an uneventful recovery and has remained well.

The publication of this case led to the discovery a few months later of a similar one in New Jersey in a colored infant, also on a soy bean milk without added vitamin A. Beside malnutrition and xerophthalmia there was present a markedly bulging fontanelle with radiographic evidence of wide separation of the cranial sutures such as one sees in hydrocephalus. The blood level of vitamin A was zero. As in the above mentioned case, the administration of vitamin A resulted in rapid recovery.

Bass and Caplan (4) also described the sudden appearance of a markedly bulging fontanelle in a deeply icteric infant with avitaminosis A due to proven congenital absence of the bile ducts. When vitamin A was given by intramuscular injection, the distention of the fontanelle disappeared.

It has long been known that in experimental animals a diet deficient in vitamin A may give rise to definite changes in the nervous system including increased cerebrospinal pressure and hydrocephalus. These changes were blamed on faulty bone formation with resultant pressure on nerve trunks or on the brain itself. Thus Wolbach and Bessie (5) reporting on experiments on young mammals in 1941 say "The nervous lesions of vitamin A deficiency are wholly of mechanical origin, the genesis of which is a disproportionate growth of the central nervous system in relation to the bone which surround it." Again in 1955 Wolbach & Hagsted (6) investigating the same subject in young chicks conclude that "The neurologic disturbances of vitamin A deficiency in the chick are the result wholly of compression of the central nervous system produced by retardation of growth of vertebrae and bones of the cranium."

Sir Edward Mellanby (7) whose researches on this subject began as long ago as 1926, reviewed his findings in 1950. He was not quite as dogmatic about the neurologic disturbances, concluding that most of the degeneration could be ascribed to the fact that "a function of the vitamin A moiety was to control the activity of osteoblasts and osteoclasts, so that in its absence from the body, the bones were thickened and altered in shape, and that the incoordination was in fact, due largely, if not entirely, to the pressure on the nervous system of this thickened bone."

However, some investigators dealing with animals, long ago suspected that defects in bone growth might not be the sole cause of neurological disturbance. Moore (8) and his collaborators working with calves, wrote in 1935 "It seems doubtful that vitamin A could be concerned with such bone malformations as in the cases reported in this paper, but such an explanation might be plausible if the absence of vitamin A in some indirect way, raised the intracranial pressure." Again in 1939 he states "Vitamin A may possibly function to regulate intracranial pressure," and in 1940 (10) he concludes from further studies "A deficiency of vitamin A in the ration of the young bovine produces an increased cerebrospinal fluid pressure."

Recently considerable light has been thrown on this subject by the carefully controlled work of Millen (11) and his collaborators in England. Their papers deal directly with hydrocephalus due to experimental hypovitaminosis A. They have produced hydrocephalus in a very large percentage of the offspring of female rabbits kept for a long period on vitamin A free diet. The longer the animal was kept on this diet, the greater was the number of offspring with hydrocephalus. Their work shows that in the rabbit the increased intracranial pressure is definitely not dependent on abnormal bone formation. They say "The hypothesis that the primary factor in the pathogenesis of the condition is an overproduction of cerebrospinal fluid (Millen and others, 1954) receives additional corroboration from the result of the present experiments." They quote experiments by others in which increased pressure in vitamin A deficient animals rapidly falls after the restoration of the vitamin. "Indeed so sensitive to vitamin A deficiency is the cerebrospinal pressure that Sorensen (12) and others (1954) suggest it may be used as a guide to the onset of deficiency."

The same conclusion is reached by Rokkones (13) who in 1955 published studies on the offspring of vitamin A deficient rats. He concludes that "A rise in the cerebrospinal pressure appears to be the most characteristic and sensible symptom of the disease. It is demonstrable already before the occurrence of hydrocephalus and before the animals show visible symptoms."

The results of these recent animal experiments account very well for the findings in the vitamin deficient infants, for it would be impossible to explain the rapid disappearance of symptoms and signs of increased cerebrospinal fluid pressure when vitamin A was given, if they were due entirely to defective bone formation.

INCREASED INTRACRANIAL PRESSURE AND ACUTE HYPERVITAMINOSIS A

In 1951 Julien Marie and Georges See (14) published a report of three infants who, after the ingestion of a single huge dose of vitamins A and D, responded after twelve hours with extreme bulging of the fontanelle, lasting twelve to twenty-four hours. The vitamins were in the form of a preparation known as Vitadone forte which contained 350,000 units of vitamin A and 300,000 units of vitamin D. The infants twelve to twenty-four hours after ingestion usually vomited and showed restlessness, discomfort, insomnia or drowsiness. Believing that these symptoms were due to the vitamin A and not to vitamin D, authors gave a number of infants large doses of vitamin A alone (350,000 units) and were

able to reproduce this transitory bulging fontanelle in three of six infants. Spinal tap in these cases showed an increase in fluid pressure. The cytology and chemistry of the fluid was normal. Blood pressure remained normal. Vitamin A content of the blood rose to many times the normal but then fell rapidly as the symptoms disappeared. No vitamin A was demonstrable in the spinal fluid. They were unable to produce the syndrome when synthetic vitamin A was used instead of the natural vitamin, nor could they reproduce it with the subcutaneous injection of 60,000–90,000 units of natural vitamin A. The authors were able to reproduce the bulging fontanelle in some of the young puppies used as experimental animals.

Their conclusion reads (15) "Our clinical observations and our work on infants and animals convinces us that the acute hydrocephalus, with intensive bulge of the fontanelle, produced by the rapid absorption of vitamin A is a transitory and harmless disorder in both its immediate and its remote prognosis."

In the past five years this syndrome in infants has been reported by numerous authors from different countries. In one case it resulted from a preparation of vitamin A used as nose drops.

In this connection it is of interest to note that, especially in the Arctic regions, acute vitamin A poisoning in adults is not unknown. It occurs from ingestion of seal or polar bear liver which contains enormous quantities of the vitamin. One of the chief complaints in this illness is particularly violent headache accompanied by dizziness and somnolence. As pointed out by Knudsen and Rothman, (16) these symptoms may very well be due to increased intracranial pressure.

In contradistinction to acute poisoning from single large doses of vitamin A, there are now many reports of chronic hypervitaminosis A due to the prolonged use of excessive amounts of the vitamin. Such cases usually reveal symptoms due to lesions in the osseous system and only very rarely present neurological manifestations. However, two cases have been reported where infants with chronic poisoning showed signs of increased intracranial pressure (Gribetz (17) and Arena (18)).

A curious case was reported by Ehrengut (19) in 1955:

A five month old infant who had been on a soy bean milk without vitamin supplement since the age of three weeks developed keratomalacia, pustular skin lesions and gynecomastia. Avitaminosis A was diagnosed and 187,000 units of vitamin A was given in two days. This was followed by the appearance of very marked bulging of the fontanelle. Spinal fluid was found to be normal but under very high pressure. Vitamin A was stopped and the fontanelle returned to normal. Several days later 44,000 units of vitamin A was given by mouth with return of the bulging fontanelle. When the vitamin was discontinued the fontanelle again returned to normal in two days. The author considers the case one of acute hypervitaminosis A (Marie-See Syndrome) resulting from excessive intake of vitamin in attempting to cure symptoms due to prolonged vitamin A deficiency.

Just as we have seen hydrocephalus produced experimentally in litters of animals kept on a vitamin A deficient diet, so, curiously enough, hydrocephalus has also been produced in the offspring of rats fed *excessive* amounts of the same

vitamin (Cohlan-20). In other words hydrocephalus may result in experimental animals and in human infants both in *hypo* and *hypervitaminosis A*.

Apparently this paradox may also be found in symptoms referable to the eyes of pigeons. Under the title "Avitaminose et hypervitaminose A du pigeon. Identité de leur séméiologie oculaire," Mouriquand (21) and his collaborators point out that the pigeon needs very little vitamin A in contradistinction to the rat, which very early shows signs of deprivation. In pigeons even as long as 300 or 400 days of deprivation, symptoms disappear very quickly when small doses are given. Both the loss of periocular feathers, resulting in the so-called "spectacle" appearance and changes in the eye itself occur in both *hypo* and *hypervitaminosis A*.

DISCUSSION

From the foregoing I believe we can definitely state that increased cerebrospinal pressure may occur both in overdosage as well as deficiency of vitamin A in infants and young animals. There is apparently in both conditions a defect in the production or absorption of cerebrospinal fluid. There are more published reports of human infants with bulging fontanelles due to acute hypervitaminosis A than to vitamin A deficiency. Most, though not all have been on some form of soy bean preparation. Mellanby (21) in 1931 postulated from work on puppies that vitamin A might be important in preventing damage to the nervous system by toxins derived from cereal grains fed to the animals. One can only speculate as to whether such a relationship might exist in some of the human infants deprived of vitamin A and fed on preparations made from soy bean.

That the ingestion of certain chemical substances may result in increased cerebrospinal pressure is emphasized by the recent observation of Gellis that "A bulging fontanelle may accompany antibiotic therapy. In these instances the bulging fontanelle was apparently directly related to antibiotic therapy and not to infection present; subsequently when the same children were tested with the same antibiotics at times when they were free of infection, the fontanelle could again be made to bulge during course of therapy and would promptly subside within twenty-four hours after antibiotics were discontinued. This has been seen most frequently with aureomycin." (23)

It is also strange that in reports in vitamin A deficient children in China, where this condition is common, no mention is made of hydrocephalus as one of its symptoms. Thus Sweet and K'Ang (24), in 1935 published a clinical and anatomical study of avitaminosis A in 203 Chinese infants, with seventeen autopsies and twenty-two biopsies. No mention is made of the finding of hydrocephalus either clinically or at post-mortem. However, the authors do mention headache as a late symptom in cases with severe ocular lesions. The headache was "Sharp, piercing and difficult to control." There were also convulsions in four cases but no lesions were found in any of the cases to explain them.

It remains hard to explain why we see hydrocephalus in vitamin A deficiency in America and not in China where dietary deficiency is so widespread. The possibility of a second factor must be kept in mind.

Bicknell and Prescott (25) in their book on "The Vitamins in Medicine" make this relevant comment. "In man no neurological symptoms are generally associated with those conditions, such as keratomalacia, where they would be expected if the central nervous system were affected by vitamin A. There is however, the possibility that in man, as in animals, the degeneration gives such tardy symptoms that they seldom occur before the deficiency has been remedied or death occurs, unless degeneration is accompanied by a second deficiency."

To sum up we can only say that up to the present time we have no adequate explanation for our clinical findings in infants. Symptoms referable to the nervous system in vitamin A deficiency are more common than has been previously believed and the pediatrician should keep this condition in mind when signs of unexplained acute hydrocephalus are encountered.

The problem of the cause of hydrocephalus in hypo and hypervitaminosis A is a challenging one and its solution awaits further clinical and laboratory investigation.

ACKNOWLEDGMENT

We are indebted to Dr. David Adlersberg of The Mount Sinai Hospital in New York City, for the vitamin A determination.

REFERENCES

1. BLACKFAN, K. D., AND WOLBACH, S. B.: Vitamin A Deficiency in Infants: Clinical and Pathological Study. *J. Pediatr.* 3: 679, 1933.
2. CORNFELD, DAVID, AND COOKE, ROBERT E.: Vitamin A Deficiency: Case report: Unusual Manifestations in a 5½ month old Baby. *Pediatrics.* 10: 33, 1952.
3. BASS, M. H., AND CAPLAN, J.: Vitamin A Deficiency in Infancy. *J. Pediat.* 47: 690, 1955.
4. *Loc. cit.*
5. WOLBACH, S. B., AND BESSIE, O. A.: Vitamin A deficiency and the Nervous System. *Arch. Path.* 32: 659, 1941.
6. WOLBACH, S. B., AND HAGSTED, D. MARK: Vitamin A Deficiency in the Chick. *Arch. Path.* 54: 13, 1952.
7. MELLANBY, SIR EDWARD: A story of nutritional research: The Effect of some Dietary Factors on Bones and the Nervous System. Baltimore, 1950, Williams and Wilkens Co.
8. MOORE, L. A., HUFFMAN, C. F. AND DUNCAN, C. W.: *J. Nutrition.* 9: 533, 1935.
9. MOORE, L. A.: *J. Nutrition.* 17: 443, 1939.
10. MOORE, L. A., AND SYKES, J. F.: Cerebrospinal Fluid Pressure and Vitamin A Deficiency. *Amer. J. Physiol.* 130: 684, 1940.
11. MILLEN, J. W., WOOLAM, D. H. M. AND LAMMING, G. E.: Hydrocephalus associated with Deficiency of Vitamin A: *Lancet.* II: 1234, 1953. and II: 679, 1954.
12. SORENSEN, D. K., KOWALCZYK, T. AND HENTGES, J. F.: *Amer. J. Veteran Res.* 15: 258, 1954.
13. ROKKONES, T.: Experimental Hydrocephalus in young Rats: *Internationale Zeitschr. fur Vitaminforschung.* XXVI: 1, 1955.
14. MARIE, J., AND SEE, G.: Hydrocephalie aigue benigne du nourrisson après digestion d'une dose massive et unique de vitamines A et D.: *Arch. Français Pediat.* 8: 563, 1951.
15. MARIE, J., AND SEE, G.: Acute Vitaminosis A of the Infant., *Amer. J. Dis. Child.* 87: 731, 1954.

16. KNUDSEN, A. G., AND ROTHMAN, P. E.: Hypervitaminosis A. *Amer. J. Dis. Child.* 85: 316, 1953.
17. GRIBETZ, D., SILVERMAN, S. H. AND SOBEL, A. E.: Vitamin A Poisoning, *Pediatrics.* 7: 372, 1951.
18. ARENA, J. M., SARAZEN, P. AND BAYLIN, G. J.: Hypervitaminosis A.: Report of an Unusual Case with Marked Craniotabes, *Pediatrics.* 8: 788, 1951.
19. EHRENGUT, W.: Akuter benigner Hydrocephalus durch Hypervitaminosis A (Syndrome Marie-See) bei Keratomalacie, *Zeitschr. fur Kinderheil.* 77: 468, 1955.
20. COHLAN, S. Q.: Congenital Anomalies in the Rat Produced by Excessive Intake of Vitamin A during Pregnancy. *Pediatrics.* 13: 556, 1954.
21. MOURIQUAND, G., ROLLET, J., EDEL, V. AND CHIGHIOZOLA, R.: Avitaminose et Hypervitaminose A du pigeon. Identite de leur semeiologie oculaire: *Comptes Rend. des Seances Acad. Sc.* 241: 348, 1955.
22. MELLANBY, SIR EDWARD: The Experimental Production and Prevention of Degeneration in the Spinal Cord, *Brain*, 54: 247, 1931.
23. GELLIS, S.: Personal communication.
24. SWEET, L. K., AND K'ANG, H. J.: Clinical and Anatomic Study of Avitaminosis A among the Chinese, *Amer. J. Dis. Child.* 50: 699, 1935.
25. BICKNELL, F., AND PRESCOTT, F.: *The Vitamins in Medicine.* 3rd. edition, London, W. Heineman, 1953, p. 75.

SEVERE NAIL DYSTROPHY ASSOCIATED WITH RETINOID THERAPY

Sir.—Vitamin A and synthetic retinoids regulate the proliferation and differentiation of squamous epithelium. This group of drugs has lately been used to treat disorders of keratinisation, including psoriasis, Darier's disease and the ichthyoses.¹ They have also been used for severe cases of acne vulgaris, lichen planus, and certain cutaneous tumours. The synthetic retinoids have a greater therapeutic index, thus reducing the hepatotoxicity associated with high doses of vitamin A. Common side-effects reported with synthetic retinoid therapy are cheilitis, exfoliation of the feet and hands, hair loss, paronychia, and pruritus.² Other disturbances of ectodermal tissues have not been recognised.

In a clinical trial extending over 12 weeks (to be published) of tretinoin in ten patients with severe erosive lichen planus of the oral mucosa, the frequency of the above side-effects was comparable with that in previous studies. Two female patients without cutaneous or lingual manifestations of lichen planus also acquired nail dystrophy (Beau's lines). In both cases a daily dosage of 75 mg tretinoin was prescribed but this had to be reduced intermittently because of the severity of side-effects. The nail dystrophy became apparent 6 weeks after the start of treatment and consisted of a horizontal depression with splitting of the nail plate. Additional horizontal lines became evident 2 months after the trial was completed and corresponded to phases of maximum dosage.

The actions of retinoids are focused principally upon tissues of ectodermal origin, and a disturbance of nail growth might be anticipated during therapy. This side-effect may have been overlooked previously in the management of dermatological disorders because nail involvement commonly occurs as an integral part of many of these. The nails of our two patients reverted to normal after the end of tretinoin treatment and have remained so for a further 6 months.

It is perhaps surprising that no dental changes have been noted in children receiving long-term retinoid therapy because the ameloblasts, being of ectodermal origin, are susceptible to changes in vitamin A levels in laboratory animals.^{3,4}

Department of Oral Medicine and Pathology,
Glasgow Dental Hospital and School,
Glasgow G2 3JZ,
and Department of Dermatology,
Glasgow Royal Infirmary

M. M. FERGUSON
N. R. SIMPSON
N. HAMMERSLEY

INTRACRANIAL HYPERTENSION WITH ETRETINATE

Sir.—Central nervous system toxicity associated with vitamin A is well known, but synthetic retinoids seem to be rarely responsible of such side-effects.⁵ We report here a case of benign intracranial hypertension due to etretinate.

A 35-year-old woman admitted with a 4 year history of typical Darier's disease. She had keratotic papules on her trunk and neck, associated with wart-like lesions on the back of her hands and ungual changes. There were no other signs or symptoms. Histological examination of a keratotic papule confirmed the clinical diagnosis. Blood cell counts and serum creatinine, transaminase, and triglyceride levels were normal.

A daily dose of 1 mg/kg of etretinate was reduced to 0.7 mg/kg after 4 weeks because of an excellent therapeutic response. At that time she complained of slight headaches, which were controlled by flacetalenine. After 2 months of treatment no more papules were

observed but severe pruritus, cheilitis, dryness of the nasal mucosa, and palmoplantar desquamation led to reduction of etretinate daily dose to 0.5 mg/kg. 1 month later the patient reduced the daily dose to 0.3 mg/kg because cheilitis and palmoplantar desquamation persisted. 10 days later the drug was stopped because of rapid aggravation of occipital headache, vomiting, and giddiness, followed by two episodes of loss of consciousness. Neurological examination was normal. There was no papilloedema. An electroencephalogram and isotopic encephalography were normal 15 days after drug withdrawal. Headaches disappeared 2 months later.

3 months later nasal vitamin A, prescribed by another physician, induced rapid recurrence of headaches, and treatment was stopped. The Darier's disease remained uncontrolled.

This observation is characteristic of acute hypervitaminosis A due to etretinate. Headaches were the first symptom and therefore must be considered as a warning of possible drug neurotoxicity. Neurological abnormalities, rarely described in association with Darier's disease, might have been predisposing factor, but 1 year after this experience, a computerised tomographic scan did not show major abnormalities. Moreover, the rapid reappearance of headaches with nasal vitamin A can be considered as secondary to the slow elimination of etretinate by the liver.

Departments of Dermatology
and Neurology,
CHU Dupuytren,
67031 Lons-le-Saunier, France

J. M. BONNETRANC
J. HUDON
M. IRIMAN

Pharmacology Unit,
Roche Laboratories, Neuilly sur Seine

D. RUFIN

NON-A, NON-B HEPATITIS FROM INTRAVENOUS IMMUNOGLOBULIN

Sir.—A 1982 review⁶ of hepatitis after infusion of plasma derivatives drew attention to the high risk of transmission of hepatitis B and, more recently, non-A, non-B hepatitis by concentrates of factor VIII (antihaemophilic globulin) and factor IX. In contrast, human normal immunoglobulin (HNIG) is not usually regarded as a vehicle for viral hepatitis infection. This is commonly attributed to loss or inactivation of virus during fractionation and to neutralising antibody in the immunoglobulin. The safety record of intramuscular HNIG in this respect is impressive and has been reinforced by the sensitive screening methods to detect HBsAg in the plasma used to prepare the fraction. However, routine screening is not available for non-A, non-B hepatitis.

In a clinical trial of an intravenous HNIG developed in this laboratory for the maintenance therapy of hypogammaglobulinaemia all twelve patients developed hepatitis compatible with a non-A, non-B viral origin. Three patients had symptoms, two being mildly icteric for a short period. The remaining patients showed only mild increases in aminotransferase levels. The data were compatible with a virus infection with a minimum incubation period of 14 to 28 days. No patients in the matched control group, receiving intramuscular HNIG from our laboratory had any clinical or biochemical evidence of hepatitis. It is not likely that the hepatitis was due to the fresh plasma that some of the patients received before the trial since aminotransferase levels at the beginning of the trial were normal. The intravenous immunoglobulin was also given, outside the trial, to patients with other conditions and their response is being carefully observed with regard to hepatitis and liver function.

From the fractionation and production aspects, these preliminary results are highly significant since the source material, a modified Cohn fraction II,⁷ for manufacture of HNIG is the same whether the

1. Bellus W. Vitamin A and retinoids: their nutrition to pharmacotherapy in dermatology and oncology. *Lancet* 1982; i: 800-63.

2. Ortuno CE, Bruzo-Falco G, Forber EM, Gutierrez Ch, Polanco MK, Schnappi R, Retinoids. Advances in basic research and therapy. Berlin: Springer-Verlag, 1981.

3. Walker SB, Howe PR. The vitamin A levels of albino rats and guinea pigs on vitamin A deficiency and repair. *Dev Biol* 1958; 8: 273-86.

4. Irving JL, Richards ML. Proximate action of vitamin A upon various tissues in the experimental rat, and sensitivity of these tissues to vitamin A deficiency. *Exp Med* 1936; 14: 7-14.

5. Bousie H, Gossu P, Hermet W-P. Proximate toxicity and sequelae of upper 100 mcg/kg of prolonged vitamin A deficiency. *J Dent Res* 1969; 48: 330.

6. Peck GL. Retinoids. Therapeutic uses in dermatology. *Drugs* 1982; 24: 241-55.

7. Lantieri J, Patrino U, Kanova I, Lanna A. Decline of plasma concentrations of retinoids and its main metabolite after treatment. *Arch Dermatol Res* 1982; 274: 377-79.

8. Gurey RJ, Amman DL. Plasma derivatives and viral hepatitis. *Transfusion* 1982; 22: 847-51.

9. Kawan P, Nussbaum H. Large-scale production of human plasma fractions. *Proteins* 1982; 7: 414-24.

NOTICE: This material
may be protected by copyright
law. (Title 17, U.S. Code)

NOTICE: This Material
may be protected by copyright
law. (Title 17 U.S. Code)

Medizinische Universitäts-Poliklinik
(Vorsteher: Prof. Dr. U. C. Dubach)
Departement für Innere Medizin, Kantonsspital Basel

U. HALTER

Der Fall aus der Praxis (224)

**Patient: Herr H. D., Arbeiter, 24jährig,
aus Jugoslawien**

Anamnese und Befunde

Ausser einem hartnäckigen Warzenproblem an den Händen war Herr H. D. immer gesund. Er arbeitete normal. Es ist keine Krankheit, kein Unfall und kein psychiatrisches Leiden bekannt. Es besteht ein Nikotin-, aber kein Alkohol- oder Drogenabusus. Auch in der Familienanamnese erscheinen keine schweren Krankheiten oder psychiatrische Leiden.

Wegen der ausgeprägten Verrucae vulgaris erhielt Herr H. D. das Dermatologen Tigason® 25 mg. Die zwei ersten Kapseln nahm der Patient gleichzeitig ein. Am nächsten Morgen schluckte er nochmals eine Kapsel Tigason® 25 mg, worauf er heftige Kopfschmerzen und Müdigkeit empfand. Deshalb sistierte Herr H. D. die Tigason®-Einnahme. Es folgten Schläfrigkeit und Halluzinationen: Er sah eine Menge böser Menschen, die auf ihn herabschauten und lachten. Der Patient ging viel schlafen, litt aber gleichzeitig an Schlafstörungen. Er träumte vom Krieg, was früher nie vorkam. Zeitweise hatte er das Gefühl, körperlich blockiert zu sein: Trotz aller Versuche konnte er sich nicht bewegen. Am Tag darauf war der Patient verwirrt. Er fuhr mit dem Tram viel zu weit und kam deshalb zu spät zur Arbeit. Trotz konkreten Anweisungen des Vorarbeiters konnte der sonst zuverlässige Arbeiter die Aufträge nicht ausführen. Der Patient konnte den Regen nicht wahrnehmen, obschon er nass wurde. Die Verwirrtheit trat intermittierend auf und ging mit einer Amnesie einher. Eine Woche nach dem Absetzen von Tigason® ging es dem Patienten allmählich wieder besser. Es bestanden noch Apathie, grosse Müdigkeit, Schläfrigkeit und ein dumpfes Gefühl im Kopf. Etwa zehn Tage nach dem Sistieren von Tigason® fühlte sich der Patient wieder ganz wohl und war voll arbeitsfähig. Im Status, fünf

Korrespondenzadresse: Dr. med. U. Halter, Med. Universitäts-Poliklinik, Kantonsspital Basel, 4031 Basel.

Tage nach der Tigason®-Einnahme, fanden sich ausser Schläfrigkeit und Kontaktarmut keine pathologischen Befunde. Insbesondere waren der Neurostatus sowie die Fundusbeurteilung normal. Leber, EEG und Schädel-CT waren ebenfalls unauffällig.

Differentialdiagnostische Überlegungen

Die Symptome, die etwa zehn Tage dauerten und ihren Höhepunkt drei Tage nach Tigason®-Einnahme erreichten, waren Kopfschmerzen, Benommenheit, Somnolenz, Desorientiertheit, Halluzinationen, die intermittierend auftraten und mit einer Amnesie einhergingen. Daraus kann die Diagnose eines Deliriums bei einem akuten exogenen Reaktionstypus gestellt werden. Differentialdiagnostisch könnte es sich um eine Erstmanifestation einer Schizophrenie handeln. Dagegen spricht jedoch die relative kurze Dauer der psychotischen Symptome. Weiter ist ein Schizophrener meist sehr wach und nicht schläfrig, wie der Patient von seinem Kollegen beschrieben wurde. Auch besteht keine familiäre Belastung. Als weitere Differentialdiagnose käme eine psychogene Psychose in Frage. Dagegen spricht, dass kein auslösendes psychosoziales Ereignis eruierbar ist.

Hingegen stehen die psychotischen Symptome in direktem Zusammenhang mit der Medikamenteneinnahme. Somit handelt es sich um einen akut exogenen Reaktionstyp, der durch eine Tigason®-Einnahme bedingt ist. Dafür spricht auch, dass nach Absetzen der Noxe eine spontane Heilung eintrat.

Unerwünschte Wirkungen der Retinoide (Roaccutan® und Tigason®) werden praktisch an allen Systemen beobachtet, so auch an Haut, Haaren, Augen, Muskeln, Knochen und Gehirn. Letztere wirken sich in Kopfschmerzen, erhöhtem Hirndruck, Übererregbarkeit, Ataxie, Schlafstörungen usw. aus. Weiter sind neben der Teratogenität auch psychiatrische Nebenwirkungen bekannt. Diese konnten nur selten in direktem Zusammenhang mit einer Retinoideinnahme gestellt werden. In der Literatur werden vor allem Depressionen (5,5 % der Patienten nach einer oralen Retinoideinnahme), Somnolenz und Persönlichkeitswandel als psychiatrische Nebenwirkungen beschrieben.

Die psychiatrischen Nebenwirkungen wurden bis jetzt nur nach längerer Behandlungsdauer beobachtet. Das Tigason® ist, wie alle andern Retinoide, fettlöslich und wird somit vom Körper akkumuliert. Unter Berücksichtigung dessen gilt eine tägliche Einnahme von 75 mg als eine hohe Normaldosis. Bei der Einnahme von 50 mg am Abend und 25 mg am Morgen, wie in unserem Fall

beschrieben, muss der akkumulative Effekt als niedrig erachtet werden. Diese Dosis wäre somit im Normalfall klein und liegt nicht im toxischen Bereich. Hingegen könnte ein anderer Mechanismus eine Rolle spielen: Die Metabolisierung von Tigason® geschieht durch eine Demethylierung am Cytochrom P450. Es besteht somit die Möglichkeit, dass diese Reaktion dem Debrisoquine- oder dem Mephenytoin-Polymorphismus unterliegt. Eine solch verminderte Metabolisierung könnte bei Trägern dieses Defekts (sogenannten Poor-metabolisern) auch bei der beschriebenen Einnahme von nur 3 Tbl. Tigason® 25 mg zur Akkumulation und somit zu den erwähnten Nebenwirkungen führen.

Diagnose

– akuter exogener Reaktionstypus (Delirium) nach Einnahme von Tigason®

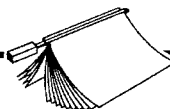
Kommentar

Obwohl psychotische Symptome als Nebenwirkungen von Tigason® in der Literatur noch nicht beschrieben worden sind, scheint der Zusammenhang des akuten exogenen Reaktionstypus mit der Medikamenteneinnahme bei dem Patienten sehr wahrscheinlich.

Bibliographie

1. *Sihla M. E., Young V. R.*: Modern Nutrition in Health and Disease. Lea & Febiger, Philadelphia, 1988.
2. *Spoerri Th.*: Kompendium der Psychiatrie. Karger, 1975.
3. *Hazen F. G. et al.*: Depression – a side effect of 13-cis-retinoic acid therapy. *J. of the Am. Acad. Derm.* 9, 278–279, 1983.
4. *Henderson C. A., Highet A. S.*: Depression induced by etretinate. *Brit. med. J.* 298, 6678, 964, 1989.
5. *Flury W. et al.*: Post-Marketing Surveillance of Retinoide. *Schweiz. Apotheker-Zeitung* 17, 470–474, 1988.

Zeitschriften/Revue



Dermatologie

Idiopathisches rekalkitantes Flushing-Syndrom des Gesichts

In diesem Artikel wird für alle Fälle von persistierendem Gesicht-Flushing unbekannter Ätiologie ein neues Syndrom geschaffen unter dem Namen «idiopathisches rekalkitantes Flushing-Syndrom des Gesichts». Drei Fälle werden beschrieben. Therapieversuche, mit Doppler-Laservelozimetrie verifiziert, haben sich als unfruchtbar erwiesen. Einige Untersuchungsmöglichkeiten und therapeutische Aspekte von schwierigen Fällen idiopathischen Flushings werden zusammengefasst.

Kommentar

Dieser kurze Artikel scheint mir für den Praktiker von besonderer Bedeutung, da die Frage eines Flushing-Syndroms bezüglich investigatorischer und therapeutischer Möglichkeiten gar nicht so selten gestellt wird. In der Diskussion dieses Artikels findet man alle diesbezüglich notwendigen Informationen.

M. Harms, Genève

Tur E., Ryatt K. S., Maibach H. I.
Dermatologica 181, 5–7, 1990

Absorption von Zink durch intakte menschliche Haut nach lokaler Anwendung von Zinkoxid

Es wurde die Zinkpenetration durch normale Haut mit Hilfe von 30% Zinkoxid unter einem Okklusivverband untersucht. Die mittlere Zinkfreigabe in der Haut war $5 \mu\text{g}/\text{cm}^2/\text{h}$. Nach 48 h Behandlung wurde mit der Kistalame-thode eine Saugblase hervorgerufen. Die Zinkkonzentration war in der Epidermis, dem Blaseninhalt und der Dermis unter dem Verband mit Zink deutlich erhöht im Vergleich zur Kontrollhaut. Diese Studie beweist, dass Zink durch die intakte menschliche Haut nach lokal aufgetragenem Zinkoxid eindringen kann.

M. Harms, Genève

Agren M. S.

Dermatologica 180, 36–39, 1990

Wirkung von Hydroxychloroquin auf den Bandtest bei diskoidem Lupus erythematoses

Es wird von zehn Fällen von lokalisier-tem und generalisiertem diskoidem Lu-pus erythematoses berichtet, bei wel-

chen die unbehandelten Patienten zehn Tage mit Hydroxychloroquinsulfat 600 mg täglich und 20 Tage mit 400 mg täglich behandelt wurden. Ziel dieser Studie war, die Wirkung dieser Substanz auf den Lupusbandtest vor und nach der Behandlung in befallener, in unbefallener lichtexponierter und in unbefallener nichtlichtexponierter Haut zu untersuchen. Bei sechs von zehn Patienten kam es zu einer eindeutig guten klinischen und immunopathologischen Antwort; bei drei weiteren Patienten bestand eine gute klinische Antwort, die aber nicht mit einer immunopathologischen Antwort korrelierte; bei einem weiteren Fall kam es klinisch zu einer Verschlechterung, verbunden mit einer Verbesserung der Immunofluoreszenz. In fünf von zehn Fällen (vier Frauen, ein Mann), bei denen eine oder mehrere Immunglobulinklassen im Lupusband vor der Therapie vorhanden waren, verblieben sie auch nach der Behandlung an der dermoepidermalen Grenze.

Kommentar

Diese Arbeit unterstreicht das gute Ansprechen von diskoidem Lupus erythematoses auf Chloroquin.

M. Harms, Genève

Chiericato G., Peroni A., Castellani L., Nigro M. A.
Dermatologica 180, 130–132, 1990

Case Reports

This photo-copy is provided by the
 NATIONAL ARCHIVES
 NOTICE: This material may be protected
 by the copyright law (Title 17 U.S. Code).

Vitamin A Poisoning in Adults*

With Description of a Case

ALEXANDER GERBER, M.D., ADOLPH P. RAAB, M.D. and ALBERT E. SOBEL, Ph.D.

Brooklyn, New York

THE present report concerns an adult with long standing vitamin A poisoning who had the highest fasting blood vitamin A level ever recorded. During the course of her intoxication, which lasted eight and one-half years, she was hospitalized ten times. Before the correct diagnosis of hypervitaminosis A was established the following diagnoses had been considered: brain tumor, serous meningitis for which she underwent a subtemporal decompression, chronic encephalitis, viral radiculoneuritis, psychoneurosis and generalized infectious arthritis. For the first time x-ray evidence of bone involvement in an adult is described.

HISTORICAL

As early as 1857 acute illness had been described by arctic explorers following the ingestion of polar bear liver. Elisha Kane mentioned "vertigo, diarrhea, and their concomitants" as the aftermath of eating this food.¹ Jackson² in 1899 mentioned that many arctic explorers of that period knew of the poisonous qualities of polar bear liver. It was not until 1942, however, that the toxic substance in polar bear liver was identified by Rodahl and Moore³ as being vitamin A.

The first reports of toxic effects of excess vitamin A in animals appeared in the late 1920's and early 1930's. von Drigalski administered a vitamin concentrate rich in vitamin A to white rats.⁴ In four to six days these animals showed dishevelled fur and marked emaciation. After five to eight days conjunctivitis, hemorrhagic rhinitis and diarrhea appeared. Within five to nineteen days the animals died. Collazo and Rodriguez conducted similar experiments.⁵ They noted inflammatory changes of the eyes, bilateral

exophthalmos, cessation of growth and spontaneous fracture of bones in addition to trophic changes of the skin and loss of hair. When the overdosage was stopped, the animals recovered and gained weight. Russo was unable to duplicate these effects in animals and concluded that high doses of vitamin A were not toxic.⁶ Clausen in an excellent review of the experimental work on this subject came to the conclusion that "the literature was so contradictory at that time (1938) so as to afford no evidence that vitamin A would have a harmful effect on human beings."⁷ Subsequently, Moore and Wang⁸ produced fatal uterine hemorrhage in adult pregnant rats by the administration of toxic doses of vitamin A.

In 1912 Czerny administered large doses of cod liver oil to tuberculous children and observed the development of seborrheic dermatitis of the face and scalp.⁹ Getz and his associates administered 50 cc. of halibut liver oil (2,000,000 units of vitamin A) in a single dose to four adults.¹⁰ All experienced dull headaches but no other symptoms. Rodahl and Moore cite the instance of a man who consumed 6,000,000 units of vitamin A daily for five days at which time he became severely ill, complaining mainly of dizziness. On stopping the vitamin A he rapidly recovered and appeared to be normal within ten days. Clinical recognition of chronic vitamin A poisoning was first described in a child by Josephs in 1944.¹¹ Since then other reports have appeared, mainly in pediatric literature. By 1952 Caffey had listed twenty-two reported cases in children.¹² Only two cases of chronic hypervitaminosis A have been reported in adults, neither of whom exhibited the advanced changes present in our patient.^{13,14}

* From the Department of Medicine and the Department of Biochemistry, Jewish Hospital of Brooklyn, Brooklyn, N. Y.

CLINICAL CLASSIFICATION

A clinical classification suggested by Knudson and Rothman divides hypervitaminosis A into acute and chronic forms as they exist in infants and adults.¹⁵

Acute Hypervitaminosis A in Infants. Acute hypervitaminosis A in infants resulting from accidental ingestion of large doses of vitamin A has been reported by Marie and See, by Mulloy and by Garcia.¹⁶⁻¹⁸ In addition to vomiting and drowsiness, there was marked bulging of the fontanelle in every case. During their illness there were no evidences of cervical rigidity, abnormal neurologic signs or fever. In every instance recovery was rapid and complete following lumbar puncture and abstinence from vitamin A. In Mulloy's case the anterior fontanelle bulged 2 cm. The spinal fluid was under greatly increased pressure and contained 30 cells of which 98 per cent were lymphocytes. The Pandy test was slightly positive and no bacterial growth was obtained. The serum vitamin A level on admission was 715 units, and after four days without vitamins fell to 217 units.* A fine cutaneous desquamation developed over the trunk and extremities after a few days.

Acute Hypervitaminosis A in Adults. Symptoms of acute hypervitaminosis A in adults appear within four to eight hours following ingestion of toxic doses of vitamin A. Headache is the predominant manifestation and has been described as being violent and localized in the forehead and eyes. Nausea, vomiting, vertigo, drowsiness, irritability and localized or generalized peeling of the skin are common findings. Lonic reported a family with vitamin A poisoning following a meal of shark liver.¹⁹ Their symptoms consisted of severe headache, dizziness, nausea and vomiting. Recovery was rapid and complete. Within thirty-six hours desquamation of the skin started and later became extensive.

Chronic Hypervitaminosis A in Infants. In 1944 Josephs reported the first case of chronic hypervitaminosis A in a child.¹¹ Toomey and Morissette in 1947 described a similar case.²⁰ They were able to reproduce the original symptoms and signs in this two year old infant by giving 6,200,000 units of vitamin A during a period of fourteen days. Gribetz, Silverman and Sobel²¹ reviewed the literature and summarized the findings in seventeen cases, including two cases of their own. Most instances occurred in the second or third year of life and followed months

of excessive vitamin A intake. The most prominent features were cortical thickening of the bones, painful swellings in the extremities, irritability, pruritus, hepatomegaly, limitation of motion or inability to stand, sparse coarse hair, fissuring of the lips, constipation and a failure to gain weight. Splenomegaly was noted only by Josephs.

Gribetz et al. reported the case of a seventeen month infant who had enlargement of the head. Slightly dilated ventricles on pneumoencephalogram and ventriculogram suggested hydrocephalus. Following a reduction in vitamin A intake her head assumed normal proportions. A six and one-half month old girl with chronic hypervitaminosis A was described by Arena as having marked craniotabes.²² X-ray of the skull showed uniformly thin bones. There was no hyperostosis. After elimination of all vitamin preparations the skull bones became normal.

Chronic Hypervitaminosis A in Adults. Only two cases of chronic hypervitaminosis A have been reported in adults. Sulzberger and Lazar in 1951 described a forty-four year old woman who, in an attempt to prevent "colds," had taken 600,000 units of vitamin A daily for eighteen months, supplemented by occasional doses of 1 to 2 million units.¹² Her complaints and findings included the following: menstrual periods of shorter duration and decreased flow; generalized joint and bone pains; soreness and fissuring at the corners of the mouth and nasal apertures; dry rough skin with brawny desquamation, peculiar pigmentation, excessive loss of hair, and generalized pruritus; night sweats; and increased prominence of the eyes. Note should be made that x-rays of several long bones and joints revealed normal features, and that headaches were not included as part of the symptomatology. Her highest vitamin A level was 60 blue units.*

Bifulco¹⁴ in 1953 presented the case of a fifty-two year old woman with a four-year history of daily intake of 100,000 units of vitamin A. After one year on this regimen insomnia and listlessness appeared. Subsequently, loss of hair, stiffness and pain in the joints, a patch of pigmentation on the forehead, and increased prominence of the eyes were noted. Because of possible dental infection, teeth were extracted with resultant severe hemorrhage. Anorexia, marked loss of weight and spontaneous oozing of blood from the nose appeared. Menses, which had become irregular about one year after the onset of vitamin

* 1 µg. of vitamin A = 3.33 U. S. P. units.

* Normal = 10 to 20 blue units.

A ingestion, ceased within the following two years. The eyes were prominent and pulsated, and the fundi disclosed abnormal pulsation of the retinal veins. A thumping headache developed one month prior to the cessation of vitamin A ingestion and was still present six months after all vitamin A had been stopped. Cerebral angiography was performed but failed to disclose an aneurysm. There was pain on flexion of all joints and marked tenderness was elicited over the long bones of the extremities. There was no joint swelling or deformity. No mention was made of x-rays. Headache and pulsation of the right eye persisted at the time of the report, all other manifestations having returned to normal several weeks after vitamin A was stopped.

CASE REPORT

S. L., a twenty-one year old unmarried white female was admitted on July 24, 1945, to hospital "A." Her chief complaints were diplopia for five weeks and headaches and nausea for four weeks. Five weeks prior to admission she noted blurring of vision followed by diplopia. This persisted and was in turn followed by severe frontal headaches and nausea. Three weeks prior to admission the patient began to have incontinence of urine and nocturia, as well as occasional enuresis. She also developed urgency and frequency but no burning on urination. Systemic review revealed occasional joint pains occurring with inclement weather. She had a cold for two weeks, and a cough for one week prior to admission. Her family history revealed hypertension in two grandparents and cancer in a third. Menses began at twelve years with regular thirty-day cycles lasting five days with a normal flow. There was occasional dysmenorrhea. She smoked one pack of cigarettes a day.

The physical examination at this time showed temperature 99.6°F., pulse 84, respirations 20, blood pressure 105/75. She was a well developed, well nourished white female in no distress. The eyes reacted equally to accommodation and light. Pupils were round, the left slightly larger than the right. There was internal strabismus with uncrossed diplopia and nystagmoid twitchings in both lateral gazes, right more than left. After repeated lateral eye movements the nystagmus became more sustained. Fundus examination showed both discs hyperemic, margins slightly blurred, slight venous congestion and a tiny hemorrhage near the right disc nasally. Bone conduction was greater than air conduction

on the left. Facial sensations, corneal reflexes and jaw motion were normal. Hearing was normal. Tongue movements, swallowing and taste were normal. The neck was supple and no glands were palpable. The lungs were clear to percussion and auscultation. Examination of the heart showed regular sinus rhythm, P_2 greater than A_2 , the point of maximal impulse in the fifth intercostal space. There were no thrills or murmurs. The liver, spleen and kidneys were not felt and no abdominal tenderness was present. No costovertebral angle tenderness or vertebral tenderness was elicited. Motor power was normal in all limbs. The reflexes were symmetrical and equal throughout except for the right knee jerk which was greater than the left. No pathologic reflexes were elicited. The finger to nose, heel to knee and pronation-supination tests were normal. Light touch and pinprick were normal throughout. Position and vibration were appreciated in the great toes; however, vibration was diminished generally on the left. Gait and speech were unimpaired. The patient was alert, intelligent and cooperative.

X-ray of the skull showed some increase in the digital markings of the cranial vault. The sella turcica was normal in size and shape. No abnormal calcifications were demonstrated. Examination of the skull following direct ventricular injection of air showed that the anterior horns were well outlined. They showed some dilatation but no evidence of a shift. The bodies of both lateral ventricles, however, were poorly outlined. The posterior and inferior horns appeared normal. The visual fields on two separate occasions showed a small but definite constriction bilaterally, the left slightly more than the right. Visual acuity was O.D. 10/15, O.S. 10/10.

The laboratory findings were as follows: urinalysis, 1 plus albumin on 2 occasions; red blood count 4,000,000; hemoglobin 81 per cent; white blood count 10,700, with a normal differential count: E.S.R. 3 mm. one hour; spinal fluid, glucose 56 mg. per cent, total protein 31 mg. per cent; ventricular fluid from the right side, total protein 15.6 mg. per cent; serologic tests for syphilis negative in blood and spinal fluid.

During the patient's stay a definite increase in the degree of choked disc was noted, more papilledema being present on the right than on the left. When she looked to the right the nystagmus was definite and well sustained, the right

732

lateral deviation being greater than on the left. The patient also began to notice diplopia on straight gaze. On occasion she complained of pain in her left trapezius region and left leg. Ventriculography was done, both anterior ventricles being tapped. A moderate amount of clear colorless fluid escaped under increased pressure from the right anterior horn. When the head was tilted no additional fluid was obtained from the right anterior horn and therefore the left anterior horn was entered. Although air had been injected into the right anterior horn under increased pressure, no air bubbles appeared in the brain cannula when the left anterior horn was tapped and the fluid which escaped seemed to be slightly cloudy. Ventriculograms revealed the lateral ventricles to be normal in shape, size and position. The third and fourth ventricles were not well visualized. An electroencephalogram suggested posterior fossa tumor or some other subtentorial disturbance.

The patient left the hospital on September 6, 1945, with a diagnosis of intracranial neoplasm. Six days later she was admitted to hospital "B." At this institution additional history was obtained. The patient stated that she had "ichthyosis" as long as she could remember and had been taking large doses of vitamin A for the past one and one-half years with remarkable improvement of the skin. Otherwise both history and physical examination were unchanged. X-ray of the skull confirmed the impression of increased intracranial pressure. Because of the normal lateral ventricles the neurosurgeon believed that poor visualization of the third and fourth ventricles was not due to obstruction at the foramen of Monro, aqueduct of Sylvius or the fourth ventricle. He favored a diagnosis of serous meningitis and performed a right subtemporal decompression. There was a continued outpouring of fluid after the dura was incised.

She was readmitted to hospital "B" on August 15, 1946, approximately eleven months after her previous discharge. She had remained "relatively well" until six weeks before this admission, when she began to have pain in the region of the seventh right rib in the anterior axillary line. This pain seemed to spread posteriorly to the region of the ninth thoracic vertebra and later also to the right ninth costochondral junction. At times she noticed that her legs began to feel heavy. Three days before admission she noticed numbness in the saddle area. Her right-sided chest pain was accentuated

by coughing and sneezing but not by straining. It was also increased if the patient lay on her abdomen.

Physical examination at this time revealed a markedly bulging area at the site of the previous subtemporal decompression. The neck was quite supple but extreme flexion caused the patient's chest pain to appear. Although the fundi showed rather full veins, the discs were well outlined. There was some diplopia on left lateral gaze and some left central facial weakness. Sensory and motor findings were normal. Reflexes were active and equal except for some hyperactivity of the biceps jerk on the left. Hoffmann's sign was positive bilaterally. There was localized tenderness over the lower chest wall at about the ninth right rib anteriorly. No spine tenderness was elicited.

Studies at this time showed the urine and the blood count to be normal. The urea clearance test and the blood sugar, urea nitrogen, total protein and cholesterol were within normal limits. The cephalin flocculation and thymol turbidity tests were normal. A lumbar puncture revealed clear fluid under normal pressure with a negative Pandy test. X-ray of the chest failed to reveal any local pathologic condition of the bone. The x-ray of the spine showed some hypertrophic lipping of the contiguous surfaces of the fifth and sixth thoracic vertebrae. Skull x-rays were normal except for the bony defect of the previous decompression. A pneumoencephalogram was likewise normal. Intravenous pyelography showed no abnormality.

During her hospitalization of two and one-half months there was no improvement. She was treated with thiamin chloride for possible intercostal neuritis. Radiation therapy also failed to cause any lessening of her pain. The medical consultant believed that her pain was probably unrelated to her cerebral lesion. The neurologist suggested that such pain is often the result of medulloblastoma metastases, although in this case a large psychic element had to be considered. There was no improvement and the patient was discharged with the diagnosis of costalgia, cause unknown.

The patient was admitted to hospital "C" on February 10, 1947, because of persistence of her complaints. Examination revealed a markedly bulging right subtemporal decompression. The fundi showed pallor and the disc margins were somewhat indistinct. There appeared to be atrophy of the right rhomboid and supra-

scapular muscles. The right scapula was winged. The patient stood in a position of forward flexion and because of pain in the right hip and knee favored the right lower extremity in walking. Blood studies included a serum phosphorus of 4.0 mg. and alkaline phosphatase of 6.2 units.

X-rays of the chest, dorsal spine and foramen magnum were considered normal. Fever therapy with typhoid vaccine was given but the results, while definite, were far from dramatic. A tantalum cranioplasty was performed and the patient was discharged on April 7, 1947. The discharge diagnosis was chronic encephalitis.

One month later the patient was admitted to hospital "D" with a febrile illness of eight days' duration during which period the pains in her knees, elbows, right hip and left shoulder had become aggravated. The exact nature of this acute illness was never determined. While physical examination of the chest was always negative, indefinite findings on lung x-ray suggested a pneumonitis. Many tests and observations were made during this hospitalization, the most significant of which were: sparse eyebrows, pigmentation over the skin of the abdomen, hepatosplenomegaly, moderate anemia and marked tilting of the pelvis. Tests for liver function were normal, including BSP and hippuric acid excretion tests.

During this hospitalization her bone and joint pains continued and her deformity seemed more marked. It was noted that while the pain in her back persisted, she was comfortable when perfectly quiet. Her greatest difficulty occurred with change in position after a period of rest. The back muscles showed spasm of moderate degree and there was a flexion contracture of the right hip. The hip joint was entirely normal, motion in all directions being free and painless, with no tenderness present. Moderate tenderness was noted in the right ilio-lumbar angle, with negligible tenderness of the spine and sacroiliac joints. A plaster of Paris spica was applied from the nipple line to the middle of the right leg. On July 14, 1947, she was discharged. When she returned five weeks later for removal of the cast there was no apparent improvement. At this time the liver was felt one and one-half finger-breadths below the costal margin. The skin was uniformly hyperpigmented, dry and shiny. The palms were cracked and scaling. One neurologist believed that the picture was one of cerebral and posterior root disorder, at various times affecting the thoracic and lumbosacral

segments. He believed that the hepatosplenomegaly had a common etiology with that of the neuropathology and therefore diagnosed encephaloradiculitis due to a virus infection.

The patient re-entered hospital "D" for the third time in five months because physiotherapy, which had been started during her previous admission and continued while at home, failed to arrest the progress of her disease or alleviate her symptoms. It was noted that she had continued to take 500,000 units of vitamin A daily for her skin condition and this was continuously administered during her hospital stay. Right lateral rotatory nystagmus was present. The lips showed desquamation, and the pigmented skin was noted to be most prominent over the left mid-abdomen. Tests for Addison's disease were negative. Biopsy of the skin did not show hemosiderin deposits. The basal metabolic rate was minus 1 per cent. Special oblique studies of the lumbar vertebrae showed no abnormality, although she now had a completely rigid "poker" spine. A plaster jacket was applied from the groin to the axilla with considerable relief. At the time of discharge on November 11, 1947, she still had a two-fingerbreadth enlargement of the liver.

Five months later, April 6, 1948, she had a muscle biopsy at hospital "E." Microscopic sections failed to reveal lymphoid infiltration. The following month she was readmitted because of multiple severe joint pains and inability to walk straight. The physical examination showed diplopia on lateral gaze, limited chest expansion, drooping right shoulder, elevated right hip, shuffling gait, bilateral hip limp, rigid back, generally limited joint motion, trunk inclined forward and flexion contractures of the knees and hips. X-ray studies were read as showing incomplete fusion of the bodies of the fourth and fifth cervical vertebrae, an ankylosing process of the upper dorsal spine, a slight list of the lumbar spine to the left without evidence of an arthritic process, and moderate arthritic changes in both sacroiliac joints.

The following were described as radiographically normal: chest, right shoulder girdle, both hips and right knee. Laboratory studies revealed an elevated sedimentation rate and increased blood alkaline phosphatase. The patient was treated with orthopedic measures and discharged to the outpatient department for continued physiotherapy. The discharge diagnoses were

neurologic examination were as follows: cranial nerves intact; cerebellar tests normal; sensory and motor systems intact; reflexes equal throughout except for the right knee jerk which was greater than the left; no pathologic reflexes. Dermatologic findings were: thinning of scalp hair, axillary hair and eyebrows; nails normal; skin diffusely pigmented, coarse over most of the body, but dry, shiny and somewhat atrophic with associated loss of lanugo hair over the arms and legs; elbows keratotic and scaly; palms and soles scaling, with deeply marked furrows and dried blebs; many scratch marks throughout. Orthopedic examination showed: temporomandibular joints and facial muscles normal; neck movements normal in range and strength; spine fixed in extension although tilted forward and slightly to the left, without tenderness but painful on motion; extreme paravertebral wasting; rib cage fixed and tender on compression; right shoulder painful on elevation to 90 degrees and fixed after 110 degrees; elbows, wrists and fingers normal; left hip relatively normal; right hip painful with limitation of terminal 30 degrees of extension and 50 degrees of abduction; the feet showed fixed hallus valgus.

Laboratory studies were as follows: hemoglobin 74 to 81 per cent (15 gm. = 100 per cent); red blood count 3.7 to 4.4 million; white blood count 6,400 to 7,400; polymorphonuclears 64 per cent, bands 1 per cent, lymphocytes 31 per cent, monocytes 2 per cent, eosinophils 1 per cent, basophils 1 per cent, platelets adequate; hematocrit 42 per cent. Bone marrow aspiration normal; myeloblasts 5 per cent, neutrophilic myelocytes 9 per cent, eosinophilic myelocytes 0, metamyelocytes 38 per cent, staff forms 39 per cent, polymorphonuclears 6 per cent, eosinophils 3 per cent, megakaryocytes adequate, granulocyte:polymorph ratio 91:9; granulocyte:erythrocyte ratio 90:10; red cell sedimentation rate 22 mm., one hour; bleeding time two minutes; clotting time three minutes fifteen seconds; urinalysis, specific gravity 1.022, albumin 0, sugar 0, microscopic examination negative; basal metabolism, plus 12 and plus 10; electrocardiogram within normal limits. (See Table 1 for chemical determinations.)

The results of x-ray examination were as follows: Skull: right subtemporal decompression with tantalum plate *in situ*; slight thinning of vault of skull; slight hyperostosis frontalis interna. Shoulders: thinning of wings of scapulae, more marked on left; thin rim of calcification

parallel to rim of glenoid fossa. Ribs: normal. Dorsal spine: narrowed intervertebral spaces with thinly calcified anterior spinal ligament; moderate decalcification of vertebral bodies; pedicles and laminae intact; interpedicular distances normal. Lumbar spine: straightened

TABLE 1
BLOOD DETERMINATIONS

	February 13	March 3	April 14
Sugar*	100	96	73
Urea acid*	4.2	3.7	4.0
Urea*	15	15	16
Urea index	9.6	12.0	13.3
Ca ⁺⁺	9.4	9.3	8.9
Total protein, gm./100 cc.	7.3		7.6
Albumin/globulin ratio	1.6		1.6
Vitamin C [†] (normal = 7-25)	0.7		
Bilirubin, free*	0.5		
Bilirubin, total*	0.7		2.7
Total cholesterol*	207	227	222
Free cholesterol	32	26	28
CO ₂ combining power (vol. %)	61.6	60.9	56.0
Sodium*	333	322	318
Potassium*	16.3	18.1	18.9
Chloride*	328	342	352
Inorganic phosphorus*	3.8	3.4	4.1
Alkaline phosphatase†	3.5	3.6	3.7
Cephalin flocculation	0		
Thromb turbidity	4.4		
Amylase (isomogy units)	70		
Amylase control	72		
Amino acid*	7.4		
Total fatty acids*	330		
Phospholipid phosphorus*	10.5	10.4	
Total lipid (Blair method)*	418		
Prothrombin time	14.4 sec.	14.0 sec.	
Prothrombin time control	10.1 sec.	11.2 sec.	
Protein-bound iodine µg./% (normal = 3-8)			1.8

Clotic Acid* (normal = 1.5-2.6)

Date

2/25 1.9

2/24 1.9

2/23 1.8

2/22 1.7

2/21 1.7

2/20 1.7

2/19 1.7

2/18 1.7

2/17 1.7

2/16 1.7

2/15 1.7

2/14 1.7

2/13 1.7

2/12 1.7

2/11 1.7

2/10 1.7

2/9 1.7

2/8 1.7

2/7 1.7

2/6 1.7

2/5 1.7

2/4 1.7

2/3 1.7

2/2 1.7

2/1 1.7

1/31 1.7

1/30 1.7

1/29 1.7

1/28 1.7

1/27 1.7

1/26 1.7

1/25 1.7

1/24 1.7

1/23 1.7

1/22 1.7

1/21 1.7

1/20 1.7

1/19 1.7

1/18 1.7

1/17 1.7

1/16 1.7

1/15 1.7

1/14 1.7

1/13 1.7

1/12 1.7

1/11 1.7

1/10 1.7

1/9 1.7

1/8 1.7

1/7 1.7

1/6 1.7

1/5 1.7

1/4 1.7

1/3 1.7

1/2 1.7

1/1 1.7

12/31 1.7

12/30 1.7

12/29 1.7

12/28 1.7

12/27 1.7

12/26 1.7

12/25 1.7

12/24 1.7

12/23 1.7

12/22 1.7

12/21 1.7

12/20 1.7

12/19 1.7

12/18 1.7

12/17 1.7

12/16 1.7

12/15 1.7

12/14 1.7

12/13 1.7

12/12 1.7

12/11 1.7

12/10 1.7

12/9 1.7

12/8 1.7

12/7 1.7

12/6 1.7

12/5 1.7

12/4 1.7

12/3 1.7

12/2 1.7

12/1 1.7

URINE DETERMINATIONS

(Twenty-four-hour Excretion)

Calcium	726 mg./1,260 ml.	(Normal = 100-300 mg.)
Uric acid	760 mg./total	(Normal = 200-914.5 mg./1,180 ml.)
Phosphorus	878 mg./1,260 ml.	(Normal = 400-652 mg./1,180 ml.)

lordotic curve; moderate decalcification of vertebral bodies; intervertebral spaces normal; minimal spur formation at anterior aspects of

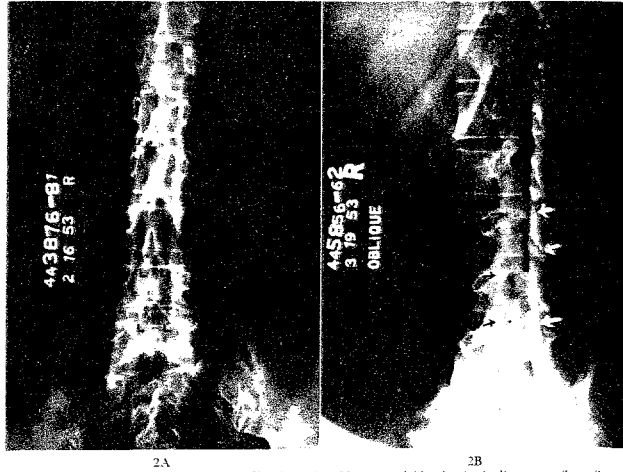


FIG. 2. A, anteroposterior roentgenogram of lumbar spine. Note the calcification in the ligamenta flava (letters L overlying these structures between the third and fourth and fourth and fifth lumbar vertebrae). Similar changes exist in the ligamenta flava between the neural arches of the upper lumbar vertebrae. B, right posterior oblique roentgenogram of lumbar spine. The white arrows point to the calcified ligamenta flava. The black arrows indicate the loss of definition of the apophyseal joints, with narrowing of the joint spaces.

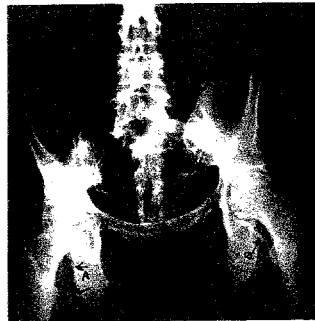


FIG. 3. Anteroposterior roentgenogram of pelvis. Periosteal elevation along ischial ramus (A), and calcification in articular capsule (B) are indicated by the respective black arrows.

upper lumbar vertebral bodies; apophyseal joints narrowed, with loss of definition of their articular surfaces; moderate calcification of ligamentum flavum; slight calcification of iliolumbar ligaments. (Figs. 2A and B.) Pelvis: sacroiliac joints normal; pelvic inlet distorted because of inability of patient to assume recumbent position; calcification in periosteal elevations and probable bone formation in lateral aspects of both iliac bones just above acetabular sockets; calcification in capsule of hip joint at insertion into superior rim of acetabulum bilaterally; similar but lesser degree of calcification in inferior aspects; shaggy appearance of ascending ramus of right ischium; a single spur-like projection of ascending ramus of left ischium and of lesser trochanter of right femur. (Fig. 3.) Hands: normal. Feet: normal. Knees: calcification at anterior tibial tubercles and anterior inferior aspects of patellas bilaterally; local thickening at upper medial aspect of left tibia; bony densities not disturbed. (Fig. 4.) Os calcis: calcification at

insertion of achilles and plantar tendons bilaterally.

Skin biopsy from the mid-abdomen showed moderate hyperkeratosis with thickening of the granular layer which contained foci of dyskeratosis as evidenced by marked vacuolization of the cells; dense hyperpigmentation of the basal layer with intracellular melanin involving some of the overlying cells of the prickle layer; normal corium. The diagnosis was hyperkeratosis with pigmentation.

Bone biopsy from the right tibial tubercle showed broad osseous trabeculae which in places presented calcification of the cartilage, thickening of the periosteum and normal marrow spaces. (Fig. 5A and B.) The diagnosis was calcification in cartilaginous tissues with thickened periosteum.

Immediately after the patient was admitted to the hospital all vitamin A medication was stopped and she was given a normal hospital diet.* Within two and a half weeks her itching had disappeared and there were no further evidences of scratch marks. At the end of one month her skin texture had improved, her bone pains were markedly diminished, her appetite was excellent and she had gained weight. Six weeks after admission she woke one morning with marked dizziness and diplopia. There was no headache. Nystagmus was present on lateral gaze. The fundi were normal. Her diplopia gradually receded and was completely gone by the end of one week. Two months after vitamin A medication had been stopped, all spontaneous pain had gone and no further sedation was needed. Her posture had begun to improve.

During her stay she had three normal menstrual periods occurring at monthly intervals and lasting five days with a normal flow. Her improvement was continuous and she was discharged on April 26, 1953.

COMMENT

Hypervitaminosis A may result from the ingestion of large amounts of vitamin A concentrates taken alone or in combination with other vitamins or minerals. Large doses of vitamin A are used in the treatment of skin, eye, renal, gynecologic and ear disorders as well as the common cold. The minimal daily requirement of vitamin A is 5,000 to 7,000 international units. In the usual diet this requirement is derived from both vitamin A and its precursor

* 7,500 units of vitamin A daily.

MAY, 1954

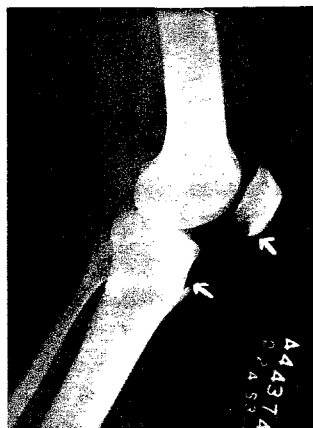


FIG. 4. Lateral roentgenogram of left knee. White arrows point to calcification in infrapatellar ligament.

carotene, which is converted in the intestinal wall and possibly elsewhere, into vitamin A.²³⁻²⁵ The conversion of carotene to vitamin A is limited and may not provide sufficient vitamin A to maintain the patient during stress.²⁶ Moreover, there is evidence to indicate that the conversion of carotene to vitamin A is impaired in some diseases, such as diabetes.²⁷⁻³¹

Vitamin A is absorbed as the free alcohol and is esterified in the intestinal wall. Following vitamin A intake the rise in serum levels is due to the ester fraction, most of which is then deposited in the liver as such.^{21,42} Vitamin A alcohol levels are not directly influenced by ingestion. The vitamin A alcohol level seems to be a measure of vitamin A storage.³² In severe infection, in hepatocellular disease and in vitamin A depletion the plasma vitamin A alcohol level is usually low. The normal vitamin A blood level is 30 to 70 μg . and may rise to 1,000 to 2,000 μg . soon after the ingestion of very large doses of vitamin A. This is a temporary state and does not alter the subsequent fasting level.

The fasting level of 2,000 μg . per 100 cc. in our patient is the highest reported in man. Unlike such high levels observed following administra-

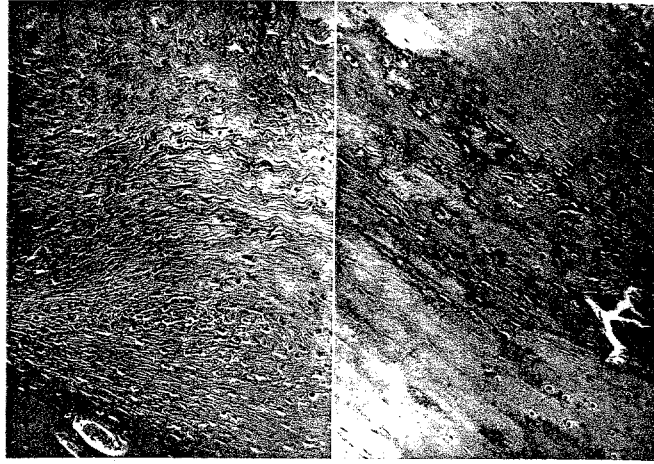


FIG. 5. Right tibial tubercle biopsy. A, note the marked periosteal thickening; B, note the calcification in the cartilaginous tissue.

tions of vitamin A, most of the blood vitamin A content in this patient was in the form of the free alcohol, not as ester. This high percentage of vitamin A alcohol with high total blood levels of vitamin A has been observed in a child reported by one of us.²¹ There is a possibility that not only the total vitamin A but the relatively high percentage of alcohol has significance in the diagnosis of hypervitaminosis A. In the previously reported adult cases the vitamin A level was 60 blue units* in one and unrecorded in the other.

The high vitamin A blood level of our patient was the result of continued daily ingestion of vitamin A for eight and one-half years. After four months of taking 25,000 units daily, she increased her dosage to 50,000 units and then rapidly to 500,000 units daily. On occasion, an additional dosage of 500,000 units was taken. The preparations of vitamin A which she had taken were stated by their manufacturers to be free of vitamin D.

During the course of this study, we had the

* Normal = 10 to 20 blue units.

opportunity of examining the blood of four other patients who had taken large doses of vitamin A over prolonged periods of time. While we cannot be certain that blood levels are a good index of vitamin A storage, they may be an index of toxicity since the transfer of vitamin A in the body is related to blood levels rather than to the total amounts of vitamin A stored. One patient had taken 25,000 units daily for three years, then 25,000 to 50,000 units for the next three years, and finally 50,000 to 100,000 for two years. Her fasting blood level was 120 μg . per 100 cc. Another patient who consumed between 25,000 and 50,000 units daily for six years had a fasting level of 88 μg . per 100 cc. A third patient took 25,000 units daily for six years and had a normal fasting level of 60 μg . per 100 cc. A fourth patient who took 50,000 units daily had a fasting level of 225 μg . per 100 cc. after eight months. Only the first and last patients had any complaints referable to possible vitamin A toxicity. Both had headaches which subsided soon after they stopped vitamin A therapy. It is apparent that individual factors

greatly affect the size and duration of the dose that will produce toxic effects.

Daily vitamin A plasma levels were determined during the eleven weeks of hospitalization to observe changes in the blood levels while the patient was on a normal hospital diet. (Fig. 6.)

the alcohol, ester or total vitamin A level in the blood is the best measure of vitamin A storage, as we did not attempt to assay the liver or other tissues for vitamin A content. We are unable to explain the change in serum vitamin A alcohol-ester relationship in the light of present concepts

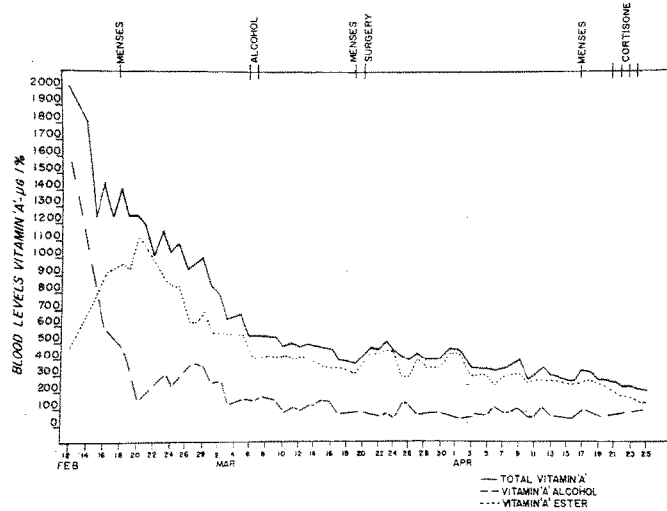


FIG. 6. Vitamin A blood levels during first ten weeks of hospitalization.

Vitamin A partitions into the alcohol and ester, together with the carotene level, were followed daily. Apart from the admission carotene level of 360 μg . per 100 cc., all carotene levels were between 180 and 290 μg . per 100 cc. (normal 54 to 310). At the onset the vitamin A levels, while extremely high, maintained the ratio of 20 per cent ester to 80 per cent alcohol. Immediately after stopping the vitamin A intake, there was a precipitous fall in the total vitamin A level, which reflected a parallel fall in the vitamin A alcohol. (Fig. 6.) However, during the first week while the alcohol fraction was falling, the ester fraction showed a very marked rise so that the ratio of ester to alcohol became reversed. This reversed ratio persisted.

We cannot establish from this study whether

of vitamin A metabolism. Is the vitamin A now being transported from the liver to the tissue in the form of ester? Has excess vitamin A in ester form been deposited in depots other than the liver, and is it now being released to the circulation in this esterified form? This would be consistent with the disappearance of hepatic enlargement. While the patient presented hepatomegaly during a six-month period, it was not present during the latter years of her illness in spite of continued excessive intake of vitamin A. This would not be expected if liver enlargement is considered an expression of vitamin A deposition. Repeated laboratory studies during her illness showed no evidence of impaired liver function, even when hepatomegaly was present. While liver enlargement has been found

frequently in children with vitamin A toxicity, it has not been noted in the previously reported adults. Splenomegaly, which was present in Josephs' case, was found in our case at one time.

Vitamin A tolerance tests carried out with half and full doses revealed no deviation from the normal. They showed the rise to be in the ester form while the alcohol fraction remained relatively unchanged.

Josephs^{11,17} observed that a rise in serum lipids occurs early in the course of vitamin A toxicity, only to return to normal in spite of continued massive dosage. In our case the blood lipids were normal.

Alkaline phosphatase studies made while the patient was under our observation were repeatedly normal. However, six years before, elevated levels were found for a period of more than one year in two different hospitals. This finding is in agreement with the elevated levels found in many of the cases reported in children. This increase in serum alkaline phosphatase is probably associated with an increase in bone metabolism. In a previous adult case no alteration in the serum alkaline phosphatase was noted.

There has been interest in vitamin A as an agent in the prevention of renal calculi. In nephrolithiasis urinary citric acid tends to be low, and it has been observed that aqueous dispersions of vitamin A may cause a rise in the urinary citric acid level with possible resulting increased solubility of calcium stones.¹⁸ We undertook studies of the blood levels and urinary excretion of citric acid, calcium and phosphorus. These blood findings were repeatedly within upper normal limits, as were the urinary excretion of citric acid and phosphorus, both in twenty-four-hour total output and concentration. However, the calcium excretion in the urine was markedly increased in both concentration and amount.

Rodahl¹⁸ found that animals with experimental hypervitaminosis A showed low ascorbic acid in the adrenals and liver. Moore and Wang¹⁹ were unable to confirm this finding. Gribetz et al. did not find evidence of vitamin C deficiency in their studies and our patient had a normal vitamin C blood level. There were no clinical manifestations of scurvy.

Studies were made to determine the effects of menstruation, starvation, large amounts of

alcohol, cortisone and operative procedures upon the total blood vitamin A levels as well as upon the alcohol and ester fractions.

It has been observed that normal women have a cyclic change in the serum vitamin A level which reaches a minimum at the time of menstruation and a maximum between menstrual periods.²⁰ This variation was not noted in our patient, who failed to show any appreciable change in relation to the menstrual cycle. The toxic levels exhibited by our patient could well have masked the slight changes noted in normal women with normal blood levels.

On two consecutive days the patient was given a pint of wine in addition to her regular diet. No influence on the vitamin A level was noted. Likewise, no appreciable effect was noticed after short periods of starvation. Because of the report that cortisone causes depletion in the amount of vitamin A present in the liver of the rat, our patient was given cortisone in doses of 300, 200, 100 and 100 mg. consecutively for four days.²¹ No significant changes occurred in the vitamin A levels. This does not mean that the vitamin A stores were not affected. It would be of interest to observe the effect of cortisone in a patient presenting acute symptoms of hypervitaminosis A.

Biopsy of the tibial tubercle was performed under intravenous sodium pentothal anesthesia. There was a seventy-two-hour rise in the level of vitamin A from 350 μg . to a peak of 490 μg . This was due entirely to an increase in the ester fraction. During the following seventy-two hours the esters returned to their previous level. The alcohol fraction, which had remained unchanged throughout, rose markedly on the fifth and sixth postoperative days and then fell to the previous level. This vitamin A must have come from the body stores and it is interesting to note that the original rise was in the ester rather than in the alcohol fraction.

NEUROLOGIC CONSIDERATIONS

There is much evidence to indicate that vitamin A poisoning may produce intracranial disturbances.^{15,16,18} In infants massive doses of vitamin A resulted in a marked increase in the cerebrospinal fluid pressure with bulging of the fontanelle. Cerebral manifestations such as severe headache, nausea, vomiting, dizziness, drowsiness and irritability are seen in adults

who receive massive doses of vitamin A.^{3,10,19} Both Gribetz and Arena have reported enlargement of the head in children with chronic hypervitaminosis A. In each instance there was a return to normal following withdrawal of vitamin A medication. In the case reported by Bifulco headaches played a prominent part. Since the headaches were associated with bilateral pulsating exophthalmos, Bifulco's patient was hospitalized for cerebral angiography which failed to disclose the suspected aneurysm. At the time of his report the exophthalmos had completely receded although pulsation of the right eye persisted. The exact nature of this mechanism is not apparent. However, the absence of an aneurysm, the recession of the exophthalmos, and the disappearance of the pulsation of the left eye since the withdrawal of vitamin A indicate a causal relationship.

In the case here reported the primary manifestations were headache, blurred vision, diplopia and nausea. These led to a diagnosis of serous meningitis, a condition of increased intracranial pressure considered to be due to thrombosis of the dural venous sinuses secondary to infection or, more rarely, trauma;⁵² at times there has been no apparent etiology for the condition and Davidoff and Epstein⁵³ reported a series of cases which occurred mainly in young people with a history of infection of the middle ear or mastoid. When our patient was first seen by us the subtemporal decompression which had been done to relieve the suspected serous meningitis was still tense and bulging. Ten weeks after the excessive vitamin A intake was stopped, the decompression was completely soft. If she is to be considered to have had serous meningitis, vitamin A toxicity must be added to the causes of this condition. We have no knowledge as to whether dural vein thrombosis was present in this case but there is enough evidence to show that either excess production or decreased absorption of spinal fluid results from vitamin A toxicity. No other explanation can account for the persistence of a tense bulging decompression until vitamin A excess was stopped. The transient episode of diplopia and nystagmus that occurred during her hospital stay took place while her blood level was 444 μg . (more than seven times normal) and therefore while she was still experiencing vitamin A toxicity. The decompression has remained soft and no further cerebral manifestations have occurred since her discharge from the hospital.

SKELETAL MANIFESTATIONS

Our case is the only adult yet reported to demonstrate bone changes. Although bone pains and disability were present in both previously reported adult cases, no x-ray changes were noted in the one case in which they were sought. Radiologic findings in our patient were present in the dorsal and lumbar spine, pelvis, femora, patellae, tibiae, os calcii, scapulae and skull. The fundamental disorder consisted of calcification, with or without true bone formation, of the pericapsular, ligamentous, tendinous and subperiosteal structures. Also noted were decalcification in the skull, scapulae and vertebral bodies. The periosteal changes were the same as observed in the cases of hypervitaminosis A in children. The bone changes were far more extensive, however, probably due to the longer period of toxicity. Biopsy of the tibial tubercle of our patient showed thickened periosteum with secondary calcification. These findings are similar to those of Rineberg and Gross⁵⁴ whose biopsy of a child's fibula "showed a strip of newly formed, poorly calcified bone of coarse fibered structure such as is usually seen in ordinary productive periostitis." Six months after vitamin A intake was stopped the child's x-rays showed the subperiosteal calcification to have completely disappeared.

Except for those changes found in the spine of our patient, no similar alterations are demonstrated by any other disease. The spine changes had been diagnosed as Marie-Strümpell arthritis during a previous hospitalization elsewhere. In our opinion there are marked differences between the two conditions. In Marie-Strümpell arthritis the sacroiliac joints are usually involved early and progress with the disease; the anterior spinal ligaments show extensive calcification; there is progressive osteoporosis of the vertebral bodies; calcification of the ligamenta flavae is absent; and clinical improvement occurs slowly, if at all, with therapy.⁵⁵ On the other hand, in hypervitaminosis A we have noted that the sacroiliac joints are spared; that only minimal calcification of the anterior spinal ligament occurs; that there is only minimal decalcification of the vertebral bodies; that the ligamenta flavae are calcified; and probably most important, clinical improvement is marked and rapid upon the discontinuance of excessive vitamin A intake.

The marked decalcification of the scapulae

may be related to the high excretion of calcium in the urine. This in turn may be the result of hypervitaminosis A or inactivity.

Studies made in our patient at the time of discharge from the hospital revealed no radiologic improvement in spite of her marked clinical improvement. It is known that in children there is reversibility of the bone findings although these lag far behind the disappearance of symptoms. It is too early to know whether a similar return to normal will occur in our case.

The mechanisms that are responsible for the bone changes in our patient are uncertain. Wolbach³⁶ found acceleration of epiphyseal cartilage cell growth and maturation of the remodeling processes involved in bone growth in the course of his animal experimentation with hypervitaminosis A. There was accelerated periosteal bone formation in some areas whereas in others there was accelerated resorption of bone with osteoclasts. He found no cause for these changes in the parathyroids, thyroids, adrenals or pituitaries of his animals and concluded that the changes were probably due to a local vitamin A effect. Fell and Mellanby³⁷ subsequently demonstrated by means of tissue culture that the changes in bone were a direct effect of vitamin A locally. In our case the high blood level of vitamin A would favor the transportation of larger amounts of vitamin A than would otherwise occur.

DERMATOLOGIC MANIFESTATIONS

Dermatologic reactions to excessive intake of vitamin A have been reported consistently in both the acute and chronic states. Polar explorers who ate bear liver had peeling of the skin as early as two days after the high vitamin A feast. Associated with other symptoms and signs of toxicity in animals were skin lesions which ranged from disheveled fur to alopecia, seborrhea, exfoliation, hemorrhagic dermatoses and dry, cracked mucous membranes.

In the chronic intoxication of humans, pruritus is an early and often severe symptom. Fissuring and soreness at the corners of the mouth may appear and disappear in spite of continued use of vitamin A. Coarsening of the skin and alopecia are reported by almost all observers. Loss of the fine lanugo hairs of the extremities is also occasionally noted. Pigmentation of localized areas of skin was noted first by Sulzberger and again by Bifulco. In our patient pigmentation of

some areas of skin was so marked that Addison's disease had been considered.

Our patient had suffered all of the skin manifestations cited during the prolonged course of her illness. Because disease of the skin was the initial reason for vitamin A therapy, the changes that took place during the course of toxicity were overlooked. Pruritus and thick, scaling, cracking palmar skin were the most distressing dermatologic manifestations of vitamin A toxicity.

The mechanisms responsible for the skin manifestations are far from clear. As to the pigmentation in our patient, we believe that it was probably secondary to the continued trauma of severe pruritus. The pigmentation was most marked over the abdomen and back where scratch marks were most evident during the early days of her last hospitalization. Biopsy of the skin of the abdomen showed hyperkeratosis and marked pigmentation.

Sulzberger considered hypovitaminosis A and hypothyroidism in the differential diagnosis because of the similarity of their dermatologic findings to those of hypervitaminosis A. That a definite antagonism exists between vitamin A and thyrotropic hormone has been established by animal experimentation.³⁸ In our patient two basal metabolic determinations made in the early days of her present hospital admission were recorded as plus 12 and plus 10. However, during this period the bone pains were so severe that one could question whether she was in a truly basal state. The protein-bound iodine was repeatedly lower than normal during the present hospital admission. The radio-active iodine uptake three weeks after discharge from the hospital was normal. Our case does not substantiate or deny the thyroid relationship found in experimental studies with vitamin A.

Two and a half weeks after withdrawal of vitamin A excess, pruritus had completely disappeared. In one month the texture of the skin had improved. In two and a half months, lanugo hairs reappeared, the eyebrows became heavier and the scalp hair was more profuse. Pigmentation was not altered.

HEMORRHAGIC MANIFESTATIONS

Hemorrhage is a prominent feature of vitamin A intoxication in animals and often leads to death even in the absence of trauma. The hemorrhages were shown by Light *et al.*³⁹ to be the result of hypoprothrombinemia and were controlled by the simultaneous administration

of vitamin K. No consistent hemorrhagic phenomena have been observed in children although sporadic instances of epistaxis were noted. The child reported by Josephs had a post-tonsillectomy hemorrhage. No abnormal bleeding was found in the adult patient reported by Sulzberger, while Bifulco's patient had a severe hemorrhage following dental extractions. These were empirically treated with vitamin K and the bleeding was controlled. There were no studies to ascertain the mechanism for these hemorrhages. In our patient there were no hemorrhagic manifestations. Her menstrual cycle was consistently normal, and she underwent dental extractions, bone biopsy and skin biopsy without excessive bleeding. Studies of prothrombin levels, prothrombin consumption, blood platelets, bleeding and coagulation time were all normal.

SUMMARY AND CONCLUSIONS

* A case of chronic hypervitaminosis A in a twenty-eight year old white female is described. Over a period of eight and a half years she was hospitalized ten times because of complaints referable to vitamin A intoxication. Many diagnoses had been made, including brain tumor, serous meningitis, chronic encephalitis, viral radiculoencephalitis, psychoneurosis and generalized infectious arthritis. Her bizarre clinical picture led to additional investigations to exclude Addison's disease, dermatomyositis and hepatitis. In an effort to provide symptomatic relief many measures had been undertaken. These included a subtemporal decompression for the relief of increased intracranial pressure, the application of body spicas, fever therapy, radiotherapy and physiotherapy. During this entire period our patient was allowed to continue the daily consumption of 500,000 units of vitamin A because of the supposed beneficial effects on "ichthyosis" of the skin.

When the clinical diagnosis of hypervitaminosis A was finally proposed, a fasting vitamin A blood level of 2,000 μg . per 100 cc., the highest ever recorded, was disclosed.

Daily estimations of the total vitamin A, including the free alcohol and ester fractions, were made over a period of two and a half months. The influence of menstruation, surgery, cortisone, starvation and alcohol consumption was noted. Stimulated by previous reports concerning the relationship of vitamin A to nephrolithiasis,

determinations of the blood levels and urinary excretion of calcium, phosphorus and citric acid were made. Blood analysis for phospholipid phosphorus, total fatty acids, and total lipids were carried out because of their role in vitamin A metabolism. Blood carotene levels were studied to emphasize their independence of the vitamin A levels attained by the ingestion of pure vitamin A.

The clinical manifestations of chronic vitamin A toxicity are reflected in the neurologic, skeletal and dermatologic systems. Persistent, severe headache with visual disturbances in the absence of focalizing neurologic signs may occur in hypervitaminosis A. This is the result of increased intracranial pressure due to excessive production or decreased absorption of cerebrospinal fluid. In our patient a subtemporal decompression had been performed elsewhere after a diagnosis of serous meningitis had been made.

Bone pains are usually present in chronic vitamin A intoxication. X-ray evidence of bone involvement has not been previously described in adults. In our case x-ray and bone biopsy studies indicate that the fundamental disturbance consists of calcification with or without true bone formation in the pericapsular, ligamentous, tendinous and subperiosteal tissues. The pain and the progressive crippling deformities in our patient had been previously considered the results of generalized infectious arthritis. The differences between Marie-Strümpell arthritis and vitamin A toxicity are discussed in detail.

The dermatologic manifestations of vitamin A toxicity include pruritus, fissuring and soreness at the corners of the mouth, coarsening of the hair with alopecia, loss of the fine lanugo hairs of the extremities and pigmentation.

Hemorrhagic manifestations during vitamin A toxicity have been considered by others to be of clinical significance. Our patient failed to show any hemorrhagic tendencies. Laboratory studies likewise showed no disturbance in any of the factors related to the clotting mechanism. Because of interest in the relationship of vitamin A to thyroid activity tests were made of the basal metabolism, protein-bound iodine and radioactive iodine uptake. These showed no consistent pattern of altered thyroid activity.

Clinical improvement in the neurologic, skeletal and skin manifestations took place rapidly upon stopping excess vitamin A intake.

744

This rapid response is a most important point in the differential diagnosis.

Treatment with massive doses of vitamin A now recommended in many clinical conditions must be reviewed from the standpoint of potential toxicity. If these large doses are to be used, rest periods should be instituted and determinations of the vitamin A blood level made. Self-medication with vitamin concentrates containing large doses of vitamin A is a common occurrence due to the general belief by the laity that vitamins improve health and increase resistance to infection.

Acknowledgment. The authors wish to thank Dr. Bernard S. Epstein, for assistance with the radiographic studies; Mr. Bruno Elkan, for technical assistance; and Miss Audrey Daniels, for clerical assistance. We are indebted to Drs. Charles Solomon and Alexander Davidson for their cooperation.

REFERENCES

- KANE, E. K. Arctic Explorations, vol. 1, p. 392. Philadelphia, 1857. Childs and Peterson.
- JACKSON, F. G. A Thousand Days in the Arctic. New York, 1899. Harper and Brothers.
- RODAHL, K. and MOORE, T. The vitamin A content and toxicity of bear and seal liver. *Biochem. J.*, 37: 166, 1943.
- VON DRIGALSKI, E. Über Schädigungen durch Vitamin A. *Klin. Wchnschr.*, 12: 308, 1933.
- COLLAZO, J. A. and SANCHEZ-RODRIGUEZ, J. Hypervitaminose A. *Klin. Wchnschr.*, 12: 1732, 1768, 1933.
- RUSSO, F. Experimental and clinical studies of hypervitaminosis A. *Fisiol. e Med.*, 10: 265, 1939.
- CLAUSEN, S. W. Pharmacology and therapeutics of vitamin A. *J. A. M. A.*, 111: 144, 1939.
- MOORE, T. and WANG, Y. L. Hypervitaminosis A. *Biochem. J.*, 39: 222, 1945.
- CZERNY, A. Beitrag zur Lebertherapie. *Therap. Gegenw.*, 80: 49, 1912.
- GETZ, H. R., HILDEBRAND, G. B. and FINN, M. Vitamin A deficiency in normal and tuberculous persons as indicated by the biophotometer. *J. A. M. A.*, 112: 1308, 1939.
- JOSEPHS, H. W. Hypervitaminosis A and carotinemias. *Am. J. Dis. Child.*, 67: 33, 1944.
- CAFFEY, J. Vitamin A poisoning. *Am. J. Roentgenol.*, 57: 818, 1952. Chronic poisoning due to excess of vitamin A: description of clinical and roentgen manifestations in 7 infants and young children. *Pediatrics*, 5: 672, 1950.
- SULZBERGER, M. B. and LAZAR, M. P. Hypervitaminosis A: report of a case in an adult. *J. A. M. A.*, 146: 788, 1951.
- BIPULCO, E. Vitamin A intoxication: report of a case in an adult. *New England J. Med.*, 248: 690, 1953.
- KNUDSON, A. G., JR. and ROTHMAN, P. E. Hypervitaminosis A. *Am. J. Dis. Child.*, 85: 316, 1953.
- MARIE, J. and SÉE, G. Hydrocéphalie aiguë bénigne du nourrisson après ingestion d'une dose massive, unique, de vitamines A et D. *Semaine hôp., Paris*, 27: 1744, 1951.
- Quoted by Knudson and Rothman.¹⁹
- GARCIA, I. M. C. Quoted by Knudson and Rothman.¹⁹
- LONIE, T. C. Excess vitamin A as a cause of food poisoning. *New Zealand M. J.*, 49: 680, 1950.
- TOOMEY, J. A. and MORISSETTE, R. A. Hypervitaminosis A. *Am. J. Dis. Child.*, 73: 473, 1947.
- GRIBETZ, D., SILVERMAN, S. and SOBEL, A. E. Vitamin A poisoning. *Pediatrics*, 7: 372, 1951.
- ARENA, J. M., SARAZEN, P. JR. and BAYLIN, C. J. Hypervitaminosis A. *Pediatrics*, 8: 788, 1951.
- SOBEL, A. E., ROSENBERG, A. and ADELSON, H. *In vivo* conversion of carotene to vitamin A in alloxan diabetes. *Arch. Biochem.*, 44: 176, 1953.
- ROSENBERG, A. and SOBEL, A. E. *In vitro* conversion of carotene to vitamin A. *Arch. Biochem.*, vol. 44, 1953.
- ROSENBERG, A. and SOBEL, A. E. *In vitro* conversion of carotene to vitamin A in alloxan diabetes. *Arch. Biochem.*, vol. 45, 1953.
- GLOVER, J., GOODWIN, T. W. and MORTON, R. A. Conversion of β -carotene into vitamin A in the intestine of the rat. *Biochem. J.*, 41: 45, 1947.
- MATTSON, F. H., MEHL, J. W. and DEUEL, H. J., JR. Studies on the carotenoid metabolism; the site of conversion of carotene to vitamin A in the rat. *Arch. Biochem.*, 15: 65, 1947.
- THOMPSON, S. Y., GANGULY, J. and KON, S. K. The conversion of β -carotene to vitamin A in the intestine. *Brit. J. Nutrition*, 3: 50, 1949.
- CHENG, A. L. S. and DEUEL, H. J., JR. Studies on carotenoid metabolism. *J. Nutrition*, 41: 619, 1950.
- THOMPSON, S. Y., BRANDE, R., COATES, M. E., CORVIES, A. T., GANGULY, J. and KON, S. K. Further studies of the conversion of β -carotene to vitamin A in the intestine. *Brit. J. Nutrition*, 4: 398, 1950.
- SEXTON, E. L., MEHL, J. W. and DEUEL, H. J., JR. Studies on carotenoid metabolism. vi. The relative provitamin A activity of carotene when introduced orally and parenterally in the rat. *J. Nutrition*, 31: 299, 1946.
- WIESE, C. E., MEHL, J. W. and DEUEL, H. J., JR. Studies on carotenoid metabolism. viii. The *in vitro* conversion of carotene to vitamin A in the intestine of a rat. *Arch. Biochem.*, 15: 75, 1947.
- BERNHARD, K., SCHEITLIN, E. and RITZEL, G. Transformation of α - and β -carotene into vitamin A in the rat intestine. *Helvet. chim. Acta*, 35: 1914-24, 1952.
- BIERI, J. G. and POLLARD, C. J. Efficient utilization of intravenous carotene by the rat. *Federation Proc.*, 12: 409, 1953.
- BICKNELL, F. and PRESCOTT, F. The Vitamins in Medicine. New York, 1947. Grune and Stratton.
- HEAD, G. D. and JOHNSON, R. A. Carotinemias: report of a case in an adult. *Arch. Int. Med.*, 28: 268, 1921.
- STONER, W. C. Carotinemias. *Am. J. M. Sc.*, 175: 31, 1928.

38. BRANDALEONE, H. and RALLI, E. P. Fasting blood carotene level in normal and diabetic individuals. *Proc. Soc. Exper. Biol. & Med.*, 32: 200, 1934.
39. RALLI, E. P., BRANDALEONE, H. and MANDELBAUM, T. The effect of administration of carotene and vitamin A in patients with diabetes mellitus. I. The effect of oral administration of carotene on the blood carotene and cholesterol of diabetic and normal individuals. *J. Lab. & Clin. Med.*, 20: 1266, 1935.
40. STUECK, G. H., FLAUM, G. and RALLI, E. P. The serum carotene in diabetic patients. *J. A. M. A.*, 109: 343, 1937.
41. BRAZER, J. G. and CURTIS, A. C. Vitamin A deficiency in diabetes mellitus. *Arch. Int. Med.*, 65: 90, 1940.
42. DORMER, B. A. and GIBSON, M. Vitamin A deficiency in tuberculosis and diabetes and the effect of various therapeutic preparations. *S. African J. M. Sc.*, 7: 109, 1942.
43. RALLI, E. P. and CLAPS, F. X. Studies on the plasma levels of vitamin A and carotene in diabetes mellitus and in cirrhosis of the liver. *New York Med.*, 5: 16, 1949.
44. POPPER, H., STEIGMANN, F., DUBIN, A., DYNIEWICZ, H. A. and HESSE, F. P. Significance of vitamin A alcohol and ester partitioning under normal and pathologic circumstances. *Proc. Soc. Exper. Biol. & Med.*, 68: 676-680, 1948.
45. CLOVER, J., GOODWIN, T. W. and MORTON, R. A. Studies in vitamin A chromatographic method for separating free and esterified vitamin A. *Biochem. J.*, 41: 94, 1947.
46. SOBEL, A. E. The problem of the absorption and transportation of fat-soluble vitamins. *Vitamins & Hormones*, 10: 47-67, 1952.
47. JOSEPHS, H. W. Factors influencing the level of vitamin A in blood of rats. *Bull. Johns Hopkins Hosp.*, 71: 253, 1942.
48. RODAHL, K. Hypervitaminosis A in the rat. *J. Nutrition*, 41: 399, 1950.
49. MOORE, T. and WANG, Y. L. Hypervitaminosis A. *Biochem. J.*, 39: 222, 1945.
50. LAURENCE, P. A. and SOBEL, A. E. Changes in the serum vitamin A during the human menstrual cycle. *J. Clin. Endocrinol. & Metab.*, in press.
51. CLARK, I. and GOLDBURN, R. W. Depletion of vitamin A in rat liver as a result of cortisone treatment. *Federation Proc.*, 12: 190, 1953.
52. SYMONDS, C. P. Hydrocephalic and focal cerebral symptoms in relation to thrombophlebitis of the dural sinuses and cerebral veins. *Brain*, 60: 531, 1937.
53. DAVIDOFF, L. M. and EPSTEIN, B. S. The Abnormal Pneumoencephalogram. Philadelphia, 1950. Lea & Febiger.
54. RINEBERG, I. E. and GROSS, R. J. Hypervitaminosis A with infantile cortical hyperostosis. *J. A. M. A.*, 146: 1222, 1951.
55. COMROE, B. I. Arthritis and Allied Conditions. Philadelphia, 1941. Lea & Febiger.
56. WOLBACH, S. B. Vitamin A deficiency and excess in relation to skeletal growth. *J. Bone & Joint Surg.*, 29: 171, 1947.
57. FELL, H. B. and MELLANBY, E. Effects of hypervitaminosis A on fetal mouse bones cultivated *in vitro*: preliminary communication. *Brit. M. J.*, 2: 535, 1950.
58. DRILL, V. A. Interrelations between thyroid function and vitamin metabolism. *Physiol. Rev.*, 23: 535, 1943.
59. LIGHT, R. F., ALSCHER, R. P. and FREY, C. N. Vitamin A toxicity and hypoprothrombinemia. *Science*, 100: 225, 1944.

LONG-TERM SAFETY AND EFFICACY OF ORAL ISOTRETINOIN IN LESS SEVERE ACNE

by A M Layton

Harrogate District Hospital, Harrogate, UK

Introduction

Acne vulgaris represents one of the commonest inflammatory dermatoses. Over the last decade clinical trials and research studies have helped to rationalise and define optimum systemic treatment regimes for acne. One such systemic therapy, oral isotretinoin, has been prescribed in the UK for over 10 years. Valuable information and data have been collected and analysed over this period and clear guidelines for the use of oral isotretinoin with respect to dosage, monitoring requirements and in particular long-term safety and efficacy, are now available.

Patient selection

When oral isotretinoin was first introduced, patient selection was determined by the clinical severity of the acne. Over the last few years, the indications for oral isotretinoin as treatment for acne have been expanded. Hence, further information on the efficacy and safety of oral isotretinoin in patients suffering with less severe acne is now available. Table 1 summarises the criteria for selection of patients with less severe acne who may be considered for treatment with oral isotretinoin.

Less severe	Severe
No or poor response to conventional antibiotics	Nodulocystic lesions
Relapse following conventional antibiotics	Extensive lesions over face, back, trunk, midriff
Scarring	Scarring
Seborrhoea	
Psychological	

Prescribing and efficacy

Once the patient has been selected for oral isotretinoin a dosage regime of 0.5-1.0mg/kg/day should be prescribed. The optimum dose with respect to relapse has been shown to be 1.0mg/kg/day over a 16 week period (1). However, side-effects may necessitate a reduction in the dosage. Patients with less severe acne may not tolerate side-effects with the same compliance as those with severe acne. If this is the case, a reduced dose of 0.5mg/kg/day will result in less severe side-effects, but this will mean prolonging the treatment period to provide a cumulative dose of 120mg/kg. An adequate cumulative threshold dose produces better long-term efficacy (1,2). Studies have

shown that the likelihood of relapse is related to several factors. These include the severity of the acne at the start of treatment (truncal acne relapsing more readily than facial acne), the degree of sebum suppression at the end of therapy (patients in whom sebosuppression is less than 80% of the pre-treatment level relapse more readily) and both the daily and cumulative dosages (1). Patients with less severe acne have an excellent prognosis provided that they receive an adequate dosage.

Side-effects

Adverse effects from oral isotretinoin are well recognised. Table 2 summarises the possible side-effects that might result from systemic therapy. The majority of these effects are dose-dependent with the exception of teratogenicity. Patients, regardless of acne severity, must be counselled by the prescribing physician regarding this possible side effect. All fertile females prescribed oral isotretinoin should be willing to use adequate contraception, and, if necessary, have a pregnancy test before starting isotretinoin and sign a consent form that stresses the need to avoid pregnancy whilst on treatment and for 4-6 weeks post therapy.

Table 2: Adverse effects of isotretinoin treatment.

Effects	Presentation
Mucocutaneous	Cheilitis Conjunctivitis Dry eyes Epistaxis Photosensitivity Pyogenic granuloma Skin fragility Sticky skin Xerosis
Musculoskeletal	Achilles tendinitis Hyperostosis Myalgia/arthritis
Gastrointestinal	Hepatotoxicity
Lipid metabolism	Hyperlipidaemia
Haematological	Neutropenia
Central nervous system	Benign intracranial hypertension
Teratogenic	Cardiovascular Craniofacial

Mucocutaneous

Mucocutaneous side-effects occur in all patients treated with isotretinoin. These symptoms are dose-dependent hence some patients with less severe acne may not tolerate these symptoms when prescribed 1mg/kg/day, and

complain that the side-effects are worse than the acne. Adjusting the dose of isotretinoin will improve the adverse effects and, providing the correct cumulative dose is received over the treatment period, the long-term efficacy in these patients is not altered.

Musculoskeletal

Up to 15% of patients receiving oral isotretinoin experience arthralgia and muscle stiffness (especially those participating in heavy exercise). This is reversible on discontinuing therapy and may be alleviated by reducing the dosage. Patients treated with low-dose oral isotretinoin over a prolonged period may have an increased prevalence of hyperostosis (3).

However, hyperostosis may also be seen in patients with acne who have not received retinoid (4). Hence, the true risk of developing bony problems is difficult to assess. It has been suggested that baseline x-rays should be obtained prior to prolonged retinoid usage, especially in patients over 35 years old.

Gastrointestinal and lipid metabolism

Minor elevations of liver function are said to occur in 10% of patients on oral isotretinoin (5). Hepatotoxicity is not necessarily dose-dependent but the condition is so rare with isotretinoin that any serious hepatic damage as a result of the drug is unlikely.

Shalita *et al* reported that up to 25% of patients on isotretinoin have elevated levels of serum triglyceride, which may or may not be associated with an increased total cholesterol, increased low-density lipoproteins and decreased high-density lipoproteins (6). This effect is dose-dependent and appears within 4–6 weeks with no apparent adverse effects in the short term. Pre-treatment screening has proved to be of little predictive value in identifying those at risk of developing hyperlipidaemia.

There is a theoretical risk of complications from the hyperlipidaemia (i.e. acute pancreatitis and eruptive xanthoma) with a triglyceride level of >10mmol/l. These levels are usually only seen in patients with pre-existing hyperlipidaemia who are receiving high dosing schedules of isotretinoin.

One retrospective study examining records of over 350 patients with moderate to severe acne treated and

monitored throughout their therapy period on isotretinoin suggested that it was not necessary to monitor liver function throughout the treatment period, but prudent to perform the analyses before initiation of therapy (7). In this study no patient developed hyperlipidaemia to a level to cause clinical concern. However, because of the theoretical risks most clinicians still check a fasting lipid profile at 4–8 weeks into the therapy period, particularly when administering the high-dosage regime.

Long-term safety

One study looking at the long-term safety aspects of oral isotretinoin has confirmed that isotretinoin used as a treatment for acne is a safe drug with no serious long-term side-effects (8). However, a small group (4.3%) of patients did complain of persistent mucocutaneous symptoms. These included xerosis, aided by emollients, eczema, treated by topical steroids and dry eyes, helped with false tears. The acne severity or dosage regime administered did not correlate with these long term effects suggesting that patients with less severe acne treated with isotretinoin are not necessarily exempt from these rare but possible adverse effects.

Summary

Oral isotretinoin has proved the test of time and represents an excellent treatment option for acne. Patients suffering with less severe acne who have not responded to conventional antibiotics and/or have a combination of seborrhoea, scarring and psychological problems should be considered for isotretinoin therapy. Long-term studies are reassuring and demonstrate that isotretinoin has an excellent safety and efficacy profile, irrespective of the severity of the complaint.

References

- 1 Layton A M *et al*, *Brit J Dermatol*, 1991, **129**(3), 292.
- 2 Lehuicher-Ceyrac D, Weber-Buisset M J and Puissant A, *Dermatol*, 1993, **186**, 123.
- 3 Tangrea J A *et al*, *Arch Dermatol*, 1992, **128**, 921.
- 4 Ellis B I *et al*, *Radiol* 1987, **162**, 541.
- 5 Roenigk H R, *J Am Acad Dermatol*, 1988, **19**, 199.
- 6 Shalita A R, Cunningham W J and Leyden J J, *J Am Acad Dermatol*, 1983, **9**, 629.
- 7 Barth J *et al*, *Brit J Dermatol*, 1993, **129**, 704.
- 8 Gouiden V, Klayton, A M and Cunliffe W, *Brit J Dermatol*.

**Treatment of Darier's Disease, Lamellar Ichthyosis,
Pityriasis Rubra Pilaris, Cystic Acne, and
Basal Cell Carcinoma with Oral 13-*cis*-Retinoic Acid**

G.L. PECK, F.W. YODER, T.G. OLSEN, M.D. PANDYA and D. BUTKUS

National Institutes of Health, Bethesda, Md.

81 patients with Darier's disease (DD), lamellar ichthyosis (LI), pityriasis rubra pilaris (PRP), and other keratinizing dermatoses, cystic acne, and basal cell carcinoma were treated with an oral synthetic retinoid Ro 4-3780 (13-*cis*-retinoic acid). The patients ranged in age from 4 to 82 years. The dosage varied from 0.5 to 7.4 mg/kg/day, and the duration of treatment varied from 1 to 55 weeks. The median dosage was 160 mg or 2 mg/kg daily for 19 weeks.

To date, a good to excellent response has been observed in 8 of 9 patients with LI, 3 of 3 with nonbullous congenital ichthyosiform erythroderma (which we distinguish from LI), 1 of 1 with ichthyosis vulgaris, 8 of 9 with DD, 3 of 5 with PRP, 2 of 6 with psoriasis, and 14 of 15 with cystic acne. Partial responses were observed in epidermolytic hyperkeratosis (4 patients), PRP (2), psoriasis (1), LI (1), DD (1), and keratosis palmaris et plantaris (1). 3 patients with psoriasis, 2 with X-linked ichthyosis and 1 with Netherton's syndrome worsened during therapy.

Of the 14 patients with cystic or conglobate acne who completed a 4-month course of therapy with 13-*cis*-retinoic acid, 10 had complete resolution (100%) of all cystic lesions, 2 had a response greater than 90%, 1 above 80%, and 1 above 70%. The 1 acne patient who did not respond was withdrawn from the study after 2 months due to the appearance of a large scrotal abscess which required antibiotic therapy. Thus far, the 14 responding acne patients have had a prolonged remission with the longest follow-up after discontinuation of therapy being 8 months.

2 patients with the basal cell nevus syndrome were treated with 13-*cis*-retinoic acid for 3 months. A marked inflammatory response developed in most tumors, especially those of the head and neck, and spared the intervening, apparently uninvolved skin. Biopsy of the inflammatory lesions

revealed a large number of plasma cells in the infiltrate. After the drug was discontinued and the inflammatory reaction subsided, an objective reduction in tumor mass was noted in those tumors in which an inflammatory reaction had occurred.

Approximately 10% of observed tumors showed complete clinical regression both clinically and histologically. These tumors were originally only 3–4 mm in diameter and were located on the head and neck.

Commonly observed side effects included cheilitis, conjunctivitis, facial dermatitis, xerosis, rhinitis sicca with nosebleed, and skin fragility. Unusual side effects were itching, headache, appetite changes, finger tip peeling, and inflammation of the urethral meatus. Rare side effects were hair thinning (4 patients), dryness of the mouth with a feeling of thirst (1) and a probable allergic reaction in 1 patient to the parabens contained in the capsule. Laboratory abnormalities were limited to an elevated erythrocyte sedimentation rate in 13 patients (an increase of greater than 20 mm/h over baseline), and a temporary, slight increase in SGPT in 3 patients, and SGOT in 1, and alkaline phosphatase in 2. Except for 1 patient who had an elevation of both SGOT and SGPT, the elevations of SGOT, SGPT, and alkaline phosphatase occurred independently.

The mechanism by which this synthetic retinoid alters these disease states is not known but may be related to the observed ability of vitamin A to affect glycoprotein synthesis and epithelial differentiation. Our results indicate that synthetic retinoids, such as 13-*cis*-retinoic acid, may represent a potent new class of drugs in the treatment of cutaneous disease. These diseases may also serve as useful screens in the further development of the synthetic retinoids, which could be beneficial in the prevention and treatment of epithelial neoplasia.

BENIGN INTRACRANIAL HYPERTENSION IN CHILDREN

Arthur Rose, M.D., C.I.B., D.C.H., and Donald D. Matson, M.D.

From the Departments of Neurology and Neurosurgery, Children's Hospital Medical Center and Harvard Medical School, Boston, Massachusetts

"BENIGN INTRACRANIAL HYPERTENSION" is used here to describe a clinical syndrome which consists of: (1) raised intracranial pressure, (2) normal cerebrospinal fluid findings, and (3) a midline ventricular system of normal or smaller than normal size as demonstrated by air contrast studies. The clinical picture is characterized by: (1) sudden onset of headache, (2) papilledema, (3) frequent sixth nerve paresis, and (4) absence of convulsions or focal neurological abnormalities. This condition differs from other forms of intracranial hypertension in that (1) the level of consciousness remains unimpaired despite intracranial pressure often high enough to lead to visual failure and (2) the prognosis for complete eventual recovery after an illness of variable duration is excellent.

The great variety of names which has been applied to this condition during the past 50 years reflects the changes of thought about its pathogenesis. In the early part of this century most cases would have been diagnosed as "serous meningitis," a diagnosis which was later superseded by that of "arachnoiditis." The latter term implied that adhesions in the posterior fossa lead to the development of internal hydrocephalus. Although arachnoiditis undoubtedly occurs as a late sequel of tuberculous meningitis and as an occasional late complication of purulent meningitis, it became clear with the advent of pneumoencephalography that arachnoiditis resulted in obstructive hydrocephalus with enlargement of the ventricular system and, therefore, did not conform to the criteria of benign intracranial hypertension as defined above.

In 1931, Symonds¹ described the now familiar syndrome of acute otitis media lead-

ing to lateral sinus thrombosis and coined the term "otitic hydrocephalus" for this etiologically distinct form of benign intracranial hypertension. McAlpine² noted the occasional occurrence of raised intracranial pressure following relatively trivial nasopharyngeal infections and suggested that the increased production of cerebrospinal fluid might represent a reaction to bacterial toxins; hence, he proposed the term "toxic hydrocephalus." During subsequent years the term "pseudo-tumor cerebri" gained popularity and remained in favor until Foley³ introduced the term "benign intracranial hypertension." This would appear to be the most appropriate name, since it succinctly states the essential clinical features of the syndrome without undue emphasis on any single etiological factor.

Benign intracranial hypertension is an uncommon condition in childhood. Davidoff's⁴ account of 81 cases, representing 20 years' experience with all age groups, included only 12 patients below the age of 12 years. Relatively little material on this subject has been published in pediatric literature and some of the cases reported have not conformed to the clinical picture described by Foley.³ Thus, Moore⁵ reported three cases in detail. His Case 1, however, showed features of obstructive hydrocephalus with dilatation of the ventricles due to posterior fossa adhesions, which were released surgically. Another of his patients developed epilepsy, which is an unusual sequel of benign intracranial hypertension. His third patient died 1 month after admission from an unstated cause. A group of cases more in keeping with the diagnostic criteria outlined here was reported by Maisel and Caplan.⁶ But, in their Case 1, raised intracranial pressure

(Received May 20; accepted for publication September 14, 1966.)

ADDRESS: (D.D.M.) Children's Hospital Medical Center, 300 Longwood Ave., Boston, Massachusetts 02115.

PEDIATRICS, Vol. 39, No. 2, February 1967

was not demonstrated and the clinical course resembled "acute cerebellar ataxia" occurring in association with epidemic parotitis. Dees and McKay⁷ were the first to draw attention to the occurrence of benign intracranial hypertension following reduction or withdrawal of corticosteroid drugs in children.

The purpose of this paper is to report our experience of benign intracranial hypertension due to diverse causes in a group of 23 children and to summarize the current knowledge of its etiology with particular reference to the pediatric age group.

MATERIAL

The significant clinical features of our cases are summarized in Table I. Twenty-one of the cases were seen at the Children's Hospital Medical Center, Boston, during the period 1953 to 1963. There were 14 males and 9 females. Their ages ranged from 6 months to 11½ years.

Etiology

Cases 1 to 8 (Table I) followed an infection other than otitis media, cases 9 to 12 were associated with middle ear infection, and cases 13 to 16 occurred in relation to an episode of trauma. In one case (Case 17) benign intracranial hypertension developed following abrupt withdrawal of steroid therapy of nephrotic syndrome. The remaining cases, 18 to 23, were classified as "idiopathic," as their etiology was entirely obscure.

In the post-infectious cases, neurological symptoms usually followed immediately after the initial illness; but, in three patients a symptom-free interval of up to 2 weeks was noted before signs or symptoms of increased intracranial pressure appeared.

Symptoms and Signs

The presenting symptoms were remarkably uniform and consisted of headache in 11 patients and strabismus or diplopia in 9. Vomiting was the main complaint in 7 patients, all of whom were below the age of 5 years. Papilledema was present in all patients except one 6-month-old infant who,

however, showed other signs of increased intracranial pressure. External rectus palsy was present bilaterally in one child and unilaterally in nine. None of the patients in this study showed any neurological signs of impaired cerebral or cerebellar function. Seizures were not recorded in any of these patients.

Cerebrospinal Fluid Findings

Cerebrospinal fluid pressure measured by lumbar puncture or ventricular puncture at the time of ventriculography was 300 to 700 mm of H₂O in 19 patients, and in 3 it was noted to have been "raised" without a recorded numerical value. In Case 15, pressure was recorded as only 120 mm of cerebrospinal fluid, despite the presence of definite bilateral papilledema, lateral rectus palsy, and marked separation of cranial sutures.

In Cases 4 and 6, who were first seen early in the course of their illnesses, the initial lumbar puncture pressure was 150 mm of water. Both patients were re-admitted with an exacerbation of symptoms 2 weeks later and ventricular fluid pressure was then found to be elevated to 550 mm. Cerebrospinal fluid protein was below 40 mg/100 ml in all patients, and there were no more than five white cells in any of the cerebrospinal fluids.

Electroencephalogram

Electroencephalographic examination was carried out in 16 patients. The major abnormality, present in seven patients, consisted of paroxysmal bursts of high voltage slow activity, especially in the anterior leads, of the type that is sometimes seen in children with obstructive hydrocephalus.⁸ Borderline abnormalities were present in six patients and three records were entirely normal.

X-ray Studies

Roentgenograms of the skull revealed separation of cranial sutures in seven patients and evidence of mastoiditis in two. Ventriculography was carried out as the di-

TABLE I
SUMMARY OF CLINICAL FEATURES IN 23 CASES OF BENIGN INTRACRANIAL HYPERTENSION IN CHILDHOOD

Case Number	Age (yr)	Sex	Prior History	Duration of symptoms (in days)	Symptoms on Admission			Physical Signs			Investigations						Treatment	Length of Follow-up (in years)		
					Headache	Stupor or Dementia	Vomiting	Pupils	Skull tenderness	Infection	Skull X-ray	R.F.G.	Pressure mm	CSF Protein mg/100 ml	CSF Cells	Chloride			Protein	Glucose
1	1	M	Gastroenteritis	10	+	+	+	++	+											
2	5	F	Tonsillitis	7	+	+	+	++	+											
3	9	M	Upper respiratory infection	7	+	+	+	++	+											
4	7	M	Pyrexia of unknown origin	5	+	+	+	++	+											
5	5	F	Streptococcal pharyngitis	10	+	+	+	++	+											
6	4	M	Fever, diarrhea, vomiting	14	+	+	+	++	+											
7	5½	M	Upper respiratory infection	14	+	+	+	++	+											
8	6	M	Chicken pox	6	+	+	+	++	+											
9	4	M	L. otitis media	1	+	+	+	++	+											
10	1	M	R. otitis media	21	+	+	+	++	+											
11	6	F	R. otitis media	2	+	+	+	++	+											
12	8	M	R. otitis media	14	+	+	+	++	+											
13	4½	F	Occipital skull fracture	14	+	+	+	++	+											
14	4½	M	Parieto-occipital head injury with loss of consciousness	1	+	+	+	++	+											
15	2	F	Head injury with brief loss of consciousness	21	+	+	+	++	+											
16	7½	F	Neck injury	8	+	+	+	++	+											
17	7	M	Absupt withdrawal of corticosteroid therapy	4	+	+	+	++	+											
18	10	F	None	42	+	+	+	++	+											
19	11½	M	None	? 12 mo	+	+	+	++	+											
20	2	M	None	2	+	+	+	++	+											
21	11	M	None	3	+	+	+	++	+											
22	7	F	None	5 mo	+	+	+	++	+											
23	6	F	None	5 mo	+	+	+	++	+											

* Ventricular fluid pressure.
 † CSF pressure recorded as "increased." F—female, M—male, +—present, N—normal, A—abnormal, D—distasis of cranial sutures, E—expectant, L—daily lumbar punctures, C—corticosteroid treatment, S—surgical decompression, U—unsatisfactory.

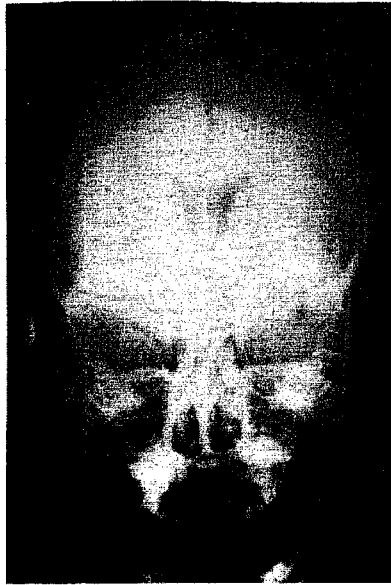


FIG. 1. C.R., 4½-year-old male, developed persistent increased intracranial pressure with papilledema and sixth nerve palsy following minor trauma. Initial lumbar puncture pressure of 480 mm water. Anteroposterior lumbar pneumoencephalogram illustrates the normal size and placement of the ventricular system. Normal recovery followed repeat lumbar punctures.

agnostic procedure of choice in 20 patients. In two, the ventricles could not be entered, presumably owing to their small size; in four, the visualization of the ventricular system was incomplete. In these patients, lumbar pneumoencephalography was subsequently carried out. None of these air studies showed any abnormality, (Fig. 1-4). Air studies were omitted in Case 17, in which the intracranial hypertension was attributed to a sudden withdrawal of steroid therapy.

Treatment

Eight patients were treated with serial spinal punctures, three were treated with corticosteroids, and, in seven, treatment was limited to fluid restriction and administration of diuretics. Suboccipital de-

compression with posterior fossa exploration, sub-occipital decompression alone, and sub-temporal decompression were each performed in one patient.

Course and Duration of Illness

In eight patients when lumbar punctures were repeated after air contrast studies, the cerebrospinal fluid pressure was found to be normal and no further treatment was necessary. In most other patients the total length of hospital stay did not exceed 2 to 3 weeks. Diplopia and strabismus resolved in all patients during a few weeks. There were no recurrences, except in Case 15; she relapsed 2 months after initial improvement following repeated lumbar punctures. She was treated with further lumbar punctures and cortisone and made a rapid recovery.

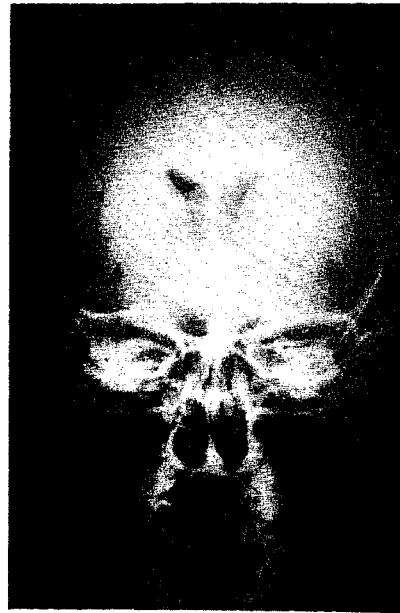

FIG. 2. N.H., 7½-year-old female, developed headache, vomiting, and diplopia 2 weeks after an ear infection. There was papilledema, sixth nerve palsy, and elevated CSF pressure. Anteroposterior ventriculogram illustrates the normal size and placement of the ventricular system. Complete recovery followed subsequent lumbar punctures.

Follow-up Results

Patients were followed for periods ranging from 6 months to 11 years (Table I). Intellectual development proceeded normally in all patients who were followed sufficiently long for this to be assessed. None of the patients developed seizures or focal neurological deficits. Optic disc appearances returned to normal within 3 to 6 months, except in two patients who showed persistent residual optic disc pallor. None of the patients suffered significant permanent impairment of visual acuity. In two patients (Cases 18 and 19) recovery from the initial illness was followed by severe emotional disturbances which required long-term psychiatric treatment.

COMMENT

It will be seen from Table I that in the largest group of patients benign intracranial hypertension followed bacterial or viral infection such as gastroenteritis, streptococcal pharyngitis, upper respiratory tract infection, and chickenpox. A symptom-free period of 1 week (Case 6) to two weeks (Cases 5 and 8) intervened between the initial infective episode and the development

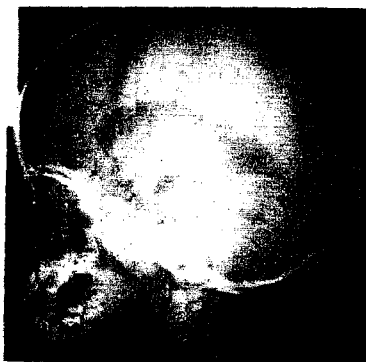

FIG. 3. B.H., 13-month-old male, had irritability and strabismus of unknown origin but no other neurological abnormalities except papilledema. There was an episode of "intestinal flu" 10 days previously. Lateral ventriculogram shows separation of cranial sutures but normal ventricles. There was complete recovery with follow-up over 5 years.

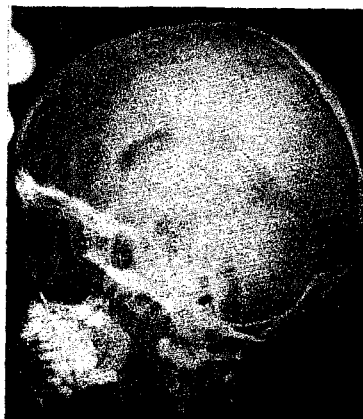

FIG. 4. D.S., 6-year-old male, developed headaches, stiff neck, diplopia, and vomiting 2 weeks after chickenpox. Papilledema was present. Lateral ventriculogram shows the normal size and placement of the ventricular system. There was complete recovery with a normal examination 2 years later.

of increased intracranial pressure. In Case 8 the absence of impairment of consciousness, lack of spinal fluid pleocytosis, and the presence of papilledema were the evidence against the diagnosis of varicella encephalitis.¹⁰ The occurrence of benign intracranial hypertension following nasopharyngeal infections has been reported by other authors.^{1,10} As early as 1937, McAlpine² proposed the "toxic hydrocephalus" theory. Symonds¹ suggested that nasopharyngeal infections may in these cases be associated with thrombosis of veins in the pterygoid plexus with retrograde propagation of the thrombus into the jugular vein. It is of interest that mastoiditis associated with lateral sinus thrombosis, which has been the most frequent cause of benign intracranial hypertension in the past, has become relatively infrequent in the era of antibiotics. This syndrome is represented by only four patients in our series. The clinical features of lateral sinus thrombosis in a group of 11 children were recently discussed by Greer¹¹ and, although the ventricular system was visualized in only three of his patients, at surgery the lateral sinus in each case was

observed to be compressed by necrotic material. We are of the opinion that when signs of increased intracranial pressure are present with middle ear infection, it is always advisable to carry out neuroradiological contrast studies in order to rule out the possibility of a cerebral abscess.

In Case 12, symptoms developed following an occipital skull fracture from which damage to the confluence of the sinuses and secondary superior sagittal sinus thrombosis probably resulted. An almost identical clinical picture was described in a 6-year-old child by Bradshaw¹⁰ in his Case 13, and similar cases were reported by Martin¹² and Beller.¹³ From the study of these cases it appears that the initial head injury may be minimal and that there may or may not be associated loss of consciousness. Approximately half of the reported patients had sustained skull fractures, but not always in relation to one of the dural venous sinuses. Our Cases 13 and 14 developed symptoms following relatively trivial closed head injuries and the clinical picture differed from the usual form of post-traumatic cerebral edema in the absence of confusion or any impairment of consciousness despite markedly elevated intracranial pressure. A similar course of events was observed by Foley,³ Davidoff,¹ and Moore,⁵ and it seems probable that even a closed head injury may result in damage to tributary veins, predisposing to sinus thrombosis. Although in Moore's⁵ patient sagittal sinus venography was performed and no abnormalities were noted, it is possible that even minor degrees of mural thrombosis may be sufficient enough to interfere with the re-absorption of cerebrospinal fluid but not extensive enough to be demonstrated radiologically.

One patient (Case 17), was of interest because he probably belongs to the growing list of children who have developed benign intracranial hypertension after sudden cessation of corticosteroid therapy. Nephrotic syndrome developed in 1961 and during the subsequent 2 years he received two short courses of intramuscular ACTH therapy.

Following a relapse in June 1963, 50 mg prednisone combined with chlorothiazide and spironolactone was administered three times per week. Four weeks later gastroenteritis developed while he was at a summer camp and the treatment was abruptly stopped. A few days later the gastrointestinal symptoms disappeared but he complained of headache and was found to have marked papilledema without any other neurological signs. Laboratory investigations revealed leucocytosis of 20,000 with marked shift to the left, biochemical abnormalities consistent with the diagnosis of nephrotic syndrome, and diagnostic lumbar puncture showed pressure of 340 mm of water. He was treated with 8 mg dexamethasone per day and, he improved rapidly following a good diuresis on the fifth day of treatment. When he was seen again 4 months later his optic fundi had returned to normal appearance.

In addition to cases following an infection or trauma there were six patients (Cases 18 to 23) in whom no apparent clinical association was evident. The average age of patients in this group was higher than in the other patients and the development of symptoms tended to be more insidious; thus, the symptoms resembled the adult form of benign intracranial hypertension. In connection with these "idiopathic" cases it is necessary to consider a few non-neurological conditions which occasionally present with a clinical picture of raised intracranial pressure. Recently one of us saw a child at the Hospital for Sick Children, London, (through the courtesy of Dr. John Wilson) who presented with severe papilledema and was subsequently shown to be suffering from hypoparathyroidism. This association is well described in endocrinological literature and accounts of chronic hypoparathyroidism with papilledema occurring in childhood have been published by Sutphin, Albright, and McCune¹⁴ and Albrecht.¹⁵ Even more infrequently, papilledema may be associated with acute hypoparathyroidism following thyroidectomy and Palmer, Seares, and Boldrey¹⁶ report

ed this condition in a child. Walsh,¹⁷ Boudin, Fimck-Bretano, and Gayno,¹⁸ and Jefferson¹⁹ have described cases of Addison's disease presenting with papilledema and headaches. This is important not only because the neurological symptoms improve with specific therapy but also because these patients have poor tolerance for diagnostic air contrast studies.

Marie and See²⁰ were the first to draw attention to the syndrome of acute intracranial hypertension associated with vitamin A overdosage in small infants. They were able to reproduce the clinical picture of a bulging anterior fontanelle and increased cerebrospinal fluid pressure in healthy babies 1 to 5 months old at 12 to 24 hours after the ingestion of 350,000 u of vitamin A.

Recently several authors have drawn attention to the occurrence of acute intracranial hypertension coinciding with the administration of tetracycline^{21,22} and chlortetracycline²³ to young infants. In this condition bulging anterior fontanelle and abnormal irritability were usually noticed during the first day or two of treatment. A single lumbar puncture and withdrawal of the drug were followed by rapid recovery. Finally, it should be added that bilateral retrobulbar neuritis in a child not cooperative enough to allow the testing of central vision to be carried out may be thought to be indicative of benign intracranial pressure, but normal cerebrospinal fluid pressure measurement would rule out this possibility.

The clinical picture in most of the children in our series was remarkably uniform. Frequently, the chief initial complaint was headache of fairly abrupt onset; initial vomiting was more frequent in younger children. Often the presenting complaint of strabismus led to ophthalmoscopic examination and discovery of papilledema. In a child presenting with bilateral papilledema and without lateralizing neurological signs, it is imperative to exclude the possibility of a midline obstructive lesion, such as aqueduct stenosis, tumor of cyst of third or

fourth ventricles or, less commonly, a cerebral hemisphere mass lesion. Tumor of the third ventricle is of particular importance in the differential diagnosis and no treatment should be undertaken until satisfactory radiological contrast studies of that area and of the fourth ventricle have been completed. If no displacement of the ventricular system from the midline is found, the ventricles are of normal or smaller than normal size, and no abnormalities are found in the cerebrospinal fluid, except for increased pressure, the diagnosis of benign intracranial hypertension may be made. Although the absence of ventricular dilatation is one of the diagnostic criteria recommended by Foley³ and most other authors, Bradshaw¹⁰ mentioned nine patients in whom air studies were performed after an average period of 5 weeks following the onset of symptoms. Some dilatation of the ventricles was demonstrated but benign intracranial hypertension was diagnosed, nevertheless.

The discovery of cerebrospinal fluid pleocytosis or of raised cerebrospinal fluid protein content in the presence of normal x-ray studies introduces various other diagnostic possibilities, such as cortical vein thrombosis, subacute bacterial or fungal meningitis, and chronic lead poisoning. In our view, diagnosis of benign intracranial hypertension should be made with extreme caution in the presence of any abnormal cerebrospinal fluid cellular reaction. It should be mentioned, however, that Foley³ and Bradshaw¹⁰ were prepared to accept a significant degree of cerebrospinal fluid pleocytosis in some of their patients.

The objects of treatment are: (1) to reduce intracranial pressure sufficiently to minimize the risk of optic nerve swelling being followed by secondary optic atrophy and (2) to maintain the patient as comfortably as possible. Traditional treatment consists of lowering the cerebrospinal fluid pressure by daily lumbar punctures and withdrawal of enough fluid to reduce the pressure slowly to half the opening value. Bradshaw¹⁰ criticized this therapy, stating

that in his experience the removal of 10 to 15 cc of cerebrospinal fluid failed to effect a sustained fall of pressure. The volume of cerebrospinal fluid produced per 24 hours is so large that it would be surprising if the withdrawal of only 10 to 15 cc produced more than a transient lowering of CSF pressure in the presence of abnormal absorption. We have employed the removal of larger volumes of cerebrospinal fluid and have performed spinal punctures twice a day, or more often if necessary. This may account for the difference between Bradshaw's¹⁰ experience and our own. Salt and fluid restriction and ammonium chloride and acetazolamide (Diamox) administration have been used for treatment of milder cases, but the effectiveness of these measures is not well documented and their value appears to be questionable. In children, the total course of symptoms tends to be briefer than in benign intracranial hypertension in adults. This, combined with the patency of cranial sutures in many younger children, renders the need for surgical intervention less frequent than in older patients. Thus, surgical decompression had to be carried out in only three of our patients. In contrast, in Davidoff's⁴ adult patients sub-temporal decompression was carried out in 51 of 61 cases. Sub-occipital rather than sub-temporal decompression has the obvious advantage of allowing inspection of the posterior fossa to be made at the time of operation.

Paterson, De Pasquale, and Mann²¹ reported details of their experience with corticosteroid therapy in six patients with benign intracranial hypertension. In one patient there was no response and in two patients the effect was difficult to evaluate; but, in at least three patients the improvement was definite and dramatic. Our own experience of corticosteroid treatment in this condition is too limited for significant comment, although its introduction undoubtedly coincided with marked subjective and objective improvement in Case 16 and in a dramatic recovery in Case 17.

Anticoagulant treatment has been used in

cases of proven sagittal sinus thrombosis by Ray and Dunbar;²⁵ but it did not prevent the reformation of a surgically evacuated thrombus in their Case 1. Nevertheless, there is probably a place for anticoagulant therapy in the rare instances of retrograde spread of thrombosis from the sagittal sinus into the cortical tributary veins, provided that hemorrhagic infarction is excluded by the demonstration of clear cerebrospinal fluid.²⁶

DISCUSSION

There can be little doubt that benign intracranial hypertension constitutes a symptom complex which may be caused by diverse etiological processes, of which only a few are understood at present. The lack of pathological material, the reluctance "to over-investigate" patients suffering from a condition with ultimately good prognosis, and the deficiencies in our knowledge of cerebrospinal fluid physiology are responsible for the fact that the pathogenesis of the clinical syndrome has been clarified in only a few instances. Moreover, even in cases where the etiology is known, as for example in lateral sinus thrombosis, the precise mechanism of intracranial pressure elevation still remains obscure.

Foley² postulated three possible ways in which the intracranial pressure may be raised without co-incident dilatation of the ventricular system: (1) by obstruction of venous drainage leading to venous congestion, (2) by edema of cerebral tissues, and (3) by active dilatation of the arterial tree. The studies of the variation in the anatomical arrangement of major venous sinuses by Woodhall²⁷ have shown why benign intracranial hypertension occurs in only some cases of lateral sinus thrombosis. The superior sagittal sinus most frequently drains into the right lateral sinus, and the straight sinus drains most frequently into the left lateral sinus. Usually a communication between the two systems is present at the torcular so that complete venous obstruction cannot develop unless: (1) thrombosis involves the confluence of the sinuses, (2)

there is an anatomical variation such as absence of communication between the two lateral sinuses at the torcular, or (3) there is complete absence of one lateral sinus.

Ray and Dunbar²² demonstrated superior sagittal sinus obstruction in several cases of benign intracranial hypertension unaccompanied by local infection. Occlusion of the jugular vein, whether due to extension of thrombosis from the pterygoid plexus or external compression by scar tissue, thrombosis around an in-lying ventriculocaval shunt tube, or trauma to the neck (as in our Case 16) results in the typical picture of benign intracranial hypertension if the thrombus was propagated to the torcular. It would seem that cerebral angiography with serial films continued late into the venous phase to visualize the major sinuses and jugular veins might be an informative additional investigation in patients with suspected benign intracranial hypertension.

It is of interest to recall that before the introduction of intravenous fluid therapy, dural sinus thrombosis was a frequent complication of acute dehydration in infants under 1 year of age. The clinical picture was complicated by the co-existing electrolytic disturbance. The degree of neurological involvement was usually severe with signs of increased intracranial pressure often accompanied by dilatation of scalp veins, soft tissue edema, convulsions, and frequently blood stained cerebrospinal fluid. The pathological findings were characterized by extensive areas of hemorrhagic infarction of cortical and sub-cortical structures.²³

It has been emphasized by several writers^{3,4,20} that in cases of benign intracranial hypertension the arachnoid membrane is under great tension when observed at the time of surgical decompression and the volume of cerebrospinal fluid in the sub-arachnoid spaces is greatly increased. Because of this it has been postulated that even partial dural sinus thrombosis could interfere with effective absorption of cerebrospinal fluid through arachnoid villi, but this explanation is difficult to accept in the

absence of ventricular dilatation, particularly in cases of long standing.

Cerebral edema, the second mechanism postulated by Foley,³ appears to be a possible cause of raised intracranial pressure in patients in whom venous thrombosis could not be demonstrated. The effect of high-dose steroid therapy on cerebral edema, associated with malignant cerebral gliomas and cerebral metastases, or on traumatic edema, is well-known.²⁴ The effectiveness of corticosteroids reported in some cases of benign intracranial hypertension supports the theory that generalized cerebral edema may be responsible for some cases of this syndrome. Further evidence for this possibility can be found in the work of Sahs and Joynt²⁰ who have demonstrated intracellular and extracellular edema in brain biopsies obtained at the time of surgical decompression in 10 of their patients. However, the striking preservation of consciousness in benign intracranial hypertension suggests that cerebral edema in this condition must be of a different variety from that which accompanies cerebral infarction, trauma, tumor or cerebral anoxia.

Although hypoadrenalism in childhood is very rare, the occasional cases of Addison's disease presenting with the clinical picture of headaches and papilledema are of interest in relation to the increasing number of cases of benign intracranial hypertension occurring in children receiving long-term steroid therapy. Dees⁷ postulated adrenal hypofunction in three children who had had prolonged corticosteroid treatment for asthma and developed signs of raised intracranial pressure following reduction of dosage; evidence of adrenal hypofunction was presented in Case 2 in which the excretion of adrenal steroids was stated to be "low" and a prolonged period of stimulation with ACTH was required before a significant rise in 17-hydroxysteroids and 17-ketosteroids occurred. Greer³¹ added five more cases of benign intracranial hypertension associated with triamcinalone therapy in children. Urinary 17-ketosteroid and 17-hydroxycorticosteroid outputs were estimated in two of

Greer's patients and were found to be normal; an ACTH stimulation test, which was carried out in one patient, was also normal. When Walker and Adamkiewicz²² reported four cases of benign intracranial hypertension after withdrawal of corticosteroid therapy in children in 1964, they reviewed the world literature and found 24 published cases. In most instances the onset of symptoms followed either cessation of therapy or reduction of dosage, sometimes even when the reduction of dosage was accomplished gradually. In most cases, neurological symptoms either subsided spontaneously or corticosteroids had to be re-introduced. Other patients were treated with lumbar punctures and one patient was even subjected to subtemporal decompression.

The probable endocrinological basis for benign intracranial hypertension occurring in some adults is strongly suggested by the well-known association of this syndrome with the first trimester of pregnancy, with disorders of the menstrual cycle, and with gross obesity. Attention was first drawn by Foley³ to the frequent occurrence of benign intracranial hypertension in obese prepubertal females, and Greer²³ recently reviewed 10 girls with this condition aged 11 to 14 years. He suggested that since the clinical syndrome in these patients, and in the cases occurring in early pregnancy, appears at a time of rapid rise of estrogen level it might result in suppression of the adrenals and cause relative adrenal hypofunction. No direct evidence was offered, however, in support of this speculation.

SUMMARY

The clinical features of 23 cases of benign intracranial hypertension occurring in childhood have been reviewed. Eight cases followed minor bacterial or viral infections, four cases occurred in association with head or neck injury, four cases occurred with otitis media, and one case followed sudden cessation of corticosteroid treatment. There were no apparent associated clinical factors in the remaining six cases. Benign intracranial hypertension thus emerges as a clin-

ical syndrome of varied etiology, generally with a short course, good prognosis, little tendency to recurrence, and only rarely requiring surgical intervention. Clinical evidence suggests that, in addition to otitis media, cerebral venous thrombosis may, in certain circumstances, follow head injury, trauma to the jugular vein, and thrombosis in the pterygoid venous plexus. Therefore, it is suggested that complete visualization of the venous cerebral circulation should be attempted in the investigation of patients with benign intracranial hypertension.

In view of the occurrence of the syndrome following gastroenteritis, upper respiratory tract infections, and chickenpox, diagnostic virological studies, including culture of cerebrospinal fluid, are of special interest. Other precipitating causes of this clinical syndrome are discussed. The occurrence of benign intracranial hypertension as an initial manifestation of two well defined endocrine abnormalities is described. It is possible in the future that systematic endocrine study of patients, particularly prepubertal females, will reveal other hormonal defects.

It appears probable that transient generalized cerebral edema of any type may be responsible for the occurrence of this syndrome. The elucidation of its pathophysiology will probably have to wait more accurate and safe methods of clinical measurement of intra- and extra-cellular fluid shifts within the brain, as well as more reliable understanding of cerebrospinal fluid and cerebral blood flow alterations.

REFERENCES

1. Symonds, C. P.: Otitic hydrocephalus. *Brain*, 54:55, 1931.
2. McAlpine, D.: Toxic hydrocephalus. *Brain*, 60:180, 1937.
3. Foley, J.: Benign forms of intracranial hypertension — "toxic" and "otitic hydrocephalus." *Brain*, 78:1, 1955.
4. Davidoff, L. M.: Pseudotumor cerebri; benign intracranial hypertension. *Neurology*, 6:605, 1956.
5. Moore, R. B.: Pseudotumor cerebri. *ΠΕΡΙΛΗΨΙΣ*, 19:266, 1957.
6. Maisel, J. E., and Caplan, J.: Pseudotumor

- cerebri, benign intracranial hypertension. *J. Pediat.*, 52:441, 1958.
7. Dees, S. C., and McKay, H. W., Jr.: Occurrence of pseudotumor cerebri (benign intracranial hypertension) during treatment of children with asthma by adrenal steroids. *ΡΕΔΙΑΤΡΙΚΣ*, 23:1143, 1959.
 8. Lombroso, C. T.: Personal communication, 1963.
 9. Miller, H. C., Stanton, J. B., and Gibbons, J. L.: Para-infectious ocephalomyelitis and related syndromes. *Quart. J. Med., New Series*, 25:427, 1956.
 10. Bradshaw, P.: Benign intracranial hypertension. *J. Neurol. Neurosurg. Psych.*, 19:28, 1956.
 11. Greer, M.: Benign intracranial hypertension, I. Mastoiditis and lateral sinus obstruction. *Neurology*, 12:472, 1962.
 12. Martin, J. P.: Signs of obstruction of superior longitudinal sinus following closed head injuries (traumatic hydrocephalus). *Brit. Med. J.*, 2:467, 1955.
 13. Boller, A. J.: Benign post-traumatic intracranial hypertension. *J. Neurol. Neurosurg. Psych.*, 27:149, 1964.
 14. Sutphin, A., Albright, F., and McCune, D. J.: Five cases (three in siblings) of idiopathic hypoparathyroidism associated with moniliasis. *J. Clin. Endocr.*, 3:625, 1943.
 15. Albrecht, K.: Stauungspapille bei tetanie. *Msehr. Psychiat. Neurol.*, 55:55, 1923.
 16. Palmer, R. F., Searles, H. H., and Boldrey, E. B.: Papilledema and hypoparathyroidism simulating brain tumor. *J. Neurosurg.*, 16:378, 1959.
 17. Walsh, B.: Papilledema associated with increased intracranial pressure in Addison's disease. *Arch. Ophth.*, 47:86, 1952.
 18. Boudin, G., Funck-Brentano, J. L., and Cayno, M.: Maladie d'Addison par aplasie surrénale et syndrome para-biermérien. *Bull. Soc. Med. Hôp. Paris*, 66:1736, 1950.
 19. Jefferson, A.: Clinical correlation between encephalopathy and papilledema in Addison's disease. *J. Neurol. Neurosurg. Psych.*, 19:21, 1956.
 20. Marie, J., and See, G.: Acute hypervitaminosis A of infant; its clinical manifestations with benign acute hydrocephalus and pronounced bulge of fontanel; clinical and biologic study. *Amer. J. Dis. Child.*, 87:731, 1954.
 21. Fields, J. P.: Bulging fontanel: a complication of tetracycline therapy in infants. *J. Pediat.*, 58:74, 1961.
 22. O'Doherty, N. J.: Acute benign intracranial hypertension in an infant receiving tetracycline. *Develop. Med. Child Neurol.*, 7:677, 1965.
 23. Gellis, S. S.: *Yearbook of Pediatrics, 1956-57*. Chicago: The Yearbook Publishers, p. 40, 1956.
 24. Paterson, R., De Pasquale, N., and Mann, S.: Pseudotumor cerebri. *Medicine*, 40:85, 1961.
 25. Ray, B. S., and Dunbar, H. S.: Thrombosis of dural venous sinuses as cause of "pseudotumor cerebri." *Ann. Surg.*, 134:376, 1951.
 26. Fishman, R. A., Cowen, D., and Silberman, M.: Intracranial venous thrombosis during the first trimester of pregnancy. *Neurology*, 7:217, 1957.
 27. Woodhall, B.: Variations of cranial venous sinuses in region of torcular herophili. *Arch. Surg.*, 33:297, 1936.
 28. Byers, R. K., and Hass, G. M.: Thrombosis of dural venous sinuses in infancy and in childhood. *Amer. J. Dis. Child.*, 45:1161, 1933.
 29. Galicich, J. H., French, L. A., and Melby, J. C.: Use of dexamethasone in treatment of cerebral edema associated with brain tumours. *J. Lancet*, 81:46, 1961.
 30. Sahs, A. L., and Joynt, R. J.: Brain swelling of unknown cause. *Neurology*, 6:791, 1956.
 31. Greer, M.: Benign intracranial hypertension. II. Following corticosteroid therapy. *Neurology*, 13:439, 1963.
 32. Walker, A. E., and Adamkiewicz, J. J.: Pseudotumor cerebri associated with prolonged corticosteroid therapy. *J.A.M.A.*, 188:779, 1964.
 33. Greer, M.: Benign intracranial hypertension. IV. Menarche. *Neurology*, 14:569, 1964.

SUPPORTED BY AN UNRESTRICTED EDUCATIONAL GRANT FROM
ORTHO DERMATOLOGICAL

Pharmacokinetics of oral isotretinoin

Ulf-W. Wiegand, PhD, and Ruby C. Chou, PhD Basel, Switzerland

ISOTRETINOIN: A PHYSIOLOGIC RETINOID

Oral isotretinoin (13-*cis* retinoic acid Accutane; Hoffmann-La Roche, Nutley, N.J.) revolutionized the treatment of acne when it was introduced in 1982. A decade and a half later, it remains the most effective antiacne drug, because it alone acts against all the major etiologic factors. In the last 10 years, important progress has been made not only in therapy with oral isotretinoin but also in our knowledge of its mechanism of action at the molecular level. The discovery that isotretinoin is a naturally occurring molecule in humans, found in every patient with acne and in women during pregnancy,¹ has major safety implications.

Isotretinoin is a metabolic product of the dietary vitamin A and provitamin A carotenoids (Fig. 1), found primarily in liver, milk, cheese, and leafy green vegetables.^{2,3} Retinol (vitamin A) is absorbed from the gastrointestinal tract and metabolized in the liver into retinal. Retinal is irreversibly oxidized into retinoic acids, which reversibly interconvert into each other. The two isomers (retinoic acid and 13-*cis*-retinoic acid) have an identical chemical structure but differ in molecular geometry. A direct consequence is the difference in elimination half-lives: approximately 20 hours for isotretinoin^{1,4,5} versus only 0.9 hours for retinoic acid.⁶

Isotretinoin and retinoic acid are further metabolized into oxo-isotretinoin and oxo-retinoic acid, respectively (Fig. 1). Interconversion again takes place between both metabolites, with half-life differences similar to those of the parent compounds but with less dramatic consequences, because of their much lower pharmacologic activity.

Isotretinoin was only confirmed as an endogenous retinoid by the development of an assay sen-

sitive enough to detect and quantify endogenous, physiologic plasma concentrations of isotretinoin and its metabolites in patients.⁷

It is important to note that the elimination kinetics of retinoic acid are not the same when retinoic acid is administered directly compared with being formed as a metabolite of isotretinoin. In the latter case, elimination does not depend on its own pharmacokinetic properties but on its rate of formation from isotretinoin. This is termed *formation-rate limited elimination*.⁸ As a metabolite of isotretinoin, retinoic acid therefore declines in the body of a patient with acne at a rate similar to that of isotretinoin, not at its own, much faster elimination rate.

MAJOR PHARMACOKINETIC PARAMETERS

As with other retinoids, the lipophilicity of isotretinoin causes variable absorption when administered without food. With food, bioavailability (measured as mean maximum plasma concentrations and area under the plasma concentration-time curve) is considerably increased, and variability is decreased.^{4,5} Typical blood concentration-time curves after single and multiple oral doses from an early study show peaks of approximately 300 ng/mL 2 to 3 hours after an 80-mg oral dose, then becoming rapidly undetectable (Fig. 2, A). Thus terminal elimination half-lives are difficult to estimate after a single dose. Fig. 2, B, shows predose blood concentrations of 100 to 200 ng/mL and 600 to 800 ng/mL for isotretinoin and oxo-isotretinoin, respectively, during treatment for 30 days. The graph demonstrates that isotretinoin and oxo-isotretinoin reach steady-state concentrations within 10 days at doses of 40 mg twice a day. Concentrations of oxo-isotretinoin at steady state are approximately 4 to 5 times higher than those of isotretinoin. After the end of treatment (Fig. 2, C), concentrations of isotretinoin and oxo-isotretinoin decline with mean terminal elimination half-lives that are approximately 19 hours and 29 hours, respectively. Isotretinoin and its metabolites are excreted to similar extents in urine and feces.^{4,5}

From F. Hoffmann-La Roche Ltd., Departments of Clinical Pharmacology and Pharmacokinetics.

Reprint requests: Ulf-W. Wiegand, PhD, F. Hoffmann-La Roche Ltd., Departments of Clinical Pharmacology and Pharmacokinetics, Grenzacher Str. 124, CH-4070 Basel, Switzerland.

(J Am Acad Dermatol 1998;39:58-12.)

Copyright © 1998 by the American Academy of Dermatology, Inc. 0190-9622/98/39:00 + 0 16/0/91343

Table II. Adverse events frequently reported during acitretin clinical trials (N = 525)

Body system	> 75%	50% to 75%	25% to 50%	10% to 25%
Mucous membranes	Cheilitis		Rhinitis	Dry mouth, epistaxis
Skin and appendages		Alopecia, skin peeling	Dry skin, nail disorder, pruritus	Erythematous rash, hyperesthesia, paresthesia, paronychia, skin atrophy, sticky skin
Eye disorders				Dry eyes
Musculoskeletal				Arthralgia, spinal hyperostosis (progression of existing lesions)
CNS				Rigors

Adapted from Sorlatane (acitretin) package insert information, Nutley, NJ: Roche Laboratories; 1997. Patients received acitretin in doses ranging from 10 to 75 mg/day, with the majority receiving 25 to 50 mg/day. Highest incidence of adverse events occurred in patients receiving highest doses (75 mg/day). Adverse events not listed in this table occurred in 10% or fewer patients.

To date, 7 pregnancies have been reported to be associated with acitretin therapy in the male at time of conception. None of these resulted in malformations typical of retinoid embryopathy.¹⁶ However, no conclusions can be made from this very limited data. Pharmacokinetic calculations based on measurement of acitretin levels of 3 males undergoing acitretin therapy predict an average concentration of 12.5 ng/ml in semen. This translates to 125 ng total dose in ejaculate (10 ml). Assuming 100% transfer of this dose to the female, this would correspond 1/200,000 of a 25 mg dose, resulting in serum concentrations far below the expected teratogenic threshold.⁷ It is not known whether acitretin in seminal fluid poses risk to a developing fetus.

Hepatotoxicity

Use of acitretin may cause elevations in serum liver enzymes. Increases in AST, ALT, or LDH of 72% have been reported to occur in approximately 1 in 3 patients treated with acitretin. These increases, however, are often transient and are reversible upon lowering the acitretin dose or discontinuing therapy.⁷ Severe hepatotoxic reactions resulting from retinoid use are rare and idiosyncratic.¹⁸ Data from 1877 patients receiving acitretin therapy showed overt chemical hepatitis in only 0.26%.¹⁶ In an open-label study evaluating hepatotoxicity by pre- and post-treatment liver biopsies, 83% of 128 patients receiving acitretin demonstrated improvement or no dete-

function. These tests should be performed before initiation of acitretin therapy, at 1 to 2 week intervals until stable, and thereafter at intervals as clinically indicated. Alcoholics, diabetics, and obese individuals are at increased risk for hepatotoxicity and require more frequent liver function studies during acitretin treatment.⁷ Concurrent use of acitretin and other potentially hepatotoxic agents also necessitates more frequent laboratory monitoring and should be avoided if possible.

Pancreatitis

Elevation of triglyceride levels occurs in some patients on acitretin therapy. Increases of serum triglycerides to levels associated with pancreatitis are not common, although 1 case of fatal fulminant pancreatitis has occurred.⁷ In this case, the patient's baseline triglyceride level was 159 mg/dL and reached a maximum of 925 mg/dL. Patients at high risk for experiencing hypertriglyceridemia include those with diabetes mellitus, obesity, increased alcohol intake, or a family history of these conditions.⁷ Dietary modifications, reduction in acitretin dose, or drug therapy may be required to control triglyceride levels. Monitoring of serum triglycerides is recommended for all patients before initiation of acitretin therapy, at 1 to 2 week intervals until stable, and thereafter at intervals as clinically indicated. In addition, patients should be advised of the potential occurrence of pancreatitis and to promptly report any significant acute abdomi-

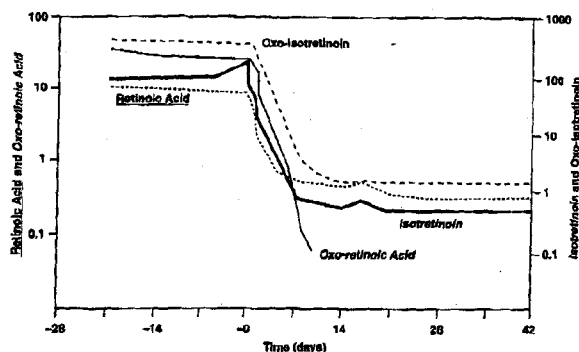


Fig. 3. Mean plasma concentrations of isotretinoin and its major metabolites during the last 4 weeks of treatment (days -28 to 0) with oral isotretinoin (normalized for a daily oral dose of 30 mg) and during 6 weeks after the end of treatment (days 0 to 42). For purposes of the graphic clarity, the actual datapoints are not shown. Please note the different y-axis scale (factor 10) for retinoic acid and isotretinoin.

Table I. Important pharmacokinetic parameters of isotretinoin and its metabolites (mean \pm SD)

	Isotretinoin	Oxo- Isotretinoin	Retinoic acid*
Half-life (hr)	18.7 \pm 6.2	29.2 \pm 5.7	0.9 \pm 0.4
C _{max} (ng/mL)	208 \pm 91.8	473.2 \pm 171.3	22.4 \pm 15.0
C _{min} (ng/mL)	89.8 \pm 48.7	387.9 \pm 152.1	11.2 \pm 5.6
T _{max} (hr)	4.5 \pm 3.4	6.8 \pm 6.5	4.5 \pm 3.3

*Pharmacokinetic parameters were derived when all-*trans*-retinoic acid was administered directly to patients.

shows plasma concentrations of isotretinoin, retinoic acid, and their metabolites in the last 4 weeks of treatment with isotretinoin at an oral dose normalized for 30 mg daily. During therapy, steady-state concentrations were higher for oxo-isotretinoin and isotretinoin than for retinoic acid and oxo-retinoic acid (please note the 10-fold difference in y-axis scale between isotretinoin and retinoic acid). Table I lists some of the pharmacokinetic parameters for isotretinoin derived from this trial in patients with acne, whereas the retinoic acid data were derived from a study in healthy volunteers receiving retinoic acid directly.⁶ Because of reversible interconversion and formation rate-

limited elimination, concentrations of retinoic acid and oxo-retinoic acid decline as isotretinoin metabolites at a slower rate. Their half-lives do not reflect their own elimination rates but those of their isomers.

ENDOGENOUS CONCENTRATIONS IN PREGNANCY

Vitamin A is required for normal embryonic development. Vitamin A deficiency and excessive intake during the first trimester of pregnancy, however, can cause embryonic malformations.

Because they are vitamin A metabolites, isotretinoin and its metabolites are endogenous physiologic compounds. On the other hand, isotretinoin is undoubtedly also a teratogen.^{3,10} To determine physiologic retinoid plasma concentrations in pregnancy, specifically in the first trimester, a multicenter trial was initiated in more than 160 pregnant women in 9 countries. Several blood samples were taken from weeks 5 to 32 of pregnancy. An extensive food record was collected before each sampling day to determine the effect of food on plasma isotretinoin concentrations. Pregnancy outcome was assessed on the assumption that retinoid plasma concentrations in the maternal circulation determine those in the

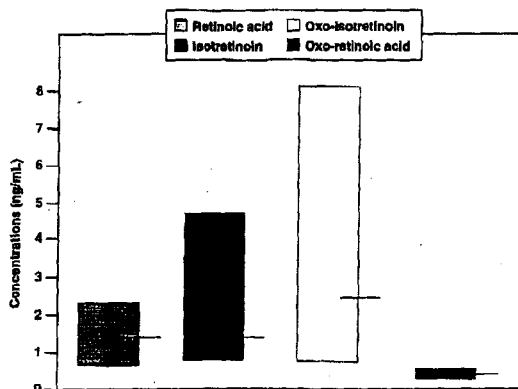


Fig. 4. Endogenous plasma concentrations (ranges and mean values) of isotretinoin and its major metabolites in women during the first trimester of pregnancy.

embryo. A healthy baby at term was taken as evidence that first-trimester endogenous retinoid plasma concentrations were nonteratogenic and vice versa. Mean isotretinoin and oxo-isotretinoin plasma concentrations in the first trimester (5.1-10.6 weeks' gestation) in approximately 80 pregnant women sampled were 1.41 ng/mL (range, 0.72-4.72 ng/mL) and 2.44 ng/mL (range, 0.84-7.72 ng/mL), respectively (Fig. 4). Mean retinoic and oxo-retinoic acid concentrations were lower: 1.33 ng/mL (range, 0.68-2.18 ng/mL) and 0.34 ng/mL (range, 0.26-0.54 ng/mL), respectively.

POSTTHERAPY CONTRACEPTIVE PERIOD

The duration of the posttherapy contraceptive period (PTCP) is a major safety consideration when treating women of childbearing potential with oral isotretinoin. Initially the PTCP was based on the elimination of isotretinoin and its metabolites in women with the use of pharmacokinetic parameters only. This is an appropriate method but has the drawback of being indirect and based only on calculations. The knowledge about endogenous isotretinoin concentrations during early pregnancy was used as the basis to better define the PTCP of isotretinoin. This new

Table II. Time (mean \pm SD) to reach endogenous retinoid plasma concentrations [T_{endo}] after therapy with oral isotretinoin

	T_{endo} (day)
Oxo-isotretinoin	9.7 \pm 1.8
Isotretinoin	4.4 \pm 1.2
Oxo-retinoic acid	3.8 \pm 1.1
Retinoic acid	1.9 \pm 0.7

approach was therefore based on the time required to reduce isotretinoin plasma concentrations after the end of isotretinoin therapy (in patients with acne) from therapeutic to endogenous levels. Data from a recent trial in 30 female and male patients with acne (Fig. 3) who received oral isotretinoin (0.5 to 1.0 mg/kg/day) for 3 to 5 months were used as the basis for this approach.¹ After the end of treatment, the time to reach endogenous concentrations (T_{endo}) was calculated for all patients.

As expected from their respective terminal elimination half-lives, T_{endo} values were different for each metabolite of isotretinoin (Table II). Oxo-isotretinoin had the longest T_{endo} value (approximately 10 days) and retinoic acid the shortest (2

S12 Wiegand and Chou

days). The study showed that in the case of the metabolite with the longest elimination half-life, nonteratogenic plasma retinoid concentrations were reached in this population no later than 2 weeks after the end of isotretinoin treatment. In the case of retinoic acid, which is suspected to contribute considerably to the teratogenic effect of isotretinoin, it takes only 2 days to return to physiologic levels.

Thus a clinical trial has experimentally confirmed the PTCP of 1 month and, in fact, indicated that this time frame provides a more-than-adequate safety margin.

TRANSPLENTAL TRANSPORT

The teratogenic effect occurs in the embryo, meaning that the retinoid must first cross the placenta. Ethics prevent the study of transplacental retinoid transport in pregnant women. However, based on the lipophilicity of isotretinoin, placental tissue can be expected to affect retinoid transport to the embryo. The best available model to study this effect is the isolated perfused human term placenta, despite its anatomic and physiologic differences from the first trimester placenta. The basic transport parameters of these retinoids seem to be surprisingly similar, probably because the relevant features of the membranes separating maternal and embryonic circulations do not change dramatically between first and third trimester; membrane thickness actually decreases during that period. The basic transport parameters developed for isotretinoin and its metabolites in the human term placenta¹¹ are currently being applied to animal models not constrained by ethical restrictions regarding pregnancy outcome. With human and animal data computer simulations of the transplacental transport should be possible to predict retinoid concentrations in the embryo leading to teratogenic effects. It is already known that the equilibrium between maternal and embryonic plasma occurs at the level of the free (nonprotein bound) maternal retinoid plasma concentration. Thus high protein binding is important in transplacental retinoid transport and modifies the amount of isotretinoin reaching the embryo. Using data from several experiments, we have been able to predict retinoid concentrations in the embryo even

across species and are confident that further refinements of our models will also allow us to generate useful predictions in humans.

SUMMARY AND CONCLUSIONS

The basic pharmacokinetic parameters generated in the early clinical trials of isotretinoin are still valid and have been verified in a recent study. With improved analytical methods, it was possible to show that isotretinoin and its metabolites are naturally occurring retinoids that are also present during pregnancy. The PTCP of 1 month for isotretinoin has been experimentally verified in a recent clinical study. Even the metabolite with the longest terminal elimination half-life (ox isotretinoin) returns to endogenous concentration within 2 weeks after the end of oral isotretinoin treatment. Therefore a 1-month PTCP provides an adequate safety margin for isotretinoin.

REFERENCES

1. Wiegand UW, Cunliffe WJ, Wyss R, Crevoisier C. Treatment of female patients with isotretinoin: What is the safe post-therapy contraceptive period? Presented Clinical Dermatology 2000; May 1996; in Vancouver, Canada.
2. Gerst H. Vitamin A: functions, dietary requirements and safety in humans. *Int J Vitam Nutr Res* 1997;67:71-90.
3. McLaren DS, Garrow JS, James WPT, editors. *Vitamin A: human nutrition and dietetics*. 9th ed. Edinburgh: Churchill Livingstone; 1993.p.208-17.
4. Allen JG, Bloxham DP. The pharmacology and pharmacokinetics of the retinoids. *Pharmacol Ther* 1989;40:27.
5. Lucek RW, Colburn WA. Clinical pharmacokinetics of the retinoids. *Clin Pharmacokinet* 1985;10:38-62.
6. Lefebvre P, Thomas G, Gourmel B, et al. Pharmacokinetics of oral all-trans-retinoic acid in patients with acute promyelocytic leukemia. *Leukemia* 1991;5:1054-8.
7. Wyss R, Bucheli F. Quantitative analysis of retinoids in biological fluids by high-performance liquid chromatography using column switching. I. Determination of isotretinoin and tretinoin and their 4-oxo metabolites in plasma. *J Chromatogr* 1988;424:303-14.
8. Rowland M, Tozer TN. *Clinical pharmacokinetics: concepts and applications*. 2nd ed. Philadelphia: Lea & Febiger; 1989.p.347-75.
9. Lammer EL, Chen DT, Hoar RM, et al. Retinoic acid embryopathy. *N Engl J Med* 1985;313:837-41.
10. Rosa FW. Retinoid embryopathy in humans. In: Koren G, editor. *Retinoids in clinical practice*. New York: Marcel Dekker; 1993.p.77-109.
11. Dittrich S, Schröder S, Malek A, Nöschel H, Schneider H, Wiegand UW. Transport and tissue uptake of retinoids in the human placenta: isotretinoin [Abstract]. *Placenta* 1993;14:A58.

LETTERS TO THE EDITOR

an interesting suggestion, I do not believe it is a practical solution to breastfeeding infants of HIV infected mothers.

Thomas Cherian,
Professor,
Department of Child Health,
Christian Medical College and Hospital,
Vellore 632 004.

REFERENCES

1. Feachem R, Koblinsky M. Strategies for the reduction of diarrheal diseases among young children: Promotion of breastfeed-
ing. Bull WHO 1984; 62: 271-291.
2. Quinn TC, Ruff A, Halsey N. Pediatric acquired immunodeficiency syndrome: Special considerations for 5 developing nations. *Pediatr Infect Dis J* 1992; 11: 558-568.
3. Dunn DT, Newell ML, Ades AE, Peckham CS. Risk of human immunodeficiency virus type 1 transmission through breastfeeding. *Lancet* 1992; 340: 585-588.
4. Cherian T. Ambulatory care of children with HIV infection in developing countries. *Malaysian J Child Health* (in Press).

Acute Toxicity of Vitamin A Administered with Measles Immunization

In the recent article(1), authors have diagnosed vitamin A toxicity after measles immunization on the basis of bulging anterior fontanelle within 24 h of intake of 1,00,000 IU of Vitamin A given along with measles vaccine. They have not estimated vitamin A levels or demonstrated any other change of vitamin A toxicity such as liver enzymes, hematological indices or tests for bone changes. Without this, it is difficult to establish unequivocally the causal association between Vitamin A supplementation and bulging anterior fontanelle(2). Further, can just three suspected cases be enough to reconsider the recommendation of Child Survival and Safe Motherhood Programme(3)?

In a similar study from Bangladesh(2), a double blind, randomized, placebo controlled trial was conducted in 167 patients less than six months. The authors concluded that bulging anterior fontanelle and administration of Vitamin A with vaccination

is only suggestive of a causal association. They concluded that further studies are required to understand clinical significance of these episodes of bulging anterior fontanelle. Bulging anterior fontanelle was seen in two children who received placebo instead of Vitamin A. Hence bulging fontanelle cannot be used as the sole criterion to diagnose Vitamin A toxicity.

Anju Aggarwal,
Department of Pediatrics,
Kalawati Saran Children's Hospital,
Lady Hardinge Medical College,
New Delhi 110 001.

REFERENCES

1. Gomber S, Chellani H. Acute toxicity of vitamin A administered with measles vaccine. *Indian Pediatr* 1996; 33: 1053-1055.
2. Baqui AH, Francisco A, Arifeen SE, Siddique AK, Sack RB. Bulging fontanelle after supplementation of 25,000 IU of Vitamin A in infancy using immunization contacts. *Acta Pediatr* 1995; 84: 863-866.
3. Control of Vitamin A Deficiency. Child Survival and Safe Motherhood Programme, Ministry of Health and Family Welfare, Government of India, 1991.

Reply

The three cases of vitamin A toxicity referred to had all the clinical features of raised intracranial tension and the children improved with decongestive measures. In fact measurement of vitamin A levels is not mandatory to prove toxicity. Observation of features of raised intracranial pressure (clinical and ultrasonography) within 24 h of Vitamin A administration is quite suggestive of causal association(1,2).

Our report was intended to apprise the pediatricians about the possibility of vitamin A toxicity when it is co-administered in a megadose (100,000 IU) with measles vaccination in infants. In this context, toxicity alluded to the clinical observation of raised intracranial pressure as evidenced by bulging fontanelle, the usual method for diagnosing acute vitamin A toxicity, particularly in the true setting of a resource starved developing country. After publication of the report, two more cases have been found by the authors and similar experience has been shared by others. We agree that three cases are insufficient to

change the recommendation. However, they certainly are useful pointers for gathering further data and the need for reconsidering the recommendation based on the possibility of toxicity vis a vis the "perceived" benefit.

Harish Chellani,
Pediatrician,
Department of Pediatrics,
Safdarjung Hospital,
New Delhi 110 029.

Sunil Gumber,
Associate Professor,
Department of Pediatrics,
Guru Teg Bahadur Hospital,
New Delhi 110 092.

REFERENCES

1. de Francisco A, Chakraborty J, Chowdhury HR, Yunus M, Baqui AH, Siddique AK, *et al.* Acute toxicity of vitamin A given with vaccines in infancy. *Lancet* 1993;342: 526-527.
2. Baqui AH, de Francisco A, Arifeen SE, Siddique AK, Sack RB. Bulging Fontanelle after supplementation with 25000 IU of vitamin A in infancy using immunization contacts. *Acta Paediatr* 1995;84: 863-866.

NOTES AND NEWS

INDIAN ACADEMY OF PEDIATRICS, BANGALORE: ANNUAL CMEP, 1997

This event is to be held under the auspices of Bangalore Branch and Karnataka State Branch of IAP and Rajeev Gandhi University of Health Sciences, Bangalore at Kuvempu Kalakshethra, K.R. Road, Bangalore between 13-15 June 1997. Highlights include Sessions on Infectious Diseases, Endocrinology, Dermatology, Nutrition, Cardiology, Neurology & Immunization; Panel Discussion on Perinatal Medicine; Workshop on Common Pediatric Procedures; Postgraduate Teaching Programme and Case Discussion and Postgraduate Quiz.

The delegate fee is Rs. 250/- till 1st June 1997, Rs. 300/- till 12th June, 1997 and Rs. 350/- for spot registration. Postgraduate students will be entitled to a discount of Rs. 100/-. For further details please contact The Organizing Secretary, Dr. R. Nisarga, 503 (Old No. 121), T. Mariyappa Road, 1st Block, Jayanagar, Bangalore 560 011. Tel: 6632438.

creased renal perfusion. Improvement in renal function in the recovery stages of HAV infection may be due to the removal of the viral antigen. The prognosis of these cases is unknown.

In conclusion, this case suggests that rarely mesangio proliferative glomerulonephritis, nephrotic syndrome and acute renal failure may occur as a complication of hepatitis A virus infection.

REFERENCES

1. Kramer MR, Hershko C, Slotki IN. Acute renal failure associated with non-fulminant type A viral hepatitis. *Clin Nephrol* 1986, 25: 219.
2. Eng C, Chopra S. Acute renal failure in non-fulminant hepatitis A. *J Clin Gastroenterol* 1990, 12: 717-718.
3. Geltner D, Naot Y, Zimhonio, *et al.* Acute oliguric renal failure complicating type A non fulminant viral hepatitis. A case presentation and review of literature. *J Clin Gastroenterol.* 92, 14: 160-162.
4. Chio F Jr, Bakir AA. Acute renal failure in hepatitis A. *Int J Artif Organs* 1992, 15: 413-416.
5. Lee MS, Choi Y, Yu SH, *et al.* A renal biopsy study of hepatitis B virus nephropathy in Korea. *Kidney Int* 1988, 34: 537-543.
6. Demetrios Z, Karabir SG, Kathryn C, *et al.* Nephrotic syndrome and acute renal failure associated with hepatitis A viral infection. *Am J Gastroenterol* 1995, 90: 295-298.
7. Heldenberg D, Weizer S. Acute type A hepatitis and acute glomerulonephritis in a carrier of hepatitis B antigen. *Harefurah* 1989, 116: 637-638.
8. Garel D, Vasmant D, Mongenot B, *et al.* Glomerular nephropathy with mesangial proliferation and acute hepatitis. A virus infection, 2 cases. *Ann Pediatr* 1986, 33: 185-188.

Acute Toxicity of Vitamin A Administered with Measles Vaccine

Sunil Gumber
Harish Chellani

Routine vitamin A supplementation in under five children has been recommended to improve child survival(1). The World Health Organization/United Nations Children Fund/International Vitamin A Consultative Group (WHO/UNICEF/IVACG) Task Force recommends universal distribution of vitamin A in countries where

xerophthalmia is a significant public health problem which includes India as well(2). It is recommended to orally supplement 100,000 IU of vitamin A to infants and 200,000 IU to children between 1 year to 6 year of age every 3-6 months.

The Government of India also recommends universal supplementation of 100,000 IU of vitamin A to all children

From the Department of Pediatrics, University College of Medical Sciences, Guru Teg Bahadur Hospital Shahdra, Delhi 110 095 and Safdarjung Hospital, New Delhi 110 029.

Reprint requisites: Dr. Sunil Gumber, F-4(A), Vijay Nagar, Delhi 110 009.

*Received for publication: September 4, 1996;
Accepted: September 10, 1996*

CASE REPORTS

along with measles vaccine(3). However, the safety and efficacy of mass vitamin A administration during infancy has not been firmly established. The present report highlights acute vitamin A toxicity noticed in 3 infants who received 100,000 IU of vitamin A with measles vaccination.

Case Reports

Three infants, 2 from one hospital (9 and 11 months of age) and 1 (aged 9 months) from another institution of Delhi were diagnosed to be suffering from acute vitamin A toxicity in the last 6 months (January 96-July 1996). All three infants presented with bulging of anterior fontanelle after 24 hours of oral intake of 100,000 IU of vitamin A given along with measles vaccine. Both nine month old infants also had associated excessive vomiting and irritability. There was no history of fever, convulsions, drug intake and jaundice in the recent past. General physical examination revealed normal vital functions with bulging anterior fontanelle. (protrusion from the skull when the child was sitting and was quiet). Central nervous system examination showed normal motor and sensory functions including reflexes.

Investigations revealed normal CSF findings in all three infants. Ultrasonography of skull in all three infants and CT scan of one patient showed normal ventricles. Two infants presenting with vomiting and irritability were treated with mannitol (1.4 g/kg/dose 8 hrly) for 24 hrs. and other child was left untreated. All three children improved within 24 hours and were discharged within 2 days.

Discussion

This report highlights acute toxicity of vitamin A noticed in 3 infants from two major hospitals. It seems to be the tip of an iceberg and we believe that many cases

occurring in the community may not be reported. Moreover the observed toxicity was bulging of fontanelle on clinical assessment. It is possible that frequency would have been higher if more sensitive technique of detection of intracranial pressure by cerebrospinal fluid cannula had been employed. Bulging of fontanelle has been noticed after supplementation with 25,000 IU-50,000 IU of vitamin A at the time of DPT/OPV immunization in two Bangladesh studies(4,5). There is a substantial support for the conclusion that exposure to 100,000 IU/day of vitamin A can produce multiple adverse effects(6) especially bulging of fontanelle as documented in the present study. A long term follow up of infants with bulging fontanelle would be important to preclude any possible neurological or developmental disorders. Moreover the efficacy of measles vaccine is reduced in infants who simultaneously receive 100,000 units of vitamin A(7).

The prevalence of vitamin A deficiency in India has declined from 2% in 1975-79 to 0.7% in 1988-90(8). Vitamin A deficiency now contributes to only 0.04% of total blindness as compared to about 2% two decades ago(9). In view of potential acute toxicity of vitamin A in infancy and marked reduction in the reported prevalence of vitamin A deficiency, it would be prudent to reconsider the recommendations of Child Survival and Safe Motherhood (CSSM) Programme(3).

REFERENCES

1. Sommer A, Tarwotjo I, Djunedj E, *et al.* Impact of vitamin A supplementation on childhood mortality. *Lancet* 1986, 1: 1169-1173.
2. Vitamin A Supplements: A Guide to their Use in the Treatment and Prevention of Vitamin A Deficiency and Xerophthalmia. Prepared by WHO/UNICEF/IVACG Task Force. Geneva, 1988.

3. Control of Vitamin A Deficiency, Child Survival and Safe Motherhood Programme, Government of India, 1991.
4. Francisco A de, Chakraborty J, Chowdhury HR, *et al.* Acute toxicity of vitamin A given with vaccines in infancy. *Lancet* 1993, 342: 526-527.
5. Baqui AH, Francisco A de, Arifeen SE, Siddique AK, Sack RB. Bulging fontanelle after supplementation with 25,000 IU of Vitamin A in infancy using immunization contacts. *Acta Paediatr* 1995, 84: 863-866.
6. Hathcock JN, Hattan DG, Jenkins MY, McDonald JT, Sundaresan PR, Wilkening VL. Evaluation of vitamin A toxicity. *Am J Clin Nutr* 1990, 52: 183-202.
7. Semba RD, Munasir Z, Beeler J, *et al.* Reduced seroconversion to measles in infants given vitamin A with measles vaccination. *Lancet* 1995, 345: 1330-1332.
8. National Nutrition Monitoring Bureau. Report of Repeat Surveys (1988-90). Hyderabad, National Institute of Nutrition, 1991.
9. National Programme for Control of Blindness, India. Report of National Workshop. New Delhi Directorate General of Health Services, 1989.

NOTES AND NEWS

3rd EAST ZONE CONFERENCE OF IAP AND 8th BIHAR STATE CONFERENCE OF IAP

These events are being organized by the Ranchi Branch of IAP on the 16th, 17th and 18th February, 1997 at the Indian Institute of Coal Management, Ranchi. The Registration forms are being individually posted to all the IAP members from the East Zone. For further details please contact: Dr. Krishna Kumar, Organizing Secretary, East Zone IAP Conference, 50 Doctors Colony, RMCH, Ranchi-834 009 (Bihar). Tel. No. (0651) 207443, 310340; Fax (0651) 205144.

FIFTH CONGRESS OF THE ASIAN PAN PACIFIC SOCIETY OF PEDIATRIC GASTROENTEROLOGY AND NUTRITION

This international event is to be held from April 10-13, 1997 at Taipei, Taiwan. For further information please contact: The Conference Secretariat: c/o K & A International Co., Ltd. P.O. Box 55-1143, Taipei, Taiwan. Tel: (886-2) 516-3952 Fax: (886-2) 516-2516.

NINTH ASIAN CONGRESS OF PEDIATRICS

This international event is to be held from 23rd-27th March 1997 at Hong Kong. For further details please contact: The Congress Secretariat, Meeting Planners (HK) Ltd., 12-A Dai Fat Street, Tai Po Industrial Estate, Tai Po, N.T., Hong Kong. Tel: (852) 2665 0990 Fax: (852) 2667 6927.

BENIGN INTRACRANIAL HYPERTENSION IN CHILDREN

Arthur Rose, M.D., C.L.B., D.C.H., and Donald D. Matson, M.D.

From the Departments of Neurology and Neurosurgery, Children's Hospital Medical Center and Harvard Medical School, Boston, Massachusetts

"BENIGN INTRACRANIAL HYPERTENSION" is used here to describe a clinical syndrome which consists of: (1) raised intracranial pressure, (2) normal cerebrospinal fluid findings, and (3) a midline ventricular system of normal or smaller than normal size as demonstrated by air contrast studies. The clinical picture is characterized by: (1) sudden onset of headache, (2) papilloedema, (3) frequent sixth nerve paresis, and (4) absence of convulsions or focal neurological abnormalities. This condition differs from other forms of intracranial hypertension in that (1) the level of consciousness remains unimpaired despite intracranial pressure often high enough to lead to visual failure and (2) the prognosis for complete eventual recovery after an illness of variable duration is excellent.

The great variety of names which has been applied to this condition during the past 50 years reflects the changes of thought about its pathogenesis. In the early part of this century most cases would have been diagnosed as "serous meningitis," a diagnosis which was later superseded by that of "arachnoiditis." The latter term implied that adhesions in the posterior fossa lead to the development of internal hydrocephalus. Although arachnoiditis undoubtedly occurs as a late sequel of tuberculous meningitis and as an occasional late complication of purulent meningitis, it became clear with the advent of pneumoencephalography that arachnoiditis resulted in obstructive hydrocephalus with enlargement of the ventricular system and, therefore, did not conform to the criteria of benign intracranial hypertension as defined above.

In 1931, Symonds¹ described the now familiar syndrome of acute otitis media lead-

ing to lateral sinus thrombosis and coined the term "otitic hydrocephalus" for this etiologically distinct form of benign intracranial hypertension. McAlpine² noted the occasional occurrence of raised intracranial pressure following relatively trivial nasopharyngeal infections and suggested that the increased production of cerebrospinal fluid might represent a reaction to bacterial toxins; hence, he proposed the term "toxic hydrocephalus." During subsequent years the term "pseudo-tumor cerebri" gained popularity and remained in favor until Foley³ introduced the term "benign intracranial hypertension." This would appear to be the most appropriate name, since it succinctly states the essential clinical features of the syndrome without undue emphasis on any single etiological factor.

Benign intracranial hypertension is an uncommon condition in childhood. Davidoff's⁴ account of 81 cases, representing 20 years' experience with all age groups, included only 12 patients below the age of 12 years. Relatively little material on this subject has been published in pediatric literature and some of the cases reported have not conformed to the clinical picture described by Foley.³ Thus, Moore⁵ reported three cases in detail. His Case 1, however, showed features of obstructive hydrocephalus with dilatation of the ventricles due to posterior fossa adhesions, which were released surgically. Another of his patients developed epilepsy, which is an unusual sequel of benign intracranial hypertension. His third patient died 1 month after admission from an unstated cause. A group of cases more in keeping with the diagnostic criteria outlined here was reported by Maisel and Caplan.⁶ But, in their Case 1, raised intracranial pressure

(Received May 20; accepted for publication September 14, 1966.)

ADDRESS: (D.D.M.) Children's Hospital Medical Center, 300 Longwood Ave., Boston, Massachusetts 02115.

PEDIATRICS, Vol. 39, No. 2, February 1967

was not demonstrated and the clinical course resembled "acute cerebellar ataxia" occurring in association with epidemic parotitis. Dees and McKay⁷ were the first to draw attention to the occurrence of benign intracranial hypertension following reduction or withdrawal of corticosteroid drugs in children.

The purpose of this paper is to report our experience of benign intracranial hypertension due to diverse causes in a group of 23 children and to summarize the current knowledge of its etiology with particular reference to the pediatric age group.

MATERIAL

The significant clinical features of our cases are summarized in Table I. Twenty-one of the cases were seen at the Children's Hospital Medical Center, Boston, during the period 1953 to 1963. There were 14 males and 9 females. Their ages ranged from 6 months to 11½ years.

Etiology

Cases 1 to 8 (Table I) followed an infection other than otitis media, cases 9 to 12 were associated with middle ear infection, and cases 13 to 16 occurred in relation to an episode of trauma. In one case (Case 17) benign intracranial hypertension developed following abrupt withdrawal of steroid therapy of nephrotic syndrome. The remaining cases, 18 to 23, were classified as "idiopathic," as their etiology was entirely obscure.

In the post-infectious cases, neurological symptoms usually followed immediately after the initial illness; but, in three patients a symptom-free interval of up to 2 weeks was noted before signs or symptoms of increased intracranial pressure appeared.

Symptoms and Signs

The presenting symptoms were remarkably uniform and consisted of headache in 11 patients and strabismus or diplopia in 9. Vomiting was the main complaint in 7 patients, all of whom were below the age of 5 years. Papilledema was present in all patients except one 6-month-old infant who,

however, showed other signs of increased intracranial pressure. External rectus palsy was present bilaterally in one child and unilaterally in nine. None of the patients in this study showed any neurological signs of impaired cerebral or cerebellar function. Seizures were not recorded in any of these patients.

Cerebrospinal Fluid Findings

Cerebrospinal fluid pressure measured by lumbar puncture or ventricular puncture at the time of ventriculography was 300 to 700 mm of H₂O in 19 patients, and in 3 it was noted to have been "raised" without a recorded numerical value. In Case 15, pressure was recorded as only 120 mm of cerebrospinal fluid, despite the presence of definite bilateral papilledema, lateral rectus palsy, and marked separation of cranial sutures.

In Cases 4 and 6, who were first seen early in the course of their illnesses, the initial lumbar puncture pressure was 150 mm of water. Both patients were re-admitted with an exacerbation of symptoms 2 weeks later and ventricular fluid pressure was then found to be elevated to 550 mm. Cerebrospinal fluid protein was below 40 mg/100 ml in all patients, and there were no more than five white cells in any of the cerebrospinal fluids.

Electroencephalogram

Electroencephalographic examination was carried out in 16 patients. The major abnormality, present in seven patients, consisted of paroxysmal bursts of high voltage slow activity, especially in the anterior leads, of the type that is sometimes seen in children with obstructive hydrocephalus.⁸ Borderline abnormalities were present in six patients and three records were entirely normal.

X-ray Studies

Röntgenograms of the skull revealed separation of cranial sutures in seven patients and evidence of mastoiditis in two. Ventriculography was carried out as the di-

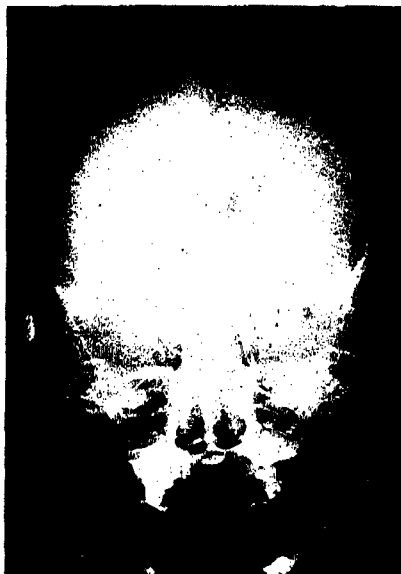

FIG. 1. G.R., 43-year-old male, developed persistent increased intracranial pressure with papilledema and sixth nerve palsy following minor trauma. Initial lumbar puncture pressure of 480 mm water. Anteroposterior lumbar pneumoencephalogram illustrates the normal size and placement of the ventricular system. Normal recovery followed repeat lumbar punctures.

agnostic procedure of choice in 20 patients. In two, the ventricles could not be entered, presumably owing to their small size; in four, the visualization of the ventricular system was incomplete. In these patients, lumbar pneumoencephalography was subsequently carried out. None of these air studies showed any abnormality, (Fig. 1-4). Air studies were omitted in Case 17, in which the intracranial hypertension was attributed to a sudden withdrawal of steroid therapy.

Treatment

Eight patients were treated with serial spinal punctures, three were treated with corticosteroids, and, in seven, treatment was limited to fluid restriction and administration of diuretics. Suboccipital de-

compression with posterior fossa exploration, sub-occipital decompression alone, and sub-temporal decompression were each performed in one patient.

Course and Duration of Illness

In eight patients when lumbar punctures were repeated after air contrast studies, the cerebrospinal fluid pressure was found to be normal and no further treatment was necessary. In most other patients the total length of hospital stay did not exceed 2 to 3 weeks. Diplopia and strabismus resolved in all patients during a few weeks. There were no recurrences, except in Case 15, she relapsed 2 months after initial improvement following repeated lumbar punctures. She was treated with further lumbar punctures and cortisone and made a rapid recovery.

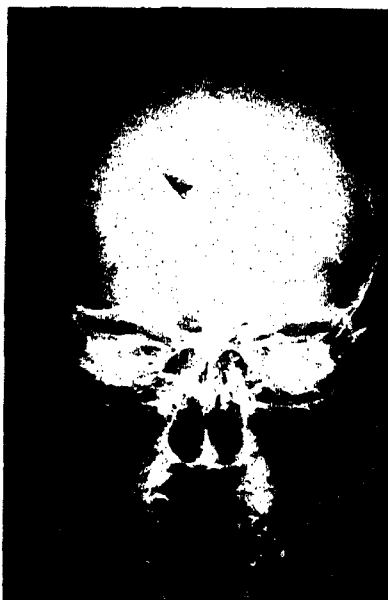


FIG. 2. N.H., 7 1/2-year-old female, developed headache, vomiting, and diplopia 2 weeks after an ear infection. There was papilledema, sixth nerve palsy, and elevated CSF pressure. Anteroposterior ventriculogram illustrates the normal size and placement of the ventricular system. Complete recovery followed subsequent lumbar punctures.

Follow-up Results

Patients were followed for periods ranging from 6 months to 11 years (Table I). Intellectual development proceeded normally in all patients who were followed sufficiently long for this to be assessed. None of the patients developed seizures or focal neurological deficits. Optic disc appearances returned to normal within 3 to 6 months, except in two patients who showed persistent residual optic disc pallor. None of the patients suffered significant permanent impairment of visual acuity. In two patients (Cases 18 and 19) recovery from the initial illness was followed by severe emotional disturbances which required long-term psychiatric treatment.

COMMENT

It will be seen from Table I that in the largest group of patients benign intracranial hypertension followed bacterial or viral infection such as gastroenteritis, streptococcal pharyngitis, upper respiratory tract infection, and chickenpox. A symptom-free period of 1 week (Case 6) to two weeks (Cases 5 and 8) intervened between the initial infective episode and the development

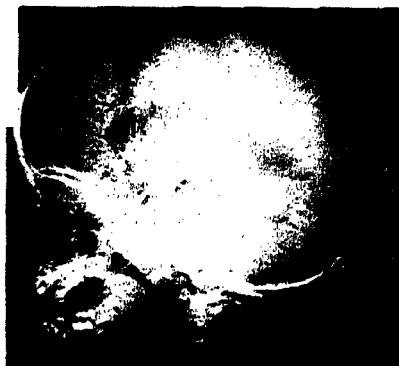

FIG. 3. B.H., 13-month-old male, had irritability and strabismus of unknown origin but no other neurological abnormalities except papilledema. There was an episode of "intestinal flu" 10 days previously. Lateral ventriculogram shows separation of cranial sutures but normal ventricles. There was complete recovery with follow-up over 5 years.

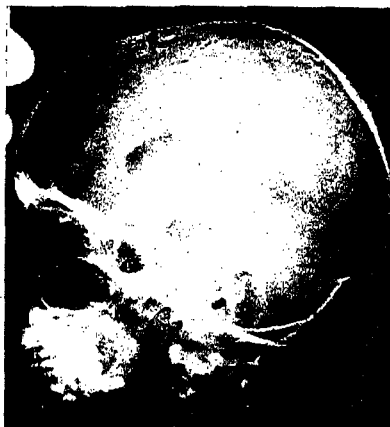

FIG. 4. D.S., 6-year-old male, developed headaches, stiff neck, diplopia, and vomiting 2 weeks after chickenpox. Papilledema was present. Lateral ventriculogram shows the normal size and placement of the ventricular system. There was complete recovery with a normal examination 2 years later.

of increased intracranial pressure. In Case 8 the absence of impairment of consciousness, lack of spinal fluid pleocytosis, and the presence of papilledema were the evidence against the diagnosis of varicella encephalitis.⁹ The occurrence of benign intracranial hypertension following nasopharyngeal infections has been reported by other authors.^{4,10} As early as 1937, McAlpine² proposed the "toxic hydrocephalus" theory. Symonds³ suggested that nasopharyngeal infections may in these cases be associated with thrombosis of veins in the pterygoid plexus with retrograde propagation of the thrombus into the jugular vein. It is of interest that mastoiditis associated with lateral sinus thrombosis, which has been the most frequent cause of benign intracranial hypertension in the past, has become relatively infrequent in the era of antibiotics. This syndrome is represented by only four patients in our series. The clinical features of lateral sinus thrombosis in a group of 11 children were recently discussed by Greer¹¹ and, although the ventricular system was visualized in only three of his patients, at surgery the lateral sinus in each case was

observed to be compressed by necrotic material. We are of the opinion that when signs of increased intracranial pressure are present with middle ear infection, it is always advisable to carry out neuroradiological contrast studies in order to rule out the possibility of a cerebral abscess.

In Case 12, symptoms developed following an occipital skull fracture from which damage to the confluence of the sinuses and secondary superior sagittal sinus thrombosis probably resulted. An almost identical clinical picture was described in a 6-year-old child by Bradshaw¹⁰ in his Case 13, and similar cases were reported by Martin¹² and Beller.¹³ From the study of these cases it appears that the initial head injury may be minimal and that there may or may not be associated loss of consciousness. Approximately half of the reported patients had sustained skull fractures, but not always in relation to one of the dural venous sinuses. Our Cases 13 and 14 developed symptoms following relatively trivial closed head injuries and the clinical picture differed from the usual form of post-traumatic cerebral edema in the absence of confusion or any impairment of consciousness despite markedly elevated intracranial pressure. A similar course of events was observed by Foley,⁸ Davidoff,⁴ and Moore,⁵ and it seems probable that even a closed head injury may result in damage to tributary veins, predisposing to sinus thrombosis. Although in Moore's⁵ patient sagittal sinus venography was performed and no abnormalities were noted, it is possible that even minor degrees of mural thrombosis may be sufficient enough to interfere with the re-absorption of cerebrospinal fluid but not extensive enough to be demonstrated radiologically.

One patient (Case 17), was of interest because he probably belongs to the growing list of children who have developed benign intracranial hypertension after sudden cessation of corticosteroid therapy. Nephrotic syndrome developed in 1961 and during the subsequent 2 years he received two short courses of intramuscular ACTH therapy.

Following a relapse in June 1963, 50 mg prednisone combined with chlorothiazide and spironolactone was administered three times per week. Four weeks later gastroenteritis developed while he was at a summer camp and the treatment was abruptly stopped. A few days later the gastrointestinal symptoms disappeared but he complained of headache and was found to have marked papilledema without any other neurological signs. Laboratory investigations revealed leucocytosis of 20,000 with marked shift to the left, biochemical abnormalities consistent with the diagnosis of nephrotic syndrome, and diagnostic lumbar puncture showed pressure of 340 mm of water. He was treated with 8 mg dexamethasone per day and, he improved rapidly following a good diuresis on the fifth day of treatment. When he was seen again 4 months later his optic fundi had returned to normal appearance.

In addition to cases following an infection or trauma there were six patients (Cases 18 to 23) in whom no apparent clinical association was evident. The average age of patients in this group was higher than in the other patients and the development of symptoms tended to be more insidious; thus, the symptoms resembled the adult form of benign intracranial hypertension. In connection with these "idiopathic" cases it is necessary to consider a few non-neurological conditions which occasionally present with a clinical picture of raised intracranial pressure. Recently one of us saw a child at the Hospital for Sick Children, London, (through the courtesy of Dr. John Wilson) who presented with severe papilledema and was subsequently shown to be suffering from hypoparathyroidism. This association is well described in endocrinological literature and accounts of chronic hypoparathyroidism with papilledema occurring in childhood have been published by Sutphin, Albright, and McCune¹⁴ and Albrecht.¹⁵ Even more infrequently, papilledema may be associated with acute hypoparathyroidism following thyroidectomy and Palmer, Seares, and Boldrey¹⁶ report-

ARTICLES

233

ed this condition in a child. Walsh,¹⁷ Bondin, Funck-Bretano, and Gayno,¹⁸ and Jefferson¹⁹ have described cases of Addison's disease presenting with papilledema and headaches. This is important not only because the neurological symptoms improve with specific therapy but also because these patients have poor tolerance for diagnostic air contrast studies.

Marie and See²⁰ were the first to draw attention to the syndrome of acute intracranial hypertension associated with vitamin A overdosage in small infants. They were able to reproduce the clinical picture of a bulging anterior fontanelle and increased cerebrospinal fluid pressure in healthy babies 1 to 5 months old at 12 to 24 hours after the ingestion of 350,000 u of vitamin A.

Recently several authors have drawn attention to the occurrence of acute intracranial hypertension coinciding with the administration of tetracycline^{21,22} and chlortetracycline²³ to young infants. In this condition bulging anterior fontanelle and abnormal irritability were usually noticed during the first day or two of treatment. A single lumbar puncture and withdrawal of the drug were followed by rapid recovery. Finally, it should be added that bilateral retrobulbar neuritis in a child not cooperative enough to allow the testing of central vision to be carried out may be thought to be indicative of benign intracranial pressure, but normal cerebrospinal fluid pressure measurement would rule out this possibility.

The clinical picture in most of the children in our series was remarkably uniform. Frequently, the chief initial complaint was headache of fairly abrupt onset; initial vomiting was more frequent in younger children. Often the presenting complaint of strabismus led to ophthalmoscopic examination and discovery of papilledema. In a child presenting with bilateral papilledema and without lateralizing neurological signs, it is imperative to exclude the possibility of a midline obstructive lesion, such as aqueduct stenosis, tumor of cyst of third or

fourth ventricles or, less commonly, a cerebral hemisphere mass lesion. Tumor of the third ventricle is of particular importance in the differential diagnosis and no treatment should be undertaken until satisfactory radiological contrast studies of that area and of the fourth ventricle have been completed. If no displacement of the ventricular system from the midline is found, the ventricles are of normal or smaller than normal size, and no abnormalities are found in the cerebrospinal fluid, except for increased pressure, the diagnosis of benign intracranial hypertension may be made. Although the absence of ventricular dilatation is one of the diagnostic criteria recommended by Foley³ and most other authors, Bradshaw¹⁰ mentioned nine patients in whom air studies were performed after an average period of 5 weeks following the onset of symptoms. Some dilatation of the ventricles was demonstrated but benign intracranial hypertension was diagnosed, nevertheless.

The discovery of cerebrospinal fluid pleocytosis or of raised cerebrospinal fluid protein content in the presence of normal x-ray studies introduces various other diagnostic possibilities, such as cortical vein thrombosis, subacute bacterial or fungal meningitis, and chronic lead poisoning. In our view, diagnosis of benign intracranial hypertension should be made with extreme caution in the presence of any abnormal cerebrospinal fluid cellular reaction. It should be mentioned, however, that Foley³ and Bradshaw¹⁰ were prepared to accept a significant degree of cerebrospinal fluid pleocytosis in some of their patients.

The objects of treatment are: (1) to reduce intracranial pressure sufficiently to minimize the risk of optic nerve swelling being followed by secondary optic atrophy and (2) to maintain the patient as comfortably as possible. Traditional treatment consists of lowering the cerebrospinal fluid pressure by daily lumbar punctures and withdrawal of enough fluid to reduce the pressure slowly to half the opening value. Bradshaw¹⁰ criticized this therapy, stating

that in his experience the removal of 10 to 15 cc of cerebrospinal fluid failed to effect a sustained fall of pressure. The volume of cerebrospinal fluid produced per 24 hours is so large that it would be surprising if the withdrawal of only 10 to 15 cc produced more than a transient lowering of CSF pressure in the presence of abnormal absorption. We have employed the removal of larger volumes of cerebrospinal fluid and have performed spinal punctures twice a day, or more often if necessary. This may account for the difference between Bradshaw's¹⁰ experience and our own. Salt and fluid restriction and ammonium chloride and acetazolamide (Diamox) administration have been used for treatment of milder cases, but the effectiveness of these measures is not well documented and their value appears to be questionable. In children, the total course of symptoms tends to be briefer than in benign intracranial hypertension in adults. This, combined with the patency of cranial sutures in many younger children, renders the need for surgical intervention less frequent than in older patients. Thus, surgical decompression had to be carried out in only three of our patients. In contrast, in Davidoff's⁴ adult patients sub-temporal decompression was carried out in 51 of 61 cases. Sub-occipital rather than sub-temporal decompression has the obvious advantage of allowing inspection of the posterior fossa to be made at the time of operation.

Paterson, De Pasquale, and Mann²¹ reported details of their experience with corticosteroid therapy in six patients with benign intracranial hypertension. In one patient there was no response and in two patients the effect was difficult to evaluate; but, in at least three patients the improvement was definite and dramatic. Our own experience of corticosteroid treatment in this condition is too limited for significant comment, although its introduction undoubtedly coincided with marked subjective and objective improvement in Case 16 and in a dramatic recovery in Case 17.

Anticoagulant treatment has been used in

cases of proven sagittal sinus thrombosis by Ray and Dunbar;²² but it did not prevent the reformation of a surgically evacuated thrombus in their Case 1. Nevertheless, there is probably a place for anticoagulant therapy in the rare instances of retrograde spread of thrombosis from the sagittal sinus into the cortical tributary veins, provided that hemorrhagic infarction is excluded by the demonstration of clear cerebrospinal fluid.²³

DISCUSSION

There can be little doubt that benign intracranial hypertension constitutes a symptom complex which may be caused by diverse etiological processes, of which only a few are understood at present. The lack of pathological material, the reluctance "to over-investigate" patients suffering from a condition with ultimately good prognosis, and the deficiencies in our knowledge of cerebrospinal fluid physiology are responsible for the fact that the pathogenesis of the clinical syndrome has been clarified in only a few instances. Moreover, even in cases where the etiology is known, as for example in lateral sinus thrombosis, the precise mechanism of intracranial pressure elevation still remains obscure.

Foley⁷ postulated three possible ways in which the intracranial pressure may be raised without co-incident dilatation of the ventricular system: (1) by obstruction of venous drainage leading to venous congestion, (2) by edema of cerebral tissues, and (3) by active dilatation of the arterial tree. The studies of the variation in the anatomical arrangement of major venous sinuses by Woodhall²⁴ have shown why benign intracranial hypertension occurs in only some cases of lateral sinus thrombosis. The superior sagittal sinus most frequently drains into the right lateral sinus, and the straight sinus drains most frequently into the left lateral sinus. Usually a communication between the two systems is present at the torcular so that complete venous obstruction cannot develop unless: (1) thrombosis involves the confluence of the sinuses, (2)

there is an anatomical variation such as absence of communication between the two lateral sinuses at the torcular, or (3) there is complete absence of one lateral sinus.

Ray and Dunbar²⁶ demonstrated superior sagittal sinus obstruction in several cases of benign intracranial hypertension unaccompanied by local infection. Occlusion of the jugular vein, whether due to extension of thrombosis from the pterygoid plexus or external compression by scar tissue, thrombosis around an in-lying ventriculocaval shunt tube, or trauma to the neck (as in our Case 16) results in the typical picture of benign intracranial hypertension if the thrombus was propagated to the torcular. It would seem that cerebral angiography with serial films continued late into the venous phase to visualize the major sinuses and jugular veins might be an informative additional investigation in patients with suspected benign intracranial hypertension.

It is of interest to recall that before the introduction of intravenous fluid therapy, dural sinus thrombosis was a frequent complication of acute dehydration in infants under 1 year of age. The clinical picture was complicated by the co-existing electrolytic disturbance. The degree of neurological involvement was usually severe with signs of increased intracranial pressure often accompanied by dilatation of scalp veins, soft tissue edema, convulsions, and frequently blood stained cerebrospinal fluid. The pathological findings were characterized by extensive areas of hemorrhagic infarction of cortical and sub-cortical structures.²⁷

It has been emphasized by several writers^{4,11,20} that in cases of benign intracranial hypertension the arachnoid membrane is under great tension when observed at the time of surgical decompression and the volume of cerebrospinal fluid in the sub-arachnoid spaces is greatly increased. Because of this it has been postulated that even partial dural sinus thrombosis could interfere with effective absorption of cerebrospinal fluid through arachnoid villi, but this explanation is difficult to accept in the

absence of ventricular dilatation, particularly in cases of long standing.

Cerebral edema, the second mechanism postulated by Foley,⁹ appears to be a possible cause of raised intracranial pressure in patients in whom venous thrombosis could not be demonstrated. The effect of high-dose steroid therapy on cerebral edema, associated with malignant cerebral gliomas and cerebral metastases, or on traumatic edema, is well-known.²⁹ The effectiveness of corticosteroids reported in some cases of benign intracranial hypertension supports the theory that generalized cerebral edema may be responsible for some cases of this syndrome. Further evidence for this possibility can be found in the work of Sahs and Joynt³⁰ who have demonstrated intracellular and extracellular edema in brain biopsies obtained at the time of surgical decompression in 10 of their patients. However, the striking preservation of consciousness in benign intracranial hypertension suggests that cerebral edema in this condition must be of a different variety from that which accompanies cerebral infarction, trauma, tumor or cerebral anoxia.

Although hypoadrenalism in childhood is very rare, the occasional cases of Addison's disease presenting with the clinical picture of headaches and papilloedema are of interest in relation to the increasing number of cases of benign intracranial hypertension occurring in children receiving long-term steroid therapy. Dees⁷ postulated adrenal hypofunction in three children who had had prolonged corticosteroid treatment for asthma and developed signs of raised intracranial pressure following reduction of dosage; evidence of adrenal hypofunction was presented in Case 2 in which the excretion of adrenal steroids was stated to be "low" and a prolonged period of stimulation with ACTH was required before a significant rise in 17-hydroxysteroids and 17-ketosteroids occurred. Creer²¹ added five more cases of benign intracranial hypertension associated with triamcinalone therapy in children. Urinary 17-ketosteroid and 17-hydroxycorticosteroid outputs were estimated in two of

Greer's patients and were found to be normal; an ACTH stimulation test, which was carried out in one patient, was also normal. When Walker and Adankiewicz²² reported four cases of benign intracranial hypertension after withdrawal of corticosteroid therapy in children in 1964, they reviewed the world literature and found 24 published cases. In most instances the onset of symptoms followed either cessation of therapy or reduction of dosage, sometimes even when the reduction of dosage was accomplished gradually. In most cases, neurological symptoms either subsided spontaneously or corticosteroids had to be re-introduced. Other patients were treated with lumbar punctures and one patient was even subjected to subtemporal decompression.

The probable endocrinological basis for benign intracranial hypertension occurring in some adults is strongly suggested by the well-known association of this syndrome with the first trimester of pregnancy, with disorders of the menstrual cycle, and with gross obesity. Attention was first drawn by Foley³ to the frequent occurrence of benign intracranial hypertension in obese pre-pubertal females, and Greer²³ recently reviewed 10 girls with this condition aged 11 to 14 years. He suggested that since the clinical syndrome in these patients, and in the cases occurring in early pregnancy, appears at a time of rapid rise of estrogen level it might result in suppression of the adrenals and cause relative adrenal hypofunction. No direct evidence was offered, however, in support of this speculation.

SUMMARY

The clinical features of 23 cases of benign intracranial hypertension occurring in childhood have been reviewed. Eight cases followed minor bacterial or viral infections, four cases occurred in association with head or neck injury, four cases occurred with otitis media, and one case followed sudden cessation of corticosteroid treatment. There were no apparent associated clinical factors in the remaining six cases. Benign intracranial hypertension thus emerges as a clin-

ical syndrome of varied etiology, generally with a short course, good prognosis, little tendency to recurrence, and only rarely requiring surgical intervention. Clinical evidence suggests that, in addition to otitis media, cerebral venous thrombosis may, in certain circumstances, follow head injury, trauma to the jugular vein, and thrombosis in the pterygoid venous plexus. Therefore, it is suggested that complete visualization of the venous cerebral circulation should be attempted in the investigation of patients with benign intracranial hypertension.

In view of the occurrence of the syndrome following gastroenteritis, upper respiratory tract infections, and chickenpox, diagnostic virological studies, including culture of cerebrospinal fluid, are of special interest. Other precipitating causes of this clinical syndrome are discussed. The occurrence of benign intracranial hypertension as an initial manifestation of two well defined endocrine abnormalities is described. It is possible in the future that systematic endocrine study of patients, particularly pre-pubertal females, will reveal other hormonal defects.

It appears probable that transient generalized cerebral edema of any type may be responsible for the occurrence of this syndrome. The elucidation of its pathophysiology will probably have to wait more accurate and safe methods of clinical measurement of intra- and extra-cellular fluid shifts within the brain, as well as more reliable understanding of cerebrospinal fluid and cerebral blood flow alterations.

REFERENCES

1. Symonds, C. P.: Otitic hydrocephalus. *Brain*, 54:55, 1931.
2. McAlpine, D.: Toxic hydrocephalus. *Brain*, 60:180, 1937.
3. Foley, J.: Benign forms of intracranial hypertension — "toxic" and "otitic hydrocephalus." *Brain*, 78:1, 1955.
4. Davidoff, L. M.: Pseudotumor cerebri; benign intracranial hypertension. *Neurology*, 6:605, 1956.
5. Moore, R. B.: Pseudotumor cerebri. *PEDIATRICS*, 10:266, 1957.
6. Maisel, J. E., and Caplan, J.: Pseudotumor

ARTICLES

237

- cerebri, benign intracranial hypertension. *J. Pediat.*, 52:441, 1958.
7. Dees, S. C., and McKay, H. W., Jr.: Occurrence of pseudotumor cerebri (benign intracranial hypertension) during treatment of children with asthma by adrenal steroids. *PEDIATRICS*, 23:1143, 1959.
 8. Lombroso, C. T.: Personal communication, 1963.
 9. Miller, H. G., Stanton, J. B., and Gibbons, J. L.: Para-infectious encephalomyelitis and related syndromes. *Quart. J. Med., New Series*, 25:427, 1956.
 10. Bradshaw, P.: Benign intracranial hypertension. *J. Neurol. Neurosurg. Psych.*, 19:28, 1956.
 11. Greer, M.: Benign intracranial hypertension, I. Mastoiditis and lateral sinus obstruction. *Neurology*, 12:472, 1962.
 12. Martin, J. P.: Signs of obstruction of superior longitudinal sinus following closed head injuries (traumatic hydrocephalus). *Brit. Med. J.*, 2:467, 1955.
 13. Beller, A. J.: Benign post-traumatic intracranial hypertension. *J. Neurol. Neurosurg. Psych.*, 27:149, 1964.
 14. Sutphin, A., Albright, F., and McCune, D. J.: Five cases (three in siblings) of idiopathic hypoparathyroidism associated with moniliasis. *J. Clin. Endocr.*, 3:625, 1943.
 15. Albrecht, K.: Stauungspapille bei tetanie. *M Schr. Psychiat. Neurol.*, 55:55, 1923.
 16. Palmer, R. F., Scates, H. H., and Boldrey, E. B.: Papilledema and hypoparathyroidism simulating brain tumor. *J. Neurosurg.*, 10:378, 1959.
 17. Walsh, B.: Papilledema associated with increased intracranial pressure in Addison's disease. *Arch. Ophthalm.*, 47:86, 1952.
 18. Doudin, G., Funck-Brentano, J. L., and Gayno, M.: Maladie d'Addison par aplasie surrénale et syndrome para-biémérien. *Bull. Soc. Méd. Hôp. Paris*, 66:1736, 1950.
 19. Jefferson, A.: Clinical correlation between encephalopathy and papilledema in Addison's disease. *J. Neurol. Neurosurg. Psych.*, 19:21, 1956.
 20. Marie, J., and See, G.: Acute hypervitaminosis A of infant; its clinical manifestations with benign acute hydrocephalus and pronounced bulge of fontanel; clinical and biologic study. *Amer. J. Dis. Child.*, 87:731, 1954.
 21. Fields, J. P.: Bulging fontanel: a complication of tetracycline therapy in infants. *J. Pediat.*, 58:74, 1961.
 22. O'Doherty, N. J.: Acute benign intracranial hypertension in an infant receiving tetracycline. *Develop. Med. Child Neurol.*, 7:677, 1965.
 23. Gellis, S. S.: *Yearbook of Pediatrics, 1956-57*. Chicago: The Yearbook Publishers, p. 40, 1956.
 24. Paterson, R., De Pasquale, N., and Mann, S.: Pseudotumor cerebri. *Medicine*, 40:85, 1961.
 25. Ray, B. S., and Dunbar, H. S.: Thrombosis of dural venous sinuses as cause of "pseudotumor cerebri." *Ann. Surg.*, 134:376, 1951.
 26. Fishman, R. A., Cowen, D., and Silberman, M.: Intracranial venous thrombosis during the first trimester of pregnancy. *Neurology*, 7:217, 1957.
 27. Woodhall, B.: Variations of cranial venous sinuses in region of torcular herophili. *Arch. Surg.*, 33:297, 1936.
 28. Byers, R. K., and Hass, G. M.: Thrombosis of dural venous sinuses in infancy and in childhood. *Amer. J. Dis. Child.*, 45:1161, 1933.
 29. Galicich, J. H., French, L. A., and Melby, J. C.: Use of dexamethasone in treatment of cerebral edema associated with brain tumours. *J. Lancet*, 81:46, 1961.
 30. Saks, A. L., and Joynt, R. J.: Brain swelling of unknown cause. *Neurology*, 6:791, 1956.
 31. Greer, M.: Benign intracranial hypertension. II. Following corticosteroid therapy. *Neurology*, 13:439, 1963.
 32. Walker, A. E., and Adamkiewicz, J. J.: Pseudotumor cerebri associated with prolonged corticosteroid therapy. *J.A.M.A.*, 188:779, 1964.
 33. Greer, M.: Benign intracranial hypertension. IV. Menarche. *Neurology*, 14:569, 1964.

Akute symptomatische Psychose bei Vitamin A-Intoxikation

R. Haupt

Neurologisch-Psychiatrische Klinik der Krankenanstalten Sarepta, Bielefeld-Bethel
 (Chefarzt: Prof. Dr. V. Alsen)

Acute Symptomatic Psychosis in Vitamin A Intoxication

Zusammenfassung. Bei einer 40jährigen Frau wurde nach einer hochdosierten Vitamin A-Behandlung eine akute symptomatische Psychose beobachtet. Nach kurzfristiger Gabe hoher Dosen Vitamin A kam es zunächst zu Verhaltensauffälligkeiten, die jedoch wieder abklungen und auch bei fortgesetzter Vitamin A-Behandlung mit 0,9–1,2 Mio. IE/täglich über 4 Monate nicht wieder auftraten. Erst nach Dosiserhöhung auf 3,0 Mio. IE Vitamin A/tägl. trat eine akute symptomatische Psychose auf, die eine stationäre psychiatrische Behandlung erforderlich machte. Gewichtsverlust, Hautabschälungen, Haarausfall, Lippenrhabden, Berührungsempfindlichkeit der Knochen und Gelenke, Appetitlosigkeit, Schlafstörungen, Otitis externa sowie Harnstoffserhöhungen im Serum, Hypercalcinose und Auffälligkeiten im EEG- und Liquorbefund, jedoch ohne Symptome eines Pseudotumors cerebri, traten in Erscheinung. In psychiatrischer Hinsicht ließ sich dieses Bild dem akuten exogenen Reaktionstyp Bonhoeffers zuordnen, wobei das Auftreten eines deliranten amentilen Syndroms mit gesteigerter Wachheit, Logorrhoe und fraglicher Hyperakusis bei gleichzeitiger motorischer Gekhemtheit dieser exogenen Psychose ein besonderes Gepräge gab. Nach Absetzen des Vitamin A und geringen Gaben von Neuroleptika klang die psychotische Symptomatik nach etwa 1wöchiger stationärer Behandlung ab.

Einleitung

Berichte über symptomatische Psychosen bei Vitamin A-Intoxikation sind selten. Leichte psychische Veränderungen können bei Vitamin A-Intoxikation vorkommen, doch stehen internistische und neurologische Befunde dabei immer im Vordergrund. Psychische Störungen werden als Begleiterscheinung und sehr kurzfristig und flüchtig beschrieben. Bisher sind

2 Fälle mit einer symptomatischen Psychose bei Vitamin A-Intoxikation bekannt geworden. Im ersten Fall kam es vor einer länger dauernden, schweren depressiven Verstimmung zu einer ausgeprägten schizophrenen Symptomatik [4]. Da diese nachweisbar auf die Intoxikation zurückzuführen ist, würden wir von einer schizophreniformen Psychose sprechen [2]. Im zweiten Fall begann die Symptomatik mit einer länger dauernden depressiven Verstimmung [18].

Wir möchten über eine weitere Beobachtung berichten, bei der die psychiatrische Symptomatik im Vordergrund des Krankheitsgeschehens stand und Anlaß für die Aufnahme auf einer geschlossenen psychiatrischen Station war. Vorausgegangen war innerhalb von 4 Monaten zweimal eine Behandlung mit hochdosierten Vitamin A-Gaben wegen Psoriasis. Zwischenzeitlich wurden ständig 0,9–1,2 Mio. IE Vitamin A täglich eingenommen.

Kasuistik

Patientin N.N., 40 Jahre

Zur Fremdanamnese erfuhren wir, daß die alleinstehende Lehrerin im März 1975 ihren Urlaub in Spanien verbrachte. In dieser Zeit wurde die 1. Psoriasis-Kur mit hochdosiertem Vitamin A durchgeführt. In den darauffolgenden Tagen habe sie eine Infektion mit Durchfall und Erbrechen durchgemacht und 10 kg an Gewicht verloren. In dieser Zeit seien „merkwürdige Dinge“ passiert. Die Patientin habe sich auffällig verhalten, genauere Angaben fehlen.

In den darauffolgenden 4 Monaten war die Patientin wieder unauffällig und nahm täglich 0,9–1,2 Mio. IE Vitamin A-Hochkonzentrat. Vom 29. 7.–6. 8. 1975 erfolgte eine Behandlung mit noch höheren Dosen Vitamin A. Aus dem Behandlungsbericht geht hervor, daß eine Antipsoriasis-Behandlung mit A-Mulsin-Hochkonzentrat® beginnend mit 1,5 Mio. IE am 1. Tag, 2,25 Mio. IE am 2. Tag und jeweils 3 Mio. IE vom 3.–8. Tag erfolgte und danach abgebrochen wurde. Gleichzeitig wurden dreimal 250 mg Sterajekt injetable®, 2 ml Wobe Muges® i.m. und 2 ml Akrinor® i.m., zweimal 5 ml Venoruton® i.v., 4 Drag. SP 54® und 1 Phlogase Supp.® wegen einer erneut aufgetretenen Unterschenkelthrombose verabreicht. Zusätzlich wurde während dieser Zeit, aus uns unbekanntem Grund, eine Elektro-Heilschlaftherapie (DORMED) jeweils 1 h lang mit Dominal® 4 ml i.m. sowie 5 ml Megaphen® i.m. durchgeführt.

Nach dieser Behandlung sei die Pat. verändert gewesen, körperlich sehr geschwächt und habe „gesponnen“, was sich unter

anderem darin geäußert habe, daß sie für die Behandlung ein stark überhöhtes Honorar auf eigenen Wunsch zahlen wollte. Ab 10.8.1975 habe sich das Bild verstärkt, der Zeitsinn habe gefehlt, sie habe gesagt, daß ihr 2 Tage im Gedächtnis fehlten und geglaubt, daß vor der Wohnungstür Leute gehen und stehen. Sie konnte nicht mehr schlafen und habe kaum noch gegessen. Sie habe seitdem im Dunkeln gegessen, nicht mehr gewußt, ob Tag oder Nacht sei, sei unruhig, aufgeregt und konfus in ihren Äußerungen gewesen, habe auf Fragen nicht mehr geantwortet, sondern mit Gegenfragen ständig überprüft und kontrolliert, ob Ref. normal sei. Sie habe ständig telefoniert und ab 12.8.1975 mit Leuten gesprochen, die gar nicht vorhanden waren. Außer A-Mulsin-Hochkonzentrat® habe die Pat. nur Tonovit® (enthält ebenfalls Vitamin A), Wobe Mugos®, SP 54® und Sterajekt® genommen. Alkohol habe sie nicht getrunken. Davor sei nie eine psychische Erkrankung aufgetreten, auch in der Familie waren keine psychischen Erkrankungen bekannt.

Allgemein körperlicher Befund

Bei der Aufnahme in der psychiatrischen Klinik am 12.8.1975 war die Anamnese nicht zu erheben. Die Pat. wurde im Krankenzug liegend gebracht und wehrte Untersuchungen zunächst ab. Die 40jährige leptosome Frau befand sich in schlechtem Az und Ez. Sie war exsikkiert. Kopfhaar stark gelichtet. Starker Haar- ausfall. An den Handinnenflächen und Fußsohlen schälte sich die Haut lappenförmig. Übrige Haut trocken. Die Lippen waren spröde und aufgerissen mit bräunlichem Belag. An den Ellenbogen und an den Knien kleinflächige psoriatische Bezirke. Offenes Ulcus cruris an der Außenseite des li. Unterschenkels. Innere Organe unauffällig. Herzaktion regelmäßig, Töne rein, RR 150/90 mm Hg. Puls um 90/min, Leber und Milz nicht vergrößert. Druckempfindlichkeit im Bereich der Kniegelenke und Unterschenkel.

Neurologischer Befund

Keine Hirnnervenstörungen, insbesondere keine Nackensteife, kein Nystagmus, normale Pupillenreaktionen, unauffälliger Fundus. An den Extremitäten keine Paresen. Muskeleigenreflexe mittelblehaft, seitengleich, BDR bds. nicht auslösbar, kein Tremor, keine spastischen Zehenzeichen, keine Störungen der Sensibilität und Koordination.

Psychischer Befund

Die Pat. lag die ersten Stunden im Bett und war körperlich vernachlässigt mit wirrem, ungekämmten Haar bei verstärktem Haarausfall. Der Gesichtsausdruck war aufmerksam, gespannt, die Augen weit geöffnet. Sie stand auch nach mehrfacher Aufforderung zur Untersuchung mitzukommen, nicht auf, hob nur gelegentlich den Kopf, schaute dabei aufmerksam im Saal herum, redete ununterbrochen mit fester, mittellauter Stimme in sehr rasch aufeinanderfolgenden in sich geordneten Sätzen. Der Gedankengang war jedoch sehr sprunghaft und verworren. Die monotonen Gedankeninhalte kehrten in rascher ungeordneter Folge in Form von Konfabulationen immer wieder, wozu die Pat. ausführende Bewegungen mit beiden Armen machte. Die Sprechweise war dabei fließend, sehr schnell, fast ohne Unterbrechungen. Weit entfernte akustische oder optische Reize oder Teile von Sätzen entfernt gehaltener Gespräche (10 m Entfernung) wurden unverzüglich aufgegriffen und mit in die Gedankengänge eingebaut. Inhaltliche Denkstörungen fielen nicht auf. Der Händedruck war kurz und kräftig. Die Stimmungslage erschien indifferent zur heiter-unbesorgten Seite hin tendierend. Das affektive Verhalten erschien oberflächlich, weitgehend teilnahmslos. Die innere Antriebslage war enthemmt, erregt und getrieben.

Das Bewußtsein war eingeeignet auf die immer wieder neu ablaufenden Gedankenketten bei erhöhter Aufnahmefähigkeit für ä-

R. Haupt: Psychose bei Vitamin A-Intoxikation

Bere Sinneseindrücke. Fragen wurden nicht beantwortet, aber Teile der Fragen wurden sofort in die rasch ablaufenden Gedankengänge eingebaut. Nur gelegentlich wurde auf kurze Fragen auch eine passende Antwort gegeben, wobei der Eindruck entstand, daß die Pat. zeitlich und örtlich nicht voll orientiert, zur Person aber voll orientiert war.

Wahrnehmungsstörungen in Form von Personenverkennungen, so daß auch nächste Angehörige nicht erkannt wurden, kamen vor. Akustische Illusionen, wobei Klappern mit Teelöffeln auf Untertassen als Wecker aufgefaßt wurde oder Glockengeläut als Schiffsglocken gedeutet wurde sowie akustische Halluzinationen, wobei sich die Pat. mit nicht anwesenden Personen unterhält, waren in Verbindung mit Ideenflucht vorhanden. Krankheitsinsicht war später vorhanden. Die sprachliche Ausdrucksweise war unauffällig. Eine partielle Amnesie für etwa 4–5 Tage war nachträglich feststellbar.

Labor

Körpergewicht 62,5 kg, Körpergröße 174 cm. WAR im Serum, Harnstatus, Transaminasen, Kreatinin, anorganisches Phosphor o. B. Im Blutbild 10400 Leukozyten bei unauffälligem Differentialblutbild. Ionogramm im Serum: Ca. 6,16 mval/l (normal 4,5–5,3) bei unauffälligen Werten für K, Na und Cl. Harnstoff i.S. 77 mg-% (normal bis 50 mg-%). Lumbaler Liquor: Kein Hinweis auf Liquordruckerhöhung. γ -Globulin-Erhöhung auf 18,1% (normal bis 14%). Übrige Liquorwerte einschließlich Zellzahl und Mastix-Reaktion unauffällig. In der Immunelektrophorese des Liquors leichte I_2 G-Vermehrung auf 4,300 mg-% (normal 0,20–2,800 mg-%). Urinuntersuchung auf Thallium negativ. Im Ruhe-EEG mäßige Allgemeinveränderung mit Herdbefund präzentro-temporoparietal li., unter HV leichte Dysrhythmie, keine Krampfpotentiale. Röntgen – Schädel und Tibia rechts: kein pathologischer Befund.

Diagnose

Akute symptomatische Psychose nach Vitamin A-Intoxikation.

Verlauf

Unter neuroleptischer Therapie mit Decentan® und Neurocil® wurde die Pat. schon nach wenigen Stunden deutlich ruhiger und wirkte bereits nach 24 h geordneter, dabei aber immer noch sehr redselig. Nächtliche Schlafstörungen waren bis zum 7. Behandlungstag erkennbar. Am 3. Behandlungstag wurde eine gelblich-grünliche Sekretion aus dem li. Ohr festgestellt. Die HNO-ärztliche Untersuchung ergab eine leichte Entzündung des äußeren Gehörganges. Im weiteren Verlauf löste sich der li. Großzehennagel nach einer Nagelbettentzündung. Nach etwa 3wöchiger Behandlung war die Pat. psychisch völlig unauffällig, hatte 3,7 kg an Gewicht zugenommen, die anfangs pathologischen Laborwerte hatten sich wieder normalisiert. Im Kontroll-EEG zeigte sich eine deutliche Rückbildung der Allgemeinveränderung, der Dysrhythmie und des Herdbefundes, der nur noch in geringer Ausprägung nachweisbar war. Auf eine erneute Lumbalpunktion wurde verzichtet.

Bei nachträglicher Erhebung der Anamnese konnte sich die Pat. nur bruchstückhaft und ungenau an die durchgemachte Psychose erinnern. Diese Erinnerungslücke bestand für etwa 4–5 Tage. Genaue Angaben darüber, wieviel Vitamin A in den letzten Tagen vor der stationären Aufnahme eingenommen worden war, konnten von ihr nicht gemacht werden. Es wurde jedoch eine angebrochene Flasche mit noch etwa 60 ml A-Mulsin-Hochkonzentrat® mit in die Klinik gebracht. Zu Hause wurden später drei leere Schachteln Tonovit® (zu 20 Kapseln) gefunden.

Katamnese

8 Monate nach der Entlassung sind keine psychotischen Erscheinungen mehr aufgetreten. Es erfolgte keine weitere Vitamin A-

Behandlung. Die Psoriasis ist kleinfächig an verschiedenen Körperstellen und im Bereich der behaarten Kopfhaut wieder aufgetreten. Wegen Thromboseneigung (die bereits vor der Vitamin A-Behandlung bestand und schon 1968 einmal zu einer Lungenembolie führte) ist die Pat. in internistische Behandlung.

Diskussion

Bei den wasserlöslichen Vitaminen kommen Intoxikationen nicht vor, da sie bei exzessiver Einnahme aufgrund ihrer guten Löslichkeit und Nierengängigkeit sehr rasch durch den Harn ausgeschieden werden [9]. Umgekehrt haben Vitamin-Mangel-Zustände in der Psychiatrie für den Vitamin B-Komplex Bedeutung erlangt. Hier sind psychische Störungen von neurosthenisch-depressiven Syndromen bis hin zum schweren akuten exogenen Reaktionstyp bekannt. Die Entwicklung hirnganischer Psychosyndrome bei Vitamin B₁-Mangel als Encephalopathia Wernicke mit häufigem Übergang in ein Korsakow-Syndrom oder bei Mangel des zum Vitamin B-Komplex gehörenden Nicotinamids und der Nicotinsäure als Pellagraptychose sowie bei Mangel des Vitamin B₁₂ als Perniciosa-Ptychose ist seit langem bekannt. Psychosen sind auch unter Mangel von Pyridoxin (Vitamin B₆) z.B. im Verlauf antituberkulöser Behandlung mit Isonicotinsäuredehydracrid (INH), einem Inhibitor des Pyridoxins oder unter Behandlung mit den als Diuretica benutzten Hydraciden oder unter Penicillamin zur Behandlung des M. Wilson bekannt geworden [11].

Über Vitamin-Mangelzustände ist bei den fettlöslichen Vitaminen A, D, E und K im Zusammenhang mit neurologischen oder psychiatrischen Störungen bisher wenig bekannt. Beim Kleinkind und Säugling verursacht Vitamin D-Mangel neben den anderen bekannten Symptomen der Wachstumsstörung und Rachitis auch Schreckhaftigkeit mit depressiver Stimmungslage. Therapieversuche wurden mit Vitamin E bei Progressiver Muskeldystrophie, amyotrophischer Lateralsklerose, Multipler Sklerose und Chorea Sydenham unternommen, die Behandlungsergebnisse sind aber unsicher und umstritten [22]. Beim sog. „Vitamin F“, einem Gemisch essentieller Fettsäuren, sind als Mangelsymptome unter anderem auch Anorexie, Müdigkeit, depressive Verstimmung und Hyperästhesie bekannt [22].

Bei exzessiver Einnahme fettlöslicher Vitamine kommt es dagegen zur Akkumulation in den körpereigenen Organzellen. Intoxikationen sind bei fettlöslichen Vitaminen den Pädiatern und Internisten gut bekannt [9, 22].

Man unterscheidet zwischen akuter und chronischer Vitamin A-Intoxikation [17], die beide im Erwachsenenalter anders verlaufen als im Säuglings- und Kindesalter. Die wahrscheinlich erste Beschreibung einer akuten Vitamin A-Intoxikation stammt von Gerrit de Veer aus dem Jahre 1597 (Lit.-Hinweis

in [20]). Bei Jugendlichen und Erwachsenen lassen sich die Folgeerscheinungen der akuten Intoxikation, die am häufigsten nach Genuß Vitamin A-reicher Eisbär-, Robben-, Walfisch- oder Heilbuttleber aufgetreten sind, folgendermaßen beschreiben: Bereits nach wenigen Stunden auftretende Benommenheit, Müdigkeit, Reizbarkeit, Übelkeit mit Erbrechen, Schwindel und heftige, meistens an der Stirn lokalisierte Kopfschmerzen sowie selten einmal generalisierte Krampfanfälle. Nach 2–3 Tagen kommt es zu erythematösen Abschuppungen der Haut, besonders an den Handinnenflächen und Fußsohlen [8].

Da erfahrungsgemäß die Bevölkerung unserer Breitengrade nur selten Gelegenheit hat, in den Genuß derartiger Leber zu kommen, haben wir vorwiegend mit medikamentös bedingten chronischen Intoxikationen zu rechnen. Diese können bei hochdosierter Vitamin A-Therapie auftreten, die in letzter Zeit gelegentlich zur Behandlung epithelialer Malignome sowie bei hyperkeratotischen Dermatosen eingesetzt wird.

Als häufigste und bekannteste Symptome der chronischen Vitamin A-Intoxikation bei Jugendlichen und Erwachsenen gelten Desquamation, Kopfschmerzen, Lippen- und Mundschleimhautveränderungen, Gelenk- und Gliederschmerzen, Haarausfall, makulöse und makulopapulöse Exantheme, Übelkeit und Brechreiz, Stauungspapille, Sehstörungen, Appetitlosigkeit, Müdigkeit und Abgeschlagenheit, Berührungsschmerzhaftigkeit der langen Röhrenknochen, Oligo-Hypomenorrhoe, sowie eine Reihe weiterer Beschwerden und klinischer Befunde, wie sie von Goeckenjan u. Mitarb. zusammengestellt sind. Von diesen Autoren wurde ebenfalls beschrieben, daß unter einer derartigen Therapie neben den bekannten Symptomen der Vitamin A-Intoxikation lebensbedrohliche Komplikationen in Form von wochenlang anhaltenden Bewußtseinstörungen, akutem Nierenversagen, Hyperglykämie und aplastischer Anämie vorkommen können.

Neurologische Auffälligkeiten wurden bei Jugendlichen und Erwachsenen bisher ausschließlich bei chronischer Vitamin A-Intoxikation gefunden, abgesehen von Stirnkopfschmerzen und seltenen generalisierten Krampfanfällen. Hervorzuheben sind vor allem Hirndruckzeichen mit beiderseitiger Stauungspapille und Liquordrucksteigerung mit Kopfschmerzen und Erbrechen, Sehstörungen in Form von Doppelbildern und Verschwommensehen, Reflexsteigerungen, Tremor, Gangstörungen sowie gelegentlich Augenmuskelerkrankungen [8, 15, 18] und Auffälligkeiten im EEG-Befund [8, 13, 15, 16], der aber auch normal sein kann [4, 6, 8, 14, 18].

Die bisher bekannten psychiatrischen Auffälligkeiten unter Vitamin A-Intoxikation bestanden in einer depressiven Symptomatik [4, 15, 18], wobei langdauernde depressive Verstimmungen mit Antiebsminderung auftraten und sich mit euphorischer Stimmungslage abwechselten. Perioden von Lethargie am

Tage mit nächtlichen Schlafstörungen bis zur Insomnie sowie Entfremdungsgefühle, Agitiertheit und Hyperakusis [18] wurden beschrieben. Diese Symptome verschwanden nach Behandlung mit Sedativa und Tranquillizern oder auch spontan nach Absetzen des Vitamin A.

Nur in einem Fall wurde bisher das Auftreten einer chronischen indifferenten schizophrenen Symptomatik im Zusammenhang mit einer Vitamin A-Intoxikation erwähnt, ohne daß eine nähere Beschreibung der Symptomatik erfolgte [18].

Über die Höhe der Dosierung und deren Dauer bis zum Eintritt der chronisch-toxischen Erscheinungen bei Erwachsenen werden sehr unterschiedliche Angaben gemacht. Sie reichen von 41 000 Mio. IE/ tägl. über 8 Jahre bis zu 200 000–275 000 Mio. IE/ tägl. mit beginnender Symptomatik nach 2 Monaten [14].

In unserem Fall waren bereits 4 Monate vor der stationären Aufnahme toxische Erscheinungen mit Verhaltensauffälligkeiten aufgetreten. Über die Höhe der damaligen Dosierung fehlen die Angaben. In den darauffolgenden Monaten waren täglich 0,9–1,2 Mio. IE Vitamin A eingenommen worden, was einer Gesamtdosis von etwa 120 Mio. IE in 4 Monaten entspricht. Diese Menge war offenbar noch toleriert worden. Erst als Ende Juli 1975 die Dosis auf 3,0 Mio. IE/Tag erhöht worden war, kam es zum Ausbruch der psychotischen Erscheinungen, die sich durch den schon vorher schlechten Allgemeinzustand bei zusätzlich hinzutretender Exsikkose noch verstärkt haben. Auch in unserem Fall ließen sich 8 der von Goeckenjan et al. beschriebenen Symptome feststellen mit Gewichtsverlust, Hautabschälungen, Haarausfall, Lippenrhagaden, Berührungsempfindlichkeit der Knochen und Gelenke, Appetitlosigkeit, Schlaflosigkeit, Otitis externa. Ferner fielen eine Harnstoffserhöhung im Serum, eine Hypercalcinose, ein auffälliger EEG-Befund sowie ein pathologischer Liquor-Befund auf. Hirndruckzeichen waren nicht vorhanden.

Ob die von uns beobachtete Liquor-Veränderung mit Erhöhung der γ -Globulin-Fraktion als Ausdruck eines chronisch entzündlichen Prozesses des ZNS angesehen werden kann, möchten wir offenlassen. Liquor-Veränderungen in Form von Pleozytosen sind bisher unter Vitamin A-Intoxikation nur im Tierversuch bekannt geworden [5], während außer in zwei Fällen von Kleinkindern mit erniedrigtem Gesamteiweiß-Wert [20] im übrigen keine Liquor-Veränderungen feststellbar waren [8, 13, 18]. Im PEG fanden sich gelegentlich kleine Ventrikel, die als Folge eines Hirnödems angesehen wurden [6, 18]. Auch eine Hyperakusis wurde beschrieben, ohne daß deren Entstehungsursache diskutiert wurde [18].

In psychiatrischer Hinsicht war es in unserem Fall zunächst zu einem mittelschweren Durchgangssyndrom gekommen [21]. Dieses hatte sich schon einige Tage vor der klinischen Aufnahme entwickelt. Es war

gekennzeichnet durch ein kritikloses Gebaren, eine motorische Antriebsminderung mit der besonderen Art der monoton ablaufenden Gedankengänge, die teilweise konfabulatorischen Charakter hatten, sowie durch Halluzinationen und Schlafstörungen. Besonders auffällig waren beschleunigt ablaufende Gedankengänge und eine große Wachheit mit Feinhörigkeit und Suggestibilität, wie sie mit Erweiterung des Bewußtseins bei gleichzeitiger Hypervigilanz und dem daraus folgenden Einfangen peripherer Sinneseindrücke und Einbau dieser Eindrücke in die psychotische Thematik auch von Arnold und Kryspin-Exner [3] bei pharmakologisch induzierten Delirien beschrieben wurden.

Pharmakogene Legorrhoeen in Form eines hastigen unaufhaltsamen Rededranges bei Bewußtseinsklarheit, Orientiertheit und motorisch ruhigem Verhalten sind ebenfalls selten beschrieben worden [1], decken sich aber ebenfalls nicht vollständig mit unserer Beobachtung, da wir zeitliche und örtliche Orientierungsstörungen fanden, wie man sie in deliranten Zuständen kennt. Zwar wird schon seit langem in Frage gestellt, ob es Bewußtseinssteigerungen gibt [12], doch gibt es Orientierungsstörungen, die ganz unabhängig vom Grade der Wachheit sind [11, 19], so daß sich das Vorliegen von Bewußtseinsstörungen mit Desorientiertheit einerseits und Steigerung der Vigilanz oder „Hypervigilanz“ andererseits nicht notwendigerweise auszuschließen brauchen.

Wir möchten annehmen, daß es in unserem Fall zusätzlich zu der beschriebenen erhöhten Suggestibilität auf akustische und optische Eindrücke noch zu einer Steigerung des Hörvermögens gekommen war, über deren Entstehungsweise nichts bekannt ist. Denkbar ist, daß es infolge einer Intoxikation zu einer „Hyperakusis“ kommt, die analog zu den Vorgängen in manchen Narkosestadien (z.B. bei Ketamin-Narkosen) zu sehen wäre.

Bei Narkosen liegt ebenfalls eine akute Intoxikation mit Bewußtseinsänderung vor. Bei der narkosebedingten „Hyperakusis“ handelt es sich vorwiegend um psychomimetische Effekte in Form von Träumen oder Halluzinationen [7] und eine Steigerung des Hörvermögens ist neurophysiologisch nicht sicher nachzuweisen.

Insgesamt ist dieses von uns beobachtete Bild dem akuten exogenen Reaktionstyp Bonhoeffers zuzuordnen und erinnert in mancher Hinsicht an den Typus der Amentia nach Jaspers. Auffällig ist, daß in den meisten Fällen, in denen psychische Auffälligkeiten erkennbar sind, die neurologische Symptomatik mit dem Symptom des Pseudotumors cerebri vorhanden ist, während in unserem Fall die psychiatrische Symptomatik ganz im Vordergrund steht und außer den EEG- und Liquorveränderungen keine neurologischen Symptome erkennbar sind.

Die bei der stationären Aufnahme vorhandene starke Exsikkose sehen wir als sekundär entstanden an, nachdem die Patientin in der Psychose ihre Nah-

rungs- und Flüssigkeitsaufnahme vernachlässigt hatte. Es ist anzunehmen, daß sich dadurch die psychotische Symptomatik noch wesentlich verstärkt hat.

Sehr fraglich erscheint dagegen, ob die beschriebene Noxe der Vitamin A-Intoxikation erst durch das Zusammentreffen mit einem bereits vorgeschädigten Gehirn (auffälliger EEG-Befund) zum Ausbruch der exogenen Psychose führen konnte. Zwar darf aus einem pathologischen EEG-Befund während der Psychose nicht auf eine Hirnvorschädigung geschlossen werden, dieser Schluß wäre aber naheliegender, wenn auch nach Abklingen der psychotischen Erscheinungen ein solcher Befund vorhanden bliebe.

Leider haben wir kein Kontroll-EEG nach der stationären Behandlung anfertigen können. Andererseits kann ein normaler EEG-Befund nach Abklingen der Psychose nicht als Beweis gegen das Vorliegen eines Hirnschadens gelten, denn es wäre auch denkbar, daß dabei durch die Noxe oder durch die Psychose ein auffälliger EEG erst provoziert wird und sich mit Beseitigung der Störfaktoren wieder normalisiert. Von Interesse in diesem Zusammenhang ist noch der folgende Hinweis: Wurden eineiige Zwillinge mit gleich hohen Dosen Vitamin A behandelt, so war bei dem Zwilling die neurologische Symptomatik wesentlich stärker ausgeprägt, bei dem der EEG-Befund noch 6 Monate nach Absetzen des Vitamin A pathologische Veränderungen aufwies [16].

Literatur

1. Allert, M.L., Broeren, W.: Experimenteller Beitrag zur pharmakogenen Logorrhoe. S. 171–174. In: Pharmakopsychiatrie u. Psychopathologie. H. Kranz u. K. Heinrich. Stuttgart: Thieme 1967
2. Aisen, V.: Schizophreniforme Psychosen mit belangvollem körperlichen Befund. Fortschr. Neurol. Psychiat. 37, 448–457 (1969)
3. Arnold, O.H., Kryspin-Exner, K.: Das experimentelle Delir. Wien. Z. Nervenheilk. 22, 73–93 (1965)
4. Di Benedetto, R.J.: Chronic Hypervitaminosis A in an Adult. J. Amer. med. Ass. 201 No. 9, 700–702 (1967)
5. Ehrenгут, W.: Hypervitaminose A, Zentralnervensystem und Infekt. Dtsch. med. Wschr. 97, 47, 1837 (1972)
6. Feldmann, M.H., Schlezinger, N.S.: Benign intracranial hypertension associated with hypervitaminosis. Arch. Neurol. (Chic.) 22, 1 (1970)
7. Frey, R., Hügin, W., Mayrhofer, L.: Lehrbuch der Anaesthesiologie und Wiederbelebung. 2. Aufl. Berlin-Heidelberg-New York: Springer 1971
8. Goeckenjan, G., Goerz, G., Pöttgen, W., Grabensee, B., Herms, W.: Lebensbedrohliche Komplikationen der hochdosierten Vit.-A-Behandlung bei Psoriasis. Dtsch. med. Wschr. 97, 1424–1429 (1972)
9. Goodman, L.S., Gilman, A.: The Pharmacological Basis of Therapeutics. Macmillan 1970
10. Helmchen, H., Hippus, H.: Therapie der organischen Psychosen. In: Psychiatrie der Gegenwart. Klinische Psychiatrie II 295–361. Berlin-Heidelberg-New York: Springer 1972
11. Huber, G.: Klinik und Psychopathologie der organischen Psychosen. In: Psychiatrie der Gegenwart. Klinische Psychiatrie II. Berlin-Heidelberg-New York: Springer 1972
12. Jaspers, K.: Allgemeine Psychopathologie. 9. Aufl. Berlin-Heidelberg-New York: Springer 1973
13. Jennkens, F.G.J., van Veelen, C.W.M.: Hypervitaminose A. Presse méd. 74, 56, 2925–2928 (1966)
14. Leicht, E., Struntz, J., Seebach, H.V., Mäusle, E., Meiser, R.J.: Akute Vitamin-A-Intoxikation mit hämolytischer Anämie, Hyperkalzämie und toxischer Hepatose. Med. Klinik 68, 2, 55–58 (1973)
15. Muechter, M.D., Perry, H.O., Ludwig, J.: Chronic vitamin A intoxication in adults. Hepatic neurologic and dermatologic complications. Amer. J. Med. 50, 129–136 (1971)
16. Mikkelsen, B., Ehlers, N., Thomsen, H.G.: Vitamin-A intoxication causing papilledema and simulating acute encephalitis. Acta Neurol. Scand. 50, 642–650 (1974)
17. Natzschka, J.: Die A-Hypervitaminose. Berl. Med. 17, 481–484 (1963)
18. Restak, R.M.: Pseudotumor cerebri. Psychosis and Hypervitaminosis. J. Nerv. Ment. Dis. 155, 72–75 (1972)
19. Scheller, H.: Über das Wesen der Orientiertheit. Nervenarzt 34, 1–4 (1963)
20. Siegel, N.J., Spackman, T.J.: Chronic hypervitaminosis A with intracranial hypertension and low cerebrospinal fluid concentration of protein. Clin. Ped. 11, 580–584 (1972)
21. Wieck, H.H.: Lehrbuch der Psychiatrie. Stuttgart: Schattauer 1967
22. Wissenschaftliche Tabellen. Documenta Geigy. 6. Aufl. 1960

Dr. R. Haupt
Krankenanstalten Sarepta
Bethesdaweg
D-4800 Bielefeld 13

Benign Intracranial Hypertension due to A-Hypervitaminosis in Adults and Adolescents

A Review

A. LOMBAERT and H. CARTON

Department of Neurology and Neurosurgery, A. Z. Sint-Rafaël,
University of Leuven, Leuven

Key Words. Vitamin A · A-hypervitaminosis · Intracranial hypertension · Pseudotumor cerebri · Intracranial murmur · Cerebrospinal fluid

Abstract. Three new cases of chronic vitamin A intoxication are reported and a review of the literature with special reference to chronic intoxication in adolescents and adults is presented. The most prominent features are intracranial hypertension, skin and hair deviations, pain in the musculoskeletal system, and fatigue. Intracranial hypertension occurs in 50% of chronic intoxications, but is not invariably linked with the other symptoms. Young women are the major age group represented. There seems to be no relation between the severity of the clinical picture and the vitamin A serum level. Discontinuance of vitamin A intake is sufficient for cure.

Introduction

In the 16th century, Gerrit De Vries most probably reported, for the first time, the symptoms of vitamin A intoxication: a group of Dutchmen wintering on Nova Zembla complained of headache, dizziness, vomiting and scurfy skin, after eating bear liver. In 1943 Rodahl and Moore attributed the toxicity of polar bear liver to the large amounts of vitamin A present: 13,000-18,000 IU/g vitamin A. In 1954 the first cases of benign intracranial hypertension (BIH) due to hypervitaminosis A in children as well as in adults were reported [MARIE and SEE, 1954; GERBER and RAAB, 1954]. Three new cases of chronic vitamin A intoxication will be report-

Received: September 26, 1975; accepted: October 8, 1975.

U. OF ILL. CHICAGO

ed, one of which had a special symptom, i.e., a cranial murmur. We thereafter present a review of the literature with special reference to chronic intoxication in adolescents and adults.

Case Reports

Case 1

A. L., a 16-year-old girl, was admitted for headache persisting over 4 months, and for a 1-week existing diplopia. Over the last year, this patient had taken 300,000 IU vitamin A daily because of her acne. Physical examination revealed a bilateral sixth nerve paresis and papilloedema. Further neurologic and internal examinations were normal, as were the results of the lab analyses. The EEG record showed slight, nonspecific disturbances. Brain scanning, X-ray skull examination, right carotid angiography, and iodiventriculography were normal. One month after discontinuing the vitamin A intake, headache and diplopia subsided.

Case 2

D. M.-L. W., 41, female, complained of tired right eye existing for 1 week. For 6 months, the patient had been taking 100,000 IU of vitamin A daily because of her acne. Clinical examinations revealed bilateral papilloedema with suffusions and nystagmus when looking aside. She was obese (128 kg). The EEG showed diffuse disturbances; echoencephalography and combined iodi- and airventriculography were normal. Apart from unchanged obesity, the patient was completely cured 8 months after discontinuance of vitamin A intake.

Case 3

M. M., 19, female, was admitted complaining of a blowing murmur in both ears, synchronic with the pulse, which had been present for 5 weeks. Since 2 weeks a throbbing frontal headache had developed and since then the patient was somnolent and tired. Horizontal diplopia had started a week previously. Furthermore, the patient complained of a dry, bursting skin and dry, chapped lips. She had been taking 300,000 IU of vitamin A daily for 2 years because of acne.

Clinical examination revealed a bilateral papilloedema (RE 2 D; LE 1 D) with suffusions, enlargement of blind spot, and a sixth nerve paresis on the right. The lips were dry and chapped; at the site of the arms, the skin was dry and squamous. In addition, a holocranial murmur with a peak in the right temporal region and synchronic with pulse was found. It decreased in intensity on turning the head to the left and subsided when the right carotid artery was pressed. The murmur could be heard on auscultation over the whole skull and could be recorded phonocardiographically (fig. 1).

The EEG showed only slight diffuse disturbances; brain scanning, X-ray skull examination and cerebral angiography were normal. The vitamin A levels in the plasma were elevated (fig. 2). Four weeks after discontinuing the medication, headache, papilloedema, diplopia and murmur were no longer present.

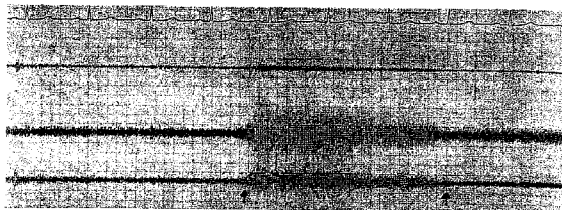


Fig. 1. The murmur was most pronounced at the skull and subsided by pressing the right carotid. The arrows indicate release and compression of the carotid. Murmur is recorded at the temporal region.

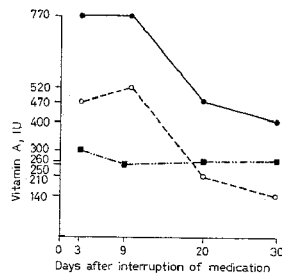


Fig. 2. Vitamin A plasma level in case M. M. Plasma levels of vitamin A were elevated. Within a few days after discontinuance of vitamin A, the levels returned to nearby normal values. Normal values of vitamin A in plasma (IU): alcohol fraction: 50–150 IU/100 ml. ● = Total; ■ = alcohol fraction; ○ = ester fraction.

Review of Literature

In the literature we found 19 cases of acute and 38 cases of chronic vitamin A intoxication in adults and adolescents.

Clinical Picture

Acute intoxication. It is generally due to the intake of high amounts of vitamin A in the form of seal liver or drugs [FURMAN, 1973; GOECKENJAN

et al., 1973; LAPLANE *et al.*, 1953; NATER and DOEGLAS, 1970]. The symptoms are: severe headache, nausea, vomiting, dizziness, diarrhoea, and a squamous skin. Epileptic attacks are reported three times [CLELAND and SOUTHCOTT, 1969; LAPLANE *et al.*, 1953]. Only in two patients was papilloedema described [LAPLANE *et al.*, 1953; FURMAN, 1973], while in 14 others papilloedema was suspected. Three patients showed no papilloedema.

Chronic Intoxication

Complaints and symptoms. The age range varied from 14 to 62 years, with the highest incidence in patients from 14 to 20 years old (fig. 3). Pseudotumor cerebri is particularly found in the second decade, decreasing abruptly in patients of the third and fourth decades (fig. 4). The large majority of patients with vitamin A intoxication and intracranial hypertension are women.

Oto-neuro-ophthalmic picture (table I): the most prominent characteristic of the neurological picture is intracranial hypertension, occurring in more than half of the patients. Headache, nausea, diplopia, papilloedema, enlarged blind spot and sixth nerve paresis are the major complaints and symptoms. In 6 of 7 patients who underwent a lumbar puncture, the CSF pressure was increased. Psychiatric disorders range from loss of interest to true psychosis [RESTAK, 1972]. Prooptosis is rare, as is pulsation of the eyeballs which was only mentioned once [BIFULCO, 1953]. An ear murmur was also reported once [FEDOTIN, 1970]. The skin is affected in about half the cases: loss of hair, dry squamous skin, yellowish-brown spotty pigmentation, pruritus, and dry, chapped lips. [FELDMAN and SCHLEZINGER, 1970; MORRICE *et al.*, 1960]. In one fifth of the cases, painful blisters and superficial ulcerations in the oral mucosa were noted.

Fatigue and anorexia are a frequent complaint and weight loss is often found [MORRICE *et al.*, 1960]. Rather frequent are hypo- and amenorrhoea. Polyuria and polydipsia are reported three times. In about one fifth of the cases sedimentation is accelerated. Hepatomegaly and splenomegaly are also observed and may even be accompanied by ascites [RUSSELL *et al.*, 1974; KATZ and TZAGOURNIS, 1972]. At various times, liver function tests showed deviations; pathological changes primarily occurred in the BSP and PTT tests. Four patients showed cirrhosis-like lesions on biopsy [MUENTER *et al.*, 1971; RUSSELL *et al.*, 1974].

In more than half of the case reports, pain in the musculoskeletal system is mentioned. Spontaneous or provoked pain of the bones, muscle

LOMBAERT/CARTON

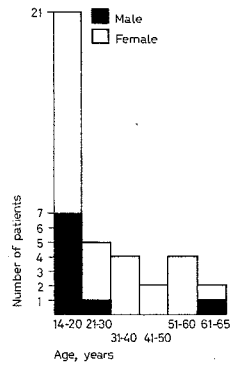


Fig. 3. Age and sex distribution in chronic hypervitaminosis A.

U. OF ILL. CHICAGO




Fig. 4. Benign intracranial hypertension due to chronic vitamin A intoxication. Age and sex distribution.

Table I. Oto-neuro-ophthalmic symptoms and signs in 38 patients with chronic hypervitaminosis A

Symptoms	%	Signs	%
Headache	58	Papilloedema	53
Double vision	34	Psychiatric disturbances	29
Impaired vision	24	Vomiting	24
Disturbed sleep	21	Enlargement of blind spot	21
Nausea	18	Sixth nerve palsies	18
Tinnitus	5	Elevation of CSF pressure	16
Rubbing sound	5	Prooptosis	10
		Nystagmus	10
		Intracranial bruit	3

Table II. General symptoms and signs in 38 patients with chronic hypervitaminosis A

	Male	Female	Total
ICH proved	0	6	6
ICH proved + other symptoms	4	11	15
ICH suspected + other symptoms	0	2	2
No ICH	5	10	15
	9	29	38

ICH = Intracranial hypertension.

pain following exertion or pain in the joints. Swelling of the ankles may be seen [TURTZ and TURTZ, 1960].

One fourth of the patients complained of spontaneous bleedings, usually at the site of nasal or oral mucosa [TEO *et al.*, 1973; SMITH, 1964], and once at the site of the ankle [ELLIOT and DRYER, 1956]. Imperious compulsion, increased frequency and nycturia are less frequent.

Technical examinations. The vitamin A content in the blood – when examined – is always elevated, with limits ranging from 165 to 2,000 $\mu\text{g}/100$ ml [BERGEN and ROELS, 1965; GERBER and RAAB, 1954]. The normal values range from 30 to 70 $\mu\text{g}/100$ ml.

Disturbances of the Ca-metabolism were mentioned six times. On X-ray examination, calcification of the ligaments, decalcification of vertebrae and thickening of the long bones may be seen [WIELAND *et al.*, 1971; SHAW and NICOLI, 1953; PARENT, 1969]. Biopsies of the bone show, in

those cases, calcifications of cartilage tissue, thickening of the periost [GERBER and RAAB, 1954] and a predominance of bone resorption over bone formation [JOWSEY and RIGGS, 1968].

X-ray skull, carotid and vertebral arteriographies, iodiventriculographies, pneumo-encephalographies, brain scanning and ECHO encephalographies are always reported as normal, whereas the EEG may show diffuse, non-specific disturbances in some patients.

Dose and Duration of Vitamin-A Intake

Daily doses of vitamin A reported to have been responsible for chronic intoxication range from 40,000 to 600,000 IU. Complaints and symptoms may appear as early as 4-6 weeks or as late as 7 years after continuous intake of vitamin A [JENNEKENS and VAN VEELEN, 1966; STIMSON, 1961; WISSE-SMIT and POTT-HOFSTEDE, 1966]. Large long-term intake of vitamin A is always related to a treatment, particularly of skin diseases, mostly acne (16 cases).

Therapy and Prognosis

Prognosis for vitamin A intoxication is good, provided the intake of vitamin A is discontinued: headache appears to stop after a few days; a few weeks later, general condition and skin lesions improve, and also papilloedema - which may last for months - will completely disappear in the end. Ureum or acetazolamide do not seem to accelerate the healing process. A transient improvement by means of steroids is reported once.

Discussion

The most prominent features of chronic, as well as of acute vitamin A intoxication are intracranial hypertension, skin and hair deviations, pain in the musculoskeletal system and fatigue. These signs and symptoms are not invariably linked: in six patients, intracranial hypertension occurred separately [GELPKKE, 1971; LASCARI and BELL, 1970] whereas no intracranial hypertension was found in 15 patients with dermatological problems (table III) [DI BENEDETTO, 1967; RAASCHOU-NIELSEN, 1961; SOLER-BECHARA and SOSCIA, 1963].

We are not aware of any systemic study on the neurological complications of patients chronically treated with vitamin A. Considering the great number of persons taking high doses of vitamin A and the limited number



Table III. Combination of benign ICH and other symptoms in chronic hypervitaminosis A (%)

Pain in joints, bone, muscles	58	Skin Desquamation	45
Fatigue	53	Changes in appearance	47
Pruritus	37	Dry, cracked lips	39
Anorexia	34	Rash	20
Spontaneous bleeding	24	Pigmentation	18
Changes in menstruation pattern	28	Oral abnormalities	20
Cystitis-like complaints	10	Hepatomegaly	37
Polyuria and polydipsia	8	Splenomegaly	18
Craving	3	Increased sedimentation rate	20
Weight loss	24	Ca-disturbances	10
Hair-changes	47	RX changes in bones	10

We consider ICH proved when papilloedema is found and/or CSF pressure is increased. ICH is suspected when the patient complained of headache, vomiting and dizziness but no objective signs of ICH could be found.

of reported cases of vitamin A-induced BIH, this complication must certainly be exceptional. Furthermore, among the several factors established to be responsible for BIH the incidence of hypervitaminosis A is very small.

Indeed, in a review study on the aetiology of BIH, hypervitaminosis A cellaneous', and constitute only 5.2% of the aetiological factors involved [JOHNSTON and PATERSON, 1974a]. On the other hand, in our own series of 16 consecutive patients with BIH vitamin A was identified as the aetiological factor in three.

BIH as well as the general clinical picture of A-hypervitaminosis mainly occur in the second decade with a striking preponderance of female patients.

Although pseudotumor cerebri is known to be 4-8 times more frequent in the female, especially in patients in their twenties or thirties, the greater number of young women taking vitamin A for beauty reasons may be the explanation rather than female predisposition for BIH.

A classical distinction is made between intoxications in adults and those in children. However, there being no clear-cut differences, this distinction appears to us rather artificial. In new-borne babies, intracranial hypertension is reflected more by protrusion of the fontanel, rather than by papilloedema. In children craniotabes may occur, while radiographic changes of the skeleton are more frequent [KNUDSON, 1953].

The finding of cerebral murmur in an adult with BIH is most unusual and has never been documented. However, it has been reported in children with raised intracranial pressure. As suggested by MACKENZIE [1955] the mechanism involved is a relative stenosis of the carotid arteries, being compressed against the floor of the skull as a result of the increased intracranial pressure.

Individual sensitivity to vitamin A varies greatly: chronic intoxication may occur after taking 50,000 IU daily for a few months [STIMSON, 1961]; another patient showed intoxication symptoms only after having taken 40,000 IU daily over several years [BERGEN and ROELS, 1965] and another one after having taken 600,000 IU after 1/2 year [SULZBERGER and LAZAR, 1951]. The vitamin A content in the blood is always elevated in case of intoxication. Yet there is no relationship between the plasma level and total dose, nor between the former and severity of the clinical picture. After discontinuance of the vitamin A intake, the plasma level decreased to markedly lower values within a few days, without reaching normal limits in the first few months. The discrepancy between vitamin A plasma level and severity of the clinical picture suggests that not the extracellular vitamin A but probably an intracellular metabolite may be involved in the clinical picture.

Few data exist on the pathophysiology of vitamin A induced intracranial hypertension. Calves with a vitamin A deficiency show structural changes at the site of the arachnoidal villi, making the absorption of cerebrospinal fluid more difficult [EATON, 1969; HAYES *et al.*, 1971].

It has been suggested that deviations of the vitamin A level in man would alter the structure of the arachnoidal villi in a similar way, thus, the absorption of cerebrospinal fluid would be decreased likewise [JOHNSTON and PATERSON, 1974a, b]. The vitamin A level was also determined in the cerebrospinal fluid of children with A-hypervitaminosis; vitamin A was never detected in the fluid [MARIE and SEE, 1954]. Prognosis for vitamin A intoxication is good provided vitamin A intake is discontinued. Neurologic sequelae were never noticed. The cure of intracranial hypertension is not shortened by administering anti-oedema medication.

References

- BERGEN, S. and ROELS, O. A.: Hypervitaminosis A. Report of a case. *Am. J. clin. Nutr.* 16: 265-269 (1965).

U. OF ILL. CHICAGO

- BIFULCO, E.: Vitamin A intoxication. Report of a case in an adult. *New Engl. J. Med.* 248: 690-692 (1953).
- CLELAND, J. B. and SOUTHCOTT, R. V.: Illnesses following the eating of seal liver in Australian maters. *Med. J. Aust. i:* 760-763 (1969).
- DI BENEDETTO, R. J.: Chronic hypervitaminosis in an adult. *J. Am. med. Ass.* 201: 700-702 (1967).
- EATON, H. D.: Chronic bovine hypo- and hypervitaminosis A and cerebrospinal fluid pressure. *Am. J. clin. Nutr.* 22: 1070-1080 (1969).
- ELLIOT, R. A. and DRYER, R. L.: Hypervitaminosis A. Report on a case in an adult. *J. Am. med. Ass.* 161: 1157-1159 (1956).
- FELDMAN, M. H. and SCHLEZINGER, N. S.: Benign intracranial hypertension with hypervitaminosis A. *Archs Neurol.* 22: 1-7 (1970).
- FEDOTIN, M. S.: Hypervitaminosis causing pseudotumor cerebri. *J. Am. med. Ass.* 212: 628 (1970).
- FURMAN, K. I.: Acute hypervitaminosis A in an adult. *Am. J. clin. Nutr.* 26: 575-577 (1973).
- GELPKE, P. M.: Vitamin A intoxication. *Can. med. Ass. J.* 104: 533 (1971).
- GERBER, A. and RAAB, A. R.: Vitamin A poisoning in adults. With description of a case. *Am. J. Med.* 16: 729-745 (1954).
- GOECKENJAN, G.; GOERZ, G.; POTTGEN, W.; GRABENSEE, B. und HERMS, W.: Lebensbedrohliche Komplikationen der hochdosierten Vitamin-A-Behandlung bei Psoriasis. *Dt. med. Wschr.* 97: 1424-1429 (1973).
- HAYES, K. C.; MCCOMBS, H. L. and FAHERTY, T. P.: The fine structure of vitamin A deficiency. II. Arachnoid granulation and CSF pressure. *Brain* 94: 213-224 (1971).
- JENNEKENS, G. F. I. and VEELLEN, C. W. M. VAN: Hypervitaminose A. *Presse méd.* 74: 2959-2928 (1966).
- JOHNSTON, I. and PATERSON, A.: Benign intracranial hypertension. I. Diagnosis and prognosis. *Brain* 97: 289-300 (1974a).
- JOHNSTON, I. and PATERSON, A.: Benign intracranial hypertension. II. CSF pressure and circulation. *Brain* 97: 301-312 (1974b).
- JOWSEY, J. and RIGGS, B. L.: Bone changes in a patient with hypervitaminosis A. *J. clin. Endocr. Metab.* 28: 1833-1835 (1968).
- KATZ, C. M. TZAGOURNIS, M.: Chronic adult hypervitaminosis A with hypercalcemia. *Metabolism* 21: 1171-1176 (1972).
- KNUDSON, A. G. and ROTHMAN, P. E.: Hypervitaminosis A. *Am. J. Dis. Child.* 85: 316-334 (1953).
- LASCARI, A. D. and BELL, W. E.: Pseudotumor cerebri due to hypervitaminosis A. Toxic consequence of self-medication for acne in an adolescent girl. *Clin. Pediat.* 9: 627-628 (1970).
- LAPLANE, R.; DUCHE, D.; JALLUT et SELIGMANN, M.: Oedème aigu cérébroméningé résolutif chez un garçon de 16 ans ayant absorbé une dose massive de vitamine A. *Archs fr. Pédiat.* 10: 979-982 (1953).
- MCKENZIE, I.: The intracranial bruit. *Brain* 78: 350-368 (1955).
- MARIE, J. and SEE, G.: Acute hypervitaminosis A of the infant. Its clinical manifes-

- tation with benign acute hydrocephaly and pronounced bulge of the fontanel. A clinical and biologic study. *Am. J. Dis. Child.* 73: 731-736 (1954).
- Mikkelsen, B.; Ehlers, N., and Thomsen, H. G.: Vitamin A intoxication causing papilloedema and simulating acute encephalitis. *Acta neurol. scand.* 50: 642-650 (1974).
- Morrice, G.; Havener, W. H., and Kapetansky, F.: Vitamin A intoxication as a cause of pseudotumor cerebri. *J. Am. med. Ass.* 173: 1802-1805 (1960).
- Muenter, M. D.; Perry, H. O., and Ludwig, J.: Chronic vitamin A intoxication in adults. Hepatic, neurologic and dermatologic complications. *Am. J. Med.* 50: 129-136 (1971).
- Nater, J. P. and Doeglas, H. M. G.: Acute vitamine A intoxicatie. *Ned. Tijdschr. Geneesk.* 114: 1789-1800 (1970).
- Parent, G.: Hypervitaminose A et œdème papillaire. *Bull. Soc. belge Ophtal.* 596-603 (1969).
- Raaschou-Nielsen, W.: Chronic intoxication with vitamin A in adults, with report of a case. *Dermatologica* 123: 239-300 (1961).
- Restak, R. M.: Pseudotumor cerebri, psychosis and hypervitaminosis A. *J. nerv. ment. Dis.* 155: 72-75 (1972).
- Russell, R. M.; Boyer, J. L.; Bagheri, S. A., and Hruban, Z.: Hepatic injury and chronic hypervitaminosis A. *New Engl. J. Med.* 291: 435-440 (1974).
- Shaw, E. W. and Niccoli, J. Z.: Hypervitaminosis A. Report of a case in an adult male. *Ann. intern. Med.* 39: 131-134 (1953).
- Smith, J. H.: Hypervitaminosis A. *Oral Surg.* 17: 305-307 (1964).
- Soler-Bechara, J. and Soccia, J. L.: Chronic hypervitaminosis A. Report of a case in an adult. *Archs intern. Med.* 112: 58-62 (1963).
- Stimson, W. H.: Vitamin A intoxication in adults. Report of a case with a summary of the literature. *New Engl. J. Med.* 265: 369-373 (1961).
- Sulzberger, M. B. and Lazar, M. P.: Hypervitaminosis A. Report of a case in an adult. *J. Am. med. Ass.* 146: 788-793 (1951).
- Teo, S. T.; Newth, M. B., and Pascoe, B. J.: Chronic vitamin A intoxication. *Med. J. Aust.* ii: 324-326 (1973).
- Turtz, C. A. and Turtz, A. I.: Vitamin A intoxication. *Am. J. Ophthal.* 50: 165-166 (1960).
- Wieland, R. G.; Hendricks, F. H.; Amatyleon, F.; Gutierrez, L., and Jones, J. C.: Hypervitaminosis A with hypercalcaemia. *Lancet* i: 689 (1971).
- Wisse-Smit, J. and Pott-Hofstede, D.: Vitamine A intoxicatie bij volwassenen. *Ned. Tijdschr. Geneesk.* 110: 10-11 (1966).

Dr. H. Carton, Department of Neurology and Neurosurgery, Akademisch Ziekenhuis Sint-Rafaël, Kapucijnenvoer 35, B-3000 Leuven (Belgium)

VITAMIN A*Excess, Deficiency, Requirements,
Metabolism and Misuse*

IDA G. BRAUN, M.D.

About 12 years ago in France 3 infants suddenly exhibited anorexia, vomiting, somnolence and a "mushroom-like" elevation of the anterior fontanel persisting for only one day.¹⁸ A few years later a young woman who had been hospitalized 10 times in 8 years for symptoms of increased intracranial pressure was finally relieved within a few days after the correct diagnosis had been made.¹¹ Treatment for all four patients was simply discontinuing the administration of vitamin A. These are but a few of the more than 50 reported patients who have suffered hypervitaminosis A since the condition was first described by Josephs¹⁵ in 1944.

At a time when lack of vitamin A is responsible for widespread disease and blindness in many parts of the world,¹⁶ medical literature of Western countries contains more articles concerning the effects of vitamin A excess. The natural sources of this vitamin and the carotenoid pigments which are its precursors are so plentiful that an adequate diet will contain ample quantities without supplementation. In the better developed countries, therefore, deficiency symptoms are found almost exclusively in patients who have disorders of fat absorption or liver function.¹⁴

Because the body can store and break down relatively large amounts of vitamin A, normal dietary sources do not provide quantities sufficient to cause symptoms of intoxication. It is only since vitamin concentrates have become readily available to physicians and patients alike that hypervitaminosis A has become more common. The manifestations of acute and chronic poisoning differ, and both have been described in patients of all age groups.

From the Bruce Lyon Memorial Research Laboratory, Children's Hospital of the East Bay, Oakland, Calif.

ACUTE HYPERVITAMINOSIS A

The earliest descriptions of acute toxicity from vitamin A ingestion, dating back as far as 1596, are those of Arctic explorers who, despite warnings from natives, partook heartily of polar bear liver and found it "more savory than fat."¹⁷ Within hours they experienced extremely severe headaches, vertigo, abdominal pain, vomiting and diarrhea. The next day these symptoms were replaced by desquamation around the mouth, on exposed areas and occasionally generalized. Within a few days they were again in normal health. Many years later analysis of polar bear livers disclosed that the extremely high vitamin A content was toxic for experimental animals, and that the concentration was such that a man might very well eat a portion containing several million units in a single meal. Other exceptionally rich sources are the livers of seals, sharks, halibut and percomorph fishes, none of which is sufficiently common in the American diet to present a clinical hazard.

More recently adults who have ingested a single dose of several million units of vitamin A have taken purified concentrates. Some have had symptoms similar to those of the explorers, including involvement of both the central nervous system and the gastrointestinal tract. Others remained unaffected, suggesting that individuals vary in their sensitivity to vitamin A toxicity.¹⁸

The infants referred to in the opening sentence also manifested acute intoxication. Each had been given the eutic contents of an ampule of vitamin A concentrate containing 350,000 units. Their symptoms were similar: vomiting, which was sometimes profuse, lassitude, sleepiness and anorexia, followed by the appearance of a knoblike bulge over the anterior fontanel without signs of meningitis. One day later the children again appeared normal. The specific type of vitamin A concentrate which these infants were fed caused more than 40 similar cases in France and Spain before the dose per ampule was decreased to 70,000 units.⁴

Although the most dramatic manifestations of acute toxicity from vitamin A result from elevated intracranial pressure, skin involvement is also common, and consists usually of desquamation, either localized or generalized. The acute episode is often accidental, e.g., after a child has drunk a whole bottle of vitamin A concentrate, and is a self-limited process which is unlikely to be repeated. No permanent sequelae have been reported.

Most of the concentrated forms of vitamin A also contain vitamin D. In the reported cases of hypervitaminosis A, all the abnormal findings could be attributed to the vitamin A alone. The vitamin D excess was apparently insufficient to cause symptoms. Investigators have duplicated both the acute and the chronic syndrome by administering purified vitamin A experimentally to human subjects.^{19, 20}

CHRONIC HYPERVITAMINOSIS A

A more confusing diagnostic picture is presented after prolonged ingestion of excessive quantities of vitamin A. Since the general public and apparently even some physicians are not aware of the danger of long exposure to moderately high doses, probably many more cases have occurred than the 40 or more patients reported in the literature would indicate. Some of the patients originally were given vitamin A by a physician for the treatment of acne or other skin disorders, and without the physician's awareness continued the medication, and sometimes even increased the dose. In other instances mothers who thought that they were giving cod liver oil (850 units per milliliter) instead gave percomorph oil (60,000 units per milliliter) or halibut liver oil (60,000 units per milliliter) or increased the dose of vitamin concentrate from 10 drops to a teaspoonful.⁴ One adult patient was so impressed by a radio advertisement of vitamin A for "dry throat and colds" that she took 600,000 units daily for 18 months.²¹

In adult patients, fatigue was a universal early symptom, and was often followed by bone pain, loss of hair, desquamation, anorexia and hepatomegaly. Involvement of the central nervous system often caused a delay in reaching the diagnosis.

The most extreme example of this delay was the young lady mentioned in the beginning.²² She was hospitalized 10 times in 6 hospitals during 3½ years, and was diagnosed as having brain tumor, serous meningitis, chronic encephalitis, and psychoneurosis. Her skin manifestations included pruritus, pigmentation, coarsening of the hair and alopecia. She was subjected to various treatments, including subtemporal decompression to relieve increased intracranial pressure, and spent months in body spicas to alleviate bone pain. During this entire time she continued to take 500,000 units of vitamin A daily for "ichthyosis." When the source of her trouble was finally recognized, her blood vitamin A level was 6600 units per 100 ml, the highest ever reported and approximately 60 times the normal level. Discontinuing the vitamin was followed within days by relief of her neurologic, skeletal and skin symptoms, and, therefore, dramatically confirmed the correctness of the diagnosis.

A less extreme example is that of 3 adolescent girls who presented diplopia and papilledema after taking from 90,000 to 200,000 units of vitamin A daily for acne.¹⁹ They also had alopecia, nonspecific dermatitis (in addition to their unimproved acne), migratory arthralgia, hepatomegaly and hypomenorrhea. They were given neurosurgical investigation only because their symptoms cleared within a few days of entering the hospital and discontinuing vitamin A, although in at least one of the girls the papilledema persisted another four to six months.

Also, in young children the central nervous system manifestations may be prominent. Several have been reported with craniofacial and

hydrocephalus,^{1, 4, 12} which resolved when vitamin A was discontinued. Hydrocephalus also has been produced in a young puppy by vitamin A.¹³ Although the mechanism causing the increased intracranial pressure is unknown, several authors attribute it to increased production of cerebrospinal fluid.^{14, 15} The fact that deficiency of vitamin A also may result in elevation of cerebrospinal fluid pressure is confusing.²

Most of the patients with chronic hypervitaminosis A show nonspecific presenting symptoms. Anorexia, failure to gain weight, and pruritus are common early signs. The pruritus seems to be due to the presence of excess vitamin A in the skin, but the mechanism is unknown.¹¹ It is noteworthy that deficiency of vitamin A may cause squamous metaplasia, while excess may cause hyperkeratosis.^{11, 14}

As intoxication continues, bone involvement becomes a prominent feature. Both adults and children have bone pain, but most children show x-ray changes, while only one adult has had abnormal osseous roentgenograms.^{11, 14} In children tender swellings of many bones are common, and use of the limbs may be painful. Several children described a feeling of "walking on rocks."¹⁶ The x-ray findings resemble those of infantile cortical hyperostosis, with subperiosteal new bone, cortical thickening and poor modeling of long bones. Caffey,⁶ who described some of the distinguishing features of the two syndromes, earlier had confused them.³ The diseases can be distinguished clinically by age at onset, systemic signs, sites of involvement, response to treatment, and skin changes, as may be seen in Table 8.

The epidermal changes reported in vitamin A poisoning include seborrhea, cracking lips and varying degrees of alopecia. The hair is usually coarse and "difficult to manage" for some time before it starts to fall out. The eyebrows and body hair may also be lost. Regrowth is prompt when vitamin administration is stopped.

Since vitamin A is stored in the liver, it is not surprising that

hepatomegaly is a common finding in hypervitaminosis A.¹⁰ The liver gradually returns to normal size as stores are utilized, and no late signs of hepatic toxicity have been reported. Splenomegaly is more difficult to explain and has only rarely been described.^{10, 24}

Few patients have had increased bleeding tendency, which was relieved by vitamin K administration.³ On the other hand, hypomenorrhea has been reported, with scanty periods at normal intervals.¹⁴

The symptoms of hypervitaminosis A in human subjects are similar to those reported in experimental animals.²⁰ The investigators who established the toxicity of polar bear liver had some difficulty in making the rats eat enough liver to poison themselves, thereby suggesting that rats know what is good for them better than human beings do. The few that did ingest large enough quantities manifested skin changes and died with internal hemorrhages. The bones of the rats became more fragile and susceptible to pathologic fractures, and did not show the hyperostosis characteristic of the young child.

Administration of excess vitamin A to pregnant rats and mice is a reliable method for producing congenital anomalies in the young, usually of the central nervous system and the skeleton. The anomalies produced are similar to those in offspring of rats deficient in vitamin A.^{8, 10} Whether comparable dangers exist for pregnant women is not known.

LABORATORY DATA IN HYPERVITAMINOSIS A

Of the many laboratory tests performed on patients with hypervitaminosis A, few have been helpful in diagnosis. Blood cell counts, urinalyses and determination of serum electrolyte and cerebrospinal fluid chemistries have been normal. In contrast to hypervitaminosis D, both calcium and phosphorus levels in the serum have also been normal. Liver function tests have been unaltered, although a mildly elevated globulin level has on occasion caused the albumin-globulin ratio to approach 1. In children the alkaline phosphatase activity has usually been high, but whether this reflects hepatic or bone involvement is not known.

The only specific and consistent change has been elevation of the serum vitamin A level in all patients in whom it was determined. The normal range is 50 to 150 I. U. per 100 ml; few patients had values below 500 I. U., most were between 800 and 2000 I. U., and one was reported at 6600 I. U.^{4, 11} When vitamin A was discontinued, the serum level dropped rapidly to approach normal levels, but often remained slightly elevated for many months.

HYPOVITAMINOSIS A

Although this discussion emphasizes the effects of excess vitamin A, it seems worth while to consider briefly the manifestations of de-

TABLE 8. Differentiation of Hypervitaminosis A from Infantile Cortical Hyperostosis

DIFFERENTIATING CHARACTERISTICS	HYPERVITAMINOSIS A	INFANTILE CORTICAL HYPEROSTOSIS
Age at onset	May occur at any age; usually only once before 6 months	Usually before 4 months; once reported at birth
Bones most frequently involved	Ulnus, metatarsals, tibiae, fibulae, clavicles	Mandible, scapulae, clavicle
Skin	Seborrhea, alopecia, and others	Hyperkeratosis, scaling over bones, sometimes discoloration
Systemic signs	Alopecia	Fever
Laboratory data	Serum vitamin A level elevated	Serum vitamin A level normal
Response to therapy	All symptoms relieved by stopping vitamin A	No change on stopping vitamin A; questionable benefit from steroids

deficiency. Hypovitaminosis A has long been known, but the problems it causes are by no means solved. A recent international conference on nutritional disease describes them dramatically.¹⁶ See also page 897.

The organ most sensitive to deprivation of vitamin A is the eye. Vitamin A is a constituent of rhodopsin, also known as visual purple, which is necessary for night vision. Night blindness has been known since the time of the ancient Egyptians and Greeks. Evaluation of night vision has been useful as a type of vitamin A assay in areas where deficiency is frequent, but in the more prosperous countries it is not sufficiently discriminating.

When vitamin A deficiency is permitted to continue, xerophthalmia and keratomalacia appear, and cause blindness if treatment with vitamin A is not begun promptly. This is a medical emergency, and unfortunately many children in parts of India, Indonesia and South and Central America are permanently blind because treatment was delayed a few days too long.

Other epithelial tissues show keratinizing metaplasia when vitamin A is lacking. The resulting loss of differentiation increases the susceptibility to infection, causes hyperkeratosis of the skin, and may predispose to the formation of vesical calculi. All these effects are reversed by adequate vitamin A.

Clinically, vitamin A deficiency is always accompanied by unusually low levels of vitamin A in blood. When liver stores are adequate, the normal range of 50 to 150 I. U. per 100 ml. can be maintained for months, and experimental deficiency is, therefore, difficult to induce in previously well fed persons.

VITAMIN A REQUIREMENT

The precise requirements for vitamin A are difficult to establish with certainty since absorption is variable. The daily dietary allowances recommended by the Food and Nutrition Board of the National Research Council are generous enough so that even persons with suboptimal absorption may stay free of deficiency symptoms and maintain normal blood levels (Table 9). See also page 896.

The patients reported with chronic hypervitaminosis A had intakes ranging from 80,000 to 600,000 units daily.¹⁷ Even with such excessive doses, symptoms did not become evident for several months. Ap-

TABLE 9. Recommended Daily Allowances

0-1 year	1500 u./day
1-3 years	2000 u./day
4-6 years	2500 u./day
7-9 years	3500 u./day
10-12 years	5000 u./day
13 and over	5000 u./day

Food and Nutrition Board, National Research Council, 1958.¹⁸

parently only when both the liver's capacity for storage and the body's mechanisms for destroying vitamin A are exceeded does hypervitaminosis A occur. The effect of the excess vitamin seems to be a generalized interference with cellular metabolism, and is thought to differ from the direct toxic effect observed with acute hypervitaminosis.¹⁸ In the latter condition, the toxic doses have ranged from 350,000 I. U. in infants to several million units in adults.

METABOLISM OF VITAMIN A

Vitamin A can enter the human body either as the vitamin itself or as its precursor, carotene. Carotene is widely distributed in vegetables of both the yellow and the green varieties. It can be broken down in the intestinal mucosa to two molecules of vitamin A. Given doses of carotene are not comparable to twice the dose of vitamin A, however, because the absorption is considerably less complete. In the normal American diet, carotene supplies approximately two thirds of the dietary intake of vitamin A. In the body, carotene is slowly converted to vitamin A and xanthom causes elevated levels of this vitamin even when carotenemia exists.¹⁹ Carotene itself is relatively nontoxic, and carotenemia occurs frequently in infants 6 to 12 months of age without causing any changes other than yellowness of the skin. In severe cases, however, elevated serum lipids and slightly depressed basal metabolic rates have been reported.¹⁸

Performed vitamin A comes from animal sources, including particularly the liver and egg yolk. Whole milk is an adequate source, and in an entirely breast-fed infant whose mother has a normal vitamin A level no supplementation is necessary.

Although the liver is the main storage site for vitamin A, many other tissues contain lesser amounts, including the kidneys and skin. The catabolism of vitamin A is poorly understood. It is not excreted as such in the urine, even after excessive intakes.¹⁹ Neither has it been detected in the cerebrospinal fluid of the infants with severe manifestations of increased intracranial pressure.¹⁸

MISUSE OF VITAMIN A

In the previously described cases the evidence for toxicity from excess vitamin A was clearcut; the signs were characteristic, the blood levels were confirmatory, and response to discontinuing medication was dramatic. The source was often the physician, who prescribed excessive doses or failed to warn the patient about the possible danger of increasing the intake. In some cases the diagnosis was delayed because the physician inquiring about vitamin consumption was concerned only with preventing deficiencies, and did not question the magnitude of the dose.

Vitamin A is still thought by many to protect against colds and to

lot would be better," and gave their children much more than the recommended dose. In this day of generous food supplies and well spread enrichment of foods, over dosage presents more danger than does deficiency.

Greater realization of these potential dangers among physicians and patients alike would eliminate these completely preventable conditions.

REFERENCES

1. Ament, J. M., Saravanan, W. Jr., and Boyth, G. F.: Hypervitaminosis A—Report of a Case in an Infant. *Am. J. Clin. Nutr.*, 1954, 6: 103.
2. Bass, M. H., and Kaplan, J.: Vitamin A Intoxication in Infancy. *J. Pediatr.*, 47:694, 1955.
3. Berman, R., Vignani, A.: International Report of a Case in an Adult. *New England J. Med.*, 248:690, 1953.
4. Boucha, R. C.: Hypervitaminosis A (Review). *Arch. Ped.*, 74:139, 1957.
5. Calton, S. Q.: Infantile Cortical Hyperostosis. *J. Pediatr.*, 29:541, 1946.
6. Haggard, C.: The Pathogenesis of the Hyperostotic Lesions of the Skull in Childhood and Reversible Manifestations in Sows Infants and Young Children. *Pediatrics*, 5:672, 1954.
7. Calton, S. Q.: Congenital Cerebral Calcification Caused by Excessive Intake of Vitamin A during Pregnancy. *Pediatrics*, 13:556, 1954.
8. DeGroot, J. J., and Shihata, J.: Chronic Vitamin A Poisoning. *Acta Paediatr.*, 46: 1176, 1957.
9. DeGroot, J. J., and Shihata, J.: Chronic Vitamin A Poisoning in Adults, with Report of a Case. *J. Pediatr.*, 46:729, 1954.
10. Grabow, D., Silverman, S. L., and Sobel, A. E.: Vitamin A Poisoning. *Pediatrics*, 7:772, 1951.
11. Grabow, D.: Hypervitaminosis A: Experimental Intoxication in the Human Subject. *Am. J. Clin. Nutr.*, 4:693, 1956.
12. Joffe, H., and Mirero, H.: Hypervitaminosis A: Its Broadening Spectrum. *Pediatrics*, 49:107, 1952.
13. Joffe, H.: W: Hypervitaminosis A and Emotions. *Am. J. Phys. Child.*, 67:55, 1944.
14. Kameny, T. D., and Poffe, R. Jr., ed.: Nutritional Disease. Proceedings of a Symposium on Nutrition. *Am. J. Clin. Nutr.*, 2:102, 1955.
15. N. H. Joffe, 1955. *Proc. Intern. Cong. Pediatr.*, 17: 102, 1955.
16. Kowalski, A. G., Jr., and Reifman, P. E.: Hypervitaminosis A: A Review with Special Reference to Vitamin A. *Am. J. Dis. Child.*, 85:316, 1952.
17. Moinz, G. J.: Acute Hypervitaminosis A of the Infant. *Am. J. Dis. Child.*, 67:731, 1954.
18. Moinz, G. J., Javovic, W. H., and Kujatinsky, F.: Vitamin A Intoxication in Infancy. *Am. J. Clin. Nutr.*, 4:693, 1956.
19. Neman, C., and Klein Olsnik, H. J.: The Biochemistry and Pathology of Hypervitaminosis A. *Vitamin and Hormones*, 12:69, 1954.
20. O'Brien, J. J.: Chronic Vitamin A Intoxication—Report of a Case in an Infant. *Am. J. Clin. Nutr.*, 4:693, 1956.
21. Recommended Dietary Allowances, Revised 1955. A Report of the Food and Nutrition Board, Washington, D.C., National Academy of Sciences, National Research Council, 1955.
22. Rodahl, K., and Moinz, G. J.: The Vitamin A Content and Toxicity of Bean and Soybean. *Am. J. Clin. Nutr.*, 4:693, 1956.
23. Shoenberger, M. B., and Jozan, M. E.: Hypervitaminosis A: Report of a Case in an Adult. *JAMA*, 146:788, 1951.

... is pre-indication, and all too often is taken in generous quantities by many people. Although most of these persons do not exhibit the classic signs and symptoms of hypervitaminosis A, it seems likely that some of them have mild symptoms of toxicity, probably in nonspecific forms such as anorexia, dry skin and failure to gain weight.^{1,2,3,4} In these cases, the degree of toxicity has been reported,^{1,2} but the diagnosis requires a high index of suspicion and is difficult to confirm.

A patient recently brought to my clinic and history may be an example. He was a 6-month-old infant with an acute, poor weight gain and mild hepatomegaly, who was being fed 100 ml of a mixture with polydiphosphates, who had been taking 50,000 I. U. of vitamin A daily for many years. His blood level was mildly elevated at 728 I. U. per liter, and the baby's was 168 I. U. per 100 ml, while her milk contained 100 I. U. per liter on a single determination. Further observations will be required to see whether the baby's condition will improve when he is no longer fed excess vitamin A. Patients like this may be more common than is generally appreciated.

The physician who recommends vitamin A should prescribe only as much as he thinks is necessary, establish a definite time for discontinuing the medication, and caution the patient about the possible toxicity. Although recommendations to label vitamin A concentrates as potentially toxic were made as long ago as 1954,^{5,6} no action has resulted, and the general public continues to be ignorant of any danger.

SUMMARY AND CONCLUSIONS

Acute hypervitaminosis A is manifested by increased intracranial pressure, gastrointestinal distress and desquamation. It has followed ingestion of 350,000 I. U. by infants and several million units by adults. The condition is self-limited, and recovery is prompt. Chronic hypervitaminosis A may defy diagnosis for years unless it is specifically considered. It affects the skeleton as well as the central nervous system, and in infants is often confused with infantile vitamin A deficiency. Symptoms are promptly relieved by stopping vitamin A and may recur in both conditions at all ages if elevation of the serum level of vitamin A. Routine laboratory tests are not helpful in arriving at the diagnosis. In clinical practice, a series of unperiodic new bone formation and continued enlargement of the epiphyseal plates, but the involvement of other osteoclasts helps to distinguish hypervitaminosis A from Caffey's disease.

Chronic hypervitaminosis A has resulted when a patient who was given vitamin A for a dermatologic condition raised the dose or continued to take the medication longer than the physician realized. Other cases were caused by mothers who thought that "if a little is good, a

944 VITAMIN A

26. Toomey, J. A., and Morissette, R. A.: Hypervitaminosis A. *Am. J. Dis. Child.*, 73:473, 1947.
27. Woodard, W. K., Miller, L. J., and Legant, O.: Acute and Chronic Hypervitaminosis in a 4-Month Old Infant. *J. Pediat.*, 59:260, 1961.

Children's Hospital of the East Bay
51st & Grove Sts.
Oakland 9, Calif.



Correspondance

La Revue Neurologique a reçu la correspondance suivante

Drouet et Valence (1998) ont récemment rapporté l'observation d'une femme de 51 ans s'automédiquant depuis des années à la vitamine A qui présenta brutalement une hypertension intracrânienne isolée. Cette observation est publiée en tant qu'hypertension intracrânienne bénigne due à l'hypervitaminose A chronique et les auteurs s'interrogent sur les mécanismes de la neurotoxicité de la vitamine A. Ils indiquent par ailleurs que les données de l'imagerie faisaient discuter « une obstruction partielle du sinus longitudinal supérieur et du sinus latéral gauche » et cette suspicion a été tellement forte que la patiente fut traitée par l'héparine à fortes doses.

L'imagerie présentée dans l'article est effectivement typique d'une thrombose du sinus longitudinal supérieur avec à l'imagerie par résonance magnétique un hypersignal à la fois en T1 et en T2 et à l'angiographie une mauvaise visualisation du sinus longitudinal supérieur avec à sa partie supérieure un aspect caractéristique de « delta » dû au réhaussement de la circulation collatérale dans la paroi du sinus. Par ailleurs, la brutalité d'apparition de la céphalée est également plus suggestive d'une thrombose des sinus veineux durs que d'une HIC dite bénigne de cause toxique ou métabolique dont l'installation est habituellement plus progressive (Tehindrazanarivelo *et al.*, 1992). Il nous semble donc que cette observation aurait donc dû être publiée sous le titre de « Thrombose des sinus veineux durs » et non pas « d'hypertension intracrânienne bénigne », terme à réserver aux hypertensions intracrâniennes isolées, sans pathologie intracrânienne lésionnelle sous-jacente. Cela n'aurait diminué en rien l'intérêt de l'observation car la question qui se pose est non pas celle de la neurotoxicité de la vitamine A mais bien celle de l'étiologie de la thrombose veineuse cérébrale chez cette femme. Il est intéressant de noter à cet égard que la patiente avait un antécédent de thrombose veineuse post-opératoire des membres inférieurs, ce qui fait fortement suspecter une maladie thrombo-embolique veineuse récidivante et donc une possible thrombophilie sous-jacente. La recherche d'une thrombophilie congénitale telle qu'un déficit en protéine C, en protéine S, en antithrombine, ou bien la présence de mutations du facteur V Leiden ou de la prothrombine eut été intéressante chez cette patiente afin d'une part d'établir la meilleure stratégie préventive vis-à-vis d'une nouvelle thrombose veineuse et d'autre part, d'effectuer éventuellement une enquête familiale (Deschiens *et al.*, 1996). Par ailleurs, il serait important de savoir si la

patiente prenait un traitement hormonal, ce qui n'est pas exceptionnel à 51 ans, étant donné le rôle bien démontré des oestrogènes comme facteur de risque des thromboses veineuses.

Quant à la relation entre l'hypervitaminose A et la thrombose des sinus veineux durs, elle reste actuellement obscure, l'hypervitaminose A n'étant pas jusqu'ici connue pour créer un état d'hypercoagulabilité. Cette observation conduit néanmoins à s'interroger sur la cause exacte de l'hypertension intracrânienne dans ceux des cas dits « d'hypertension intracrânienne bénigne par hypervitaminose A » qui ont été rapportés sans avoir eu ni IRM, ni angiographie pour exclure une thrombose des sinus veineux durs. Certes, il existe des cas incontestables d'hypertension intracrânienne bénigne par hypervitaminose A sans thrombose des sinus veineux mais peut-être en est-il d'autres dans lesquels, comme dans l'observation de Drouet et Valence (1998), la thrombose des sinus veineux durs est l'intermédiaire qui favorise l'hypertension intracrânienne.

M.G. BOUSSER

Service de Neurologie, hôpital Lariboisière
2, rue Amarois Paris, F-75475 Paris Cedex 10

RÉFÉRENCES

- DESCHIENS M.A., CONARD J., FORELLOU M.H., AVIGNI A., PRETER M., CHEDRU F., SAMAMA M.M. et BOUSSER M.G. (1996). Coagulation studies, factor V Leiden, and anticardiolipin antibodies in 40 cases of cerebral venous thrombosis. *Stroke*; 27: 1724-1730.
- DROUET A., VALENCE J. (1998). Hypertension intracrânienne bénigne et hypervitaminose A chronique. *Rev. Neurol.*; 154: 3: 253-256.
- TEHINDRAZANARIVelo A., ERARD S., SCHAISSON M., MAS J.L., DORMONT D., BOUSSER M.G. (1992). Prospective study of cerebral sinus venous thrombosis in patients presenting with benign intracranial hypertension. *Cerebrovasc. Dis.*; 2: 22-27.

Les auteurs répondent

Les remarques et réserves émises par Mme le Professeur Bousser concernant l'article récemment publié dans ces colonnes, sous le titre d'« Hypertension intracrânienne bénigne et hypervitaminose A chronique », nous conduisent à apporter les précisions suivantes :

1) Bien que le mécanisme de la neurotoxicité de la vitamine A (et de l'acide rétinolique) ne soit pas établi à ce jour, un faisceau d'arguments concordants, à la fois cliniques, paracliniques, et expérimentaux, plaide en faveur de sa responsabilité dans la survenue possible d'un tableau

d'hypertension intracrânienne bénigne. La normalité de l'artériographie dans la majorité des cas où elle fut pratiquée, comme le renforcement de l'activité fibrinolytique en cas d'hypervitaminose A (Van Bennekum *et al.*, 1993) vont contre le fait qu'une thrombose des sinus veineux soit le mécanisme intermédiaire de cette hypertension intracrânienne.

2) Comme mentionné dans le texte, il existe dans trois observations (celle de Krausz *et al.*, 1978, de Sirdofsky *et al.*, 1994, et la notre), des aspects radiologiques en faveur d'une thrombose de sinus veineux, plus ou moins étendue, conduisant implicitement à retenir cette pathologie comme co-responsable du tableau d'hypertension intracrânienne, dans la mesure où la neurotoxicité de la vitamine A ne paraît pas agir par son intermédiaire : il est vrai en ce cas, qu'elle n'est plus stricto-sensu, une HIC bénigne. On notera que rien, sur le plan clinique et évolutif ne distinguait les deux cas sus-mentionnés des autres observations de la littérature, alors même qu'aucun traitement anti-coagulant n'avait été utilisé. Dans notre propre cas, les données moins probantes, par rapport à celles de l'IRM, de

l'artériographie pourtant précocement réalisée (notamment les coupes sagittales), ne nous ont pas conduit à être plus affirmatifs. Enfin, le bilan de la coagulation (dosages en particulier des protéines C et S, de l'anti-thrombine III ; recherche d'un anticoagulant circulant de type anti-prothrombinase) était sans anomalie.

A. DROUET

Service de neurologie, HIA Desgenettes,
108 boulevard Pinet, F-69275 Lyon

RÉFÉRENCES

- KRAUSZ M.M., FENSOO M., SELZER A.J. (1978). Bilateral transverse sinus obstruction in benign intracranial hypertension due to hypercarotidemia. *Am J Med Sci*, 14 : 858-861.
- SIRDOSKY M., KATTAN J., MACEDO P. (1994). Intracranial hypertension in a dieting patient. *J Neuro Ophthalmol*, 14 : 9-11.
- VAN BENNEKUM A.M., EMES J.J., KOOISTRA T., HENDRIKS F.J. (1993). Modulation of tissue type plasminogen activator by retinoids in rat plasma and tissues. *Am J Physiol*, 264 : 931-937.

Eye Manifestations of Chronic Vitamin A Intoxication

THOMAS K. OLIVER Jr., M.D., and WILLIAM H. HAVENER, M.D., Columbus, Ohio

Poisoning due to prolonged ingestion of large amounts of vitamin A occurs primarily in children receiving excessive vitamin dosage. Occasional cases are seen in adults because of the very high level of vitamin A used in some disorders. Apparently on an empirical basis, 1000 to 500,000 I. U. daily have been advised in treatment or prophylaxis of the common cold, acne, a variety of dermatoses with particular selection of those exhibiting hyperkeratosis, ocular diseases manifesting themselves by night blindness or corneal degeneration, and sometimes in otologic, gynecologic, renal, and enteric disorders. Indications for such use of vitamin A are not clearly established, and serious doubt exists as to the value of this type of treatment. Since 5000 to 7000 I. U. are recommended as the minimum daily requirement for adults, it is apparent that a very wide range exists between actual need and toxic levels of vitamin A.

Manifestations of vitamin A toxicity do not appear until many months of a fairly high dosage. (Enormous single doses may cause an acute rise in cerebrospinal fluid pressure, with attendant symptoms of headache, vomiting, and vertigo. These symptoms may be noted when single doses as high as 350,000 units are given an infant. Apparently shark and polar bear liver contain high concentrations of vitamin A, and acute intoxications are reported following a single meal of these livers.) Toxic symptoms include the central nervous system; manifestations of increased intracranial pressure; exophthalmos; loss of hair, cutaneous rash, desquamation, and pigmentation; migrating arthritis pains, bleeding,

hypomenorrhea; hepatomegaly and splenomegaly, and generalized malaise (Fig. 1).




Fig. 1.—Incidence of symptoms in 36 cases summarized by Oliver.

hypomenorrhea; hepatomegaly and splenomegaly, and generalized malaise (Fig. 1).

Although not a common manifestation, central nervous system involvement is the feature of vitamin A intoxication most likely to result in ophthalmologic consultation. The cause of increased intracranial pressure is unknown, though most authors believe it to be due to increased secretion of cerebrospinal fluid. The patient may have a typical papilledema, accompanied by the usual headaches, and sometimes develops extraocular muscle paralysis with diplopia. (Gerber reports a young woman taking 500,000 units of vitamin A daily for treatment of a skin disorder. During a period of eight and one-half years she was hospitalized 10 times in five different institutions, with diagnosis of subtentorial tumor, serous meningitis, chronic encephalitis, and infectious arthritis. Subtemporal decompression, tantalum cranioplasty, and repeated ventriculograms were done. She became totally disabled from hypertrophic arthritis and manifested all the other symptoms of vitamin A intoxication, which improved dramatically when vitamin A was stopped.) Infants may show bulging font-

Received for publication Oct. 17, 1957.
Ohio State University, Department of Pediatrics (Dr. Oliver) and Acting Chairman, Department of Ophthalmology (Dr. Havener).

tales and other manifestations of internal hydrocephalus, including increased digital markings of cranial bones.

Exophthalmos is occasionally present but is not marked. It is best detected by persons familiar with the patient's previous appearance. Clinical studies of orbital tissue are not available. Speculation as to cause of this exophthalmos should take into account the known antithyroid activity of very large doses of vitamin A. Animal experimentation has clearly established this inhibitory activity. Reported limitations of extraocular movement have been on the basis of nerve paralysis rather than orbital infiltration.

Loss of hair is generalized and includes the brows and lashes. Desquamation may be marked, especially affecting the palms and soles. Often a diffuse cutaneous pigmentation develops. An itching maculopapular eruption may spread over the entire body.

The commonest manifestation of vitamin A intoxication is migrating pain and tenderness of the bones (noted in 34 of the 36 cases surveyed by Oliver). In infants this pain is often associated with noninflammatory swelling overlying the long bones. Characteristic roentgenologic findings of cortical hyperostosis and mottling are seen in children. Adults rarely show positive x-ray findings. The spontaneous fractures reported in laboratory rats do not occur in human cases.

Hypoprothrombinemia, which responds to vitamin K therapy, may cause bleeding following minor injuries or surgery. Adult females develop hypomenorrhea, which disappears promptly when vitamin A is discontinued. Hepatomegaly and splenomegaly may occur. General irritability, anorexia, and weight loss are common.

Treatment of vitamin A intoxication is entirely dependent upon the recognition of the syndrome and withdrawal of vitamin A therapy. Symptoms clear spontaneously within a short period of time.

The following report describes a typical case of hypervitaminosis A.

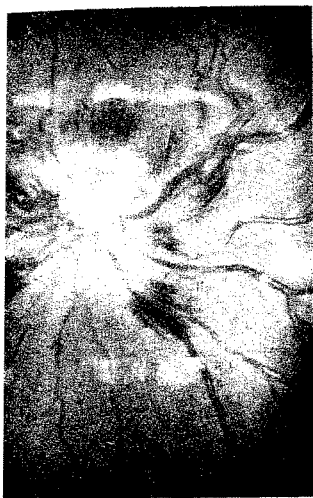A 14-year-old white girl was admitted to Children's Hospital on Sept. 11, 1956, with the chief complaint of leg pain of weeks' duration. Two years prior to admission the patient developed superficial nonpitting acne vulgaris, for which, months prior to admission, 200,000 units vitamin A daily had been prescribed by a dermatologist. Two months prior to admission she had her last normal menstrual period, succeeding ones being at the normal interval but scanty and of one day's duration. About the same time, the patient noticed scaling and cracking of her lips and fissures at the corners of her mouth, for which she used a number of salves without success. Five weeks before admission she began complaining of dull constant pain in her legs, particularly about the knees, aggravated by activity. At this time she was seen by her private physician, who directed that vitamin A be discontinued. This advice was not heeded by the patient, unbeknownst either to her family or the physician. In the month prior to admission leg pain worsened. She walked with a noticeable limp, favoring her left leg, and was unable to continue gym activities. She observed that her scalp hair became dry in texture and fell out in large quantities with brushing. She also developed a maculopapular eruption on her trunk and desquamation of palms and soles. The family observed during this period that she manifested increasing irritability but there were no specific symptoms of central nervous system involvement. No bleeding or bruising was noted. Appetite remained good, although the patient was on a self-imposed rather rigid diet because of the acne.

Family history was noncontributory.

Past history was essentially unremarkable. Menarche occurred two and one-half years prior to admission, and menstrual periods had been normal up to the present illness.

Physical examination. Weight, 54 kg.; height, 169 cm.; blood pressure, 130/70. Skin. The face was the site of superficial

VITAMIN A INTOXICATION



Papilledema, as photographed at time of our case.

g acne vulgaris and milia. The skin was scaled and cracked, and there were crusts at the corners of the mouth. Over the face and to a less degree on the extremities was a fine discrete light-tan non-papular eruption. The skin on the palms and soles was desquamated in sheets. The underlying skin in the hands was delicate and thin, Nikolsky's sign was absent. The scalp hair was dry and brittle. There was moderate alopecia. Axillary hair was normal. As shown in Figure 2, the typical appearance of papilledema was present in each eye. The retinal margins were completely blurred and the optic disc was markedly elevated, and the physiologic cup was completely obscured. Slight venous stasis existed, and spontaneous venous collapse was absent. Minimal external pressure elicited venous collapse. Fine arteriolar dilation was apparent on the disc. A Giæstening retinal edema encircled the disc extending out about 1 dd. A nummularly large and dense flame-shaped hemorrhage was clustered about the disc, and periphery were completely normal. There were no visual symptoms. External ocular examination was entirely

negative. (Specifically, no exophthalmos or extraocular muscle paresis existed.) Abdomen. Liver and spleen were not enlarged. Extremities: Pain and tenderness in both legs, more on the left, particularly medial and inferior to the tibial tubercle. There was no swelling, heat, or redness. There was no weakness, sensory disturbance, or reflex changes, nor were there signs of meningeal irritation. Mentation was normal to bedside testing.

Laboratory data. Hemoglobin, 12.9 gm/100 ml.; white cell count, 8050 per cubic millimeter, with a normal differential count; platelets, normal on appearance; blood urea nitrogen, 24 mg/100 ml.; CO_2 , 21 mEq/liter; chloride, 102 mEq/liter; total base, 149 mEq/liter; total protein, 7.3 gm/100 ml.; albumin, 3.6 gm.; globulin, 3.7 gm/100 ml.; calcium, 10 mg/100 ml.; inorganic phosphate, 3.5 mg/100 ml.; alkaline phosphatase, 3.5 Bodansky units; cephalin flocculation, 1+; thymol turbidity, normal; cholesterol, 94 mg/100 ml.; protein-bound iodine, $9.6\mu\text{g}/100\text{ ml.}$ (Sept. 20, 1956); repeat, $4.8\mu\text{g}/100\text{ ml.}$ (Oct. 25, 1956). B. M. R., normal. Skeletal survey including long bones, spine, and skull, normal. Lumbar puncture (supine), crystal-clear fluid; initial pressure, 600 mm. H_2O ; cells, 3 per cubic millimeter; sugar and protein, normal. EEG, normal. Fasting serum carotene and xanthophyll (Sept. 11, 1956), $264\mu\text{g}/100\text{ ml.}$ (normal, $75\mu\text{g.}$ to $150\mu\text{g.}$) and $135\mu\text{g}/100\text{ ml.}$ (normal, $40\mu\text{g.}$ to $80\mu\text{g.}$), respectively; on Feb. 4, 1957, $195\mu\text{g}/100$

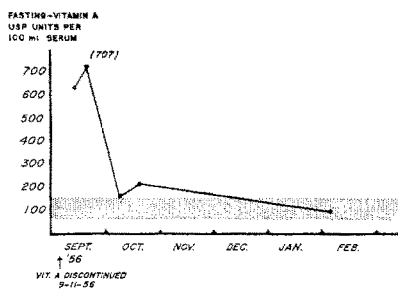


Fig. 3.—Fasting vitamin A levels. Shaded area indicates normal range.

ml. and $98\mu\text{g}/100\text{ ml.}$, respectively. The fasting vitamin A levels are shown in Figure 3.

Course. A diagnosis of chronic hypervitaminosis A was made on admission, and all medications were discontinued. Symptoms and signs began to abate within a week, and the patient was entirely asymptomatic, except for continued loose hair, after two weeks. She was discharged on Sept. 17, 1956. When examined on Oct. 6, 1956, there were no abnormalities, except that alopecia and superficial acne vulgaris (unchanged from before) were noted. Ophthalmoscopic examination was entirely normal, with no residue of the retinal hemorrhages. Regrowth of scalp hair, which was of fine texture, was not observed until six weeks after the vitamin A was stopped. Menstrual periods became normal in duration two months after medication was stopped. The patient has remained asymptomatic for nine months.

Summary

The syndrome of chronic vitamin A intoxication includes the central nervous system manifestations of increased intracranial pressure, mild exophthalmos, including brows and lashes, cutaneous and pigmentation, migraines, hypoprothrombinemia, and splenomegaly, hypomenstruation, and generalized malaise.

A case of chronic hypervitaminosis A in a 14-year-old girl is presented.

The vitamin A levels were determined by Robert Forbes, M.D., Rochester University School of Medicine and Dentistry.

Dr. Sophie Rogers gave permission to publish this case, and Prof. Jack Prince assisted with the photography.

University Hospital (10).

REFERENCES

1. Oliver, T. K.: Chronic Vitamin A Intoxication. *A. M. A. J. Dis. Child.*, Pt. I, 1956.
2. Gerber, A.; Raab, A. P., and others: Vitamin A Poisoning in Adults with Report of a Case. *Am. J. Med.* 16:729-7, 1954.

NEUROLOGY

NOTICE: THIS MATERIAL MAY BE PROTECTED
BY COPYRIGHT LAW (TITLE 17 U.S. CODE)

Chronic Hypervitaminosis A with Intracranial Hypertension and Low Cerebrospinal Fluid Concentration of Protein

Two Illustrative Cases

NORMAN J. SIEGEL, M.D., THOMAS J. SPACKMAN, M.D.

An unusually high dietary intake can lead to vitamin A intoxication. These two children had clinical and radiologic evidences of increased intracranial pressure and low cerebrospinal fluid protein concentrations.

"... it made us all sicke, specially three that were exceeding sicke, and we verily thought we should have lost them all, for all their skins came of from the foote to the head; but yet they recovered again, for which we gave God heartie thanks."

GERRIT DE VEER, historian of an Arctic expedition in 1597, recorded this early account of the toxicity of polar bear liver.¹ Not until this century was the high content of vitamin A found to be responsible for the toxic properties.² Both acute and chronic vitamin A intoxication are now well documented syndromes.

This paper describes two siblings who had chronic hypervitaminosis A which was manifested primarily by signs and symptoms of intracranial hypertension. Of particular interest in these cases were the radiologic features and the finding of low concentration of protein in the cerebrospinal fluid. Their vitamin A intoxication was induced by the administration of large amounts of vitamin by a health faddist mother.

From the Departments of Pediatrics and Radiology, Yale University School of Medicine, New Haven, Connecticut.

Correspondence to: Norman J. Siegel, M.D., Yale University School of Medicine, 333 Cedar Street, New Haven, Connecticut 06510.

Case Reports

Case 1

This 30-month-old boy was admitted to the Yale New Haven Hospital because of anorexia, lethargy, stiff neck and inability to walk. These complaints were accompanied by increasing head size, patchy alopecia, and an exfoliative pruritic rash which had developed over a period of several weeks. His mother, a health faddist, had refused to have her children immunized and had been feeding them a variety of health foods and vitamins for about a year. Retrospectively the daily diet had included estimated minimums of at least 57,000 IU of vitamin A, 1,000 IU of vitamin I, 290 IU of vitamin E, 480 mg of vitamin C, 1,600 mg of calcium, and 750 mg of phosphate.

The child appeared chronically ill. His height was 90 cm (90th percentile), weight 14.1 kg (50th percentile) and head circumference 54 cm (greater than 97th percentile). The pertinent physical findings included an obviously large head, stiff neck, slightly enlarged liver and spleen and patches of alopecia. He refused to walk because of pain in both shins which were tender to palpation.

Laboratory studies yielded normal readings for blood count, serum electrolytes, blood urea nitrogen and phosphate. Liver function results were normal except for a transaminase level of 10 units (normal 15-35). The serum calcium was initially 13.5 mg/100 ml but fell to 10.0 mg/100 ml after the calcium and vitamin D supplements were stopped. Blood carotene was normal at 9 μ gm/100 ml (normal 70-200). The serum vitamin A was markedly elevated at 520 μ gm/100 ml (nor-

HYPERVITAMINOSIS A

mal 80-80) on admission and fell to 285 μ gm/100 ml ten days later. The cerebrospinal fluid contained no cells, the glucose was 58 mg/100 ml (simultaneous blood glucose was 78 mg/100 ml) and the protein concentration was low at 6 mg/100 ml (normal 11.5-23.9).

Radiographic skeletal survey demonstrated slight cupping of the metatarsal and phalangeal metaphyses in the feet. There was subtle periosteal new bone along portions of one ulnar shaft (Fig. 1), but the most striking findings were widening of cranial sutures and enlargement of the cranial vault relative to the size of the facial bones (Fig. 2A).

The child's clinical condition improved dramatically when all vitamin supplements were stopped. His anorexia, lethargy, and irritability decreased within a few days and by the end of a week he was able to walk. Repeat x-rays two months later demonstrated complete subsidence of the sutural widening of the skull (Fig. 2B). The periosteal new bone of the ulna was now partially incorporated into the shaft; the cupped metaphyses in the feet were unchanged.

• Case 2

The 12-month-old female sibling was brought in because of irritability and vomiting which began three weeks after her brother's admission. Her parents reported a daily intake of 25,000 IU of vitamin A over a period of nine months, but they denied giving any other food or vitamin supplements.

Her height was 72.5 cm (25th percentile), weight 7.85 kg (10th percentile) and head circumference 48 cm (90th percentile). Pertinent physical findings included exfoliative dermatitis and a liver edge palpable 3 cm below the right costal margin. The anterior fontanel was bulging but the optic discs were normal and there were no neurologic signs or bone pain.

Laboratory studies gave normal readings for blood count, serum electrolytes, blood urea nitrogen, serum calcium and phosphate. Blood carotene was normal at 112 μ gm/100 ml but serum vitamin A was elevated at 180 μ gm/100 ml. On lumbar puncture the opening pressure was elevated to 260 mm of water. The cerebrospinal fluid contained no cells; the glucose was 49 mg/100 ml (simultaneous blood glucose was 70 mg/100 ml), but the protein concentration was low at 6 mg/100 ml (normal 11.4-22.2).

Radiographic examination demonstrated pronounced widening of the cranial sutures. There was no periosteal new bone formation and no abnormality of the metaphyses.

The child improved rapidly when vitamin A was stopped and by five days she was asymptomatic. Repeat skull x-rays six weeks later were normal.

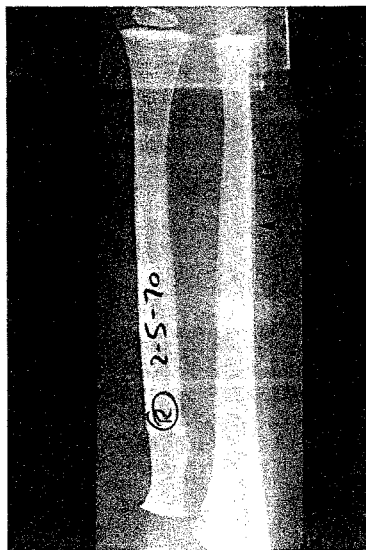


FIG. 1. Case 1. A fine line of periosteal new bone is indicated by arrows along one margin of the ulna.

Comments

Numerous instances of hypervitaminosis A in both children and adults have been recorded since Josephs' first description in 1944,³ and the subject has been reviewed in several publications.⁴⁻⁷ The acute form of vitamin A intoxication is manifested by bulging fontanels, vomiting, agitation and insomnia, all of which are probably induced by increased intracranial pressure. Chronic hypervitaminosis A, the more common variety, consists of anorexia, dry pruritic skin, fissures of the lips, localized subcutaneous and bone tenderness, and a diversity of lesser manifestations which have been listed by Stimson.⁸

Clinical signs of intracranial hypertension are seen most often in acute toxicity, but our patients support the view of Rothman and Knudson⁸ that the CSF pressure can rise in both acute and chronic toxicity. The precise mechanism behind the intracranial hyperten-

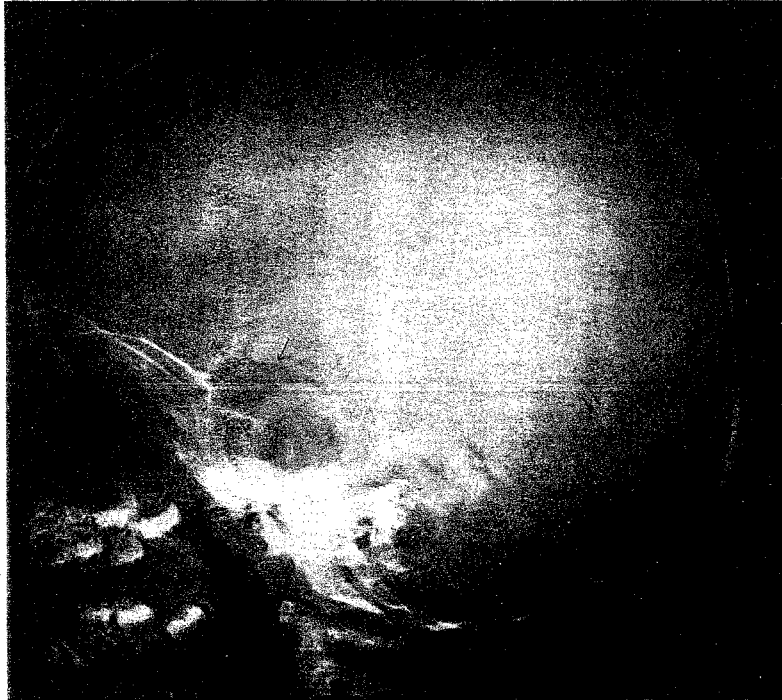

FIG. 2A. Case 1. The initial lateral skull film demonstrates widening of cranial sutures, especially the squamosal (single arrow) and the lambdoid (double arrows). Lengthening of the sawtooth sutural interdigitations is another sign of increased intracranial pressure and can be seen along the coronal suture (triple arrows).

sion is not known, though enhanced CSF production, or impaired CSF resorption, or a combination of both are postulates.⁹

Each of our two patients had significantly low CSF protein levels for their ages by comparison with normal standards.¹⁰ Although other authors have recorded low or low normal values,^{9, 11-13} this has not previously been suggested as a helpful feature for distinguishing hypervitaminosis A from other causes of intracranial hypertension.

Roentgen findings in hypervitaminosis A include cortical periosteal new bone forma-

tion (hyperostosis), metaphyseal cupping, increased metaphysical density, and signs of intracranial hypertension.^{4, 5, 14-16} Most reports of children have emphasized hyperostosis of long bones, occasionally associated with bulging fontanel or large calvarium. Persson¹⁴ described several children who had widened cranial sutures in association with typical long bone changes. The siblings reported here are unusual because the predominant roentgen finding in both was widening of cranial sutures; in fact this was the only abnormality in one of them.

HYPERVITAMINOSIS A

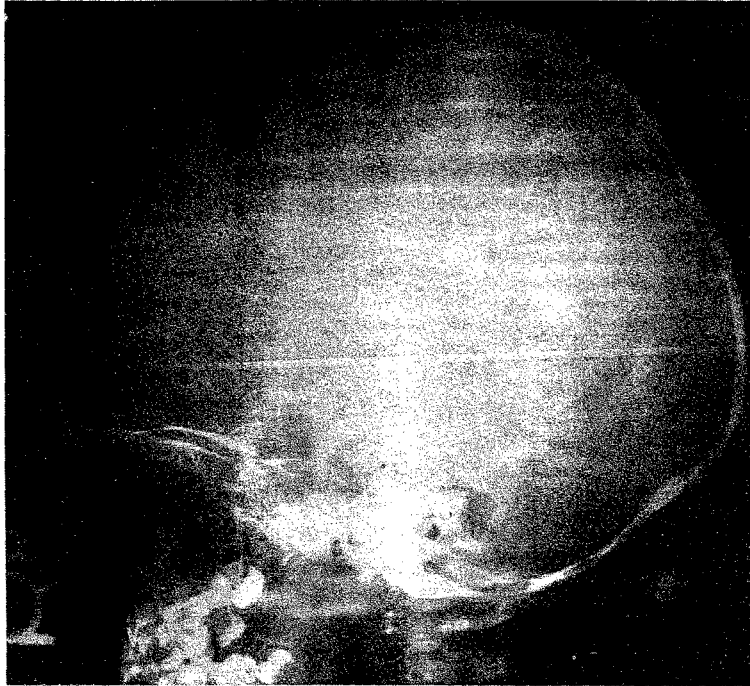


FIG. 2B. Case 1. Repeat skull film two months after stopping vitamin A shows normal sutural width.

The combination of behavioral change, elevated CSF pressure, and widened sutures on skull x-rays are very suggestive of the possibility of a mass lesion within the skull. Children with these disturbances might be subjected to various neuroradiologic procedures if the possibility of vitamin A intoxication is not considered early in their evaluation.

The use and abuse of vitamin A has been reviewed in a recent report from the Canadian Pediatric Society.¹⁷ This points out that a diet normal for any age does provide an adequate intake of vitamin A, and that the danger

from toxicity makes it unwise to prescribe supplements for infants in excess of 5,000 IU per day. Intoxication may result when large amounts of vitamin A are given for treatment of dermatologic diseases (most often acne vulgaris in adolescents and young adults) and hence this practice should be discontinued because of its doubtful benefit and possible hazard. Sometimes, hypervitaminosis A is the result of constitutional idiosyncrasy.

As illustrated in this report, the use of non-prescription vitamins and health food supplements can result in the ingestion of large

amounts of vitamin A. A precise history of bizarre food habits may be difficult to obtain from the patients or their parents, yet is of utmost importance for the making of the diagnosis.

References

1. Quoted by Bloch, H. S.: Chronic Hypervitaminosis A. *Minn. Med.* 38: 627, 1955.
2. Rodahl, K.: Toxicity of Polar Bear Liver. *Nature (London)* 164, 530, 1949.
3. Josephs, H. W.: Hypervitaminosis A and Carotemia. *Am. J. Dis. Child.* 67: 33, 1944.
4. Caffey, J.: Chronic Poisoning Due to Excess of Vitamin A—Description of the Clinical and Roentgen Manifestations in Infants and Young Children. *Pediatrics* 5: 572, 1950.
5. Oliver, T. K., Jr.: Chronic Vitamin A Intoxication: Report of a Case in an Older Child and Review of the Literature. *Am. J. Dis. Child.* 95: 57, 1958.
6. Stimson, W. H.: Vitamin A Intoxication in Adults—Report of a Case with Review of the Literature. *N. Engl. J. Med.* 265: 369, 1961.
7. Feldman, M. H. and Schlezinger, N. S.: Benign Intracranial Hypertension Associated with Hypervitaminosis A. *Arch. Neurol. (Chicago)* 22: 1, (Jan.) 1970.
8. Rotnam, P. E. and Knudson, A. G.: Hypervitaminosis A: A Review with a Discussion of Vitamin A. *Am. J. Dis. Child.* 85: 316, 1953.
9. Bass, M. D.: The Relation of Vitamin A to Cerebrospinal Fluid Pressure—A Review. *J. Mount Sinai Hospital N. Y.* 24: 713, 1957.
10. Widell, S.: C.S.F. Protein Various Ages. *Acta Paediatr. Scand.* 47: 1, 1958 (Suppl. 1:5).
11. Marie, J. and See, G.: Acute Hypervitaminosis of the Infant—A Clinical and Biological Study. *Am. J. Dis. Child.* 87: 731, 1954.
12. Fried, C. T. and Grand, M. J. H.: Hypervitaminosis A. *Am. J. Dis. Child.* 79: 475, 1956.
13. Gerber, A., Raab, A. P. and Sobel, A. E.: Vitamin A Poisoning in Adults. *Am. J. Med.* 16: 729, 1954.
14. Persson, B., Tunnell, R. and Ekengren, K.: Chronic Vitamin A Intoxication During the First Half Year of Life. *Acta Paediatr. Scand.* 54: 49, 1965.
15. Caffey, J.: Chronic Poisoning Due to Excess of Vitamin A. *Am. J. Roentgenol.* 65: 12, 1951.
16. Woodward, W. K., Miller, J. J. and Legaut, O.: Acute and Chronic Hypervitaminosis in a 4-month-old-infant. *J. Pediatr.* 59: 260, 1961.
17. The Use and Abuse of Vitamin A. Report of the Nutrition Committee. *Can. Med. Assoc. J.* 104: 521, 1971.

Abuse of Vitamin A Preparations

Hypervitaminosis A may result from use of high potency vitamin A preparations with or without prescriptions, and from the enthusiasm of overzealous parents who administer vitamins under the popular premise that, if one is good, two are better. The problem may be compounded by the use of bizarre, highly fortified health foods.

Serious problems of hypervitaminosis A have arisen from the use of large doses of vitamin A in treatment of acne vulgaris in adolescents. The clinical impression that high doses of vitamin A (50,000 I.U. to 150,000 I.U. per day) over a prolonged period are beneficial treat-

ment for acne vulgaris has not been validated by well-controlled clinical trials, nor is the rationale for this method of treatment clear.

Vitamin supplements with proper levels of vitamin A should be prescribed when indicated. Supplements containing more than the daily doses recommended (6,000 I.U.) should not be given.

The recommended daily allowances of vitamin A are: for infants and children up to age 12 years, from 1,500 to 4,500 I.U.; for adults, 5,000 I.U.; and for pregnant women 6,000 I.U. There are no known advantages in exceeding these allowances in normal individuals.

The grave risks resulting from the unrestricted sale of high concentrations of vitamin A make it imperative that an active curb, by appropriate legislation if necessary, be placed on the over-the-counter marketing of high potency vitamin A preparations. Physicians should be aware of the vitamin A content in the preparations they prescribe for their patients. They also should caution parents regarding the dangers of overdosage of this vitamin.

—Extracted from a Joint Statement of the Committee on Drugs and the Committee on Nutrition of the American Academy of Pediatrics, *Pediatrics*, October 1971.

Notice: This material may be protected by copyright law (Title 17 U.S. Code).

265

Wondu Alemayehu. 1995. *Ethiop Med J* 33,

CASE REPORT

PSEUDOTUMOR CEREBRI (TOXIC EFFECT OF THE "MAGIC BULLET")

Wondu Alemayehu, MD, MPH¹.

ABSTRACT: A 10 year-old female patient presented to the outpatient unit of the ophthalmology department of Menelik II Hospital with complaints of inward deviation of the left eye, of three weeks' duration. The patient was on a mega dose of vitamin A 200,000 I.U. (the "magic bullet") daily for two months prior to the onset of the present illness. Physical examination revealed left sixth nerve palsy and bilateral papilloedema in an alert and oriented patient without localizing neurologic findings. The cerebrospinal fluid pressure (>250 mm water) was increased and skull X-ray findings were suggestive of increased intracranial pressure (IIP). This case meets the modified Dandy criteria except that a highly likely cause, hypervitaminosis A, is associated. Therefore, a diagnosis of Idiopathic Intracranial Hypertension (IIH) or Pseudotumor Cerebri was made. This disorder and its management is discussed and literature reviewed. The serious and potentially blinding toxic effect of Vitamin A, if consumed in excessive amounts, is emphasized.

INTRODUCTION

Idiopathic intracranial hypertension (IIH), first described by Quincke in 1897, is a syndrome characterized by increased intracranial pressure with its associated signs and symptoms. Loss of sensory visual function is the major form of morbidity with IIH (1,2). A large majority of IIH patients are obese women (3). The childhood form of IIH is different in that it affects both sexes equally and obesity is not a prominent factor (1). Intracranial hypertension, that meets the

modified Dandy criteria, in association with highly likely causes verified by multiple lines of evidence have been reported (4,5). Hypervitaminosis A is one of these causes convincingly associated with IIH (6).

The true incidence of IIH in Ethiopia is not known. Although the cause of IIH remains obscure, the potential risk of loss of visual function is common and blindness might result. Valid association with obesity, recent weight gain, female sex in adults, hypervitaminosis A and steroid withdrawal have been reported (1-6). The most popular pathogenetic hypothesis is that IIH is a syndrome of

¹Department of Ophthalmology, Faculty of Medicine, Addis Abeba University, Addis Abeba.

Notice: This material may be protected by copyright law (Title 17 U.S. Code).

266

reduced CSF absorption (7,8). The purpose of this paper is to present such a case and thereby draw attention to the serious and potentially blinding toxic effect of Vitamin A.

CASE REPORT

A 10 year-old girl presented to the neuro-ophthalmic clinic of Menelik II Hospital, Addis Abeba on September 30, 1994 with three weeks' history of inward deviation of the left eye observed by her father. The patient was on Vitamin A 200,000 I.U. daily for two months prior to the development of the ocular misalignment.

Physical examination revealed left sixth cranial nerve paresis and bilateral papilloedema. The patient was alert and oriented and had no localizing neurologic findings. Other pertinent ophthalmic findings were: Snellen visual acuity of the right eye, 6/9, of the left eye, 6/6, esotropia of 15 prism diopters, normal color vision in both eyes and a perimetry with enlargement of blind spots only.

Laboratory results revealed a haemoglobin of 12 gm%, white blood cell count of 6,600 mm³, ESR of 12 mm/hr., fasting blood sugar of 80 mg%, urea 1.6 mg%, creatinine 1.4 mg%, calcium 9.8 mg%, phosphorus 3.1 mg%, a negative urinalysis and antinuclear antibody. The FTA-ABS and VDRL were non-reactive. Serum retinol was not determined as the

facility was not available.

A lumbar puncture was done using a 22-gauge needle and the needle was immediately connected to a pressure transducer. The pressure was recorded on BBC recorder model (SE 120) connected to the transducer for about one minute and stopped. About one ml CSF sample was taken for analysis. The CSF analysis showed a clear fluid with no inflammatory cells, glucose of > 50 mg/dl and protein of < 40 mg/dl. CSF VDRL was non-reactive. CSF pressure was highly elevated; 250-300 mm water (normal <200 mm water) (Figure 1). A repeat lumbar puncture was suggested but was not possible as the patient and her father declined. X-ray of the skull, P-A and lateral views showed separation of sagittal and other sutures (Figures 2 & 3).

A diagnosis of pseudotumor cerebri was made and the patient was managed accordingly. Vitamin A was discontinued immediately. Treatment using oral acetazolamide (Diamox), a dehydrating agent that also reduces CSF production and lowers intracranial pressure, was started in doses of two grams per day (9). A dramatic recovery was observed in the first two weeks of follow-up. The esotropia disappeared, the papilloedema almost totally resolved and intact visual fields were recorded by perimetry. The patient is still under close follow-up.

Notice: This material may be protected by copyright law (Title 17 U.S. Code).

267

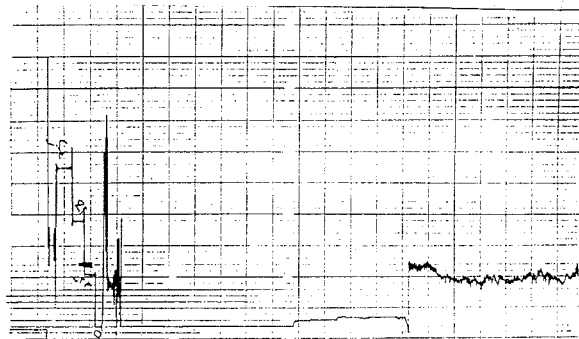



Figure 1. Cerebrospinal fluid pressure tracing = 250-300 mm water

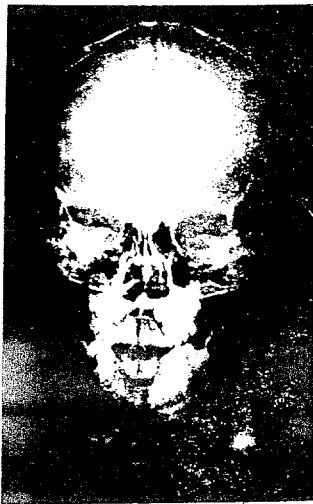

Figure 2. X-ray skull (PA view) showing separated sagittal and other sutures



268

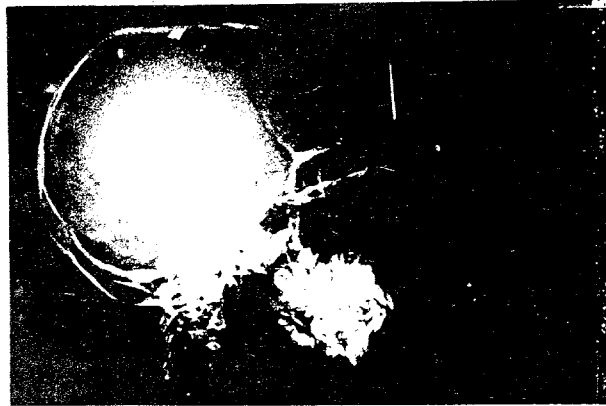

Figure 3. X-ray skull (lateral view) showing separated sagittal and other sutures.

DISCUSSION

This patient was an evident case of IIP that meets the modified Dandy criteria in association with Vitamin A intoxication. The modified Dandy criteria is constituted by increased intracranial pressure with its associated signs and symptoms in an alert and oriented patient without localizing neurologic findings. The signs and symptoms of increased intracranial pressure detected were headache, nausea, vomiting, pulsatile intracranial noises and visual findings, no abnormality of ventricular system and normal neurodiagnostic studies with the exception of increased CSF pressure (>200 mm water in the non-obese and 250 mm

water in the obese patient). Furthermore, no secondary causes of intracranial hypertension was apparent (1-10).

The clinical features of hypervitaminosis A vary considerably depending on individual susceptibility and the amount of Vitamin A intake. Since young children may be unable to verbalize complaints such as headache, the most frequent symptom of IIP, the physician must rely on the observations of parents. In chronic hypervitaminosis A papilloedema, extraocular muscle paralysis, diplopia and occasionally exophthalmos occur simulating brain tumor. Recognition of this fact is important not only because withdrawal cures the patient, but also because expen-

Notice: This material may be protected by copyright law (Title 17 U.S. Code).

269

sive, uncomfortable and hazardous neurosurgical diagnostic procedures can be avoided. An increased level of awareness on the part of the physician simplifies the diagnosis of chronic hypervitaminosis A (11).

Our patient had left abducens paresis, bilateral papilloedema and enlargement of the blind spots. A history of horizontal diplopia is obtained in about a third of the IHH patients and a sixth nerve paresis is present in 10-20% (3). The increase in intracranial pressure might give rise to diplopia due to sixth nerve paresis, transient visual obscurations and papilloedema with its associated loss of sensory visual function. Papilloedema is the hallmark and is the cause of much of the visual loss of IHH (12). Snellen visual acuity remains normal in patients with papilloedema, as in our patient, unless papilloedematous optic atrophy sets in when the condition is a long standing one. Therefore, visual loss should be monitored by perimetry (3). The common visual field defects are

enlargement of the physiologic blind spot as observed in our patient. Loss of inferonasal portion of the visual field and constriction of isopters are also seen. The loss of visual field may be progressive, leading to blindness (2,13). Treatment of the disorder results in a significant improvement in perimetry as demonstrated by a prospective study (3).

Last but not least, inappropriate use of Vitamin A should be avoided and patients receiving large doses of Vitamin A should be carefully observed for toxicity.

ACKNOWLEDGEMENTS

I would like to express my sincere thanks to the heads and staff of the Department of Paediatrics, Physiology and the Audiovisual units of the Faculty of Medicine, Addis Abeba University, for their valuable assistance. My thanks also goes to Ato Assefa Adinew for his support in preparing the manuscript.

REFERENCES

1. Baker RS, Carter D, Hendrick EB, Buncic JR. Visual loss in pseudotumor cerebri of childhood. A follow-up study. *Arch Ophthalmol* 1985;103:1681-6.
2. Corbett JJ, Savino PJ, Thompson HS, et al. Visual loss in pseudotumor cerebri. Follow-up of 57 patients from 5 to 41 years and a profile of 14 patients with permanent severe visual loss. *Arch Neurol* 1982;39:461-74.
3. Wall M, George D. Idiopathic intracranial hypertension (pseudotumor cerebri): a prospective study of 50 patients. *Brain* 1991;114:115-80.
4. Wall M. Idiopathic intracranial hypertension. In: Breen L, editor, *Neurology of Clinics of North America*. Philadelphia: W. B. Saunders, 1991;9:73-95.
5. Giuseffi V, Wall M, Siegel PZ, Rojas PB. Symptoms and disease associations in idiopathic intracranial hypertension: A case control study. *Neurology* 1991;41:239-44.
6. Feldman MH, Schlezinger NS. Benign intracranial hypertension associated with hypervitaminosis A. *Arch Neurol* 1970;22:1-7.
7. Donaldson JO. Endocrinology of pseudotumor cerebri. *Neurol Clin* 1986;4:919-27.

J
A
S Notice: This material may
be protected by copyright
law (Title 17 U.S. Code).

270

8. Fishman RA. The pathophysiology of pseudotumor cerebri. An unsolved puzzle. *Arch Neurology* 1984;41:257-8.
9. Gucer G, Viernstein L. Long-term intracranial pressure recording in the management of pseudotumor cerebri. *J Neurosurg* 1978;49:256-63.
10. Corbett JJ, Mehta MP. Cerebrospinal fluid pressure in normal obese subjects and patients with pseudotumor cerebri. *Neurology* 1983;33:1386-8.
11. McLaren DS. Nutritional Ophthalmology. In: Darby WJ, editor. Vitamin A: human studies of hypervitaminosis A. London: Academic Press, 1980;118-21.
12. Smith TJ, Baker RS. Perimetric findings in pseudotumor cerebri using automated techniques. *Ophthalmology* 1986;93:887-94.
13. Foley J. Benign forms of intracranial hypertension - "toxic" and "otitic" hydrocephalus. *Brain* 1955;78:1-41.

(Accepted 3 July 1995)

Letters

Depression Associated with Vitamin A Intoxication

SIR: Vitamin formulas containing supplements far in excess of the Food and Drug Administration's recommended daily intake are readily available in the United States. The toxic effects of megavitamin regimens have been reported elsewhere.¹ Excessive amounts of vitamin A, a fat-soluble retinoid stored in the liver and other tissues, can have serious health consequences. We report a case of chronic vitamin A intoxication with both psychiatric and medical manifestations.

Case Report

Ms. A., a 54-year-old female with no past psychiatric history and no family history of affective disorder, presented with a 1-year history of depressed mood, poor concentration, frequent tearfulness, and guilty rumination. Insomnia and poor appetite had become prominent during the previous 2 months. A 25-item Hamilton Depression Rating Scale (HDRS) score of 29 was obtained at initial evaluation. The patient expressed fear of an undetected cancer because of physical symptoms that included fatigue, long bone and neck pain, and alopecia areata. Medications included only a proprietary multivitamin preparation taken at the manufacturer-recommended daily dosage of 6 capsules (25,000 IU of vitamin A)/day for 2 years.

Abnormal physical findings included a 6×8-cm area of sparse hair in the frontal scalp region and dry mucous membranes at the nares and lips with fissuring. Laboratory studies revealed low hemoglobin (11.3 g/dl) and hematocrit (33.2%) levels. Liver function tests and vitamin A level (42 µg/dl) were normal.

The patient was instructed to discontinue vitamin A and was seen 2 and 4 weeks later. The HDRS score dropped to 4 and 6, respectively. Progressive improvement in the physical symptoms and full remission of depressive symptoms occurred at 2 months.

The recommended daily intake of vitamin A is 2,331 IU (700 retinol equivalents) for adult males and 1,998 IU (600 retinol equivalents) for adult

females.^{2,3} This patient had ingested more than 12 times the recommended daily intake daily for 2 years.

Acute or chronic vitamin A intoxication may cause headache, diplopia, alopecia, dry mucous membranes, desquamation, bone abnormalities, and liver damage.² Psychiatric manifestations are rare, but may resemble severe depression or schizophrenia.⁴ Chronic toxicity has usually been associated with daily intakes exceeding 50,000 IU,^{2,3,5} but signs of vitamin A intoxication were described in a 51-year-old female patient who had ingested 27,500–35,000 IU daily for 30 years.³

Diagnosis is based on history and physical findings. Other findings may include liver enzyme elevation and hypercalcemia. Plasma vitamin A level is often not a good indicator of tissue concentration and total body reserves.² Treatment consists of discontinuation of vitamin A. Recovery begins within several days and is usually complete at 2 months.³

Although spontaneous resolution of depression is a consideration in this patient, it seems unlikely given the worsening physical, psychological, and neurovegetative symptoms prior to evaluation and negative past personal and family history of affective disorder. To our knowledge, this is the first report of chronic vitamin A toxicity presenting with symptoms consistent with major depressive episode.

Elinore F. McCance-Katz, M.D., Ph.D.
Lawrence H. Price, M.D.
Yale University School of Medicine
New Haven, Connecticut

Supported in part by United States Public Health Service Grants MH-14276, MH-30929, and MH-36229.

References

1. Schaumburg H, Kaplan J, Windebank A, et al: Sensory neuropathy from pyridoxine abuse, a new megavitamin syndrome. *N Engl J Med* 309:445–448, 1983
2. Olson JA: Recommended dietary intakes (RDI) of vitamin A in humans. *Am J Clin Nutr* 45:704–716, 1987
3. Benedich A, Langseth L: Safety of vitamin A. *Am J Clin Nutr* 49:358–371, 1989
4. Robbins SL, Cotran RS, Kumar V: *The Pathologic Basis*

Letters

- of Disease, 3rd Edition*. Philadelphia, WB Saunders, 1984
5. Biesalski HK: Comparative assessment of the toxicology of vitamin A and retinoids in man. *Toxicology* 57:117-161, 1989.

**Tricyclic Antidepressants in
Nine Heart Transplant Recipients**

SIR: Kay et al.¹ recently reported in this journal the safe use of tricyclic antidepressants in nine heart transplant recipients, but I believe they have made an error on an important point. They state that transplanted hearts "are externally paced, so the conduction disturbances that can complicate use of tricyclic antidepressants are not a hazard" (p. 169). Because the transplanted heart is denervated, heart rate is under the control of the intrinsic atrial pacemaker (sinoatrial node) and is free of external neurogenic influence. As a result, heart rate remains relatively constant, although circulating catecholamines still have some influence.² It does seem logical to infer that tricyclic antidepressants would have less chronotropic effects in transplanted hearts compared with normal hearts, but actual data on this point are scarce.³ Kay et al. are mistaken in concluding that conduction disturbances are not a hazard. Conduction disturbances are related to tricyclic antidepressants' quinidine-like (Type IA antiarrhythmic) effects that occur at the A-V node and His bundle. Therefore, conduction disturbances with tricyclics are at least as likely in the transplanted heart as they are in the normal heart.

James L. Levenson, M.D.
Virginia Commonwealth University
Richmond, Virginia

References

1. Kay J, Bienenfeld D, Slomowitz M, et al: Use of tricyclic antidepressants in recipients of heart transplants. *Psychosomatics* 32:165-170, 1991
2. Shapiro PA, Sloan RP, Horn E, et al: Differential effects of psychological stress on innervated and denervated SA node activity after cardiac transplantation (abstract). *Psychosom Med* 52:222-223, 1990
3. Trzepacz PT, Levenson JL, Trngali RA: Psychopharmacology and neuropsychiatric syndromes in organ transplantation. *Gen Hosp Psychiatry* 13:233-245, 1991

In Reply

SIR: Dr. Levenson raises an important issue about the caution advisable in using tricyclic antidepressants (TCAs) in denervated hearts. Our point, in passing, was that in externally paced hearts, the conduction defects that can occur with TCAs are of less concern than they are in unpaced hearts. The ventricular pacemaker does not in any way prevent atrioventricular node or His bundle effects of TCAs, but it does protect against untoward results of these effects. Even in the unlikely event of TCA-induced complete atrioventricular block, the ventricular pacer assures rhythmic ventricular contraction.

In unpaced hearts, this "safety net" is missing, and all usual cautions apply. In our series of nine cases and in several more cases subsequently treated with TCA, antidepressants have been both safe and effective. We stand by our conclusion that TCAs are reliable agents for use in heart transplant recipients. We thank Dr. Levenson for his reminder that these agents should always be used with respect.

David Bienenfeld, M.D.
Jerald Kay, M.D.
Wright State University School of Medicine
Dayton, Ohio

**Response to Letter "Mania and
Paranoid Psychosis"**

SIR: Rif S. El-Mallakh, M.D., suggests that mania, paranoid psychosis, and cognitive decline share a similar pathophysiology that forecasts a worsened prognosis in AIDS¹. This hypothesis is supported by a major role in the modulation of mood for the basal region of the right temporal lobe² dysregulating frontal function,³ hence a network of structures as in the case of right frontoparietal mediation of directed attention to extrapersonal space.⁴ In contrast, focal enhancement of the left parietal lobe on CT scan in a 33-year-old homosexual man who died 5 months after a violent outburst is supported by violence linked to the left hemisphere,⁵ in which the metabolic rate is higher in males.⁶

Ernest H. Friedman, M.D.
Case Western Reserve
University School of Medicine
East Cleveland, Ohio

References

1. El-Mallakh RS. Mania and paranoid psychosis in AIDS (letter). *Psychosomatics* 32:362, 1991
2. Friedman EH, Robinson RG. Speech hesitation pauses as markers for mood disorder in stroke patients? (letter and reply). *J Clin Psychiatry* 52:140, 1991
3. Friedman EH: Temporal lobe in schizophrenia (letter). *Br J Psychiatry* 157:784-785, 1990
4. Friedman EH, Spiers RA: Visual neglect (letter and reply). *Neurology* 41:609, 1991
5. Convit A, Czebor P, Volavka J: Lateralized abnormality in the EEG of persistently violent psychiatric inpatients. *Biol Psychiatry* 30:363-370, 1991
6. Friedman EH, Jacobs S: Anxiety disorders during acute bereavement (letter and reply). *J Clin Psychiatry* 52:241, 1991

Coming Up In the Next Issue

Prevalence of Mental Disorders in Newly Admitted Medical Inpatients With AIDS

By Stephen Snyder, M.D.,
Andrew Reyner, M.D.,
James Schneider, Ph.D., et al.

Body Dysmorphic Disorder: Diagnostic Issues and Related Disorders

By Eric Hollander, M.D.,
David Neville, M.D.,
Maxim Frenkel, M.D., et al.

During the course of the workshop, time was set aside for the presentation of very short clinical reports by the investigators. These short reports and their discussions are presented below.—*Editors*

Short clinical reports

C. N. Ellis, M.D.: I will report on serum lipid changes during etretinate therapy for psoriasis in a 56-year-old woman with adult-onset diabetes mellitus who consistently refused to take oral hypoglycemic agents or insulin. Her height was 157.0 cm, and her weight remained constant at 80.0 kg.

As shown in Fig. 1, during an 8-week placebo phase, her serum triglycerides averaged 655 mg/dl. In the first week of etretinate therapy at 1 mg/kg/day, her triglyceride level almost doubled to 1,285 mg/dl. Our protocol required a dose reduction to 0.5 mg/kg/day for the second week, and her triglycerides declined to 775 mg/dl. Subsequently, a strict diet was imposed which eventuated in a further decline to 215 mg/dl, despite a dose increase back to 1 mg/kg/day. At this point, the patient went off her diet, and while eating imprudently, her triglycerides rose to 1,975 mg/dl. Modest dietary controls resulted in a lowering of triglycerides. After etretinate was stopped, serum triglycerides declined to her placebo range. Serum cholesterol averaged 216 mg/dl during placebo and peaked at 355 at the same time that triglycerides were maximal. Her cholesterol also declined with dietary control. When etretinate was discontinued for 8 weeks, her cholesterol fell to 221 mg/dl, which was within her placebo range.

In summary, a diabetic patient is described who has significant increases in serum lipids during etretinate therapy, but whose lipid levels are responsive to dietary manipulation and to adjustments in etretinate dose.

I. M. Freedberg, M.D.: Could you define the diet for us? When you say strict diet, what does that mean?

C. N. Ellis, M.D.: For the strict diet, the patient closely followed our recommendation of a daily intake of 1,300 kcal, with 40% of the calories provided by carbohydrates, 20% by protein, and 40% by fat, with an approximate polyunsaturated to saturated fat ratio of 1:1. The patient refused to give complete details of her diet during her period of indiscretion, but she did admit to a high carbohydrate intake, and we suspect that the total caloric intake was excessive. The prudent diet has

no strict calorie limit, but requires that 50% of the calories be derived from carbohydrates, 20% from protein, and 30% from fats. Based on dietary history, our patient maintained these proportions with an average intake of approximately 1,800 kcal per day.

F. L. Meyskens, Jr., M.D.: I want to make one comment on the psychologic changes we have observed. We are largely treating advanced cancer patients with isotretinoin, so these remarks have to be taken into the context of that difficult clinical setting. Basically, these patients were treated with 3 mg/kg/day of isotretinoin. We initially did not notice any psychologic changes. Then in short order two incidents occurred; one patient decided to get divorced rather precipitously, and another patient's law partner noted he could not argue in court as well as he previously had been able to. The emotional symptomatology improved in both patients when the drug was stopped.

We became curious about that and not only started asking patients but also alerted our staff to look for emotional changes, depression, or any psychologic changes. While the patients in general would deny any changes, the families would indicate that changes had occurred. On this basis, we found psychologic changes in about 25% of our patients. It does not appear to be time-related because several of the changes were in the first month. It also does not seem to be predictive or related to the underlying personality type of the individual. It is probably important that you watch your patients for psychologic changes, particularly if they are on long-term therapy. It doesn't seem to be a serious problem, but it certainly seems to be there.

G. L. Peck, M.D.: In my acne patients I have done prospective psychologic testing along with psychologic interviews by my social worker. We have seen no evidence that isotretinoin can induce a depressive syndrome. In fact, we have seen a marked improvement in psychologic test scores. Patients are less depressed, less hostile, more self-confident, and so on. Admittedly, they are getting a lower dose than Dr. Meyskens's

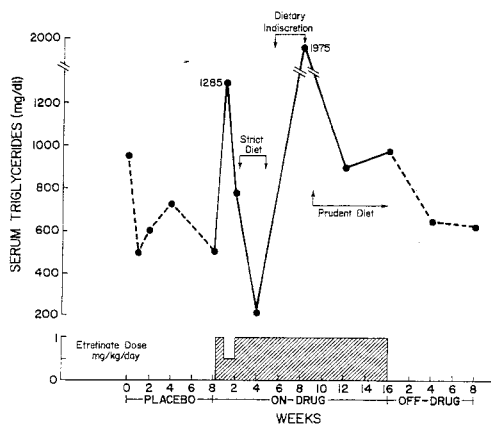


Fig. 1.

patients, and they have acne not cancer. But we have, additionally, treated patients with disorders of keratinization and multiple basal cell carcinomas with doses of isotretinoin as high as 8 mg/kg/day and have not seen the described adverse psychologic changes. My impression is that the behavioral changes reported may represent an inability of the cancer patients to tolerate the side effects of isotretinoin or may indicate an interactive effect between isotretinoin and certain metabolic or physiologic concomitants of metastatic carcinoma rather than a primary psychotoxic effect of isotretinoin.

V. J. Derbes, M.D.: I agree with Dr. Peck. We are comparing two dissimilar groups. In the case of benign but socially devastating conditions such as severe acne and so forth, the change is extraordinary. Not only is the affect of the patient greatly improved but also this radiates and permeates the family and those who love them and those who see them in school. In brief, that effect is entirely pleasing.

F. L. Meyskens, Jr., M.D.: I think the psychologic changes may be dose-related. In addition, I do not think that cancer patients per se are more depressed than other patients. In fact, the observation that we have made is unusual because we do not usually see these responses when we use hormones or cytotoxic drugs for cancer therapy. Many of the cytotoxic drugs are ten times worse in terms of total toxicity. The toxicity of isotretinoin in our minds is fairly inconsequential.

D. West, M.S.: Our group at the University of Illinois (Virginia C. Weiss, M.D., Rollie Ackerman, M.D., and Lisa Robinson, B.S.) found that one of twenty-two patients treated with etretinate for psoriasis developed a presumed etretinate-associated hepatitis. This will be reported elsewhere.

P. G. Hazen, M.D.: We have treated fourteen patients with isotretinoin at Case Western Reserve in Cleveland. Nine of those patients had Darier's disease, three had lamellar ichthyosis, and one each had pityriasis rubra pilaris and an epidermal nevus. Our patients with pityriasis rubra pilaris and epidermal nevus, respectively, had responses that were in the definitely improved range. However, both of these patients ultimately decided not to continue on the program largely because of side effects.

Our patients with Darier's disease and lamellar ichthyosis had clearing that was classified as definitely to markedly improved. One patient with Darier's disease cleared almost completely. Side effects that we observed agree with those observed by others. Cheilitis and conjunctivitis, in particular, were most common. Five members of one family with Darier's disease had triglyceride elevations. This elevation persisted (although decreased in quantity) after drug withdrawal, and it was our opinion they had a familial rather than a drug-induced hypertriglyceridemia.

L. A. Schachner, M.D.: At the University of

Miami during these last three years, Dr. Gerald Weinstein, Dr. Madelyn Lipman, and I used isotretinoin in the management of fourteen patients with disorders of keratinization. There were eleven female and three male patients; three of the patients were less than 15 years of age. Six patients had lamellar ichthyosis, four had epidermolytic hyperkeratosis, and four had Darier's disease. The average daily dose to sustain therapeutic effects was 1.6 mg/kg/day. Improvement started in 3 to 4 weeks. The optimal time for improvement was found to be 6 to 10 weeks. After therapy was stopped, relapses occurred after 4 to 5 weeks. However, even 8 weeks after therapy was discontinued, all of the patients reported that disease activity was far less than that prior to the onset of treatment. Dr. Dickens pointed out that some of the Darier's patients in subsequent studies have gone off medication for several months without clinical relapse. We concur in this finding, as several of our patients went for 3 to 4 months without substantial relapse.

All of the patients with epidermolytic hyperkeratosis had a significant and sometimes remarkable decrease in scaling while on therapy. Decreases in erythema paralleled the decrease in scaling. In comparison, while improvements were seen in the patients with lamellar ichthyosis, the response was not as great. Of the three diseases studied, in Darier's disease the reduction in scaling was the most dramatic. Crusting all but cleared, and the erythema showed considerable clearing.

In brief, more of our patients had problems with cheilitis than with conjunctivitis, as seen in many other groups. On the initial 16-week treatment period, six of the fourteen patients had elevated triglycerides. Our experience has been that the clinical benefits far outweighed the apparent risks in those patients who had severe disorders of keratinization that previously had been resistant to therapy.

G. L. Peck, M.D.: I have used both isotretinoin and etretinate in the treatment of disorders of keratinization. I observed approximately comparable responses to both retinoids in Darier's disease, lamellar ichthyosis, and chronic pityriasis rubra pilaris. Etretinate was superior in keratoderma palmaris et plantaris, ichthyosis vulgaris, X-linked ichthyosis, and epidermolytic hyperkeratosis. Two patients with Hailey-Hailey disease worsened with both retinoids. Increased blistering of the palms and soles occurred in one patient with epidermolytic hyperkeratosis treated with etretinate. Fritsch also reported increased palmar and plantar blistering in patients with pachyonychia congenita (*J Am J Dermatol* 20:314, 1981) and the epidermolytic type of keratoderma palmaris et plantaris (*Br J Dermatol* 99:561, 1978) treated with etretinate. Those patients with the dry, brown, hyperkeratotic type of Darier's disease respond better and may have more prolonged remissions than those with the red, inflamed, infected variety of Darier's disease. The latter patients are much more difficult to treat and relapse very quickly after therapy is stopped. Similarly, the response varies with the clinical subtype of pityriasis rubra pilaris. Patients with chronic pityriasis rubra pilaris, characterized in my series by childhood onset, myriads of follicular papules, and a duration of longer than 10 years, respond very dramatically to the retinoids and relapse dramatically on discontinuation. The adult-onset, erythrodermic, self-limited type of pityriasis rubra pilaris clinically has fewer follicular papules, and the therapeutic response to the retinoids is less impressive. In my series, the permanent clearing that occurs after therapy is most likely spontaneous and not induced by the retinoids.

piroxicam is unusual. However, patients who use piroxicam often also use additional analgesic drugs. Therefore some cases in which fixed drug eruption has been caused by piroxicam may have been missed because the other drugs have been blamed.

When cautious provocation is performed, as described by Kauppinen,¹⁰ a mild reaction is produced. Topical provocation can replace systemic testing with phenazone derivatives but with other drugs the results are not reliable.⁴

REFERENCES

1. Pasricha JS. Drugs causing fixed eruptions. *Br J Dermatol* 1979;100:183-5.
2. Kauppinen K, Stubb S. Fixed eruptions: causative drugs and challenge tests. *Br J Dermatol* 1985;112:575-8.
3. Stubb S, Alanko K, Reitano S. Fixed drug eruptions: 77 cases from 1981 to 1985. *Br J Dermatol* 1989;120:583.
4. Alanko K, Stubb S, Reitano S. Topical provocation of fixed drug eruption. *Br J Dermatol* 1987;116:561-7.
5. Bigby M, Stern R. Cutaneous reactions to nonsteroidal anti-inflammatory drugs: a review. *J AM ACAD DERMATOL* 1985;12:866-76.
6. Bertail M-A, Cavalier B, Civatte J. Réaction au piroxicam (Feldène). A type d'ectodermose érosive pluri-orificielle. *Ann Dermatol Venerol* 1982;109:261-2.
7. Torres H, Martí MR. Urticaria aguda por Piroxicam. *Med Cutan Ibero Lat Am* 1982;10:351-2.
8. Kauppinen K, Stubb S. Drug eruptions: causative agents and clinical types. *Acta Derm Venerol* 1984;64:320-4.
9. Savin JA. Drugs causing fixed eruptions. *Br J Dermatol* 1970;83:546-9.
10. Kauppinen K. Rational performance of drug challenge in cutaneous hypersensitivity. *Semin Dermatol* 1983;2:227-30.

Acute depression from isotretinoin

Pamela L. Scheinman, MD,* Gary L. Peck, MD, David R. Rubinow, MD, John J. DiGiovanna, MD, Donita L. Abangan, MD, and Paula D. Ravin, MD
Bethesda, Maryland

A spectrum of central nervous system side effects, similar to that observed with the hypervitaminosis A syndrome induced by retinyl esters has been described with other natural and synthetic retinoids.¹ For example, depressive symptoms, such as crying spells, malaise, and forgetfulness, have been noted in some patients receiving isotretinoin.² The depression subsides with discontin-

uation³ and recurs with reinstatement of therapy.⁴ In this article we describe seven patients in whom severe depression developed during isotretinoin therapy.

Material and methods. Seven patients, five women and two men, reported major depressive symptoms during treatment with oral isotretinoin. They participated in clinical trials of isotretinoin involving approximately 700 patients with cystic acne, psoriasis, cutaneous disorders of keratinization, or basal cell carcinoma. Patients involved in clinical trials were volunteers from whom informed consent was obtained.

The diagnosis of depression was made on the basis of the patients' spontaneous report of the recent onset of the cardinal symptoms of depression.⁵ The diagnosis of a major depressive disorder was confirmed by a psychiatrist (D. R. R.) in the three patients who were interviewed during their depression. The rapid resolution of depression after discontinuation of isotretinoin precluded a psychiatric interview while the remaining four patients were symptomatic.

Results. In five of the seven patients in whom depressive symptoms developed during treatment with isotretinoin, the symptoms developed during the first course of therapy. The other two previously had one or two courses of treatment with isotretinoin without depression (Table I).

The patients in this study voluntarily reported symptoms characteristic of a major depressive episode⁵ during treatment with isotretinoin (Table II). The severity of these symptoms interfered with normal functioning in most patients. In each patient isotretinoin therapy was discontinued when depressive symptoms were reported. All symptoms resolved within 2 to 7 days after discontinuation of the drug.

Although two patients had a history of mild depression, none required medication or hospitalization. The depressive episodes during isotretinoin therapy in patients 1 and 6 were much more severe than those previously experienced. During treatment in these two patients, fatigue, inability to concentrate, lack of motivation, forgetfulness, and crying spells also developed.

In one patient (No. 5) the relationship of depression to isotretinoin therapy was confirmed by rechallenge. In this patient symptoms developed during the tenth week of the initial course of isotretinoin (0.7 mg/kg/day). The depression resolved within 7 days after discontinuation of the medication. Ten weeks later treatment was resumed at 10 mg/day and after a month increased to 20 mg/day (0.3 mg/kg/day). The depression reappeared during the third month of this second course of therapy. Discontinuation of isotretinoin was again followed by rapid disappearance of depressive symptoms.

Three of seven patients also had headache during their depression. In one patient the headaches occurred daily and were not relieved by medication (acetaminophen). Headaches in all patients resolved after cessation of therapy. One patient had dizziness that also resolved promptly.

From the Dermatology Branch, National Cancer Institute, National Institutes of Health.

Reprint requests: Gary L. Peck, MD, Dermatology Branch, National Cancer Institute, National Institutes of Health, Bldg. 10, Room 12N238, Bethesda, MD 20892.

*Now at the Department of Dermatology, University of Rochester School of Medicine, Rochester, N.Y.

16/4/20231

Table I. Characteristics of therapeutic courses of isotretinoin associated with depression

Patient No.	Diagnosis	Age (yr)/ Sex	Time to onset* (wk)	Mean dosage		No. of prior courses	Headache	Time to clear† (days)
				mg/day	mg/kg/day			
1	Acne	31/M	8	80	1.3	2‡	-	7
2	Acne	22/F	10	40	0.7	0	+	7
3	Acne	24/F	14	40	0.7	0	-	2
4	Psoriasis	26/F	47	60	1.1	1§	+	4
5	Acne	42/F						
	1st course		10	40	0.7	0	+	7
	2nd course		8-12	17	0.3	1	-	2
6	BCC	47/F	7	40	0.5	0	-	2
7	Acne	26/M	6	40	0.5	0	-	7
Mean		32	14		0.7			

+, Present; -, absent; BCC, basal cell carcinoma.

*Time to presentation of depression after initiation of therapy.

†After discontinuation of therapy.

‡Mean dosage for first course was 0.3 mg/kg/day for 16 weeks; mean dosage for second course was 2 mg/kg/day for 26 weeks; interval between second and third course was 3.5 years.

§Mean dosage for first course was 2.4 mg/kg/day; interval between first and second course was 5 years.

Funduscopy examination in four patients during the depressive episode failed to identify papilledema. At the time of presentation none of the patients were taking other medications that have been implicated in the development of pseudotumor cerebri.⁶

Discussion. The results of this study suggest that depression is a rare side effect of isotretinoin that was spontaneously reported in 7 of approximately 700 patients. In these patients the onset of depression was related to neither dosage nor time. Irrespective of dosage, all depressive symptoms rapidly resolved within 1 week of cessation of medication. On the basis of the patients' psychiatric history, the development of a major depressive episode in all seven patients in this study most likely represents an idiosyncratic side effect of isotretinoin rather than a predictable effect in a subset of patients predisposed to develop major depressions.

Treatment with retinoids can produce benign intracranial hypertension (BIH).^{1,7} BIH also has been reported after the resolution of a major depressive syndrome.⁸ Nonetheless, depression was reported to precede by 1 year the diagnosis of pseudotumor cerebri in one patient with chronic hypervitaminosis A.⁹ BIH is characterized by (1) increased intracranial pressure, (2) normal cerebrospinal fluid composition, (3) normal radiographic studies, and (4) symptoms and signs that result from the increased intracranial pressure, such as headache, visual disturbances, and papilledema.⁶ Thus the symptoms of headache and depression observed in this study could suggest a diagnosis of BIH. However, the rapid resolution of the depression after discontinuation of isotretinoin in all patients and the negative funduscopy examination in four patients argue against a diagnosis of BIH. There-

Table II. Symptoms observed during isotretinoin treatment in seven patients developing a major depression

	No. of patients with symptom
Fatigue (increased sleep, loss of energy)	5
Irritability	4
Decreased concentration	4
Sadness	4
Crying spells	3
Loss of motivation (school, social contacts)	3
Forgetfulness	2
Suicidal ideation	1
Anhedonia	1
Abnormal dreams	1
Fear of going insane	1

fore no further diagnostic studies (e.g., lumbar puncture, computed tomographic scanning) were performed.

REFERENCES

1. Peck GL, DiGiovanna JJ. The retinoids. In: Fitzpatrick TB, Eisen AZ, Wolff K, et al., eds. *Dermatology in general medicine*. 3rd ed. New York: McGraw-Hill, 1986:2582-608.
2. Hazen PG, Carney JF, Walker AE, et al. Depression—a side effect of 13-*cis*-retinoic acid therapy. *J AM ACAD DERMATOL* 1983;9:278-9.
3. Meyskens FL, Jr. Short clinical reports. *J AM ACAD DERMATOL* 1982;6:732-3.

1114 Brief communications

4. Physicians desk reference, 43rd ed. Oradell, NJ: Medical Economics, 1988:1713.
5. Diagnostic and statistical manual of mental disorders, 3rd ed.—revised. Washington, DC: American Psychiatric Association, 1987:218-24.
6. Ahlskog JE, O'Neill BP. Pseudotumor cerebri. *Ann Intern Med* 1982;97:249-56.
7. Viraben R, Mathieu C, Fontan B. Benign intracranial hypertension during etretinate therapy for mycosis fungoides [Letter]. *J AM ACAD DERMATOL* 1985;13:515-7.
8. Ross DR, Coffey CE, Massey EW, et al. Depression and benign intracranial hypertension. *Psychosomatics* 1985; 26:387-93.
9. Restak RM. Pseudotumor cerebri, psychosis and hypervitaminosis A. *J Nerv Mental Dis* 1972;155:72-5.

Urticarial vasculitis and Lyme disease

Judyann C. Olson, MD, and Nancy B. Esterly, MD
Milwaukee, Wisconsin

Erythema chronicum migrans (ECM) is the classic skin lesion of Lyme disease, a multisystem disease caused by the spirochete *Borrelia burgdorferi*.¹ Other cutaneous manifestations of Lyme disease include localized and generalized urticaria, generalized macular eruptions, malar erythema in febrile patients,² and septal panniculitis.³ We describe a child with urticarial vasculitis as the presenting feature of Lyme disease.

Case report. A 4-year-old girl had sudden onset of erythematous, pruritic, indurated skin lesions that persisted for several days. Three weeks later the resolving skin lesions became increasingly echymotic. Results of a hemostasis screen were normal. Crops of new lesions then developed. The patient had diffuse arthralgias and angioedema of the lip and of the left side of the face. During the illness no fever, fatigue, or anorexia was associated. The patient's parents were uncertain whether she had been bitten by a tick; however, she had visited wooded areas in central Wisconsin. Review of systems was otherwise unremarkable.

Results of a physical examination were normal except for the presence of multiple erythematous, slightly elevated, indurated, plaque-like, urticarial lesions that did not blanch completely on diascopy. Many lesions were surrounded by a pale, 1 to 2 mm halo. The lesions were present on the face, ears, trunk, extremities, buttocks, and soles. Large echymoses were present at the sites of old lesions on the dorsum of the feet and on the lower extremities. No petechiae were seen. There was no evidence of synovitis.

Laboratory evaluation revealed the following results: white blood cells, $8.8 \times 10^3/\mu\text{l}$, with 47% segmented neutrophils, 17% bands, 30% lymphocytes, 4% monocytes, 1% eosinophils, and 1% reactive lymphocytes; hemoglobin, 11.2 gm/dl; platelets,

From the Department of Pediatrics, Divisions of Rheumatology and Dermatology, The Medical College of Wisconsin.

Reprint requests: Judyann C. Olson, MD, Department of Pediatrics, The Medical College of Wisconsin, MACC Fund Research Center, 8701 Watertown Plank Rd., Milwaukee, WI 53226.

16/4/16618

490,000/ μk , erythrocyte sedimentation rate, 45 mm/hr; albumin, 3.8 gm/dl; blood urea nitrogen, 7.0 mg/dl; creatinine, 0.4 mg/dl; SGOT (AST), 27 IU/L; SGPT (ALT), 11 IU/L; lactate dehydrogenase, 233 IU/L; total protein, 7.2 gm/dl; negative cryoglobulins; IgE, 18 U/ml (normal 37 to 70 U/ml); IgG, 1326 mg/dl (normal 434 to 1164 mg/dl); IgA, 133 mg/dl (normal 22 to 137 mg/dl); IgM, 90 mg/dl (normal 41 to 188 mg/dl); antinuclear antibodies, negative; rapid plasma reagin, negative; C3, 229 mg/dl (normal 86 to 166 mg/dl); C4, 19.8 mg/dl (normal 13 to 32 mg/dl); CH₅₀, 149 U/ml (normal 80 to 220 U/ml); hepatitis panel, negative; Epstein-Barr virus and cytomegalovirus titers, negative; polyvalent immunofluorescence antibody titer for *B. burgdorferi*, 1:256.

A skin biopsy specimen of a fresh lesion showed a lymphocytic infiltrate surrounding superficial and deep dermal vessels, some degeneration of the vessel walls, and invasion by lymphocytes and eosinophils (Fig. 1). No thrombi, fibrin deposition, erythrocyte extravasation, or nuclear debris was noted. Direct immunofluorescence studies failed to demonstrate deposition of IgG, IgM, IgA, C3, or fibrin in either vessel walls or at the dermoepidermal junction.

In light of the elevated titer for Lyme disease, treatment with phenoxymethyl penicillin, 50 mg/kg/day for 2 weeks, was initiated. Symptoms improved dramatically but did not resolve entirely; therefore treatment was extended for 1 month. At the end of treatment the arthralgias and all skin lesions had resolved. Telephone follow-up 7 months after treatment revealed neither recurrence of joint pain or skin lesions nor development of neurologic or arthritic symptoms.

DISCUSSION

Erythema chronicum migrans is the hallmark of Lyme disease.¹ However, Berger noted that a small number of patients (3/5) had secondary cutaneous manifestations. These included localized and generalized urticaria, malar erythema, and generalized macular eruptions.² One patient had ECM, and subcutaneous nodules subsequently developed. The biopsy specimen showed septal panniculitis without evidence of vasculitis.³

ECM is not always present. In a study of childhood Lyme arthritis, more than half the patients had no history of rash, tick bite, or prodromal illness. In the absence of rash the diagnosis can be made on the basis of a compatible exposure history, a compatible clinical syndrome, and immunofluorescence antibody titers of at least 1:256, the recognized value for a "positive" titer suggestive of *B. burgdorferi* exposure in an endemic area.⁴ Antibody testing for the Lyme spirochete is specific, with false-positive results chiefly limited to other spirochetal illnesses⁵ or, rarely, as a result of infectious mononucleosis or autoimmune disease.⁶ In our patient the history was not suggestive of another illness and results of serologic studies were negative for syphilis. The resolution of the illness with penicillin therapy, seropositivity suggestive of exposure, and residence in an endemic area supported the diagnosis of Lyme disease.

Although urticaria has been documented in patients with Lyme disease,² we are unaware of previous reports

278 Correspondence

2. Kligman AM, et al: New uses for benzoyl peroxide: A broad-spectrum antimicrobial agent. *Int J Dermatol* **16**: 413-417, 1977.
3. Faergemann J, Fredriksson T: Propylene glycol in treatment of tinea versicolor. *Acta Derm Venereol (Stockh)* **60**: 92-93, 1979.

Quinidine-induced psoriasis

To the Editor:

Quinidine is associated with many skin reactions, but an association with psoriasis has been reported only rarely. Recently a patient with an apparent exacerbation of psoriasis while on quinidine was seen and is now reported.

On May 3, 1982, a 64-year-old white male retired railroad conductor experienced acute anterior chest pain due to an acute myocardial infarction and was admitted to the hospital. On May 11 he underwent coronary artery bypass surgery. Prior to admission, during his recovery period, and throughout his posthospital convalescent period, his chronic psoriasis vulgaris of 25 years remained in remission. He had received once-weekly ultraviolet light therapy (PUVA, 8 joules) prior to his hospitalization but received no treatments after May 3. On June 29, he was begun on quinidine for an arrhythmia that had developed. Within 72 hours he noted slight scaling of his scalp, which progressed to include psoriatic plaques on the scalp, trunk, hands, elbows, and knees. He was restarted on twice-weekly PUVA therapy on August 6. He was begun at 1.5 joules and increased 0.5 joule per treatment. Despite PUVA therapy and topical steroid creams, the psoriasis continued to worsen. In October, 1982, the patient asked that the quinidine be stopped because he was convinced that it made his psoriasis worse. His physician reviewed the available literature, did not find an association between quinidine and psoriasis, and advised him not to stop the quinidine. However, the patient decided to stop the quinidine despite this advice without telling the physician. The psoriasis began to clear 1 week after stopping the quinidine, and all psoriatic lesions were gone within 2 weeks. He has remained free of psoriatic lesions since that time but has continued once-weekly PUVA therapy.

A more detailed search of the literature revealed two previously reported cases of quinidine^{1,2} exacerbating psoriasis. In addition to quinidine, other drugs reported as exacerbating psoriasis include the structurally related antimalarials, such as chloroquine,³⁻⁵ adrenergic agents such as propranolol,^{6,7} and clonidine⁸; agents which stimulate leukocytes, such as iodine,⁹

lithium,^{10,11} and the prostaglandin inhibitor, indomethacin.¹²

William B. Harwell, M.D.
1905 Hayes S
Nashville, TN 37206

REFERENCES

1. Gougerot B, Weill J: Erythrodermis quinidinique: anaphylactique chez une ancienne psoriasique: Transformation des lesions erythemateuses en parakeratose psoriasiforme, puis developpement du psoriasis. *Bull Soc Fr Dermatol Syph* **37**:1121-1123, 1930.
2. Baker H: The influence of chloroquine and related drugs on psoriasis and keratoderma biennorrhagicum. *Br Dermatol* **78**:161-166, 1966.
3. Ziprkowski L, Haim S, Bank H: Atabrine in psoriasis. *Acta Med Orient* **13**:45-52, 1954.
4. Cornbleet T: Action of synthetic antimalarial drugs on psoriasis. *J Invest Dermatol* **26**:435-436, 1966.
5. Witten VH, Sulsberger MB: Psoriasis: An interesting and perhaps distinctive response following quinacrine therapy. *Arch Dermatol* **73**:636-639, 1956.
6. Felix RH, Ives FA, Dahl MGC: Cutaneous and ocular reactions to practolol. *Br Med J* **4**:321-324, 1974.
7. Jensen H, Mikkelsen H, et al: Cutaneous reactions to propranolol (Inderal). *Acta Med Scand* **199**:363-364, 1976.
8. Wilkin J: Exacerbation of psoriasis during clonidine therapy. *Arch Dermatol* **117**:4, 1981.
9. Shelley WB: Generalized pustular psoriasis induced by potassium iodide. *JAMA* **13**:133-138, 1967.
10. Lowe NJ, Ridgway HB: Generalized pustular psoriasis precipitated by lithium carbonate. *Arch Dermatol* **11**: 1788-1789, 1978.
11. Skoven I, Thormann J: Lithium compound treatment of psoriasis. *Arch Dermatol* **115**:1185-1187, 1979.
12. Katayama H, Kawada A: Exacerbation of psoriasis induced by indomethacin. *J Dermatol (Tokyo)* **8**:323-324, 1981.

Depression—a side effect of 13-*cis*-retinoic acid therapy*To the Editor:*

Reported side effects of 13-*cis*-retinoic acid (isotretinoin) have included cheilitis, xerosis, skin fragility, bone aching, headache, stomach upset, alopecia, and corneal abnormalities.¹ We now wish to report another side effect recently observed by us—depression.

Six of 110 patients (5.5%) with acne or keratinization disorders treated with 1.0 to 2.0 mg/kg body weight per day experienced depressive symptoms while on the drug. The depression was present in five patients with acne and in a single patient with palmar-plantar keratoderma associated with hypohidrotic ectodermal dysplasia. Four patients were women and two were

American Academy
Dermatology

men. The mean age of affected patients was 28.5, with a range from 20 to 42 years. One patient had a previous history of depression. In a 21-year-old man, symptoms of depression and forgetfulness were severe enough to cause withdrawal of the drug. The other five patients continued with the drug despite feelings of depression.

All patients experienced depressive symptoms, manifested by crying spells (3/6), malaise (3/6), or forgetfulness (1/6), within 2 weeks of starting the drug. Symptoms rapidly resolved on discontinuing the drug.

Meyskens² noted similar psychologic changes in patients with cancer treated with 3 mg/kg/day of 13-*cis*-retinoic acid. Peck,³ however, saw psychologic improvement in his patients with acne treated with isotretinoin. It was not reported whether any of their patients had a previous history of psychiatric disorder.

Paul G. Hazen, M.D.

James F. Carney, M.D.

Allen E. Walker, M.D.

John J. Stewart, M.D.

*Department of Dermatology
University Hospitals of Cleveland
Cleveland, OH*

REFERENCES

1. Windhorst DB, Nigra T: General clinical toxicology of oral retinoids. *J AM ACAD DERMATOL* 6:675-682, 1982.
2. Meyskens FL Jr: Short clinical reports. *J AM ACAD DERMATOL* 6:732, 1982.
3. Peck GL: Short clinical reports. *J AM ACAD DERMATOL* 6: 732-733, 1982.

Stanford study of Sézary syndrome

To the Editor:

Stanford University Medical Center is opening a study for the treatment of mycosis fungoides (especially with Sézary syndrome). This is an experimental protocol using monoclonal antibodies which may be combined with interferon in some patients. Requirements for this study include: Karnofsky status greater than 70% (cares for self but unable to carry on normal activity or do active work), white blood cell count greater than 3,500, platelet count greater than 100,000, and off all treatment for 1 month prior to treatment. The patient should not have renal, hepatic, or cardiac dysfunction that would interfere with treatment. Additionally, the patient must be willing to commute to Stanford for a 4- to 8-week treatment program which requires two to three visits per week.

If you have a patient who meets these general eligi-

bility requirements, please contact Linda Rich, R.N., (address and phone number below). Thank you for your interest.

Linda Rich, R.N.

Ronald Levy, M.D.

Sandra Horning, M.D.

Thomas C. Merigan, M.D.

Stanford University Medical Center

Division of Oncology

Stanford, CA 94305/415-497-6886

Reproduction of hydroa vacciniforme with UVA

To the Editor:

We are pleased that Halasz et al (*J AM ACAD DERMATOL* 8:171-176, 1983) confirmed our observation that repetitive exposures to ultraviolet A (UVA) light reproduce the lesions of hydroa vacciniforme to clinical and histologic examination.¹ We constructed a dose-response relationship, showing that even suberythemogenic doses of UVA, when given repetitively at 48-hour intervals, could reproduce the papulovesicles of hydroa vacciniforme, whereas a single dose of up to 160 joules/cm² was ineffective in producing lesions other than erythema. Pathologic responses were neither produced nor enhanced by exposures to UVB light, either alone or in combination with UVA light. We observed that the antimalarial hydroxychloroquine sulfate, when given in doses of 200 mg by mouth daily, was dramatically effective in diminishing our patient's photosensitivity both subjectively and objectively. The number of repetitive applications of UVA light, the dose of UVA light per application, and the total dose of UVA light applied which were necessary to reproduce lesions of hydroa vacciniforme were all elevated after hydroxychloroquine sulfate therapy. In addition, the UVA minimal erythema dose rose from 12 joules/cm² to 20 joules/cm², both within the normal range. Indomethacin in doses of 200 mg by mouth daily did not affect the patient's photosensitivity.

We have further observed a low level of the third component of complement before therapy with hydroxychloroquine sulfate, with a return to the normal range after treatment and after cessation of disease activity.

It would be interesting to assess Halasz et al's patient in a similar manner with respect to therapy with antimalarials to confirm the usefulness of hydroxychloroquine sulfate in the treatment of hydroa vacciniforme. Photo-

Pseudotumor Cerebri Caused by Isotretinoin

Mark Roytman, MD, Oklahoma City, Oklahoma
 Azriel Frumkin, MD, Oklahoma City, Oklahoma
 Tim G. Bohn, MD, Oklahoma City, Oklahoma

A 16-year-old girl treated with isotretinoin at a dosage of 0.7 mg per kg each day experienced severe headaches and impaired night vision two months after the start of therapy. Bilateral papilledema and narrowing of the lateral ventricles of the brain were found. Pseudotumor cerebri and impaired night vision abated when isotretinoin was discontinued and systemic corticosteroids (dexamethasone) were administered.

Isotretinoin (13-*cis* retinoic acid) is a synthetic retinoid closely related to vitamin A. It is prescribed mainly by dermatologists for the treatment of severe acne. Pseudotumor cerebri is a dangerous complication of vitamin A therapy. Its occurrence following the use of isotretinoin is highlighted in the *Physicians' Desk Reference*.¹ This serious complication has received scant attention in the dermatologic literature. We report here a case of pseudotumor cerebri and transient impaired night vision in a young girl treated with isotretinoin for cystic acne.

Case Report

A 16-year-old girl had had severe acne since the age of eleven. Her treatment had included oral erythromycin and tetracycline as well as topical benzoyl peroxide and tretinoin. Her acne worsened, despite the treatment, and when seen by us, she had nodulocystic acne of the face and back. Her past and family history were noncontributory except that she smoked two packs of cigarettes a day.

Treatment with tetracycline at a dosage of 1000 mg per day for two months did not improve her condition and was stopped two months after we first saw her. One month later she was started on 40 mg of isotretinoin daily (0.7 mg per kg), after the risks involved in this therapy had been explained to her and to her family. Topical erythromycin was also prescribed. After two months of therapy she complained of spells of dizziness and of severe headaches, mostly frontal. These were aggravated by coughing. She also complained of impaired night vision, manifested by an inability to drive at night.

Results of complete physical and neurologic examinations were normal as were findings from a complete blood cell count, evaluations of blood chemistry, blood lipids, and liver function tests. X-ray studies of the paranasal sinuses and of the sella turcica also showed normal findings.

The examination of the optic fundi, however, showed papilledema with blurring of the optic disc margins bilaterally. Lumbar puncture was recommended, but the patient refused this procedure.

Computed axial tomography of the brain with and without contrast material infusion showed the basilar structures to be intact. The fourth ventricle was normal in size and in the midline. The frontal horns and bodies of the lateral ventricles were smaller than expected and slit-like. They were normal in configuration and position. The computed axial tomography scan was interpreted as showing findings consistent with pseudotumor cerebri. The impaired night vision was not tested objectively.

Following the diagnosis, the use of isotretinoin was stopped and oral dexamethasone therapy was instituted at a dosage of 16 mg per day. This was quickly tapered over a period of two weeks to a dosage of 1 mg per day.

Six weeks later, she was free of symptoms and the optic discs had improved; night vision had also recovered. Use of dexamethasone was discontinued. No changes in the complete blood cell count or blood chemistry values were observed throughout the episode.

Comments

Isotretinoin is prescribed mainly by dermatologists for the treatment of severe nodulocystic and conglobate acne that is unresponsive to other forms of therapy.² The drug is effective but its many side effects range from cheilitis to increased blood lipid levels and teratogenesis.³ The subject of retinoid toxicity has been addressed in many excellent reviews.³⁻⁵ Most of the reported adverse effects resemble those of vitamin A intoxication.⁶ There have, however, been few reports of isotretinoin-induced pseudotumor cerebri,^{7,8} especially in the dermatologic literature.⁹

Pseudotumor cerebri is characterized by neurologic and ophthalmologic complaints and signs pointing to increased intracranial pressure. The complaints include headaches, vertigo, nausea, and visual disturbances such as spells of diminished vision and transient diplopia. The neurologic examination usually shows normal findings except for the presence of various degrees of papilledema and occasional sixth nerve palsies. The cerebral ventricles are small to normal and are not shifted from the midline. No findings point to a localized or focal lesion.¹⁰ Lumbar puncture shows a cerebrospinal fluid of

Drs. Roytman and Bohn are in private practice. Dr. Frumkin is Associate Professor of Dermatology at the University of Oklahoma. REPRINT REQUESTS TO 3330 Northwest 56th Street, Suite 3 and 4, Oklahoma City, Oklahoma 73112 (Dr. Roytman).

normal composition except for an occasional low protein content.¹¹ The pressure of the cerebrospinal fluid, however, is elevated. It is important in every case of pseudotumor cerebri to exclude other conditions that cause increased cerebrospinal fluid pressure without localizing signs, such as certain tumors, subdural hematoma, inflammation, and mechanical obstruction.

Some cases of pseudotumor cerebri are caused by an excessive intake of isotretinoin or concomitant use of tetracyclines,^{7,8} which by themselves may very rarely cause pseudotumor cerebri.¹² In our case, however, the dosage of isotretinoin was not high and use of tetracycline had been discontinued long before isotretinoin therapy was begun.

Other toxic neurologic effects of isotretinoin include headaches without evidence of increased intracranial pressure, loss of libido, impotence, insomnia, effects similar to disulfiram, oculogyric crisis and psychiatric symptoms, especially depression.^{9,13}

Impaired night vision has been reported following the use of isotretinoin.¹⁴⁻¹⁶ This complication, presumably due to a toxic effect on the retinal rods,¹⁶ is much less known among dermatologists than the more common "dry eye."

Alertness to the possibility of pseudotumor cerebri should lead to a prompt neurologic and funduscopic examination of every patient taking isotretinoin who complains of severe headaches. The condition will usually improve when use of the drug is stopped and systemic corticosteroid therapy is begun. Patients whose condition does not improve quickly should be referred to a neurologist, who may re-evaluate the diagnosis or add other treatment modalities. Delay in diagnosis and therapy may lead to serious sequelae, such as permanent impairment of vision or even blindness.

REFERENCES

1. Physicians' Desk Reference, 42nd edition. Oradell, NJ, Medical Economics Co, 1988.
2. Shalita AR, Cunningham WJ, Leyden JJ, et al: Isotretinoin treatment of acne and related disorders: An update. *J Am Acad Dermatol* 9: 629-638, 1983.
3. Yob EH, Pochi PE: Side effects and long-term toxicity of synthetic retinoids. *Arch Dermatol* 123: 1375-1378, 1987.
4. Shalita AR: Mucocutaneous and systemic toxicity of retinoids: Monitoring and management. *Dermatologica* 175 (Suppl 1): 151-157, 1987.
5. Windhorst D, Nigra T: General clinical toxicology of oral retinoids. *J Am Acad Dermatol* 6: 676-682, 1982.
6. Jennekens GFL, Veeler CWM: Hypervitaminosis A. *Presse Med* 74: 2928-2959, 1966.
7. Spector RH: Pseudotumor cerebri caused by a synthetic Vitamin A preparation. *Neurology* 34: 1509-1511, 1984.
8. Adverse effects with isotretinoin. *FDA Drug Bull* 13:21-23, 1983.
9. Bigby M, Stern RS: Adverse reactions to isotretinoin. A report from the adverse drug reaction reporting system. *J Am Acad Dermatol* 18: 543-552, 1988.
10. Adams RA, Hochberg F: Pseudotumor syndromes. In: Harrison's Principles of Internal Medicine (Petersdorf RG, Adams RD, Braunwald E, et al, eds), 10th edition, p 2077-2078. New York, McGraw Hill, 1983.
11. Siegel NJ, Spackman TJ: Chronic hypervitaminosis A with intracranial hypertension and low cerebrospinal fluid concentration of protein. *Clin Pediatr* 11: 580-584, 1972.
12. Walters BNJ, Gubbay SS: Tetracycline and benign intracranial hypertension: Report of five cases. *Brit Med J* 282: 19-20, 1981.
13. Hazen P, Carney J, Walker A, et al: Depression—a side effect of 13-*cis* retinoic acid therapy. *J Am Acad Dermatol* 9: 278-279, 1983.
14. Weleber R, Denman S, Hanin J, et al: Abnormal retinal function associated with isotretinoin therapy for acne. *Arch Ophthalmol* 104: 831-837, 1986.
15. Feist RM, Kimble JA, Morris RE, et al: Visual side effects of isotretinoin therapy. *South Med J* 80: 1332, 1987.
16. Grattan CEH, Brown RD, Cowan MA, et al: Retinoids and the eye—reduced rod function with isotretinoin. *Br J Dermatol* 117 (Suppl 32): 23, 1987.

their homosexuality was known to 8% of their fellow service members, and that 11% of officers and 15% of enlisted personnel were also homosexual or bisexual.

Thirty of the 36 physicians report that their sexual orientation had no effect on their ability to perform military duties, four report a beneficial effect, and two claim an adverse effect. Thirty-four physicians report that their sexual orientation had no effect on the functioning of their military units; two claim a beneficial effect.

The Department of Defense should consider these physicians' experience and observations when reassessing its policy on sexual orientation. Further studies are needed to understand the medical care needs of homosexual and bisexual military personnel, including physicians, who serve their country in an organization that denies their very existence.

STANLEY E. HARRIS, MD
SRI VALLEY, CALIF

1. Council on Scientific Affairs: Health care needs of a homosexual population. *JAMA* 1982;248:730-739.
2. Kinsey AC: *Sexual Behavior in the Human Male*. Philadelphia, WB Saunders Co, 1948.

Diagnosis of Persistent Shoulder Pain

To the Editor.—An additional diagnosis to consider in the case of persistent shoulder pain is reflex sympathetic dystrophy.

For such diagnosis, the following special tests are useful: bone scan (scintigraphy), which may show hyperfixation of radioactive phosphate; repetition of roentgenography of the shoulder, which may now show localized osteopenia (Sudeck's atrophy); and thermography, either telethermography or liquid crystal contact thermography,¹ which may reveal either increased or decreased cutaneous temperature at the shoulder. In 27 cases of shoulder-hand syndrome, thermography results were positive in 18 of 25 studies of the back of the shoulder and in 11 of 18 studies of the front of the shoulder.

ARTHUR EGGER, MD
Community-General Hospital
Syracuse, NY

1. Persistent shoulder pain: Differential diagnosis. *JAMA* 1984;251:1344.
2. Doury P, Dichtimer Y, Patten S: *Algodystrophy*. New York, Springer Publishing Co Inc, 1981, pp 14, 55.
3. Ecker A: Reflex sympathetic dystrophy: Thermography in diagnosis. *Psychiatr Ann*, in press.

Liver Lover's Headache: Pseudotumor Cerebri and Vitamin A Intoxication

To the Editor.—We wish to draw attention to dietary habits of patients with pseudotumor cerebri (PTC), a syndrome of elevated intracranial

pressure that typically occurs in obese young women and is characterized by headache and papilledema. The nature of this condition is usually undiscovered but is associated with a variety of disorders, the most predictable of which is vitamin A intoxication. In fact, pseudotumor cerebri occurs in 30% to 50% of patients with hypervitaminosis A.^{1,2} This causal relationship prompted us to conduct a dietary survey of approximately 50 patients with idiopathic PTC.

Report of Cases.—Surprisingly, we discovered five patients who ate beef liver at least once or twice a week. Several patients consumed liver at multiple meals during a single day or regularly on luncheon sandwiches; two patients disclosed that they routinely purchased 6 to 24 lb of liver each week. None of the patients were using any of the medications occasionally associated with PTC. With the exception of mild to moderate papilledema, general physical and neurological examination findings were normal. Cranial computed tomographic scans were also normal, and CSF pressure was elevated in each of the four patients who permitted a lumbar puncture. Dietetic estimates of daily vitamin A intake in the five patients were 60,000 IU, 64,000 IU, 70,000 IU, 87,000 IU, and 241,000 IU. (Recommended dietary allowance is 4,000 to 5,000 IU/day.) Random serum vitamin A levels (normally 30 to 70 µg/dL) were elevated in four of the five patients (75 µg/dL, 107 µg/dL, 121 µg/dL, and 146 µg/dL). Two patients were men and three were women. All five patients were mildly to severely obese, and each had habitually ingested liver for several years or more. Skin manifestations of vitamin A intoxication were not observed in any of the patients; this suggests the possibility that neural membranes have the lowest level of sensitivity to chronic hypervitaminosis A.

Comment.—Acute vitamin A intoxication is widely acknowledged in Arctic explorers who ingested polar bear liver. A dietary source of acute hypervitaminosis A and documented PTC, however, was recently described in a housewife who ate the liver of a shark.³ Consumption of smaller amounts of vitamin A presumably has similar but more insidious effects. Farris and Erdman⁴ and others have reported PTC following protracted use of low-level (ten times the recommended daily allowance) vitamin A supplements. The induction of PTC from a diet of small but toxic amounts of vitamin A was previously limited to 7-month-old twins who were fed a diet containing 120 g/day of ground chicken liver for four months.⁵ In the five patients described herein, the amount of liver regularly consumed for several years or more was astonishing but was

verified from interviews with skilled dietitians.

These observations in adults warrant closer attention to the possibility of habitual ingestion of liver and other dietary sources of vitamin A in patients with PTC. Added scrutiny of the diet is further justified because liver and vegetables rich in vitamin A are often recommended in weight-reducing diets.

JOHN B. SELKORST, MD
EDWARD A. WARBURG, MD
SANDRA JENNINGS, RD
Medical College of Virginia
Richmond
JAMES J. CORRETT, MD
University of Iowa
Iowa City

1. Muenster MD, Perry HO, Ludwig J: Chronic vitamin A intoxication in adults. *Am J Med* 1971;50:129-136.
2. Lombart A, Carton H: Benign intracranial hypertension due to A-hypervitaminosis in adults and adolescents. *Eur Neurol* 1976;14:240-250.
3. Misbah SA, Ferris JB, Anukorala TMS: Ingestion of shark liver associated with pseudotumor cerebri due to acute hypervitaminosis A. *J Neurol Neurosurg Psychiatry* 1984;47:216-220.
4. Farris WA, Erdman JW Jr: Protracted hypervitaminosis A following long-term, low-level intake. *JAMA* 1982;247:1317-1318.
5. Maloney CP, Margolis T, Knazus TA, et al: Chronic vitamin A intoxication in infants fed chicken liver. *Pediatrics* 1980;65:808-809.

Gender of Companions

To the Editor.—I am struck by the letter of Richard F. Herndon, MD, concerning companions.

Except for a passing reference to a grown daughter or son, all examples of companions given are female. This corresponds to my own observations.

I agree with Dr Herndon that the companion is almost always relevant, has an influence on care, and should be catered to.

However, I do not understand how Dr Herndon asks the companion "why he came."

FRANKLIN DRUCKER, MD
Santa Monica, Calif

1. Herndon RF: The companion. *JAMA* 1984;251:2936.

Effects of Food on Behavior

To the Editor.—In the QUESTIONS AND ANSWERS section of THE JOURNAL, an inquiry was made regarding behavioral abnormalities and food sensitivity in a 4-year-old child. I found the consultant replies to be succinct and to the point, but I feel attention should be paid to possible neurological disorders. The case as presented was characterized by a symptom complex that included headache, abdominal pain, and mood changes. Such a picture could arise as a result of childhood migraine. At this age, an attack may take the form of an acute confusional state with or without other migrainous accompaniments.¹ Dysphoria or mental status changes also

High Levels of Dopamine D₂ Receptor Occupancy With Low-Dose Haloperidol Treatment: A PET Study

Shitij Kapur, M.D., F.R.C.P.C., Gary Remington, M.D., Ph.D., F.R.C.P.C.,
Corey Jones, B.Sc., Alan Wilson, Ph.D., Jean DaSilva, Ph.D.,
Sylvain Houle, M.D., Ph.D., F.R.C.P.C., and Robert Zipursky, M.D., F.R.C.P.C.

Objective: The purpose of this study was to determine the dopamine D₂ receptor occupancy induced by low-dose haloperidol treatment in a prospective trial. **Method:** Seven patients with schizophrenia were treated with 2 mg/day of haloperidol for 2 weeks, and D₂ receptor occupancy was measured by [¹¹C]raclopride and positron emission tomography. **Results:** The patients showed high levels of D₂ occupancy (53%–74%); five of them showed substantial clinical improvement, and none showed important side effects. **Conclusions:** The findings demonstrate that low doses of haloperidol induce D₂ receptor occupancies that are in the putative therapeutic range. In combination with recent empirical trials, these findings should encourage clinicians to initiate treatment of psychotic episodes with low (2–4 mg haloperidol equivalent) doses of typical neuroleptics, particularly for first-episode patients.

(Am J Psychiatry 1996; 153:948–950)

Recent evidence suggests that treatment of acute psychosis with low doses of typical neuroleptics is as effective as high-dose treatment and is better tolerated (1–3). These studies suggest that 2–4 mg/day of haloperidol may be an optimal starting dose for most patients (1–3), with first-episode patients requiring lower doses (2). While it is generally held that typical neuroleptics act through dopamine D₂ blockade, the precise relation between events at the receptor level and clinical response is not clear. If the mechanism of action of antipsychotics were better understood at the receptor level, and if it could be demonstrated that low-dose treatments achieve the required effect at the receptor level, then the argument for low-dose treatment would be strengthened further.

It is speculated that D₂ blockade in the mesolimbic regions may be the most relevant pharmacological effect of typical neuroleptics (4). Because of a low density of D₂ receptors in the mesolimbic regions, they are not reliably visualized with the current positron emission

tomography (PET) techniques. However, the affinity of the striatal D₂ receptors for haloperidol is the same as that of the mesolimbic receptors (4). Therefore, striatal D₂ blockade can be used as an indirect measure of mesolimbic blockade until such time as direct, reliable PET measures of the mesolimbic D₂ receptors become available. Toward this end, recent PET studies have shown that patients with striatal D₂ occupancy greater than 50%–60% had a better response than those with lower receptor occupancy (5). In addition, patients with occupancies greater than 80% have a higher chance of experiencing extrapyramidal side effects, as compared with those with lower D₂ occupancies (6). Thus, there may be a “therapeutic window” of striatal D₂ occupancy, below which treatment is ineffective and above which side effects become problematic (5). The lowest dose of haloperidol required to reach this therapeutic window of D₂ occupancy is not yet established. The present study was undertaken to establish the degree of D₂ occupancy with low-dose haloperidol treatment (2 mg/day) in a prospective-dosing clinical study.

Received Oct. 18, 1995; revision received Feb. 22, 1996; accepted March 18, 1996. From the Schizophrenia Research Program and the PET Centre, The Clarke Institute of Psychiatry, University of Toronto. Address reprint requests to Dr. Kapur, PET Centre, The Clarke Institute of Psychiatry, 250 College St., Toronto, Ont., Canada M5T 1R8. E-mail: kapur@clark-inst.on.ca.

Supported by an award from the National Alliance for Research in Schizophrenia and Depression and by an award from the Medical Research Council of Canada to Dr. Kapur.

The authors thank professors Philip Seeman, Philip Janicak, and Peter Liddle for their suggestions and Astra Arcus AB for providing the precursor used in the synthesis of [¹¹C]raclopride.

METHOD

Seven patients (two female and five male) with acute psychosis and a diagnosis of schizophrenia (DSM-III-R) participated in this study, which was carried out in the First Episode Psychosis Program at the Clarke Institute of Psychiatry. Written consent, as approved by the University of Toronto Review Committee on the Use of Human Subjects, was obtained prior to the study. Patients were treated with a fixed dose of 2 mg of haloperidol nightly for 2 weeks. Symptom severity was rated with the Positive and Negative Syndrome Scale (7).

TABLE 1. Data on Seven Patients With Schizophrenia Given Low Doses of Haloperidol

Patient ^a	Age (years)	Sex	Other Medications	Haloperidol Level (ng/ml) ^b	CGI ^c Score	Positive Symptom Score ^d		Negative Symptom Score ^d		D ₂ Receptor Occupancy (%) ^f
						Pretreatment	Posttreatment ^e	Pretreatment	Posttreatment ^e	
1	32	M	Lorazepam	0.7	2	27	18	9	9	63
2	37	F	—	—	3	22	16	9	8	69
3	26	M	—	1.1	2	15	11	22	15	66
4	22	M	Lorazepam plus bentrzopine	1.5	2	21	13	8	7	71
5	30	M	—	0.6	3	23	17	25	17	53
6	20	F	Lorazepam	1.4	2	31	23	29	15	69
7	23	M	—	1.3	2	16	9	23	15	74

^aFive of the seven patients were neuroleptic-naive. Patients 2 and 7 had had less than 1 month of exposure to oral neuroleptics more than 6 months before this episode of treatment.

^bPlasma level of haloperidol plus reduced haloperidol. The coefficient of variance in measurement at these levels was less than 7%. A plasma sample was inadvertently missed at the time of scanning for patient 2.

^cClinical Global Impression scale. Minimal improvement=1, much improvement=2. Patients 1, 3, 6, and 7 continued on a regimen of 2 mg/day of haloperidol after the end of the fixed-dose phase of the trial.

^dPositive and Negative Syndrome Scale. Each score represents a sum of seven items, and a score of 7 is "normal" on this scale.

^eAfter 2 weeks of treatment.

^fAll subjects except patients 1 and 6 provided their own baseline. For these two, age-controlled baseline estimates were obtained from 12 neuroleptic-naive patients with schizophrenia.

and the Clinical Global Impression (CGI) (8) scale. Side effects were rated with the Extrapyramidal Symptom Rating Scale (9). Clinical ratings were completed, before patients received the first dose of medication and after 2 weeks of treatment, by a rater blind to the receptor status (S.K.). The D₂ receptor status was assessed with the use of PET and [¹¹C]raclopride before and 10–14 days after haloperidol treatment. The PET scans were obtained 12–14 hours after the last dose of haloperidol, at which time plasma was obtained for the measurement of haloperidol and reduced haloperidol by gas/liquid chromatography.

The PET scans were performed with 10 mCi of high-specific-activity [¹¹C]raclopride (300–1600 Ci/mmol) and a General Electric 2048-15B head scanner, as described earlier (10). The striatal and cerebellar regions of interest were drawn on two contiguous PET slices with reference to a coregistered magnetic resonance image (GE Signa 1.5-T scanner, spin-echo sequence, T₂-weighted) by a rater blind to the clinical status of the patients (C.J.). On the basis of work by Farce et al. (11), the cerebellar time-activity curve was taken as an estimate of free and nonspecific [¹¹C]raclopride binding. The striatal time-activity curve provided an estimate of specific binding to the D₂ receptors plus free and nonspecific binding. Therefore, the striatal minus the cerebellar time-activity curve estimated the [¹¹C]raclopride bound specifically to the D₂ receptors. The specific and cerebellar binding curves were fitted by a nonlinear least squares method to provide an estimate of the ratio of the maximum number of binding sites (B_{max}) to the dissociation constant (K_d) (10, 12). The B_{max}/K_d ratio provides a valid index of the number of available D₂ receptors and has been used in most previous studies of receptor occupancy (5, 6). Haloperidol-induced D₂ receptor occupancy was determined as follows: (R_{post} - R_{ON})/R_{pre}, where R_{post} is the B_{max}/K_d ratio prior to treatment, and R_{ON} is the ratio when the patient was on the haloperidol regimen.

RESULTS

Table 1 shows demographic and clinical characteristics of the subjects. Treatment with 2 mg/day of haloperidol resulted in striatal D₂ occupancy levels ranging from 33% to 74% (mean=67%, SD=7%). Plasma concentrations of total haloperidol ranged from 0.6 to 1.5 ng/ml (mean=1.1 ng/ml; SD=0.36). None of the patients exhibited clinically significant extrapyramidal symptoms at the time of scanning. One of the subjects (patient 5) had a rating of "borderline" parkinsonism (a

score of 1 out of 7 on the parkinsonism global impression rating in the Extrapyramidal Symptom Rating Scale) because of stiff gait and posture even before treatment with a neuroleptic and a rating of "very mild" (2 out of 7) because of stiff gait and posture after treatment. However, he had no other signs and did not require anticholinergic treatment. Another subject (patient 4) complained of restlessness, presumably akathisia, and received bentrzopine 12 hours before the PET scan. He had no restlessness or akathisia at the time of scanning, although the bentrzopine may have affected his akathisia evaluation. Five patients were considered to be "much improved" and two were "minimally improved" according to the CGI change scores. The Positive and Negative Syndrome Scale scores declined from an average of 22 to 15 for positive symptoms (paired t test, t=10.8, df=6, p<0.0001) and from 18 to 12 for negative symptoms (paired t test, t=2.88, df=6, p<0.001) (table 1).

DISCUSSION

This study demonstrates that 2 mg/day of haloperidol occupies a high proportion (average=67%) of striatal D₂ receptors. While the study group was small, the study provides the best evidence to date of D₂ occupancy in patients treated prospectively with a fixed low dose of haloperidol. It has been shown that patients who achieved D₂ occupancies of 50%–60% or higher had much greater clinical response than those with lower occupancies (5). On the other hand, a series of clinical trials showed that a low dose of haloperidol (mean=3.7 mg [2], mean=4 mg [3], and mean=3.3 mg [1] for chronic patients and mean=2.1 mg for first-episode patients [2]) is as effective as 10–60 mg/day of haloperidol in acute psychosis. Our results link these findings. They show that 2 mg of haloperidol resulted in high receptor occupancy (the average

BRIEF REPORTS

was greater than 65% in five of seven patients), a level that would be in the putative therapeutic range (5). At the same time, it resulted in "much improvement" in five of seven patients according to the CGI change scores, consistent with the findings of the series of low-dose trials (1-3).

There was a positive relation between the percent improvement in positive and negative symptoms and D_2 occupancy (Spearman's rank correlations, one-tailed; between percent positive symptom improvement and D_2 occupancy: $r_s=0.57$, $N=7$, $p=0.09$; between negative symptom improvement and D_2 occupancy: $r_s=0.79$, $N=7$, $p=0.02$), which is in agreement with the findings of Nordstrom et al. (5). However, given the small study group, the limited variation in receptor occupancy, and the lack of a placebo control group, we consider these correlations tentative until they are replicated in a larger group.

Patients in this study were young (20-37 years), with little previous exposure to neuroleptics, and all but one (patient 3) were experiencing a first episode of psychosis. Would the D_2 occupancy have been different if the patients had been chronically treated with neuroleptics? McEvoy et al. (2) have shown that at a clinical level, first-episode patients are more sensitive to neuroleptics, with a median "neuroleptic threshold" for extrapyramidal symptoms at 2 mg/day of haloperidol, as opposed to previously exposed patients, who required 4 mg/day. At this time, there are no PET data directly comparing receptor response of first-episode and chronically treated patients. Wolkin and colleagues (13) reported that chronic patients showed 60%-70% D_2 occupancy at a plasma concentration of 4-5 ng/ml of haloperidol, whereas the first-episode patients in our study did so with only 1-1.5 ng/ml. Whether this reflects a systematic effect of neuroleptic exposure, resulting perhaps from D_2 receptor up-regulation, or whether it reflects a technical difference is not clear at present. However, the available evidence does suggest that the question merits a more controlled comparison.

There is considerable variability in individual response to neuroleptics. The fact that some patients may require higher doses does not mean that all patients should be started on high doses (1, 2). We conclude that 2 mg/day of haloperidol results in a high degree of D_2 receptor occupancy, and in this small group of first-episode patients, this resulted in substantial clinical improvement. In light of the emerging understanding of the relation between D_2 receptor occupancy and re-

sponse (5, 6), and in concert with recent empirical clinical trials (1-3), our findings should encourage clinicians to begin treatment with low (2-4 mg haloperidol equivalent) doses of typical neuroleptics, particularly for first-episode patients.

REFERENCES

- Janicak PG, Javadi JI, Sharma RP, Leach AM, Dowd S, Davis JM: A double-blind randomized study of three haloperidol plasma levels for acute psychosis. In New Research Program and Abstracts, 148th Annual Meeting of the American Psychiatric Association, Washington, DC, APA, 1995
- McEvoy JP, Hogarty GE, Steingard S: Optimal dose of neuroleptic in acute schizophrenia: a controlled study of neuroleptic threshold and higher haloperidol dose. *Arch Gen Psychiatry* 1991; 48:739-745
- Stone CK, Gasser DL, Guffrich J, Herschowitz J, Bennett J: Further evidence of a dose-response threshold for haloperidol in psychosis. *Am J Psychiatry* 1993; 152:1213-1217
- Seeman P: Atypical neuroleptics: role of multiple receptors, endogenous dopamine, and receptor linkage. *Acta Psychiatr Scand* 1990; 82:14-20
- Nordstrom AL, Farde L, Wiesel FA, Forslund K, Pauli S, Hallidin C, Uppfeldt G: Central D2-dopamine receptor occupancy in relation to antipsychotic drug effects—a double-blind PET study of schizophrenic patients. *Biol Psychiatry* 1993; 33:227-235
- Farde L, Nordstrom AL, Wiesel FA, Pauli S, Hallidin C, Sedvall G: Positron emission tomographic analysis of central D1 and D2 dopamine receptor occupancy in patients treated with classical neuroleptics and clozapine: relation to extrapyramidal side effects. *Arch Gen Psychiatry* 1992; 49:538-544
- Kay SR, Fiszbein A, Opler LA: The Positive and Negative Syndrome Scale (PANSS) for schizophrenia. *Schizophr Bull* 1987; 13:261-276
- Guy W (ed): *ECDEU Assessment Manual for Psychopharmacology*. Publication ADM 76-533. Rockville, Md, US Department of Health, Education, and Welfare, 1976, pp 217-222
- Chouinard G, Ross-Chouinard A, Annable L, Jones BD: Extrapyramidal Symptom Rating Scale (ESRS). *Can J Neuro Sci* 1980; 7:233-245
- Kapur S, Remington G, Zipursky RB, Wilson AA, Houle S: The D2 dopamine receptor occupancy of risperidone and its relationship to extrapyramidal symptoms: a PET study. *Life Sci* 1993; 57:PL103-PL108
- Farde L, Eriksson L, Blomqvist G, Hallidin C: Kinetic analysis of central [¹¹C]-raclopride binding to D2-dopamine receptors studied by PET—a comparison to the equilibrium analysis. *J Cereb Blood Flow Metab* 1989; 9:696-708
- Houle S, Kapur S, Hasse D, Jones C, DaSilva J, Wilson AA: Measurement of [¹¹C]-raclopride binding using a bolus plus infusion protocol. In *Quantification of Brain Function Using PET*. Edited by Myers R, Cunningham B, Bailey D, Jones T. San Diego, Academic Press, 1996, pp 262-265
- Wolkin A, Brody JD, Barouche F, Roserosen J, Wolf AP, Smith M, Fowler J: Dopamine receptor occupancy and plasma haloperidol levels. *Arch Gen Psychiatry* 1989; 46:482-483



Brève communication

Hypertension intracrânienne bénigne et hypervitaminose A chronique

A. Drouet¹, J. Valance²

¹ Service de Neurologie, H.I.A. Desgenettes, Lyon.
² Service de Neurologie, H.I.A. Sainte-Anne, Toulon.

RÉSUMÉ

Les auteurs rapportent un cas d'hypertension intracrânienne bénigne survenue au cours d'une intoxication chronique par la vitamine A, et le rapprochent de 30 cas décrits dans la littérature, chez l'adulte et l'adolescent. Il s'agissait le plus souvent de femmes jeunes, de poids normal, traitées pour de l'acné par la vitamine A à posologie et durée variables, qui développaient un tableau d'hypertension intracrânienne bénigne identique dans la moitié des observations. Dans tous les cas les troubles neurologiques régressèrent à l'arrêt de l'intoxication. Une hypertension intracrânienne bénigne en tout point identique peut être produite par l'acide rétinolique, comme le montrent cinq autres cas. En dépit d'une meilleure connaissance du métabolisme de la vitamine A, le mécanisme de sa neurotoxicité n'est pas clairement établi. Ainsi, la diminution du risque de l'hypervitaminose A passe d'abord par le respect d'un emploi bien codifié.

Benign intracranial hypertension due to chronic A-hypervitaminosis.
 A. Drouet, J. Valance. Rev Neurol (Paris) 1998 ; 154 : 3, 253-256.

SUMMARY

We report a case of benign intracranial hypertension due to chronic A-hypervitaminosis and a review of literature with 30 cases in adults and adolescents. The most prominent clinical features are: predominance of young women with normal weight and cured for acne; benign intracranial hypertension without other symptoms in half of cases; wide difference of daily doses and time of continuous intake. Prognosis for vitamin A intoxication is good, when intake of vitamin is discontinued. We reviewed five cases of benign intracranial hypertension due to retinoic acid. The mechanism of vitamin A neurotoxicity is still unknown.

Gerber *et al.*, (1954), rapportaient le premier cas bien documenté chez l'adulte, d'une hypertension intracrânienne (HIC) apparue au cours d'un traitement prolongé par la vitamine A (rétinol), alors principalement indiquée dans le traitement d'affections cutanées (acné, ichtyose, maladie de Darier). La constatation de nombreux effets adverses, dont l'HIC, devait conduire à limiter son utilisation et au développement dans les années 1970 des rétinoïdes, comprenant l'acide rétinolique (AR), métabolite physiologique de la vitamine A, et des dérivés aromatiques. Mais il apparut rapidement qu'un tableau d'HIC pouvait survenir aussi avec l'acide rétinolique (Spector et Carlisle, 1984). Nous rapportons un cas d'HIC secondaire à une intoxication chronique par la vitamine A, en le rapprochant des cas déjà décrits. Il nous paraît important d'insister sur cette complication car l'AR déjà très utilisé, voit ses indications s'étendre, en particulier à l'oncologie (Defer *et al.*, 1996).

OBSERVATION

Cas n° 940915. Une femme de 51 ans, sans profession, droitère, installa brutalement dans la nuit du 18 au 19 septembre 1994, une céphalée violente, accompagnée de nausées et de vomissements, puis à partir du 24 septembre, d'une diplopie binoculaire horizontale. Dans ses antécédents, elle avait présenté une phlébite surale post-opératoire et des accès migraineux. En raison de troubles anxio-dépressifs présents depuis 15 ans, mais non récemment aggravés, elle bénéficiait d'un soutien psychotérapeutique et d'un traitement par Zolpidem (10 mg au coucher), Méprobamate-acéprométazine (1 comprimé au coucher), et Clonazepam (60 mg par jour). Elle souffrait plus récemment de troubles liés à la ménopause. Enfin, elle avoua s'automédiquer depuis plusieurs années, de façon intermittente, en raison d'une ichtyose avec de la vitamine A : ainsi prenait-elle quotidiennement depuis cinq mois du Rétinol (A313*) à une posologie de 100 000 UI. Le 26 septembre, l'examen retrouvait chez cette patiente bien vigilante et orientée, normotendue et apyrétique, à la surcharge pondérale modérée (77 kg pour 165 cm), une paré-

Tirés à part : A. DROUET, Service de Neurologie, Hôpital d'Instruction des Armées Desgenettes, 108, boulevard Pinel - F-69275 Lyon cedex 03.

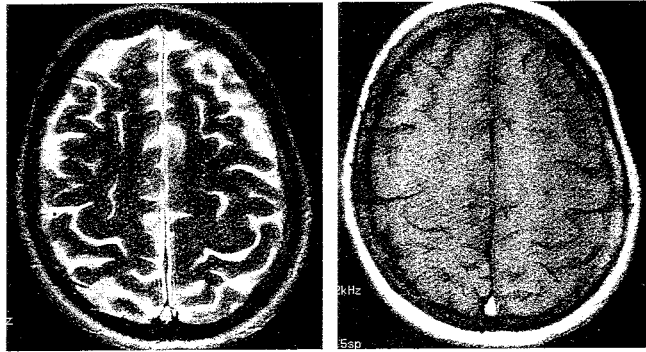


Fig. 1. - IRM cérébrale c
septembre 1994, coupes
es : e sinus longitudinal s
neur (SLS) est hyperintens
séquence T2 (TR : 4 000
TE : 119 ms) (a), comm
(TR : 500 ms ; TE : 18 ms
1,5 T MR transverse cer
images (26 septembre 199
T2 (TR : 4 000 ms ; TE : 119
a hyperintense signal sui
sagittal sinus. b) and in T1
500 ms ; TE : 18 ms).

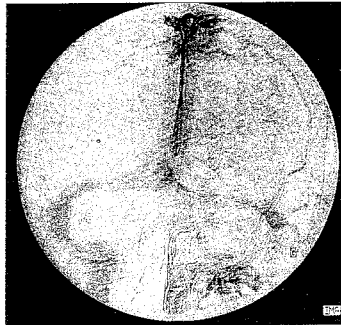


Fig. 2. - Artériographie cérébrale du 27 septembre 1994, temps veineux : as-
trie des sinus latéraux aux dépens du gauche, qui paraît effilé et mal visualisé
Cerebral angiogram in the late venous phase, 27 septembre 1994 demonstrat
lack of filling, on antero-posterior view, in left lateral sinus.

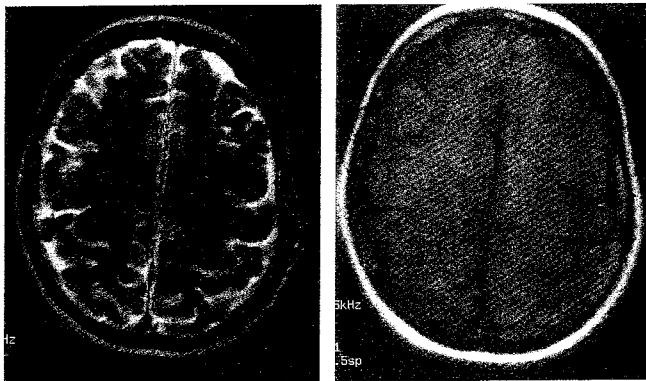


Fig. 3. - IRM cérébrale c
octobre 1994, coupes axia
a) séquence T2 : le SLS
signal normal hypointe
b) comme en T1.
MR transverse cerebral ima
6 octobre 1994 : a) the sup
sagittal sinus now hav
hypointense signal T2, b) a
T1.

sie des muscles droits externes, une sécheresse cutanée, et un œdème papillaire bilatéral, plus marqué à gauche, avec quelques hémorragies en flammèche. L'acuité visuelle était normale. Le scanner X cérébral montrait une petite plage hypodense en regard de la corne occipitale gauche, qui en imagerie par résonance magnétique (IRM) était en net signal hyperintense en T2, faiblement hypointense en T1, et non rehaussée lors de l'injection de gadolinium; hyperintense en T2 (fig. 1a) et T1 (fig. 1b), le signal était ainsi anormal de la partie moyenne du sinus longitudinal supérieur (SLS) au sinus latéral (SL) gauche. Les cavités ventriculaires étaient de taille normale. La ponction lombaire mit en évidence un liquide clair sous pression (non mesurée), cellulièrement et biochimiquement normal. L'angiographie cérébrale (27 septembre) montrait un remplissage hétérogène et retardé du SLS et du SL gauche de diamètre inférieur au droit (fig. 2). Les seules anomalies biologiques sanguines étaient une élévation des triglycérides à 2,02 mmol/l (N: 0,35-1,60), des transaminases SGOT à 102 U/l (N: < 40) et SGPT à 137 U/l (N: < 50), des gamma GT à 313 U/l (N: < 32) et de la créatinémie à 166 µmol/l (N: 62-98). Le dosage sanguin de la vitamine A donnait le 27 septembre un taux élevé à 4,04 µmol/l pour une normale entre 1,55 et 3,3. Les données de l'imagerie faisant discuter une obstruction partielle des SLS et SL gauche, un traitement par héparine calcique fut prescrit du 27 septembre au 12 octobre, à dose anticoagulante, sans relais par les AVK, tandis que la vitamine A était interrompue. L'évolution clinique fut rapidement favorable en une dizaine de jours, sans récédive depuis. L'IRM du 6 octobre notait le retour à la normale du signal intra-luminal du SL gauche et du SLS redevenu hypointense en T2 (fig. 3a) et T1 (fig. 3b). L'œdème papillaire était un peu moins marqué à cette date et les anomalies biologiques hépatiques étaient réduites de moitié lorsqu'elle sortit le 12 octobre.

COMMENTAIRES

Comme dans les 30 cas d'intoxication chronique par la vitamine A et les 5 causées par l'acide rétinolique (AR) colligés chez des sujets de plus de 14 ans, notre observation réalise un tableau d'hypertension intracrânienne bénigne (HICB) (Johnston et Paterson, 1974); elle est habituellement pure et souvent isolée sans autre signe d'intoxication (17 cas sur 36). Il existe une nette prédominance féminine (77,21 p. 100) avec une moyenne d'âge de 19,69 ans (extrêmes de 14 et 51 ans). Dans les cas d'intoxication chronique par le rétinol, la dose quotidienne toxique variant de 10 000 à 500 000 UI (moyenne de 176 000 UI), sans corrélation avec la durée moyenne de la prise, égale à 23,39 mois avec des extrêmes de 0,75 et 84 mois (5000 à 10 000 UI/24 H étant recommandées en cas d'état carenciel). Pour l'AR, en dehors du cas de Spector et Carlisle (1984), la posologie était non excessive et cela durant une période de 1,25 à 10 mois (moyenne de 3,75 mois). Un œdème papillaire, le plus souvent bilatéral ne manquait qu'une fois, tandis que le LCR était de composition normale mais hypertendu. Le scanner X cérébral (13 cas) montrait 3 fois une réduction de la taille ventriculaire et l'IRM (4 cas, en dehors de notre observation), un aspect de phlébothrombose du tiers postérieur du

SLS dans le cas de Sirdofsky *et al.*, (1994). L'artériographie, réalisée dans 10 cas, était anormale dans ce dernier cas, le nôtre et celui de Krausz *et al.*, (1978), où il était noté un aspect d'obstruction partielle des SL. Dans les observations de Krausz *et al.*, (1978) et de Sirdofsky *et al.*, (1994), l'évolution fut favorable sans anticoagulant, et l'arrêt de l'intoxication inconstamment aidé d'un traitement symptomatique suffit, comme pour les autres, à la régression des signes cliniques d'HICB en 30 jours en moyenne. Dans 2 cas toutefois persistèrent de discrètes séquelles visuelles et dans un autre cas une fibrose hépatique sévère. La prise concomitante de tétracycline ou de minocycline, notée 6 fois, pouvait participer à l'HICB (Gardner *et al.*, 1995), au même titre 3 fois qu'un poids excessif (Sugerman *et al.*, 1995). La constatation d'une HICB est inconstante en cas d'intoxication chronique par la vitamine A et l'AR, ce qui pourrait traduire: 1) une tolérance individuelle variable fonction des mécanismes d'adaptation biochimique aux entrées, comme la capacité de stockage hépatique du rétinol ou de synthèse des protéines porteuses sanguines ou intracellulaires; ce dernier transporteur pourrait « séquestrer » les rétinols et réduire leur accès aux récepteurs et cibles dans les cellules (Snodgrass 1992); 2) ses difficultés diagnostiques; 3) l'existence d'un terrain prédisposant à l'HICB indépendamment de sa cause, pouvant contribuer à expliquer la prédominance féminine et le jeune âge des sujets.

Les mécanismes de la neurotoxicité de la vitamine A demeurent mal compris: action toxique directe du rétinol ou par l'intermédiaire de sa transformation irréversible en AR? Comment et où serait alors produite l'action délétère au niveau cellulaire? 1) impacts cytoplasmiques: modifications post-traductionnelles de certaines protéines de surface, par glycosylation, altérant leur fonctionnement (Snodgrass 1992); altération membranaire (instabilité et augmentation de la perméabilité) des cellules et des organelles intracellulaires (lysosomiale et mitochondriale) en cas d'excès de rétinol (Meecks *et al.*, 1981; Snodgrass 1992); dysfonctionnement mitochondrial avec dépression de la synthèse des protéines dépendantes de l'ADN mitochondrial, sujet à des mutations (Cheng et Wilkie, 1991); 2) impact nucléaire, sachant le rôle majeur sur la différenciation cellulaire de l'acide rétinolique, grâce à sa fixation sur des récepteurs nucléaires, lui permettant de moduler l'expression de nombreux gènes, par action sur leur transcription (Chytil, 1986). Le même manque de certitude existe à l'échelon tissulaire: 1) hyperproduction de LCR, via une interaction avec la transthyréline et le transport de vitamine A dans le plexus choroïde (Herbert *et al.*, 1986); 2) œdème cérébral? 3) augmentation de la pression veineuse intracrânienne contrebalancée par le renforcement de l'activité fibrinolytique en cas d'hypervitaminose A (Van Bennekum *et al.*, 1993); 4) enfin, l'hypothèse la plus communément admise serait l'existence d'un trouble de la résorption du LCR au niveau des villosités arachnoïdiennes, démontré expérimentalement chez l'animal soumis à une carence en vitamine A (Eaton, 1969).

Ainsi Hayes *et al.* (1971) ont montré la présence d'un épaississement de la dure-mère avec un élargissement des granulations arachnoïdiennes. En l'absence d'étude animale comparable, puisque l'hypervitaminose A chronique induit paradoxalement pour les espèces étudiées une hypotension intracrânienne (Eaton, 1969), ces résultats ne peuvent être extrapolés à l'homme qu'avec prudence, en notant : a) qu'un temps de latence est nécessaire à l'apparition de l'HICB en cas de carence ou d'intoxication chronique ; b) qu'existe un point d'impact tissulaire méningé démontré pour la vitamine A ; c) qu'une différenciation prématurée ou défaillante peut conduire au même résultat, à savoir un manque cellulaire avec une fonction définie (Snodgrass, 1992) ; ainsi un tableau d'HICB pourrait se constituer en cas de carence ou d'excès vitaminique, via le contrôle nucléaire exercé par l'AR au niveau de certaines cellules méningées.

En conclusion, nous soulignons le fait d'évoquer une intoxication chronique par la vitamine A ou l'acide rétinolique devant tout tableau d'hypertension intracrânienne bénigne. La diminution du risque d'hypervitaminose A passe avant tout par le respect des indications, presque limitées actuellement à un état carenciel confirmé.

RÉFÉRENCES

- CHENG L.L., WILKIE D. (1991). Mitochondrial activity and cytotoxicity of vitamin A (retinol) in yeast and human cell cultures. Protective effect of antioxidants. *Biochemical Pharmacology*, 6 : 1237-1240.
- CHYMI F. (1986). Retinolic acid biochemistry and metabolism. *J. Am Acad. Dermatol.*, 15 : 741-747.
- DEPER G. (1996). Retinoïdes et tumeurs gliales. Une nouvelle approche thérapeutique ? *Revue Neurol.* 152 : 653-657.
- EATON H.D. (1969). Chronic bovine hypo and hypervitaminosis A and cerebrospinal fluid pressure. *Am J Clin Nutr.* 22 : 1070-1080.
- GARDNER K., COX T., DIGE K.B. (1995). Idiopathic intracranial hypertension associated with tetracycline use in fraternal twins: case reports and review. *Neurology*, 45 : 8-10.
- GEISER A., RAAS A.F., SOBEL A.E. (1954). Vitamin A poisoning in adults with description of a case. *Am J Med.* 16 : 729-745.
- HAYES K.C., Mc COMBS H.L., FAHERTY T.P. (1971). The fine structure of vitamin A deficiency. II. Arachnoid granulations and CSF pressure. *Brain*, 94 : 213-224.
- HERBERT J., WILCOX J.N., PHAM K.T., FREMEAL R.T., ZEVANI M., DWORAK A., SUPRANO D.R., MADOWER A., GOODMAN DE WITT S., ZIMMERMAN E.A., ROBERTS J.L., SCHON E.A. (1996). Transthyretin: a choroid plexus-specific transport protein in human brain. *Neurology*, 36 : 900-911.
- JOHNSTON I., PATERSON A. (1974). Benign intracranial hypertension I. Diagnosis and prognosis. *Brain*, 97 : 289-300.
- KRALJIC M.M., FENSOO M., BELLER A.J. (1978). Bilateral transverse sinus obstruction in benign intracranial hypertension due to hypervitaminosis A. *Isr J Med Sci.* 14 : 858-861.
- MEBES R., ZAHAREVITZ D., CHEN R. (1981). Membrane effects of retinoids: possible correlations with toxicity. *Arch Biochem Biophys*, 207 : 141-147.
- SIRODOKY M., KATTAH J., MACEDO P. (1994). Intracranial hypertension in a dieting patient. *J Neuro Ophthalmol.* 14 : 9-11.
- SNODGRASS S.R. (1992). Vitamin neurotoxicity. *Molecular Neurobiology*, 7 : 41-73.
- SPECTOR R.H., CAPRUSLE J. (1984). Pseudotumor cerebri caused by a synthetic vitamin A preparation. *Neurology*, 34 : 1509-1511.
- SUGERMAN H.J., FLETON W.L., SALVANT J.B., SISMANS A., KELLUM J.M. (1995). Effects of surgically induced weight loss on idiopathic intracranial hypertension in morbid obesity. *Neurology*, 45 : 1655-1659.
- VAN BENNEKUM A.M., EMBIS J.J., KOOISTRA T., HENDRIKS F.J. (1993). Modulation of tissue type plasminogen activator by retinoids in rat plasma and tissues. *Am J Physiol.* 264 : 931-937.

The dose of levodopa given was assessed in each group after 1 year of treatment. In the one group (levodopa combined with a decarboxylase inhibitor), an average dose of 0.63 g (0.125 to 1.1 g) was given; in the other group, 3.4 g (0.6 to 6 g).

Discussion. There are several hypotheses to explain the random oscillations: sudden desensitization block of dopamine receptors¹; decreased bioavailability in plasma because of amino acid competition for intestinal transport of levodopa²; competition with amino acids for transport into the brain; formation of dopa metabolites that act as false transmitters or as competitors against dopamine for receptors³; or a central noradrenergic mechanism.¹⁰

According to Fahn,¹ sudden desensitization of dopamine receptors due to conformational change of receptor protein as a result of chronic bombardment by dopamine seems the most satisfactory explanation. A higher dose could possibly explain the more frequent and earlier occurrence of response variations (end-of-dose deterioration, on-off response fluctuation) in patients treated with both levodopa and a decarboxylase inhibitor. However, the amount of levodopa prescribed in this group was even lower (0.63 g; 3.4 g). Thus, the difference found cannot be explained on the basis of a difference in dose. Fahn states that the receptor desensitization hypothesis is also compatible with the observation that the receptors had been excessively bombarded by dopamine, because these patients had previously experienced choreic movements, indicating excess dopamine at receptors. However, only four of our patients who later developed end-of-dose deterioration or on-off response fluctuation had experienced choreic movements.

According to these findings, levodopa, in combination with a decarboxylase inhibitor, should not be the drug of first choice in the treatment of Parkinson's disease. Patients with response variations, especially those with end-of-dose deterioration, will probably gain more by the addition of bromocriptine

mesylate than by a change to levodopa combined with a decarboxylase inhibitor. One could argue¹¹ whether those patients who have peripheral side effects on levodopa therapy should not be treated with low-dose bromocriptine mesylate.

From the Department of Neurology, University Hospital Rotterdam, The Netherlands.

Accepted for publication March 8, 1984.

Address correspondence and reprint requests to Dr. Meerwaldt, Department of Neurology, University Hospital Rotterdam "Dijkzigt", 40 Dr Meelwaterplein, 3035 GD Rotterdam, The Netherlands.

References

1. Barbeau A. Long-term side effects of levodopa. *Lancet* 1971;1:395.
2. Marsden CD. "On-off" phenomenon in Parkinson's disease. In: Rinne UK, Klingner M, Stamm G, eds. *Parkinson's disease: current progress, problems, and management*. Amsterdam: Elsevier North Holland, 1982:241-54.
3. Marsden CD, Parkes JD, Quinn N. Fluctuations of disability in Parkinson's disease: clinical aspects. In: Marsden CD, Fahn S, eds. *Movement disorders*. Butterworth Scientific, 1982: 96-123.
4. Marsden CD, Parkes JD. "On-off" effects in patients with Parkinson's disease on chronic levodopa therapy. *Lancet* 1976;1:292-5.
5. Klawans HL, Weiner WJ. *Textbook of clinical neuropharmacology*. New York: Raven Press, 1981:1-37.
6. Kaplan EL, Meier P. Nonparametric estimation from incomplete observation. *J Amer Stat Assoc* 1958;53:451-81.
7. Fahn S. Fluctuations of disability in Parkinson's disease: pathophysiology. In: Marsden CD, Fahn S, eds. *Movement disorders*. Butterworth Scientific, 1982:123-45.
8. Cotzias GC, Mens L, Papavasiliou PS. Overview of present treatment of parkinsonism with L-dopa. *Adv Neurol* 1973;2: 265-77.
9. Sandler M. The dopa effect: possible significance of transamination and tetrahydroisoquinoline formation. *Adv Neurol* 1973;2:255-64.
10. Shoulson I, Gleubiger GA, Chase TN. "On-off" response: clinical and biochemical correlations during oral and intravenous levodopa administration in parkinsonian patients. *Neurology (Minneapolis)* 1975;25:1144-8.
11. Teychenne PF, Bergsvold D, Raey A, Vern B. Low-dose bromocriptine therapy in Parkinson's disease. *Research and Clinical Forums* 1981;3:37-47.

Pseudotumor cerebri caused by a synthetic vitamin A preparation

Article abstract—Pseudotumor cerebri developed in a 14-year-old girl with nodulocystic acne, who was taking excessive amounts of a synthetic vitamin A derivative. Although hypervitaminosis A has reportedly caused pseudotumor, Accutane has not previously been implicated.

NEUROLOGY (Cleveland) 1984;34:1509-11

Robert H. Spector, MD, and Jeffrey Carlisle

Acute or chronic hypervitaminosis A may cause pseudotumor cerebri.¹⁻⁴ We describe a teenager who was taking excessive amounts of a synthetic vitamin A derivative, 13-*cis*-retinoic acid (Accutane).

Case report. Minocycline hydrochloride (Minocin), 100 mg bid, and oral 13-*cis*-retinoic acid (Accutane), 40 mg bid, were prescribed for severe nodulocystic acne to a 14-year-old, 50-kg girl. However, she unintentionally used 120 mg

bid of 13-*cis*-retinoic acid. After 5 weeks, she had headaches and blurred vision. The headaches were uncharacteristically severe—worse in the morning—and gradually increased in intensity for 5 weeks. Later headaches were accompanied by momentary blurred vision, brought on by exertion or by change from a recumbent to sitting position.

The 13-*cis*-retinoic acid was discontinued, but the headaches unabatingly increased. Four months after onset, there was subacute bilateral papilledema, with perimetric evidence of enlarged blind spots in each eye. Visual acuity, pupillomotor activity, color perception, and ocular motility were normal, as were results of general neurologic examination. She was thin, 5 feet 5 inches tall, and there were no external signs of a dysmorphic craniocervical junction.

Brain CT was normal. CSF pressure was 380 mm of water. The protein content was 25 mg/dl, and there were no cells. Digital venous subtraction angiography showed patent dural sinuses. Investigation of the patient's blood, urine, and stool was unremarkable. She was discharged with the diagnosis of pseudotumor and advised to discontinue the synthetic vitamin A derivative.

For the next 2 weeks, she had less intense headaches and less frequent visual obscurations, and the papilledema improved. Unfortunately, the acne flared, and she insisted on resuming 13-*cis*-retinoic acid. Using the same dosage, she experienced recurrent symptoms 3 weeks later, and there was objective redocumentation of fully developed papilledema. The 13-*cis*-retinoic acid was again discontinued, the papilledema subsided, and the patient soon became asymptomatic.

Discussion. Pseudotumor cerebri is characterized clinically by three criteria: (1) neurologic and ocular symptoms and signs of increased intracranial pressure, which may include headache, nausea, transient visual obscurations, sixth-nerve palsies, and papilledema; (2) radiologically demonstrable normal or small-sized cerebral ventricles; and (3) normal CSF, except that the pressure is elevated and the protein content may be low. Many medical conditions and drugs, including tetracycline⁸⁻¹¹ and vitamin A administration,¹⁻⁷ have been associated with pseudotumor. In our patient, we first discontinued the tetracycline preparation, but there was no change in symptomatology. After 13-*cis*-retinoic acid was stopped, however, headaches, transient visual obscurations, and papilledema resolved.

Lombaert and Carton³ reviewed pseudotumor after vitamin A administration, including 19 cases of acute intoxication and 38 cases of chronic abuse. Large long-term intake of vitamin A was usually related to treatment of skin diseases, particularly acne. Although only two patients with definite papilledema were described, the authors noted headaches, diplopia, and impaired vision with great frequency. Twenty-five percent complained of spontaneous bleeding, usually from nasal or oral mucosa. Other common symptoms included diarrhea, skin changes, musculoskeletal pain, and fatigue. Individual sensitivity to vitamin A varies; daily doses of vitamin A responsible for chronic intoxication ranged from 40,000 to 600,000 IU.^{12,13} Symptoms appeared as early as 4 to 6 weeks or as late as 7 years

after continuous use of vitamin A. Although the vitamin A content in blood was always elevated, there was no relationship between plasma level and total dose, or between plasma level and severity of the clinical disorder—suggesting that an intracellular and not extracellular, metabolite of vitamin A was involved.

13-*cis*-retinoic acid^{14,15} is a vitamin A derivative that is rapidly absorbed through the portal route and transported in albumin-bound form. Although retinoic acid has little or no physiologic function in the vitamin A-dependent processes involving vision¹⁶ or reproduction, it seems to have a definite role in other vitamin-A related activity involving skeletal deposition as well as epithelial and membrane stability.^{17,18} Retinoic acid increases permeability of liposomes to potassium, iodine, and glucose; decreases membrane resistance; and increases both water permeability and membrane fluidity.¹⁹

The pathogenesis of hypervitaminosis A-induced pseudotumor is unknown. One theory, that excessive vitamin A enhances CSF production, was weakened by evidence that toxic amounts of vitamin A had no effect on cyclic AMP accumulation in the choroid plexus of the rat.²⁰ 13-*cis*-retinoic acid may affect triglyceride and cholesterol metabolism^{14,15} and could alter the lipid constituents of the arachnoid villi, disrupting normal transport systems and impeding absorption of CSF at the arachnoid villi. Calves with vitamin A deficiency^{21,22} show structural changes at the site of the arachnoid villi, but the effects of toxic amounts of vitamin A have not been reported. Although a precise explanation for this phenomenon is lacking, higher-than-recommended amounts of vitamin A in our patient caused pseudotumor. The increasing popularity of this drug in treating nodulocystic acne should alert physicians to this unusual complication.

From the Departments of Ophthalmology and Neurology, Emory University Clinic, Emory University School of Medicine, Atlanta, GA.

Accepted for publication March 8, 1984.

Address correspondence and reprint requests to Dr. R. Spector, 1365 Clifton Road NE, Atlanta, GA 30322.

References

1. Marie J, See G. Acute hypervitaminosis A of the infant: its clinical manifestation with benign acute hydrocephaly and pronounced bulge of the fontanelle. *Am J Dis Child* 1954;73:731-6.
2. Garber A, Raab AP, Sobel AE. Vitamin A poisoning in adults. *Am J Med* 1954;16:729-45.
3. Lombaert A, Carton H. Benign intracranial hypertension due to hypervitaminosis A in adults and adolescents. *Eur Neurol* 1976;14:340-50.

4. Siegel NJ, Spackman TJ. Chronic hypervitaminosis A with intracranial hypertension and low cerebrospinal fluid concentration of protein. *Clin Pediatr (Phila)* 1972;11:580-4.
5. Feldman M, Schlezinger N. Benign intracranial hypertension associated with hypervitaminosis A. *Arch Neurol* 1970;22:1-7.
6. Oliver TK, Haverner WH. Eye manifestations of chronic vitamin A intoxications. *Arch Ophthalmol* 1958;60:19-22.
7. Morrie G, Haverner WH, Kapetansky F. Vitamin A intoxication as cause of pseudotumor cerebri. *JAMA* 1960;173:1802-5.
8. Furman KI. Acute hypervitaminosis A in an adult. *Am J Clin Nutr* 1973;26:575-7.
9. Beran RG. Pseudotumor cerebri associated with minocycline therapy for acne. *Med J Aust* 1980;1:323-4.
10. Giles C. Intracranial hypertension and tetracycline therapy. *Am J Ophthalmol* 1971;72:981-2.
11. Koch-Weser J. Benign intracranial hypertension in an adult after tetracycline therapy. *JAMA* 1967;200:169-71.
12. Jennekens GFI, Veeler CWM. Hypervitaminosis A. *Presse Med* 1966;74:2928-59.
13. Stimson WT. Vitamin A intoxication in adults: report of a case with a summary of the literature. *N Engl J Med* 1961;265:369-73.
14. Jones H, Blanc D, Cunliffe WJ. 13-Cis-retinoic acid and acne 1961. *Lancet* 1969;2:1048-9.
15. Voorhees JJ, Orfanos CE. Oral retinoids. *Arch Dermatol* 1981;117:418-21.
16. Ganguly J, Rao MRS, Murthy SK, Sarada K. Systemic mode of action of vitamin A. *Vitam Horm* 1980;38:1-50.
17. Zile R, Maija H, Cullum ME. The function of vitamin A: current concepts. *Proc Soc Exp Biol Med* 1983;172:139-52.
18. Dowling J, Wald G. Effect of growth hormone on vitamin A storage and release. *Nutr Rev* 1981;39:139-40.
19. Stillwell W, Ricketts M, Hudson H, Nahmias S. Effects of retinol and retinoic acid on permeability, electrical resistance, and phase transition of lipid bilayers. *Biochimica et Biophysica Acta* 1982;688:653-9.
20. Feldman A, Epstein MH, Bruslow SW. Role of cyclic AMP in cerebrospinal production. In: Wood JH, ed. *Neurobiology of cerebrospinal fluid*. New York: Plenum Press, 1980:17-25.
21. Eaton HD. Chronic bovine hypo- and hypervitaminosis A and cerebrospinal fluid pressure. *Am J Clin Nutr* 1969;22:1070-80.
22. Hayes KC, McCombs HL, Faherty TP. The fine structure of vitamin A deficiency. II. Arachnoid granulation and CSF pressure. *Brain* 1971;14:213-24.

Head trauma and seizures as risk factors of glioblastoma

Article abstract—This is a case-control study of 160 persons with glioblastoma and 128 of their "best friends" as controls. Subjects came mainly from greater Boston, and data were gathered by questionnaire and telephone interview. Among those who had had a "severe" head injury at age 15 or later, the age-adjusted rate ratio (RR) of glioblastoma was 10.6, $p = 0.004$. There were six cases and no controls who had seizures for 15 or more years. The related RR is inestimable, but has a p value of 0.03. We could not evaluate whether the latter association implies a direct relationship between the causes of seizures and the causes of glioblastoma, or if it reflects the effect of another factor, such as medications to control the seizures.

NEUROLOGY (Cleveland) 1984;34:1511-4

F. Hochberg, MD; P. Toniolo, MD; and P. Cole, MD

Glioblastoma is the most common primary malignant brain tumor. The 5-year survival rate is about 6%,¹ and the tumor accounts for one-half of the 7,000 deaths due to primary brain cancer that occur annually in the United States. The causes of glioblastoma are almost entirely unknown. We therefore undertook a case-control study to evaluate possible risk factors.

Methods. Between 1977 and 1981, 231 patients, aged 15 to 81 years, had histologically confirmed glioblastomas (grade 3 or 4 astrocytoma, anaplastic glioma) at three participating hospitals in Boston, one in Providence, and one in Baltimore. Excluded from the study were 20 patients who were too ill to participate, 4 who did not speak English, and 53 who did not return the questionnaire. Therefore, 160 patients (68%) were included. Each one was asked to identify a control of the same sex and closest in age (± 5 years) from among his or her best friends, excluding blood relatives. Each of these friends resided within 100 miles of the patient's residence. Of 160 friends identified in

this way, 35 did not return the questionnaire, leaving 125 (78%) controls for study. Information was also available for five controls who did not match the sex of the corresponding case and for three controls who correctly matched to nonrespondent cases.

A self-administered questionnaire, designed to assess exposure to over 500 potential risk indicators, was given to all eligible cases and was mailed to all eligible controls. Each subject was requested to complete the questionnaire, without a time limit. Returned questionnaires were checked for completeness by a trained interviewer. An a priori part of our study design included telephone calls that were routinely made to confirm data or elicit missing, incomplete, or ambiguous information. These calls were made to 91% of cases and 96% of controls. A proxy assisted in completing the questionnaires for 20% of cases and 2% of controls, and in the telephone interviews for 43% of cases and 3% of controls.

A description of every head injury was obtained during the telephone follow-up. Every questionnaire mentioning a history of any head trauma was

Adverse reactions

Adverse reactions to isotretinoin

A report from the Adverse Drug Reaction Reporting System

Michael Bigby, M.D., and Robert S. Stern, M.D. *Boston, MA, and Chicago, IL*

Between October 1982 and June 1985 the Adverse Drug Reaction Reporting System received reports of 104 suspected adverse reactions occurring in 93 patients who took isotretinoin. Adverse reactions involving the skin and mucous membranes (29 reports), central nervous system (23), musculoskeletal system (12), pregnancy (11), and eyes (8) were most commonly reported. Severe headache was the most frequently reported adverse reaction (15 reports). In four cases headaches were attributed to pseudotumor cerebri. Some of the reported reactions, for example, a disulfiram (Antabuse)-like reaction and oculoerythric crisis, have not been described previously in the literature. Other reports, such as congenital malformations, serve to emphasize some of the serious reactions that are known to occur. These spontaneous reports of adverse reactions associated with isotretinoin use, together with the literature we review, may help alert physicians to the diverse spectrum of adverse reactions that may develop in patients taking isotretinoin. (*J AM ACAD DERMATOL* 1988;18:543-52.)

Isotretinoin became available by prescription in the United States in September 1982. It has proved to be effective in treating nodulocystic and inflammatory papulopustular acne and is the only available drug that causes a prolonged remission of the disease.¹ Adverse reactions to isotretinoin are frequent, varied, and at times severe. In clinical trials involving 523 patients, at least one adverse reaction occurred in over 90% of patients.² From 1983 to 1985, 824,000 new prescriptions for isotretinoin were dispensed.* The actual number of patients who were treated with isotretinoin during this period may be smaller because many patients get a

new prescription every 3 to 4 weeks during the usual 16 to 20 weeks of therapy. With large numbers of patients having taken the drug, a wider spectrum of toxicities than observed in clinical trials is to be expected.

The Adverse Drug Reaction Reporting System (ADRRS) of the American Academy of Dermatology was organized in 1980 to facilitate the reporting of new, unusual, or severe reactions to drugs. The ADRRS provided a mechanism for receiving, codifying, and reporting adverse reactions to drugs.³ The ADRRS received 123 reports of suspected adverse reactions to isotretinoin, which we present in this study. In addition, we review the literature of adverse reactions associated with isotretinoin.

METHODS

The methods of the ADRRS have been described previously.³ All reports received by the ADRRS were reviewed by a board-certified dermatologist. Reports were classified according to algorithms for judging the type, severity, and outcome of reactions based on a

*From the Department of Dermatology and the Charles A. Dana Research Institute, Beth Israel Hospital and Harvard Medical School, Boston, and the Adverse Drug Reaction Reporting System of the American Academy of Dermatology, Chicago.

Supported in part by United States Food and Drug Administration Contract No. 223 80 3015.

Reprint requests to: Dr. Michael Bigby, Department of Dermatology, Beth Israel Hospital, 330 Brookline Ave., Boston, MA 02215.

Wanju Dai, M.D., Ph.D. (Hoffman-La Roche Inc., Nutley, NJ).
Personal communication.

standard vocabulary.⁴ Reports were also classified according to the likelihood that each drug to which a patient was exposed was responsible for an adverse reaction.⁵ Reactions were judged to be definitely related to the drug if the reaction resolved when the drug was withdrawn and reappeared on rechallenge. Probably related reactions were those in which the reaction appeared in association with the drug and resolved when the drug was withdrawn. An intercurrent illness and other drugs that may have caused the reaction were excluded before a reaction was judged probably related. Reactions were considered to be possibly related to isotretinoin if they appeared in temporal association with drug use and resolved when the drug was withdrawn, but other drugs or intercurrent illness as possible causes of the reaction could not be excluded.⁵ The above criteria are useful for defining the degree of association but do not prove causality. The data for each report are entered into Miniature Information Storage and Retrieval (MISAR), a system that permits retrieval of reactions on the basis of the type of reaction, suspected drug, or patient characteristics.⁶ In this report we discuss only reactions judged to be definitely, probably, or possibly due to isotretinoin.

This report is based on 104 reactions associated with isotretinoin use reported to the ADRRS by over 90 cooperating dermatologists. To compare them to reports already in the medical literature, we searched the Medline database for all adverse reactions associated with retinoids and identified 304 reports indexed as dealing with retinoids' adverse effects or toxicity. One hundred thirteen of the 304 reports identified by the Medline search were adverse reactions to isotretinoin.

RESULTS

Between October 1982 and June 1985, the ADRRS received 123 reports of suspected adverse reactions to isotretinoin. We excluded 12 reports judged as only remotely associated with isotretinoin and another 18 because of incomplete information. The remaining 93 reports represent 7% of all reports to the ADRRS for all drugs during this time period. Forty-seven (51%) of the reported patients were women and 45 (48%) were men. One patient's sex was not indicated.

These 93 patients had 104 adverse reactions judged as possibly, probably, or definitely related to isotretinoin. The most commonly reported adverse reactions involved the skin and mucous membranes (29 reports), nervous system (23), musculoskeletal system (12), pregnancy (11), and

eyes (8). Adverse reactions involving the hematopoietic and lymphatic (6), gastrointestinal (5), cardiorespiratory (4), and genitourinary (2) systems were also reported. There were four miscellaneous reactions. The percentages of the reactions judged to be definitely, probably, and possibly related to isotretinoin were 5, 45, and 50 percent, respectively.

Teratogenicity

There were 11 reports of women who became pregnant while taking isotretinoin. The women's ages ranged from 17 to 30 (mean, 24). There were six spontaneous abortions. In three reports, abortions occurred after 1 week, 5 weeks, and 3 months of gestation. One woman aborted a blighted ovum at 6 weeks and one woman who took isotretinoin for the first 5 weeks of her pregnancy delivered a dead, hydrocephalic female fetus. One 18-year-old had a spontaneous abortion after fetoscopy. This same patient had previously had a therapeutic abortion after getting pregnant while taking isotretinoin. In one other report a woman who became pregnant in her fourth month of isotretinoin therapy had a therapeutic abortion.

Three women who took isotretinoin during pregnancy delivered apparently normal children. One woman had taken isotretinoin for 1 week during her first 3 weeks of gestation. Another woman had taken isotretinoin for 2 months starting in the second half of her first trimester. Finally, a 17-year-old woman took isotretinoin from the twenty-seventh through the fortieth day of gestation and delivered at 30 weeks because of cervical incompetence. The child had no reported anomalies of cardiac defects at birth.

One 22-year-old woman took isotretinoin for 2 months during the first trimester of her pregnancy. At delivery at 32 weeks' gestation, her child had no ear pinnae and had a heart murmur and respiratory distress.

Central nervous system

Adverse reactions involving the central nervous system that were judged to be definitely or probably related to isotretinoin use are shown in Table I. Headache, usually described as severe, was reported in 10 patients. Headaches developed in

Table I. Central nervous system reactions definitely or probably related to isotretinoin use

Reaction	Number	Comments
Headache	10	Pseudotumor cerebri (4) With chest pain (2)
Depression	1	
Disulfiram-like reaction	1	With headache

the first month of isotretinoin therapy in two thirds of the reported cases, and in 6 of the 10 reports headaches occurred in the first week. Evidence of pseudotumor cerebri (papilledema and/or elevated cerebrospinal fluid pressure) was present in four patients. In the other reports of severe headaches, the headache resolved when isotretinoin was withdrawn and further evidence for pseudotumor cerebri was not sought. Three of the reported patients with headache were also taking tetracycline or minocycline, and one patient had a history of pseudotumor cerebri while taking minocycline. Two patients had throbbing headaches with visual disturbances and nausea similar to migraine headaches.

A 23-year-old man on nortriptyline noted a worsening of depression when he started isotretinoin. Isotretinoin therapy was continued. One patient developed a disulfiram-like reaction after drinking alcohol while taking isotretinoin. The patient, who was taking 30 mg of isotretinoin daily, developed a headache, flushing, and malaise after one alcoholic drink. An additional patient had a disulfiram-like reaction judged possibly to be related to isotretinoin. This patient, who had been on isotretinoin for 3 months, noted the onset of nausea and vomiting within a half hour of ingesting alcohol. A similar reaction was noted with cocaine. Isotretinoin was not withdrawn.

In addition to the reactions reported in these 13 patients, there were an additional 11 reports that were judged possibly to be related to isotretinoin use (Table II). One 15-year-old boy developed fixation of the eyes in one direction, facial spasm, and loss of speech after taking isotretinoin for 2 weeks. He responded to intravenous diphenhydramine. Isotretinoin was withdrawn and addi-

Table II. Central nervous system reactions possibly related to isotretinoin use

Reaction	Number	Comments
Headache	5	With optic neuritis (1)
Depression	2	
Disulfiram-like reaction	1	
Decreased hearing	1	
Dizziness	1	
Oculogyric crisis	1	
Personality disorder	1	Spells of violent behavior

tional episodes did not occur. One patient who was being treated with lithium for manic-depressive psychosis became suicidal after 6½ weeks of isotretinoin treatment. Three months after isotretinoin was withdrawn her depression had lessened. A 29-year-old man reported loss of libido, impotence, and insomnia after 2 months of isotretinoin. He completed 20 weeks of therapy. Follow-up after the drug was discontinued is not available. Five additional reports described patients who had headaches that were judged possibly to be related to isotretinoin use.

Cutaneous toxicity

There were ten adverse reactions involving the skin and mucous membranes that were judged definitely or probably to be related to isotretinoin use (Table III). In four reports, paronychia was caused by overgrowth of the distal and lateral nail folds, and each patient had associated exuberant granulation tissue at the sites of paronychia. Multiple fingers were involved in all patients. In one case of paronychia, causality was established by rechallenge. Two patients developed urticaria within 3 days of starting isotretinoin. Causality was established by rechallenge. In one reported case, urticaria developed after each of three rechallenges. One patient developed onycholysis judged probably to be related to isotretinoin use.

Erythema nodosum was diagnosed in a 19-year-old patient who developed tender nodules on the anterior aspect of the legs after 3 weeks of therapy. Perivascular dermatitis was observed in a skin bi-

Table III. Adverse reactions involving the skin and mucous membranes definitely or probably related to isotretinoin use

Reaction	Number	Comments
Paronychia	4	Involved multiple fingers in all cases
Varicella-zoster infection	1	Scarring worse than expected
Erythema nodosum	1	
Erythema multiforme	1	
Urticaria	2	Proved by rechallenge (2)
Onycholysis	1	

opsy specimen. The patient was hospitalized and treated with bed rest and leg elevation and the lesions resolved in 3 weeks. Clinically diagnosed erythema nodosum, possibly related to isotretinoin, developed in one patient after 6 weeks of isotretinoin therapy. The dose of isotretinoin was reduced from 50 to 40 mg and was continued for an additional 14 weeks. The tender leg nodules resolved in 2 to 3 weeks.

A 16-year-old male patient developed an erythema multiforme-like eruption on his arms, legs, and right sole within 24 hours of taking a single 40-mg tablet. Sore throat and nausea accompanied the eruption, which resolved slowly after drug withdrawal and prednisone therapy. A second case of erythema multiforme possibly related to isotretinoin occurred in a 23-year-old woman. This patient developed bullae of her skin and mucous membranes and fever in the sixth month of her second course of isotretinoin. She recovered after drug withdrawal and hospitalization.

There were an additional 16 reports in which the adverse reaction was judged possibly to be related to isotretinoin use (Table IV). A 27-year-old patient developed an exudative, eczematous plaque on his penis after 1 month of tetracycline and isotretinoin therapy. The lesion showed no resolution after tetracycline was discontinued and isotretinoin was continued. This was diagnosed as a fixed drug eruption possibly due to isotretinoin. Generalized (3 patients) or localized erythematous, papular eruptions were reported in four pa-

Table IV. Adverse reactions involving the skin and mucous membranes possibly related to isotretinoin use

Reaction	Number	Comments
Papular rash	4	Clinically similar to pityriasis rubra pilaris (1)
Varicella-zoster infection	2	Severity worse than expected (1)
Hyperpigmentation	3	Exacerbation of chloasma (2); photodistribution (1)
Vascular reactions	2	Fever and localized petechiae (1)
Erythema nodosum	1	
Erythema multiforme	1	
Nail dystrophy	1	
Leukoderma	1	
Exacerbation of acne	1	
Fixed drug eruption	1	
Facial calcified cysts	1	1- to 2-mm black, calcified cysts developed after 2 months of isotretinoin
Change in hair texture	1	Straight hair became curly after 2 months of isotretinoin

tients. In one patient the rash began after 2 weeks of isotretinoin therapy and was diffuse, with islands of sparing, clinically similar to pityriasis rubra pilaris. A skin biopsy was not performed.

In a 17-year-old patient who developed widespread varicella after being on isotretinoin for 8 weeks, the reporting physician suggested that the severity of his disease might have been increased as a result of drug exposure. Another patient on 1.2 mg/kg of isotretinoin had hypertrophic scarring of varicella lesions.

Musculoskeletal system

Adverse reactions involving the musculoskeletal system were reported in 13 patients. Five of these reactions were judged to be definitely or probably related to isotretinoin use. In three reports, patients taking isotretinoin developed muscular or joint pain without objective signs of arthritis or myositis. Pains occurred in the chest,

back, hips, thighs, and knees. Achilles tenosynovitis developed in a 17-year-old man after 2½ weeks of isotretinoin therapy. The disease abated when the drug was withdrawn and was exacerbated following reintroduction of isotretinoin at the original dose. This patient was able to tolerate isotretinoin at a reduced dose. Another patient on 1.5 mg/kg of isotretinoin developed bilateral ankle pain and swelling after 4 days of isotretinoin therapy. Therapy was continued.

There were an additional eight reports of adverse reactions involving the musculoskeletal system that were judged possibly to be related to isotretinoin use. Four of these reports were of patients who developed myalgia and arthralgia while taking isotretinoin. In two reports, both male, diffuse myalgia persisted for 4 to 6 months after isotretinoin was discontinued.

Arthritis was reported in three patients. One 24-year-old man developed arthritis of his second metacarpophalangeal and proximal interphalangeal joints, accompanied by small vessel vasculitis of the same hand 4 weeks into his second course of isotretinoin. All symptoms resolved within 1 week of stopping the drug. He was hospitalized and bed rest was requested. This same patient developed achilles tenosynovitis 1 month after discontinuation of the drug. A 35-year-old man developed polyarteritis nodosa 3 months after completing a 4-month course of isotretinoin. His disease was manifested by arthritis, chills, night sweats, testicular and abdominal pain, and a rash consisting of erythematous plaques. He was hospitalized and treated with prednisone.

One woman was reported to have profound generalized weakness after vigorous exercise while taking isotretinoin. On one occasion she was hospitalized and had an elevated creatine phosphokinase level and a normal myelogram. Another patient developed severe, generalized weakness after 6 weeks of therapy. His symptoms increased while isotretinoin was continued for an additional 6 weeks. All symptoms resolved within 1 month after the drug was discontinued.

Ocular reactions

Adverse ocular reactions were reported in eight patients. Two of these reactions were judged probably to be related to isotretinoin use. Both were

reports of patients who developed dry eyes. One patient who developed dry eyes after 3 weeks of therapy complained of seeing black spots and a film across his field of vision. The other patient developed dry eyes after 10 weeks of treatment. This patient had an associated recent onset of a refractive error.

An additional six reports of patients with adverse ocular reactions were judged possibly to be related to isotretinoin use. A 30-year-old man was noted by an ophthalmologist to have keratoconus after completing a 4-month course of isotretinoin. A 16-year-old man reported decreased visual acuity at night after 3 months of isotretinoin therapy. The drug was continued. A 55-year-old man was reported to develop decreased visual acuity after taking isotretinoin for 3 months. On physical examination he was noted to have cataracts that had progressed despite discontinuing therapy. One reported case of keratitis was probably related to isotretinoin use and one case of blepharitis was possibly related to isotretinoin use.

Other toxicities

Hematopoietic and lymphatic complications were reported in six patients. Four of these reactions were judged to be definitely or probably related to isotretinoin use. Leukopenia was reported in three patients and anemia in one patient. The reactions of one patient who developed cervical, submandibular, and occipital lymphadenopathy and tonsillar enlargement while taking isotretinoin and another patient who had leukopenia that could not be distinguished from cyclic neutropenia were judged possibly to be related to isotretinoin use.

There were four reports of gastrointestinal symptoms associated with isotretinoin use. Only one of these was judged definitely to be related to isotretinoin use. A 36-year-old man developed nausea and vomiting after taking isotretinoin. Causality was established by rechallenge. A 22-year-old man developed x-ray-documented gastric ulcers after 2 weeks of isotretinoin at 1 mg/kg. Follow-up after the drug was discontinued was not available. One reported patient developed right upper quadrant pain requiring hospitalization after taking isotretinoin for 22 days. No etiology for his pain was discovered, and it resolved within 4 days after the drug was discontinued. A 16-year-old

man developed Crohn's disease in his seventeenth week of therapy. He lost 20 to 30 pounds and required hospitalization and prednisone. His isotretinoin was discontinued.

Cardiorespiratory symptoms were reported in three patients. One reaction was judged probably to be related to isotretinoin use. In that report a 26-year-old woman developed tachycardia of 1-hour duration after each dose of isotretinoin. Pleuritic chest pain, judged possibly to be related to isotretinoin use, was reported in two patients. The symptoms began after 1 month of therapy. Isotretinoin was withdrawn.

There were two reports of adverse reactions involving the genitourinary system. A 19-year-old man developed hypercalciuria, hyperuricuria, and nephrolithiasis, probably related to 16 weeks of isotretinoin therapy (1.4 mg/kg). One of the previously reported patients with paronychia also developed a testicular cyst.

Two patients developed hypertriglyceridemia. In one patient the peak triglyceride level reached 1253 mg/dl and decreased to 260 mg/dl after the drug was discontinued. One patient developed caries in 11 teeth while taking isotretinoin for 6 weeks. This reaction was judged possibly to be related to isotretinoin use. One patient had an unexplained weight loss of ten pounds possibly related to isotretinoin use.

DISCUSSION

The single most important risk associated with isotretinoin is that of fetal malformation associated with intrauterine exposure. A survey of the basic science literature indicates that this now well-established risk should not have come as a surprise to clinicians. We identified seven studies in laboratory animals, which were published in the 5 years before isotretinoin's release; these studies suggested an association between retinoic acid and fetal malformations.⁷⁻¹³ The characteristic cardiac abnormalities subsequently observed in humans were described in a 1980 study of hamsters.⁷ Craniofacial abnormalities were also noted in other animal studies.^{8,9} Almost 1 year after its release in the United States, the first reports of fetal malformations were described in a letter to the editor in *Lancet*.¹⁴ In the following year, ten letters,

case reports, and the first case series that summarized initial reports to the Adverse Drug Reaction Reporting System and the United States Food and Drug Administration presented instances of isotretinoin-associated teratogenicity in humans.¹⁵⁻²³

Lammer et al²⁴ published an analysis of 154 pregnancies in which there was fetal exposure to isotretinoin. This study was the largest series to appear in the medical literature and is the only one that included more than ten prospectively assessed cases. It documented the high relative risk of a select group of major fetal malformations associated with isotretinoin exposure.

The adverse effect of isotretinoin on pregnancy was reflected in the report to the ADRRS of the birth of a child with characteristic isotretinoin-associated birth defects. Isotretinoin, when taken during the first trimester, causes a tetrad of congenital abnormalities involving the cranium, ears, thymus, and heart.^{21,24} These defects are postulated to result from altered differentiation and migration of cephalic neural crest cells.²⁴ In addition, there is an increased incidence of spontaneous abortions. Three reports of apparently normal children born to women who took isotretinoin during the critical period are compatible with the results of Lammer et al, who noted that 64% of exposed women followed prospectively delivered children without major malformations.²⁴ The occurrence of normal births for women taking isotretinoin does not, however, preclude the importance of ensuring that women of childbearing age not be pregnant when they begin to take isotretinoin and that adequate contraception be used during and for 1 month after completion of therapy.

Many of the adverse reactions to isotretinoin reported to the ADRRS serve to emphasize some of the serious adverse reactions that are known to occur. Prominent among these are severe headaches, sometimes due to pseudotumor cerebri. Severe headaches were the single most frequent adverse reaction to isotretinoin reported to the ADRRS. As reported previously, some of the patients who have severe headaches while taking isotretinoin are found on subsequent evaluation to have raised intracranial pressure. Concomitant use of tetracycline or minocycline is an added risk

factor for developing pseudotumour cerebri.^{25,26} Based on the reports noted herein, patients who developed headaches secondary to isotretinoin did so early in the course of therapy, usually in the first week. It is therefore important that patients on isotretinoin be informed about the early appearance of headache when they begin the drug. They should also be questioned about headaches on their first follow-up visit.

Among the 25 reports of adverse reactions involving the central nervous system, the disulfiram-like reaction has not been described previously. In one report, a patient developed symptoms after only one alcoholic drink. This reaction was judged probably to be due to isotretinoin. The other newly described central nervous system reaction was the occurrence of oculogyric crisis possibly due to isotretinoin. This reaction was both interesting and dramatic and has not recurred since the drug was withdrawn.

Only four of the 113 reports of adverse reactions to isotretinoin identified in the Medline search dealt principally with central nervous system side effects. Of these, one reference discussed depression in association with isotretinoin use.²⁷ Pseudotumor cerebri has been addressed in a United States government agency publication.²⁸ A phase I study of isotretinoin toxicity revealed intense headache and ataxis associated with doses of greater than 60 mg/m², doses larger than those generally used for acne.²⁹

Several of the cutaneous reactions reported to the ADRRS either have not been described previously in the literature or are very uncommonly reported. Varicella-zoster and herpesvirus infections are known to have the propensity to be more extensive in patients with abnormal epidermal surfaces. It is, therefore, not surprising to find reports of exaggerated reactions to varicella-zoster infection in patients on isotretinoin, as were reported to the ADRRS. The two reports of erythema multiforme associated with isotretinoin are the first to appear in the literature. There is one previously published report of isotretinoin associated with erythema nodosum and several cases have been reported to Hoffman-La Roche and the Food and Drug Administration.^{25,30,31} The report of a patient with straight hair developing curly hair after

2 months of isotretinoin may represent a case of retinoid-induced pili torti, as described by Hays and Camisa.³²

We received four reports of paronychia developing in patients on isotretinoin. In each case multiple fingers were involved. Paronychia was preceded by overgrowth of distal and lateral nail folds and was complicated by the formation of exuberant granulation tissue. The frequency of similar reports suggests that this complication may be more frequent than is recognized.^{33,*} Paronychia and excess granulation tissue around the nails have also been observed with etretinate.³⁴

A total of 26 reports concerning cutaneous toxicity associated with isotretinoin were noted in our literature search. These included 12 case reports and 14 reports based on clinical and toxicologic studies in treatment cohorts. In addition to describing the cheilitis, conjunctivitis, dry skin, and pruritus so frequently associated with this therapy and noted in even the very earliest studies of isotretinoin,³⁵ other cutaneous toxicities reported include skin fragility,³⁶ pyogenic granuloma-like lesions,^{34,37,38} photosensitivity,³⁹ granulomatous lesions,³⁰ a pityriasis rosacea-like eruption,⁴⁰ erythema nodosum,³⁰ a dermatitis suggestive of mycosis fungoides,⁴¹ acquired pili torti,³² and osteoma cutis. We found no reports of life-threatening cutaneous reactions, such as toxic epidermal necrolysis or angioedema, in our Medline search, and no life-threatening cutaneous reactions were reported to the ADRRS.

While arthralgias and myalgias occur in 16% of patients treated with isotretinoin, they usually abate when the medication is discontinued.^{2,25} In two reports to the ADRRS that were judged possibly to be related to isotretinoin use, symptoms persisted in young men for 4 to 6 months after drug discontinuation. In one instance extensive in-hospital evaluations yielded no diagnostic explanation for the symptoms. There was no evidence of polymyositis or demyelinating disease.

We identified 17 reports that addressed musculoskeletal toxicity associated with isotretinoin.

*Billetter M, Dreis M. Suspected new, rare or unexpected serious adverse drug reactions reported to the Division of Drug Experience to: isotretinoin—paronychia. ADR Highlights 1983;9:1-4.

Ten were case reports. Premature closure of the epiphysis⁴² and hyperostosis⁴³ were both reported prior to isotretinoin's approval by the Food and Drug Administration. Subsequently, both prospective and retrospective studies have attempted to assess the frequency of hyperostosis in isotretinoin-treated patients.⁴⁴⁻⁴⁷ Musculoskeletal pain without objective signs of arthritis or myositis occurs in approximately 15% of patients taking isotretinoin. The etiology of this pain remains unknown. Acute, aseptic arthritis has also been reported.⁴⁸

The blepharitis and conjunctivitis associated with isotretinoin use were recognized well before its marketing.⁴⁹ Corneal opacities^{28,50} and acute myopia⁵¹ have been reported in government publications and in the ophthalmologic literature. An extensive review of 261 adverse ocular reactions occurring in 237 patients who were taking isotretinoin was reported in 1985 in the ophthalmologic literature. While blepharoconjunctivitis (88 cases) and dry eyes (47 cases) were most commonly reported, blurred vision was noted in 39 patients. Corneal opacities, contact lens intolerance, myopia, decreased dark adaptation, and uveal tract inflammation were also reported in association with isotretinoin use. Congenital ocular abnormalities occurred in ten children exposed to isotretinoin in utero. These abnormalities included microphthalmos, orbital hypertelorism, optic nerve hypoplasia, and cortical blindness.⁵² Decreased dark adaptation has been noted by others and in one report was accompanied by abnormal dark adaptation curves and with elevations of either cone or rod thresholds.⁵³

Gastrointestinal intolerance occurs in 20% of patients on isotretinoin.² X-ray-documented gastric ulcers, as reported to the ADRRS, are rarely reported. A variety of other toxicities have been associated with isotretinoin use, including ileitis,²⁸ breast discharge,⁵⁴ and bronchoconstriction.⁵⁵

Unfortunately, spontaneous reports of adverse reactions to a drug provide little information about the rate of adverse reactions or the mechanisms responsible for the reactions. Isotretinoin is a newly marketed drug that has received a great deal of public attention. It is, therefore, the type of

drug for which many reports of adverse reactions can be anticipated. It is not surprising that 7% of adverse reactions reported to the ADRRS were related to isotretinoin. It is important to bear in mind that reports of rare adverse reactions associated with isotretinoin have not been attributed directly to the drug.

Isotretinoin decreases sebum production by more than 85%. It also causes epidermal desquamation, alters cellular differentiation, decreases neutrophil and eosinophil motility, and may be an inhibitor of 5-lipoxygenase.⁵⁶⁻⁵⁸ Isotretinoin, like the other retinoids and vitamin A, stimulates bone growth and may participate in organizing and stabilizing cell membranes and in glycosylation reactions.^{24,56,59} None of these known effects of the drug can explain its ability to produce prolonged remission nor do they explain all of the wide variety of adverse events associated with this drug.

The mechanisms by which adverse reactions to newly introduced drugs are reported to physicians have not been systematically studied. From our Medline search of the literature concerning adverse reactions to isotretinoin, it is apparent that information about adverse reactions to newly marketed drugs reaches physicians by different routes and at different rates. Information about serious adverse reactions, exemplified by isotretinoin teratogenicity, may be available from animal studies prior to marketing of the drug. Such serious adverse reactions become widely known after the drug is marketed because numerous case reports and reports of large series of patients are quickly published. Other adverse reactions, for example, pseudotumor cerebri due to isotretinoin, may be disseminated rapidly by agencies such as the Food and Drug Administration and the ADRRS, which receive reports of adverse reactions to drugs. Reporting of other adverse reactions may take a much longer time to reach physicians because only a few or no case reports are published in many different journals and large series are not compiled and reported. This report, which is based on spontaneous reports to the ADRRS by cooperating dermatologists and on a review of the literature, should serve as a comprehensive review of adverse reactions encountered with isotretinoin use.

REFERENCES

1. Conner CS. Isotretinoin: a reappraisal. *Drug Intell Clin Pharm* 1984;18:308-9.
2. Windhorst DB, Nigra T. General clinical toxicology of oral retinoids. *J AM ACAD DERMATOL* 1982;6:675-82.
3. Stern R, Bigby M. An expanded profile of cutaneous reactions to nonsteroidal anti-inflammatory drugs: reports to a specialty-based system for spontaneous reporting of adverse reactions to drugs. *JAMA* 1984;252:1433-7.
4. National Adverse Drug Reaction Directory. Rockville, MD: U.S. Department of Health, Education, and Welfare, Food and Drug Administration, 1974.
5. Dreis MW, Jones JK, Graham CF. Procedure manual for processing of FDA forms FD-1639 and 1639-A drug experience report. Rockville, MD: U.S. Department of Health, Education, and Welfare, Food and Drug Administration, 1981.
6. Melski JW, Geer DE, Bleich HL. Medical information storage and retrieval using preprocessed variables. *Comput Biomed Res* 1978;11:613-21.
7. Taylor IM, Wiley MJ, Agur R. Retinoic acid-induced heart malformation in the hamster. *Teratology* 1980;21:193-7.
8. Newell-Morris L, Sirianni JE, Shepard TH, Fantel AG, Moffett BC. Teratogenic effects of retinoic acid in pigtail monkeys (*Macaca nemestrina*). II. Craniofacial features. *Teratology* 1980;22:87-101.
9. Hendrickx AG, Silverman S, Pellegrini M, Steffek AJ. Teratological and radiocephalometric analysis of craniofacial malformations induced with retinoic acid in rhesus monkeys (*Macaca mulatta*). *Teratology* 1980;22:13-22.
10. Yip JE, Kokich VG, Shepard TH. The effect of high doses of retinoic acid on prenatal craniofacial development in *Macaca nemestrina*. *Teratology* 1980;21:29-38.
11. Lorente CA, Miller SA. Vitamin A induction of cleft palate. *Cleft Palate J* 1978;15:378-85.
12. Kochlar DM. Cellular basis of congenital limb deformity induced in mice by vitamin A. *Birth Defects* 1977;13:111-54.
13. Kwasiogoch TE, Neubert D. Estimation of creatine phosphokinase and hydroxyproline in the developing limb: its use in evaluating the effect of teratogens on myogenesis and chondrogenesis. *Teratogenesis Carcinog Mutagen* 1980;1:181-91.
14. Rosa FW. Teratogenicity of isotretinoin [letter]. *Lancet* 1983;2:513.
15. Lott IT, Bocian M, Pribram HW, Leitner M. Fetal hydrocephalus and ear abnormalities associated with maternal use of isotretinoin. *J Pediatr* 1984;105:597-600.
16. Fernhoff PM, Lammer EJ. Craniofacial features of isotretinoin embryopathy. *J Pediatr* 1984;105:595-7.
17. Benke PJ. The isotretinoin teratogen syndrome. *JAMA* 1984;251:3267-9.
18. Hill RM. Isotretinoin teratogenicity [letter]. *Lancet* 1984;1:1465.
19. Braun JT, Franciosi RA, Mastro AR, Drake RM, O'Neil BL. Isotretinoin dysmorphic syndrome [letter]. *Lancet* 1984;1:506-7.
20. de la Cruz E, Sun S, Vangvanichyakorn K, Desposito F. Multiple congenital malformations associated with maternal isotretinoin therapy. *Pediatrics* 1984;74:428-30.
21. Update on birth defects with isotretinoin. *FDA Drug Bull* 1984;14:15-6.
22. Stern RS, Rosa F, Baum C. Isotretinoin and pregnancy. *J AM ACAD DERMATOL* 1984;10:851-4.
23. Isotretinoin—a newly recognized human teratogen. *MMWR* 1984;33:171-3.
24. Lammer EJ, Chen DT, Hoar RM, Agnish ND, et al. Retinoic acid embryopathy. *N Engl J Med* 1985;313:837-41.
25. Shalita AR, Cunningham WJ, Leyden JJ, Pochi PE, Strauss JS. Isotretinoin treatment of acne and related disorders: an update. *J AM ACAD DERMATOL* 1983;9:629-38.
26. Dreis MW. Suspected new, rare or unexpected serious adverse drug reactions reported to the division of drug experience to: isotretinoin—pseudotumor cerebri. *ADR Highlights* 1983;7:1-5.
27. Hazen PG, Carney JF, Walker AE, Stewart JJ. Depression—a side effect of 13-*cis*-retinoic acid therapy. *J AM ACAD DERMATOL* 1983;9:278-9.
28. Adverse effects with isotretinoin. *FDA Drug Bull* 1983;13:21-3.
29. Band PR, Besner JG, Leclaire RE, et al. Phase I study of 13-*cis*-retinoic acid toxicity. *Cancer Treat Rep* 1982;66:1759-61.
30. Kellett JK, Beck MH, Chalmers RJ. Erythema nodosum and circulating immune complexes in acne fulminans after treatment with isotretinoin. *Br Med J [Clin Res]* 1985;290:820.
31. Reports from the Voluntary Reporting System of the Division of Drug Experience, Bureau of Drugs, Food and Drug Administration, Rockville, MD: U.S. Department of Health, Education, and Welfare, Food and Drug Administration, 1985.
32. Hays SB, Camisa C. Acquired pili torti in two patients treated with synthetic retinoids. *Cutis* 1985;36:466-8.
33. Blumenthal G. Paronychia and pyogenic granuloma-like lesions with isotretinoin [letter]. *J AM ACAD DERMATOL* 1984;10:677-8.
34. Campbell JP, Grekin RC, Ellis CN, Matsuda-John SS, Swanson NA, Voorheer JJ. Retinoid therapy is associated with excess granulation tissue responses. *J AM ACAD DERMATOL* 1983;9:708-13.
35. Peck GL, Yoder FW. Treatment of lamellar ichthyosis and other keratinizing dermatosis with an oral synthetic retinoid. *Lancet* 1976;2:1172-4.
36. Williams ML, Elias PM. Nature of skin fragility in patients receiving retinoids for systemic effect. *Arch Dermatol* 1981;117:611-9.
37. Spear KL, Muller SH. Treatment of cystic acne with 13-*cis*-retinoic acid. *Mayo Clin Proc* 1983;58:509-14.
38. Exner JH, Dahod S, Pochi PE. Pyogenic granuloma-like acne lesions during isotretinoin therapy. *Arch Dermatol* 1983;119:808-11.
39. McCormack LS, Turner ML. Photosensitivity and isotretinoin therapy [letter]. *J AM ACAD DERMATOL* 1983;9:273-4.
40. Helfman RJ, Brickman M, Fahey J. Isotretinoin dermatitis simulating acute pityriasis rosea. *Cutis* 1984;33:297-300.
41. Molin L, Thomson K, Volden G, Lange Wantzin G.

- Retinoid dermatitis mimicking progression in mycosis fungoides: a report from the Scandinavian Mycosis Fungoides Group. *Acta Derm Venereol* (Stockh) 1985;65:69-71.
42. Milstone LM, McGuire J, Ablow RC. Premature epiphyseal closure in a child receiving oral 13-*cis*-retinoic acid. *J Am Acad Dermatol* 1982;7:663-6.
 43. Pittsley RA, Yoder FW. Retinoid hyperostosis. Skeletal toxicity associated with long-term administration of 13-*cis*-retinoic acid for refractory ichthyosis. *N Engl J Med* 1983;308:1012-4.
 44. Pennes DR, Ellis CN, Madison KC, Voorhees JJ, Martel W. Early skeletal hyperostoses secondary to 31-*cis*-retinoic acid. *AJR* 1984;142:979-83.
 45. Ellis CN, Madison KC, Pennes DR, Martel W, Voorhees JJ. Isotretinoin therapy is associated with early skeletal radiographic changes. *J Am Acad Dermatol* 1984;10:1024-9.
 46. Garber LH, Helfgott RK, Gross EG, Hicks JE, Ellenberg SS, Peck GL. Vertebral abnormalities associated with synthetic retinoid use. *J Am Acad Dermatol* 1984;10:817-23.
 47. Ellis CN, Pennes DR, Martel W, Voorhees JJ. Radiographic bone surveys after isotretinoin therapy for cystic acne. *Acta Derm Venereol* (Stockh) 1985;65:83-5.
 48. Matsuoka LY, Wortsman J, Pepper JJ. Acute arthritis during isotretinoin treatment of acne. *Arch Intern Med* 1984;144:1870-1.
 49. Milson J, Jones DH, King K, Cunliffe WJ. Ophthalmological effects of 13-*cis*-retinoic acid therapy for acne vulgaris [letter]. *Br J Dermatol* 1982;107:491.
 50. Weiss J, Degnan M, Leupold R, Lumpkin LR. Bilateral corneal opacities. Occurrence in a patient treated with oral isotretinoin. *Arch Dermatol* 1981;117:182-3.
 51. Palestine AG. Transient acute myopia resulting from isotretinoin (Accutane) therapy. *Ann Ophthalmol* 1984;16:660-2.
 52. Fraunfelder FT, La Braico JM, Meyer SM. Adverse ocular reactions possibly associated with isotretinoin. *Am J Ophthalmol* 1985;100:534-7.
 53. Weleber RG, Dearman ST, Hanifin JM, Cunningham WJ. Abnormal retinal function associated with isotretinoin therapy of acne. *Arch Ophthalmol* 1986;104:831-7.
 54. Larsen GK. Iatrogenic breast discharge with isotretinoin. *Arch Dermatol* 1985;121:450-1.
 55. Fisher DA. Exercise-induced bronchoconstriction related to isotretinoin therapy [letter]. *J Am Acad Dermatol* 1985;13:524.
 56. Dickens CH. Retinoids: a review. *J Am Acad Dermatol* 1984;11:541-2.
 57. Orfanos CE, Bauer E. Evidence for anti-inflammatory activities of oral synthetic retinoids: experimental findings and clinical experience. *Br J Dermatol* 1983;109(suppl 25):55-60.
 58. Kragballe K, Herlin T. Benoxaprofen improves psoriasis. *Arch Dermatol* 1983;119:548-52.
 59. DeLuca LM. The direct involvement of vitamin A in glycosyl transfer reactions of mammalian membranes. *Vitam Horm* 1977;35:1-57.

ABSTRACTS

Mupirocin-resistant *Staphylococcus aureus*

Rahman M, Noble WC, Cookson B. *Lancet* 1987;2:387

In studies at St. Thomas' Hospital in London, 14 patients have yielded mupirocin-resistant isolates of *Staphylococcus aureus*.
J. Graham Smith, Jr., M.D.

Methotrexate in rheumatoid arthritis

Health and Public Policy Committee. *Ann Intern Med* 1987;107:418-9

The guidelines for the use of methotrexate in rheumatoid arthritis as developed by the health and public policy committee of the American College of Physicians are notable by the lack of recommendations for liver biopsies.
J. Graham Smith, Jr., M.D.

Perinatal hepatitis B virus infection: screening of pregnant women and protection of the infant

Stevens CE. *Ann Intern Med* 1987;107:412-3

Most infants acquire hepatitis B virus infection at or near the time of delivery. Administration of hepatitis B immunoglobulin or

hepatitis B vaccine reduces the carrier rate from an expected 70% to 90% to 25%. Among the highest risk infants whose mothers have both hepatitis B surface and e antigens, administration of both immunoglobulin and hepatitis B vaccine reduces the carrier rate to 5% to 10%.

J. Graham Smith, Jr., M.D.

Nifedipine in the treatment of Raynaud's phenomenon in patients with systemic sclerosis

Meyrick Thomas RH, Rademaker M, Grimes SM, et al. *Br J Dermatol* 1987;117:237-41

Nifedipine, 10 mg three times daily for 6 weeks in ten patients with Raynaud's phenomenon secondary to systemic sclerosis, produced a significant reduction in the duration of attacks of Raynaud's phenomenon in a double-blind, placebo-controlled, crossover trial. It also reduced the number and severity of attacks of Raynaud's phenomenon and the development of new digital ulcers, and it increased digital blood flow.

J. Graham Smith, Jr., M.D.

these reasons, further study is needed to expand our observation and confirm the possible association between *B. burgdorferi* infection and urticarial vasculitis.

Judyann C. Olson, MD, and
Nancy B. Eslerly, MD

Departments of Pediatrics and Dermatology
The Medical College of Wisconsin
Children's Hospital of Wisconsin
Milwaukee, Wisconsin

REFERENCE

1. Grodzicki RL, Steere AC. Comparison of immunoblotting and indirect enzyme-linked immunosorbent assay using different antigen preparations for diagnosing early Lyme disease. *J Infect Dis* 1988;157:790-7.

Acute depression from isotretinoin

To the Editor: We read with interest the article by Scheinman et al. (*J AM ACAD DERMATOL* 1990;22:1112-4). We wish to add to the authors' evidence by reporting the case of a 17-year-old boy affected by a severely disfiguring cystic acne. After 4 months of treatment with isotretinoin, 0.5 mg/kg/day, the patient's skin was almost completely clear. One month after treatment was stopped, the patient began having difficulties in social readjustment. He still had problems in finding a job; he was unsettled at home, frequently arguing with his father and having difficulty in relating to girls. The patient was deeply disturbed by these problems. During the following month the boy unsuccessfully attempted suicide and received psychiatric care; however, 3 weeks later he succeeded in killing himself.

We cannot draw any specific conclusion because it is difficult to say in this case whether the treatment with isotretinoin played any specific role in promoting a major psychiatric illness in an already predisposed subject. However, we can suggest that clearing of an extremely disfiguring skin disease like cystic acne made it more difficult for the patient to overcome these minor failures, which had probably been previously accepted because they had been attributable, in the patient's mind, to his disfigured appearance.

Stefano Gatti, MD,^a and
Ferdinando Serri, MD,^b
2nd University of Rome,^a
and Catholic University,^b
Rome, Italy

Reply

To the Editor: Drs. Gatti and Serri raise several important points. As the authors suggest, it is improbable that isotretinoin played a direct role in the suicide of their pa-

tient because symptoms began 1 month after treatment was stopped. In our experience, patients with isotretinoin-induced depression developed symptoms during therapy. Moreover, as we noted in our article, these symptoms resolved rapidly, within 2 to 7 days, after discontinuation of therapy. We also agree with Drs. Gatti and Serri that some patients with severe acne may have unrealistically high expectations of what life will hold for them after the successful treatment of their acne.¹ A few of our patients had expressed a belief that on the healing of their last acne lesion, there would be immediate improvement in their academic, financial, or social lives. These patients were not prepared for the unsatisfying realities that they later experienced. Although dermatologists may be familiar with patients who have active, grossly disfiguring, facial acne and have attempted suicide, we must also be alert to this possible consequence occurring as a result of unrealistic expectations after isotretinoin therapy. We are aware of patients with other disfiguring diseases, such as Darier's disease, who have attempted suicide^{2,3} and therefore suggest that dermatologists maintain a high index of suspicion for suicide in patients with these disorders.

Gary L. Peck, MD,^a
John J. DiGiovanna, MD,^a and
David R. Rubinow, MD,^b
Dermatology Branch, National Cancer
Institute,^a and National Institute of
Mental Health,^b Bethesda, Maryland

REFERENCES

1. Rubinow DR, Peck GL, Squillacce KM, et al. Reduced anxiety and depression in cystic acne patients after successful treatment with oral isotretinoin. *J AM ACAD DERMATOL* 1987;17:25-32.
2. Demioff KD, Lehman ZA, Rubinow DR, et al. Suicidal ideation in Darier's disease and related disorders. *J AM ACAD DERMATOL* 1990;22:195-8.
3. Milton GP, Peck GL, Fu JL, et al. Exacerbation of Darier's disease by lithium carbonate. *J AM ACAD DERMATOL* 1990;23:926-8.

Determination of UVA protection

To the Editor: I read with great interest the recent article by Sayre and Agin (*J AM ACAD DERMATOL* 1990;23:429-40) regarding methodology for the determination of UVA protection. The authors' perspective, which is not shared by others in the scientific community, serves to further the discussion of UVA relevance to skin damage and the development of means of conveying this information to the consumer.

Sayre and Agin describe a procedure for determining UVA protection that involves three steps: (1) spectrophotometric determination of sunscreen UV absorbance spectra; (2) convolution of these spectra with the CIE UV Hazard Spectrum; and (3) incorporation of the

Chromosomal Locations and Modes of Action of Genes of the Retinoid (Vitamin A) System Support Their Involvement in the Etiology of Schizophrenia

Ann B. Goodman

Statistical Sciences and Epidemiology Division, Nathan S. Kline Institute for Psychiatric Research, Orangeburg, and Division of Epidemiology, Columbia University School of Public Health, New York, New York

Vitamin A (retinoid), an essential nutrient for fetal and subsequent mammalian development, is involved in gene expression, cell differentiation, proliferation, migration, and death. Retinoic acid (RA) the morphogenic derivative of vitamin A is highly teratogenic. In humans retinoid excess or deficit can result in brain anomalies and psychosis. This review discusses chromosomal loci of genes that control the retinoid cascade in relation to some candidate genes in schizophrenia. The paper relates the knowledge about the transport, delivery, and action of retinoids to what is presently known about the pathology of schizophrenia, with particular reference to the dopamine hypothesis, neurotransmitters, the glutamate hypothesis, retinitis pigmentosa, dermatologic disorders, and craniofacial anomalies. © 1995 Wiley-Liss, Inc.

KEY WORDS: schizophrenia, retinoids, dopamine receptors, glutamate receptors, neuroregulators, gene expression regulation

INTRODUCTION

Vitamin A (retinoid) is an essential nutrient for mammalian development and survival. It is required by the early embryo, throughout fetal development, until the end of the life span. The vitamin is involved in the processes of gene expression and regulation, and in cell differentiation, proliferation, migration, and death. The role of retinoids in neurodevelopmental processes is the focus of much study, but less is known about the effects of retinoids in the adult brain. The pervasive

regulatory presence and far reaching effects of retinoid activity in these processes has led me to seek evidence for specific roles for retinoids that might be fundamental to the etiology of schizophrenia. In this respect, retinoic acid (RA), the morphogenic derivative of vitamin A, is known to alter patterns of neurulation and brain development. Retinoid toxicity or deficit can result in psychosis, and in craniofacial, limb, digit, heart, and urogenital abnormalities similar to those co-occurring with schizophrenia. Hydrocephalus, characterized by increased third or fourth ventricle size and/or decreased size of the hind- or fore-brain, is a characteristic pattern of retinoid toxicity. The nuclear receptors for RA and the transport proteins for retinoid metabolites are present in all parts of the brain and delivery of retinoids is tightly controlled throughout embryonic, fetal, and postnatal development. Since vitamin A cannot be synthesized within the body, a highly developed and well-regulated storage and transport system has evolved, which is well conserved. Alterations in the functioning of the retinoid cascade may have profound implications for neurodevelopmental and/or neurodegenerative disorders like schizophrenia.

This review discusses the genes that control the retinoid cascade in relation to genes that are suggested in the literature to be involved in the schizophrenic diathesis. The breadth of the control of gene expression by retinoids and the specificity of the effects regarding processes postulated to be abnormal in schizophrenia suggests that this control system may be integral to our understanding of this disease.

BACKGROUND

The multiple demonstrations of neuropathological abnormalities in schizophrenic brains leads to the general agreement that a significant proportion of schizophrenic patients suffer from a subtle disorder of early brain development [Bogerts, 1993; Bloom, 1993; Conrad et al., 1991]. This disorder results in the subsequent stigmata of schizophrenia that includes: structural brain anomalies [Suddath et al., 1990; Jacob and Beckman, 1986], e.g. abnormalities of neuronal migration and faulty apoptosis [Akbarian et al., 1993], anomalous development of midline brain regions [Shapiro,

Received for publication December 29, 1994; revision received April 24, 1995.

Address reprint requests to Ann B. Goodman, Nathan S. Kline Institute, 140 Old Orangeburg Road, Orangeburg, NY 10962.

© 1995 Wiley-Liss, Inc.

1993] with reduced size of the thalamus [Andreasen et al., 1994a] and frontal cortex [Andreasen et al., 1994b], ventricular enlargement [De Lisi et al., 1986]; van Horn and McManus, 1992; Gur et al., 1994], minor physical anomalies [Green et al., 1989; O'Callaghan et al., 1991; Torrey et al., 1994; Green et al., 1994], involving the eyes, nose, ears, mouth, and digits [Lane et al., 1994], altered neurotransmitter and excitotoxic functions [Lieberman and Koren, 1993], and disordered thinking and psychosis. It is an hypothesis of this paper that these stigmata may reflect, in part, alteration of the functioning of the retinoid cascade.

Over the years European and United States literature contains sporadic case reports of the occurrence of acute schizophrenia or remitting psychosis associated with either hypervitaminosis A [Restak, 1972; Haupt, 1977; Ragavan et al., 1982; Landy, 1985; Gatti and Serrit, 1991; Halter, 1991] or vitamin A deficiency [Olver, 1986]. Prenatal nutritional deprivation may be a risk factor in the subsequent development of schizophrenia [Butler et al., 1994]. I have proposed retinoid dysregulation as a possible cause of schizophrenia [Goodman, 1994a,b]. Implicit in the retinoid hypothesis is the theory that at least some of the many varieties of neurochemical, biological, and physical anomalies found among schizophrenics are pleiotropic spectrum variations of the disturbances found in genetic and early developmental disorders of anomalous retinoid function. This paper will demonstrate that the genes for several of these disorders lie in close chromosomal proximity to the retinoid genes. It will show that in many cases the conditions occurring with schizophrenia are found in biological systems that respond to retinoid regulation or are similar to conditions thought to be caused by retinoid toxicity.

GENES INVOLVED IN THE RETINOID CASCADE

Vitamin A, which is a fat soluble vitamin, found as beta carotene in vegetables, and as retinyl esters in animal tissues, is taken in from the diet, hydrolyzed to retinol and esterified in reaction to fatty acids in the intestine, and incorporated into chylomicrons. Other peripheral tissues, e.g., brain, skin, and bone, also play roles in the storage, transport and metabolism of retinol [Soprano and Blaner, 1994]. Chylomicron remnants probably serve as a delivery system for retinyl esters to multiple target tissues which are experiencing periods of intensive cell proliferation and differentiation [Blomhoff et al., 1990]. Essentially all of the retinol in plasma that is not associated with chylomicron remnants is mobilized from liver stores in parenchymal and stellate cells [Goodman and Blaner, 1984] and transported in plasma as retinol bound to the retinol binding proteins (RBPs). It is thought that cellular retinol-binding proteins (CRBPs) incorporate retinol at the cell membrane level of target tissues [Goodman, 1984a; Blomhoff, 1990].

Most of the retinol-RBP is reversibly complexed with another protein, transthyretin (TTR), and normally circulates as a 1:1 molar RBP-TTR complex. TTR also serves as a transport protein for thyroxine in some

species [Goodman, 1987]. TTR transports bound retinol to target tissues throughout the body, including the brain. Within the central nervous system TTR is synthesized in the choroid plexus, and as such TTR may serve as the transchoroidal transport protein carrying retinol and thyroxine across the blood/cerebrospinal fluid (CSF) barrier. Twenty-five percent of the protein in the CSF is TTR [Herbert et al., 1986]. Owing to its potential role as the choroid plexus transport for retinol and its high level in CSF of the third and fourth ventricles, I have proposed TTR as a candidate gene in schizophrenia [Goodman, 1994b]. Linkage of manic depressive illness to a pericentromeric region proximal to TTR has been suggested [Berretini et al., 1994]. Although RBP has been studied in many diseases, there have been no reports of diseases where RBP is totally absent or where an abnormal form of RBP is present [Goodman, 1987], whereas more than 40 mutations of TTR, the gene which causes various forms of familial amyloidotic polyneuropathy, have been identified [Saraiva, 1995]. The pathogenicity of mutant TTR is modulated by allelic variants of complement factor C3, with increase in C3F variants resulting in expression of the disease phenotype [Nylander et al., 1990]. Increase in the C3F allele is associated with schizophrenia in one study [Rudduck et al., 1985], but this finding is not confirmed [Fananas et al., 1992].

Currently seven genes are thought to serve as the primary transports of retinoids throughout the body, and six genes are identified that code for the nuclear receptors that bind a variety of the final metabolite of vitamin A, RA. The genes which regulate this cascade code for the retinol binding proteins (RBPs) and their cellular analogs (CRBPs), RBP1, RBP2, RBP3, RBP4, cellular retinaldehyde binding protein (CRALBP1), the cellular retinoic acid binding proteins (CRABPs), CRABP1 and CRABP2, the retinoic acid receptors (RARs), RAR α , RAR β , RAR γ ; and the retinol X receptors (RXRs), RXR α , RXR β , RXR γ , and transthyretin (TTR). To my knowledge, to date no mutations have been identified in the RBPs, CRBPs, CRABPs, RARs, or RXRs. Such mutations may be lethal [Kastner et al., 1994].

The morphogens in the retinoid cascade consist of a variety of RAs, e.g., all-*trans*-RA and 9-*cis*-RA, created through the oxidation of retinol. The prevailing hypothesis is that retinol is first oxidized to retinaldehyde, which in turn is oxidized to RA. Most cells and tissues have the metabolic machinery needed to oxidize retinol and retinaldehyde to RA [Blaner and Olsen, 1994]. RA is synthesized from retinol by means of the alcohol dehydrogenases [Napoli et al., 1992; Shih and Hill, 1991; Saari, 1994]. The production of alcohol dehydrogenase is modulated by both retinoic acid and thyroid hormones, which are able to repress RA induction of alcohol dehydrogenase through complex feedback mechanisms, thus altering this rate limiting step in the synthesis of retinoic acid [Harding and Duester, 1992]. Several studies have demonstrated disordered thyroid functioning in psychotic illness, some showing thyroid alterations with acute psychotic symptoms [Kerwin and Burnett, 1989; Haberfellner et al., 1993; Roca et al., 1990], or occurring with increased ventricle/brain ratios

[Johnstone et al., 1986], one of the pathognomonic hallmarks of retinoid toxicity, or co-segregating with schizophrenia within families [DeLisi et al., 1991]. The aldehyde form of vitamin A, retinal, is bound by cellular retinaldehyde binding protein (CRALBP) [Saari, 1994]. RA is synthesized from retinal by various aldehyde dehydrogenases [Mangelsdorf et al., 1994; McCaffery et al., 1992]. High levels of retinaldehyde dehydrogenase are found in the mouse forebrain, particularly the dopaminergic regions [Zimatkin, 1991]. This suggests that RA might be important in the functioning of these neural structures. The finding of high levels of retinoic acid-generating dehydrogenase in the dopaminergic system suggests that these dehydrogenases could function as a back-up for dopamine metabolism [McCaffery and Drager, 1994].

RA is bound to two cellular retinoic acid-binding proteins (CRABP1 and CRABP2) which have a strong structural relation to the CRBPs, but that do not bind retinol [Ong et al., 1994]. CRABP1 is found in relatively high levels in the brain, and in neonatal skin, but not in adult skin. CRABP2 has not been found in the brain [Ong et al., 1994]. CRABPs sequester RA that is present in excess of cellular needs, providing stable availability when needed for metabolism and regulation of differentiation-specific gene expression [Boylan and Gudas, 1991]. In vitro, CRABP significantly alters the metabolism of bound retinoids to other compounds as compared to the metabolism of free RA, thus accelerating some conversions of retinol to RA but preventing others, and in this manner conserving homeostasis of the system [Napoli, 1993]. The CRBPs are also important in maintaining the rate of oxidation of retinol to RA, for they sequester bound retinol from oxidation, but still permit the oxidation of unbound retinol to retinal and then to RA, via the action of the various dehydrogenases [Ong et al., 1994]. In humans it is thought that retinoid toxicity occurs through a disruption of this homeostasis, not only as the result of exposure to excessive levels of RA [Rosa, 1983; Braun et al., 1984; Lammer et al., 1985; Creech Kraft et al., 1989], but also as the result of increased plasma concentration of total retinol and retinyl esters. In such cases it has been suggested that vitamin A toxicity (with retinol) occurs when the capacity of the proteins which transport retinol and RA is exceeded, so that the retinoids are presented to cell membranes in unbound form, that leads to non-specific effects on cell membranes [Smith and Goodman, 1976; Morriss-Kay, 1993].

RA may have a role in the regulation of neuronal migration [Johnston and Bronsky, 1991; Maden and Holder, 1992], which may be mediated by the distribution of the CRABPs found in migrating neural cells [Ruberte et al., 1992]. CRABP is expressed in the CNS and the craniofacial mesenchyme. It probably plays an important role in normal embryogenesis in those tissues, which are highly susceptible to the adverse effects of excess RA [Vaessen et al., 1990]. Exposure of early neural plate stage embryos to RA excess causes abnormalities of craniofacial development. Conversely maternal vitamin A deficiency produces other craniofacial anomalies. In rats, supplementation of a vitamin A de-

ficient diet with RA prevents abnormal development [Morriss-Kay, 1993].

No protein is unequivocally established as the transport for RA, although circulating RA is bound to serum albumin, but not to RBP [Fidge et al., 1968; Smith et al., 1973]. CSF concentration of albumin is elevated in some schizophrenics, but not all, suggesting an impairment in the blood/CSF barrier [Kirch et al., 1985; Bauer and Kornhuber, 1987]. A finding of elevated albumin levels in the brains of some schizophrenics raises the question of increased transport of RA, resulting in abnormal availability of RA to brain structures. A recent report shows that RA may displace thyroxine in binding to TTR, and this suggests that, in addition to transporting RBP and thyroxine, TTR may also serve as a transport protein for RA [Smith et al., 1994], and in this role supplement the RA transport role of albumin. Since TTR is known to be highly polymorphic, some of these polymorphisms may result in abnormal levels of RA in brain.

RA is incorporated into the nucleus by means of six steroid hormone-like nuclear retinoic acid receptors (RARs): RAR α , RAR β , RAR γ , RXR α , RXR β , and RXR γ . At least one RAR is present in all parts of the brain [Morriss-Kay, 1993]. These receptors function as transcription factors that regulate the expression of specific genes, e.g., oncogenes, suppressor genes, and many growth factors and cytokines and their receptors [Gudas et al., 1994]. RA is active on the transcriptional level through retinoic acid response elements (RAREs), particular sequences within the DNA which recognize RARs, and serve as mechanisms of gene transcription and regulation [Goodman, 1984b; Goodman and Blaner, 1984; Blomhoff et al., 1990; Blaner and Olson, 1994].

There are several different mechanisms by which RA can control a gene. The first would be through a change in the rate of gene transcription. A second mechanism would involve a change in the stability or half-life of a particular mRNA in response to RA. A RA-associated change at the level of transcription could result either from a *direct* or *indirect* effect of RA. *Direct* effects of RA on gene transcription are generally assumed to be effects that can be elicited without any new protein synthesis, that are rapid (occurring from minutes to a few hours after RA exposure) and that are mediated by direct binding of RARs or RAR-RXR complexes to a RA-responsive element (RARE). In the case of indirect regulation, the gene generally responds to RA by a change in the rate of transcription at a later time, and no direct binding of RARs or RAR-RXRs to the RA-responsive portion of the DNA is seen. In this case, RA (through RA-RAR complexes) may first activate the expression of a transcription factor, which would then regulate the RA-responsive gene through a response element that would depend on the type of transcription factor. (Gudas et al., 1994, pp 444-446).

Through their interaction with c-fos/c-jun AP-1 binding sites in the DNA, RAR molecules also control cell

growth and proliferation [Fanjul et al., 1994]. Effective action of antipsychotic drugs induces the expression of c-fos [Deutch et al., 1994]. These molecules are all part of an exquisitely controlled and regulated cascade of interactions used by cells and tissues to integrate information relating to their state of differentiation and proliferation [Gudas et al., 1994].

The capacity of RA to control gene transcription and expression means that retinoid dysregulation, either through altered transport of retinoid products, resulting in altered availability of RA to target cells, or altered timing of exposure to RA, or altered spatial distribution of RARs in target tissues, or altered incorporation of RARs into target genes may cause abnormalities in gene protein products independent of DNA mutations in the target genes. This observation suggests new research strategies to investigate the genetic basis for schizophrenia. In addition to seeking to identify mutations and allelic variants in target genes, the study of retinoid regulation of candidate genes may offer a fruitful avenue of investigation.

CHROMOSOMAL LOCUS OF RETINOID GENES AND SOME GENES IMPLICATED IN SCHIZOPHRENIA

In bacteria it is observed that genes contiguous to one another tend to regulate the transcription of one another, under a common control unit [Vogel and Motulsky, 1986], leading to the operon concept of positive and negative genetic regulation. For example in *E. coli* the expression of three *closely linked* structural genes are under the common control of the lactose operon [Jacob and Monod, 1961]. In this case bacteria utilize energy to express lactase-cleaving enzymes only in the presence of lactose. Positive or negative feedback relative to the availability of lactose serves as an energy-efficient system within the organism. Although the elements of gene activity and regulation are much more complicated in higher organisms than in bacteria, "it can be expected from experience with evolutionary genetics that nature may have utilized similar principles for gene regulation." [Vogel and Motulsky, 1986, p 325].

With this in mind I have hypothesized that genes in the retinoid cascade, whose genetic regulation is highly conserved [Goodman, 1987], may operate under a concept analogous to the lactose operon. This reasoning is supported by the observations that the expression of three genes in the retinoid cascade, RAR- β , CRABP1, and CRBP1 are, themselves, induced by retinoic acid [Ruberte et al., 1992], and that CRABP limits the access of RA to the nuclear receptors [Ruberte et al., 1993]. These observations are suggestive of an operon-like link between the synthesis of RA from retinol and the control of expression of subsets of RA-responsive genes. The possibility exists that under various conditions of vitamin A availability retinoid cascade genes may also act in an operon manner to regulate groups of other *closely linked* structural genes, as in the *E. coli* example above. While direct evidence for this in eukaryotes is meager, it is certainly implied in the colinearity of the RA responsive Hox genes, and in the linkage between the RA responsive Wnt and keratin genes

and the gene for the RAR γ [Hart et al., 1992]. Another good example is the transcriptional regulation of the closely linked RAR genes, homeobox genes, and integrin genes by RA [Maden and Holder, 1992; Ross et al., 1994; Dedhar et al., 1991; Hofmann and Eichele, 1994]. This regulation is accomplished by means of a variety of nucleic acid retinoic acid response elements (RAREs) within the promoter regions of these genes. In humans, these genes are co-localized at chromosomes 12q13 and 17q21 (see Table I). I have observed the co-localization of many genes thought to be implicated in schizophrenia with the major retinoid genes. These observations support the hypothesis that retinoids may act as operon-like controllers or regulators of many of the putative schizophrenia genes, which are located in close chromosomal contiguity to genes of the retinoid cascade.

Table I displays the chromosomal location of the genes within the retinoid cascade. Also displayed are some genes at the same or nearby loci which review of the literature indicates to be potentially involved in schizophrenia. An hypothesis of this paper is that there is an increased likelihood that these genes are regulated by retinoids, due to their chromosomal proximity to the retinoid genes. The genes presented in Table I represent only a portion of those genes that are proximal to retinoid genes and are implicated in schizophrenia.

POSSIBLE MECHANISMS OF ACTION OF RETINOIDS IN SCHIZOPHRENIA

Proposed mechanisms that might explain the co-occurrence of schizophrenia with various illnesses known to be caused by genes which are located contiguous to retinoid pathway genes are:

Disease Gene Mutation vs. Disease Gene Retinoid Regulation

The schizophrenic phenotype and the disease gene phenotype may arise from disruption of the disease gene function by one of several mutations. For example, Gaucher's disease, type 1, caused by absence of glucocerebrosidase, and adult GM2 gangliosidosis (Tay Sachs disease), caused by absence of hexosaminidase A, are recessive lysosomal enzyme illnesses of high frequency in the Ashkenazi gene pool. Each illness has been reported to co-occur with psychosis [for review, see Goodman, 1994c]. This psychosis may be an alternate phenotypic spectrum presentation that is part of a common pathway of pathology caused by the particular mutations in the genes.

On the other hand, each of these disease genes is found in the genome at the same locus as one of the major retinoid genes, raising the possibility of retinoid regulation. Retinoids are known to profoundly alter the release of lysosomal enzymes [Dingle et al., 1971; Camisa et al., 1982]. The Tay Sachs gene is on chromosome 15q23-24 at the locus of CRABP1 and near by CRALBP1 at chromosome 15q26. The GM2 ganglioside activator protein is at the CRBP2 locus, 3q21-q25. The Gaucher's gene is on chromosome 1q21 at the locus of CRABP2, and proximal to the RXR γ locus at 1q23-25. Of important note here is that a DNA sequence that

TABLE I. Loci of Retinoid Genes and Co-Localized Genes Implicated in Schizophrenia or Psychosis*

1q21 CELLULAR RETINOIC ACID BINDING PROTEIN II (CRABP2)	10q23-q24 RETINOL BINDING PROTEIN 4 (RBP4)
1q21 Dopamine receptor D6 pseudogene 2 (DRD5P2)	10q23.3 Glutamate dehydrogenase (GLUD1)
1q21 Glucocerebrosidase (GBA)	10q22.1 Glutamate dehydrogenase pseudogene (GLUDP3)
1q21 Interleukin receptor 6 (IL6R)	10q24.1-q25.1 Glutamic-oxaloacetic transaminase 1 (GOT1)
1q21 Epidermal differentiation genes: profilaggrin, loricrin, involucrin, and catyelin	10q24-q26 F1 Adrenergic receptor
1q21 Ichthyosis vulgaris	10q25.1-qter Glutamate decarboxylase-2 (GAD2)
1q21.2-q22 Heat shock protein 90 (HSPCAL1)	12q13 RETINOIC ACID RECEPTOR γ (RAR γ)
1q22-23 RETINOIC X RECEPTOR γ (RXR γ)	12q1.1-q13.3 Integrin $\alpha 5$ (ITGA5)
3p24.3-p24.2 RETINOIC ACID RECEPTOR β (RAR β)	12q11-q13.3 Human immunodeficiency virus-1 (HIV-1)
3p24 Treacher Collins syndrome	12q13.1 Integrin $\beta 7$ (ITGB7)
3p21 Sotos syndrome (cerebral gigantism)	12q12-q13 Homeobox C cluster (HOXC)
3p11-qter CELLULAR RETINOL BINDING PROTEIN II (RBP2)	12q13 Serine hydroxymethyltransferase (SHMT)
3q13.3 Dopamine receptor D3 (DRD3)	12q15 Cerebral gigantism (Sotos syndrome)
3q13.1-q13.2 Integrin-associated protein (IAP)	12q24.2 ALDEHYDE DEHYDROGENASE
3q21-q22 CELLULAR RETINOL BINDING PROTEIN I (RBP1)	12q23-q24.1 Spinocerebellar ataxia 2 (SCA2)
3q21.2-q24 Retinitis pigmentosa 4	12q23-q24.1 Darier's disease
3q21-q25 GM2 ganglioside activator protein, pseudo (GM2AP)	12q22-qter Noonan's syndrome
6p21.3 RETINOIC X RECEPTOR β (RXR β)	15q22-qter CELLULAR RETINOIC ACID BINDING PROTEIN (CRABP1)
6p23.05-p24.2 Spinocerebellar ataxia 1 (SCA 1)	15q22 Cerebral gigantism (Sotos syndrome)
6p21.2 cen Retinitis pigmentosa (RDS, RP7)	15q23-q24 HLA class II genes
6p21 Sotos syndrome (cerebral gigantism)	15q17 (q22-24;q21.1) Acute promyelocytic leukemia
6p21.3 Heat shock protein 90 (HSPCB)	16q24 Nicotinic cholinergic receptors, alpha 3, 5 and beta 4 (CHRNA3, CHRNB4, CHRNA5, CHRNB4)
6p21.3 Homeobox 12 (HOX12)	15q26 CELLULAR RETINALDEHYDE BINDING PROTEIN 1 (CRALBP1)
6p21.3 Microtubule associated protein, tau 2 (MAPT2)	15q26 Muscarinic cholinergic receptor (CHRM5)
6p21.3 Major histocompatibility complex (HLA)	17q21.1 RETINOIC ACID RECEPTOR α (RAR α)
9q34 RETINOIC X RECEPTOR α (RXR α)	17q21 Microtubule associated protein tau (MAPT)
9q34 Dopamine beta hydroxylase (DBH)	17q21-q22 Disinhibition-dementia-parkinsonism-amyotrophy complex (DDPAC)
9q34.3 N-methyl-D-aspartate receptor 1 (NMDAR1)	17q21-q22 Homeobox B cluster (HOXB)
9q34.3 Glutamate receptor, ionotropic (GRIN1)	17q21.3 Integrins, alpha 2b (ITGA2B)
22q11 Breakpoint (B22P1) (19;22)(q34;q11)	17q11-qter Integrin, beta 4 (ITGB4)
9pter-9q34 ALDEHYDE DEHYDROGENASE X (ALDHx)	17q21.32 Integrin, beta 3 (ITGB3)
9q21 ALDEHYDE DEHYDROGENASE 1 (ALDH1)	17q12-q24 Keratosis palmaris et plantaris (aka Darier's disease, tylosis)
10q11.2 RETINOL BINDING PROTEIN 3 (RBP3)	17q12-q21.1 Sjogren-Larsson syndrome
10q11.2 Glutamate dehydrogenase pseudogene (GLUDP 2)	CHROMOSOME 17 ALDEHYDE DEHYDROGENASE 3
10q11.2 Choline acetyltransferase (ChAT)	18q12.1 TRANSTHYRETIN (TTR)
	18p11-q11.2 Manic depressive illness

*Reference citation for all loci is Genome Data Base, 1994.

identifies an RARE is found in the 5' promoter region of the Gaucher's gene, glucocerebrosidase (Goodman and Sapirstein, unpublished observation). It seems probable, therefore, that retinoids are involved in the regulation of the glucocerebrosidase gene. Retinoid dysregulation of the non-mutated gene might result in an end phenotype, psychosis, that resembles the psychosis caused by the mutant gene, but without the requirement of gene mutation. In such a case DNA point mutation searches of the suspected disease candidate gene would yield negative results, although the gene product could be intimately involved in the resultant psychotic phenotype. If the retinoid dysregulation was not due to mutation of a retinoid gene, but rather was the result of alterations in retinoid availability, as controlled by a dysfunctional retinoid gene mapping distant from the candidate gene, i.e., a *trans* mechanism, then linkage studies, too, would be negative, in spite of actual gene protein product involvement. However, if the dysfunctional retinoid gene co-localized with the candidate gene, then, indeed, linkage would detect it.

Retinoids involved in the dopaminergic system.

In mouse embryos RXR γ is found in the caudate putamen, the major target of dopaminergic innervation by the substantia nigra [Mangelsdorf et al., 1992]. In situ hybridization and immunohistochemical studies demonstrate that RAR β , RXR γ , RBP1, and RBP2 are extremely highly expressed in the dopamine-innervated areas in newborn rats, and that expression declines during postnatal development. Preliminary studies of human postmortem tissue find similar populations of retinoid expressive neurons in the human caudate and putamen [Zetterstrom et al., 1994]. These data suggest that retinoids are important in the development of both embryonal and adult dopamine-innervated areas of the brain, particularly the caudate nucleus, an area in which the D4 receptors, which are elevated in schizophrenia [Seeman et al., 1993], occur [Sumiyoshi et al., 1994]. Recently it has been reported that exposure of a neuroblastoma cell line (SHSY-5Y) to RA results in increased mRNA and density of dopamine D2 receptors in the differentiated cells. The increased presence of D3 and D4 receptors could not be excluded [Faroqui, 1994]. These observations have critical importance for the dopamine hypothesis in relation to the etiology of schizophrenia, because they directly link retinoid gene products and the possibility of retinoid regulation to the dopaminergic system. The DRD3 gene at 3q13.3 lies within the area to which RBP2 is mapped, and adjacent to RBP1 at 3q21-q22. Retinoid pathology, either genetic, spatial, or temporal, could alter transcription of the dopamine receptors, resulting in any one of the phenotypic presentations associated with dopamine receptors in schizophrenia [Seeman et al., 1993; Crocq et al., 1992; Laurent et al., 1994; Schmauss et al., 1993; Gurevich et al., 1994] without any allelic abnormalities in the receptor genes themselves. With one exception [Crocq et al., 1992], no mutations of the dopamine receptors are identified in schizophrenia [Daniels et al., 1994; Barr et al., 1993]. Retinoid involvement could occur via epistatic or environmental interactions relating to the availability of vitamin A, regulated by the various

retinoid transport genes and ligand-activated transcription factors.

Retinoic acid regulation of neurotransmitter systems.

Alteration of neurotransmitters is a classic hallmark of the psychoses, and treatments in schizophrenia reflect the importance of neurotransmitters in the psychotic process [Meltzer, 1992]. Recent work shows that RA is a major regulator of several of the genes involved in neurotransmission [Berrard et al., 1992], and, therefore, it is not unreasonable to suggest that retinoid dysregulation may be one of the base causes of neurotransmitter pathology in schizophrenia. The proximity of several of the genes involved in catecholamine synthesis to major retinoid genes lends support to this hypothesis. Dopamine beta hydroxylase (DBH) is located at the 9q34 locus of RXRa. Several studies find lowered levels of DBH in paranoid schizophrenic patients [Arato et al., 1982; Fujita et al., 1978; Meltzer et al., 1980]. One study reports an association between decreased DBH and increased ventricle size [Meltzer et al., 1984]. This might reflect altered retinoid processing that results in both ventricular enlargement and lowered DBH. RA reduces the specific activity of DBH and tyrosine hydroxylase, and increases the activity of acetylcholine and choline acetyltransferase (ChAT) [Berrard et al., 1993; Adem et al., 1987; Pedersen and Blusztajn, 1994]. ChAT is at the 10q11.2 locus of interstitial RBP3. RA also increases the survival of cholinergic and met-enkephalinergic neurons in rat spinal cord cultures, but has no effect on GABAergic neurons [Wnarin et al., 1991]. A recent study finds significant decreases in cholinergic receptors in the basal ganglia of schizophrenics compared to controls. The authors suggest that the decrease might be the result of downregulation of cholinergic or dopaminergic expression [Spurney et al., 1994]. Such downregulation could result from anomalous functioning of the various genes in the retinoid cascade, which are present in the dopaminergic areas of the brain and are, themselves, regulated by retinoids.

Virgo et al. [1992] characterize the distribution of ChAT mRNA in normals and in patients with motor neuron disease, particularly amyotrophic lateral sclerosis (ALS). They report high concentrations in the ventral gray matter of normals and substantial decreases in ALS cases. I have found significantly increased rates of grey matter disease, particularly ALS, in schizophrenic families [Goodman, 1994b,c]. Recent studies report anomalies in grey matter in schizophrenic brains [Keshavan et al., 1994; Nopoulos et al., 1994]. The co-occurrence in families of disorders of the gray matter regions of the brain, suggest a number of possible common underlying etiologies, e.g., abnormalities of glutamate excitotoxicity, coupled with free radical injury resulting in cell death [Lipton and Rosenberg, 1994; Lafon-Cazal et al., 1993]. Retinoids can disrupt the functioning of migrating neural crest cells [Shankar et al., 1994], and in the process generate oxygen free radicals [Davis et al., 1990]. Other possibilities might include disorder of mRNA expression of genes controlled by retinoids, due to dysregulation of retinoid processing that potentially involves ChAT at the RBP3

locus, or any one of a number of genes at the 17q21 locus of RAR α , including microtubule associated protein tau (MAPT). In these disorders abnormal function of retinoid genes or genes regulated by retinoids might result in some cases in ALS, and in other cases might lead to abnormal neuronal migration, resulting in brain pathology and resultant behavioral disorder. Very recently linkage of chromosome 17q21-22 to a new syndrome, DDPAC, which includes psychosis and ALS, has been demonstrated [Wilhelmsen et al., 1994].

In addition to upregulating ChAT expression and generating radical oxygen species, RA can direct the migration of neural crest cells in mice to inappropriate sites. Such abnormal patterning appears to be initiated while the crest cells lie within the hindbrain neural epithelium [Murphy et al., 1992]. Numerous authors suggest abnormal neuronal migration in schizophrenia [Conrad and Scheibel, 1987; Akbarian et al., 1993; Keshavan et al., 1994; Bloom, 1993; Virgo et al., 1994]. Evidence to suggest direct retinoid control of some of the neurotransmitters is the occurrence of RARE DNA sequences within the neurotransmitter genes, ChAT, nicotine acetylcholine, and DOPA decarboxylase-like protein, and within the protein kinase c beta isoform (Goodman and Sapirstein, unpublished observations).

Retinoids and regulations of the excitatory amino acids. As displayed in Table I several of the excitatory amino acid receptors are co-localized with genes in the retinoid cascade. Glutamate genes are concentrated on chromosome 10 at the RBP3 and RBP 4 loci. Mitochondrial serine hydroxymethyltransferase (SHMT), the enzyme that metabolizes glycine, is on 12q13 at the RAR γ locus. Because of its role in NMDA-receptor potentiation, SHMT has been suggested as a candidate gene in schizophrenia [Waziri et al., 1990; Devor and Waziri, 1993]. RA has been shown to upregulate the expression of both NMDA and non-NMDA glutamate receptors [Younkin et al., 1993; Hardy et al., 1994]. RA-induced cell differentiation is accompanied by an increase in NMDAR1 mRNA [Beczowska et al., 1994]. NMDAR1 is at the 9q34 locus of RXR α . Aldehyde dehydrogenase x, the rate limiting enzyme in the synthesis of retinal to RA in the brain, is also mapped to this locus [Hsu and Chang, 1991].

Several laboratories establish a case for glutamates in the etiology of schizophrenia [Carlson and Carlson, 1990; Javitt and Zukin, 1991; Simpson et al., 1992; Williamson, 1993; Debonnel, 1993; Ulas and Cotman, 1993; Olney and Farber, 1994]. Data suggest that abnormalities of NMDA function may relate to the pathophysiology of schizophrenia, in that the drug, phencyclidine (PCP), produces psychotic symptoms that mimic schizophrenia by blocking NMDA-gated ion channels. An abnormality in glutamate innervation is proposed to explain the observed increase in kainate and NMDA receptors in schizophrenic frontal cortex [Deakin et al., 1989]. The NMDAR1 locus has been investigated in schizophrenia, and linkage has been deemed unlikely [Coon et al., 1994a,b]. However, as discussed above in relation to the dopamine receptors, if the gene itself is normal but the expression of the gene, as regulated by retinoids, is abnormal, then linkage would not be found

even though NMDAR1 function might be abnormal in schizophrenia.

Contiguity of Retinoid Gene and Psychosis Gene vs. Retinoid gene mutation

Retinitis pigmentosa, ataxia, psychosis, and the retinoid loci. Retinitis pigmentosa is frequently reported to co-occur with psychosis, in the form of Usher's syndrome [Weiss et al., 1981; Sharp et al., 1994], and certain of the spinocerebellar ataxias [Hallgren, 1959; Keddie, 1969], including Sjogren-Larsson syndrome [Selmanowitz and Porter, 1967]. The co-occurrence of retinitis pigmentosa and deafness, accompanied by slow psychomotor development with autistic features, is observed in a cohort of children. These children were followed to age five after in utero exposure during the 1980s to Acutane, a synthetic RA derivative used to treat severe acne in the mothers [Adams and Lammer, 1993]. Longitudinal followup studies now in process will indicate whether these children are vulnerable to adult psychosis (Adams, personal communication, 1994). Several reports show psychosis in connection with retinitis pigmentosa and deaf-mutism. In these reports the investigators suggest that the mental illness is an integral part of the organic configuration [Remvig, 1969; Hallgren, 1959]. Sjogren-Larsson syndrome, a disorder thought to be caused by deficiency of an aldehyde dehydrogenase, has recently been linked to a marker at the 17q21.1 locus of RAR α [Pigg et al., 1994]. Aldehyde dehydrogenase 3 also maps to chromosome 17. Thus, the search for mutations associated with the syndromes with retinitis pigmentosa, deafness, ataxia, and psychosis might focus on chromosome 17q21, or the chromosome 3 and 6 loci of the several other forms of retinitis pigmentosa and deafness. Chromosome 3 contains the genes for RAR β , RBP1, and CRBP2. Chromosome 6p21 is the locus of RXR β , spinocerebellar ataxia 1 (SCA1), and one form of retinitis pigmentosa, slow retinal degeneration (RDS). Chromosome 12q23-q24.1 contains the locus for an aldehyde dehydrogenase, catabolizing retinal to RA [Mangelsdorf et al., 1994; McCaffery et al., 1992]. Such a search would supplement a continuing investigation of the Usher's Type 1 locus on chromosome 1q32 as a candidate in schizophrenia [Sharp et al., 1994].

Skin diseases, psychiatric abnormalities, and the retinoids. There are occasional reports of Darier's disease, a severe skin affliction, co-occurring in families with schizophrenia [Sidenberg et al., 1994; Thiers et al., 1968; Getzler and Flint, 1966]. A Darier's disease variant which maps to chromosome 12q23-q24.1, near the aldehyde dehydrogenase 2 locus, segregates with major affective psychosis, including schizoaffective disorder [Craddock et al., 1993]. Other skin diseases, with dyskeratotic clinical features overlapping those of Darier's disease map to chromosome 17q12-q24, near the RAR α gene [Rogaev et al., 1993; Torchard et al., 1994; Reis et al., 1994] and the 1q21 locus of CRABP2 [Volz et al., 1993]. Among them, ichthyosis vulgaris is reported to co-occur with psychosis [Donnet and Samuelian, 1988; Browning and Jones, 1988; Mochizuki et al., 1980; Arai and Matsushita, 1977; Zeligman and

Houston, 1971]. Some families with keratotic disorders co-segregate congenital malformations, and familial cancers [Torchar et al., 1994], which suggests evidence for contiguous gene syndromes [Rogaev et al., 1993; Chow et al., 1994]. Retinoid dysfunction could also account for such a variety of clinical manifestations. Hypovitaminosis A occurs together with Darier's disease and other forms of keratosis [Anderson and Klintworth, 1961] and the disease responds to treatment with synthetic retinoids [Peck and DiGiovanni, 1994; Thiers et al., 1968]. Hailey-Hailey disease, another skin disorder with clinical and histological features similar to Darier's disease, is found in association with psychiatric abnormalities [Korner et al., 1993]. A recent molecular genetic study indicates that the disease is not an allelic variant of Darier's disease [Welsh et al., 1994]. In addition Hailey-Hailey disease is worsened by treatment with retinoids, whereas hypovitaminosis A-associated Darier's disease and ichthyosis vulgaris are ameliorated by retinoid therapy [Peck and DiGiovanni, 1994; Prystowski, personal communication, 1994]. The genes causing these disorders may share retinoid regulatory elements which control their transcription. Retinoid dysregulation may be involved in the pleiotropic expression of the broad phenotype of skin disorder, congenital malformation, familial cancer and psychiatric abnormality [Goodman, 1994a].

Retinoid Toxicity and Schizophrenia

In mammals maternal administration of RA during pregnancy causes embryonic defects depending on the stage of exposure [Mendelsohn et al., 1992]. At the time of neurulation RA administration can lead to craniofacial abnormalities [Morriss and Thorogood, 1978; Sulik et al., 1988; Webster et al., 1986] and abnormal brain development [Drake et al., 1994]. Numerous studies document the occurrence of minor physical anomalies, particularly craniofacial anomalies, in schizophrenia [Green et al., 1989; McGillivray et al., 1990; Torrey et al., 1994; O'Callaghan, 1991; Lane et al., 1994]. The anomalies described in these studies involve the same areas as those that are shown to be highly sensitive to retinoid regulation. Human congenital malformations associated with vitamin A toxicity include hydrocephalus characterized by increase in ventricular size, microcephalus, abnormalities of the external ear, micrognathia, microphthalmia, cardiovascular abnormalities, facial dysmorphism, mandibular underdevelopment, and cerebellar and other midline structure brain malformations [Lammer, 1991; Hofman and Eichele, 1994; Morriss-Kay, 1993]. RA is involved in the induction and differentiation of the olfactory bulb of the developing mammalian forebrain, which leads to the subsequent formation of the neocortex, hippocampus, basal ganglia, and basal forebrain [LaMantia et al., 1993]. RA has been shown to cause the inhibition of forebrain development in chick embryos [Chen and Solurush, 1992]. This is thought to be due to perturbation of the normal functioning of neural crest-derived cells [Davis et al., 1990] or loss of neural crest-cell substratum adhesiveness, for altered neuronal cell migration has

resulted from administration of RA [Morriss, 1975; Thorogood et al., 1982; Maden and Holder, 1992]. Since the linguistic working memory is connected to mouth and orofacial regions of the brain, it has been suggested that dysmorphology of these regions may be related to thought disorder in schizophrenia, as a result of disrupted linguistic working memory [Goldman-Rakic, 1987]. As noted above, hyper- or hypo-vitaminosis A is associated with acute psychosis, which remits when vitamin A levels return to normal [Restak, 1972; Haupt, 1977; Ragavan et al., 1982; Olver, 1986; Gatti and Serri, 1991; Halter, 1991]. Chronic subtle abnormalities in availability of retinoids to the linguistic working memory areas of the brain, if possibly caused by abnormalities in the retinoid transport system, may not reasonably be expected to result in the more chronic type of thought disorder characterizing schizophrenia.

Craniofacial agenesis anomalies. Some of the many craniofacial disorders described in the literature may be caused by abnormal retinoid action on neural crest cells [Johnston and Bronsky, 1991]. Of particular interest are those craniofacial disorders characterized by midline malformations and agenesis of the corpus callosum, e.g., DiGeorge syndrome, holoprosencephaly, Treacher Collins syndrome, and velocardiofacial syndrome, since midline agenesis has been reported also in connection with schizophrenia [DeGrief et al., 1992; Bogerts, 1993; Swayze et al., 1990; Andreasen et al., 1994a]. Behavioral disorders, including schizophrenia, are found disproportionately among patients with these disorders [Nimgaonkar et al., 1993; Mitnick et al., 1994; Chow et al., 1994; Shprintzen et al., 1992]. Many of the callosal agenesis syndromes are characterized by anomalies of the heart, digits, and limbs, as well as ear, eye, and other craniofacial abnormalities. These are pathognomonic markers of retinoid excess or deficit [Lammer et al., 1985; Kasner et al., 1994]. At least one group has proposed RA dysregulation as the proximal cause of Treacher Collins syndrome [Sulik et al., 1987], and the disease phenocopy has been produced in rats exposed to excessive levels of RA [Wilkinson and Poswillo, 1991]. Although chromosome 5q11, including hexosaminidase B [McGillivray et al., 1990], is the locus most frequently associated with Treacher Collins syndrome [Dixon et al., 1991], at least one study has identified a chromosomal deletion at 3p23-p24, the locus of the RAR β gene, in a mild, but typical case of Treacher Collins syndrome [Arn et al., 1993; Hawks et al., 1993].

Retinoid Gene Deletion, Duplication, Breakpoint, or Translocation Causing Disease Phenotype

Chromosome 22 karyotypal anomalies. Velocardiofacial syndrome is associated with deletions of the DiGeorge locus at chromosome 22q11 [Scambler et al., 1992], and with schizophrenia [Chow et al., 1994; Shprintzen et al., 1992]. However, there are several reports of the phenotype that do not show the characteristic chromosome 22 deletion [Chow et al., 1994]. Mutations or deletions at the chromosome 22 area may be associated with schizophrenia [Coon et al., 1994a] at

though this suggestion has yet to be confirmed [Pulver et al., 1994; Polymeropoulos et al., 1994]. Evidence of possible retinoid control of genes at the chromosome 22q11 breakpoints associated with behavioral disorders is suggested by the presence of several breakpoint translocations from chromosome 9q34, the locus of the RXR α gene, to 22q11 [Genome Data Base, 1994]. There is one case report of a deletion of the 9q34 region associated with schizophrenia and mental retardation [Park et al., 1991]. Noonan's syndrome, which in some cases is characterized by psychosis [Propping and Friedl, 1988], mimics the DiGeorge phenotype, and co-occurs with deletions at the DiGeorge locus [Wilson et al., 1993]. This syndrome has recently been mapped to chromosome 12q22-qter [Jamieson et al., 1994], which contains the locus of one of the aldehyde dehydrogenases, the rate limiting enzymes in the conversion of retinal to RA.

Cerebral overgrowth anomalies. Operating in the opposite manner from the agenesis syndromes are the overgrowth syndromes. Cerebral gigantism (Sotos syndrome) is associated with behavioral disorders, including autism [Morrow et al., 1990], and social isolation [Rutter and Cole, 1991; Bale et al., 1985] and by deletions, translocations, or trisomy of chromosomes 3p21, 6p21, 12q15, and 15q22 [Schrandt-Stumpel et al., 1990; Tamaki et al., 1989; Maroum et al., 1994], loci of several of the retinoid genes [Goodman, 1995]. Maroum et al., 1994 suggest a specific locus for Sotos syndrome, the long arm of chromosome 15, and their karyotype findings pinpoint 15q22, the locus of CRABP1. Several authors note that the distinctive craniofacial anomalies and neuropsychological dysfunctions of the overgrowth syndromes are similar to those produced by retinoic acid syndrome [Johnston and Bronsky, 1991; Lammer and Armstrong, 1992].

CONCLUSION

Taken together this review theorizes that many of the pathologies found in association with schizophrenia may be either directly or indirectly influenced by genes of the retinoid cascade. The retinoid influence is suggested in terms of chromosomal contiguity of retinoid genes with disorders associated with schizophrenia, demonstrated or postulated retinoid regulation of putative schizophrenia candidate genes, demonstrated or suggestive evidence of retinoid involvement in neurodevelopmental pathologies known to occur with schizophrenia, and the occurrence of vitamin A excess or deficit with psychosis. Several of the disorders co-occurring with schizophrenia, e.g., Darier's disease [Thiers et al., 1968; Sidenberg et al., 1994] and retinitis pigmentosa [Sharp et al., 1994] are amenable to treatment with vitamin A derivatives [Thier et al., 1968; Berson et al., 1993; Peck and DiGiovanna, 1994]. HIV, which is often accompanied by psychosis, may respond to treatment with synthetic retinoid antagonists [Fanjul et al., 1994; Lee et al., 1994]. Retinoids are known to be directly involved in the etiology of some of these disorders [Saari, 1994; Turpin et al., 1992; Poli et al., 1992]. If the retinoid regulatory mechanisms suggested here are op-

erative in schizophrenia, this would lead to the possibility that schizophrenia, too, may be amenable to treatment with vitamin A-related compounds.

NOTE ADDED IN PROOF

Since this manuscript went to press, two different laboratories have demonstrated linkage of spinocerebellar ataxia with retinal degeneration to chromosome 3p12-p21.1 [Gouw et al., 1995; Benomar et al., 1995]. A susceptibility locus for schizophrenia on chromosome 6pter-6p22 has also been identified [Wang et al., 1995]. This locus includes the 6p23.05-p24.2 locus of olivopontocerebellar ataxia 1 (SCA1).

ACKNOWLEDGMENTS

I thank David Shepro, Victor Sapirstein, Seymour Levine, Kaare Norum, Rune Blomhoff, and Alexander Guidotti for their careful reading of and editorial suggestions for this manuscript. I am deeply grateful to the staff of the Health Sciences Library of the Nathan S. Kline Institute for Psychiatric Research. This work is supported by the New York State Office of Mental Health. The body of work on vitamin A of the late DeWitt S. Goodman provided the foundation for the development of my thinking.

REFERENCES

- Adams J, Lammer EJ (1993): Neurobehavioral teratology of isotretinoin [Review]. *Reprod Toxicol* 7:175-177.
- Adem A, Mattsson ME, Nordberg A, Pahlman S (1987): Muscarinic receptors in human SH-SY5Y neuroblastoma cell line: regulation by phorbol ester and retinoic acid-induced differentiation. *Brain Res* 430:235-242.
- Akbarian S, Bunney WE, Jr, Potkin SG, Wigal SB, Hagman JO, Sandman CA, Jones EG (1993): Altered distribution of nicotinamide-adenine dinucleotide phosphate-diaphorase cells in frontal lobe of schizophrenics implies disturbances of cortical development. *Arch Gen Psychiatry* 50:169-177.
- Anderson IF, Klintworth GK (1961): Hypovitaminosis-A in a family with tylosis and clindaoctyly. *Br Med J* 1:1298-1297.
- Andreassen NC, Arndt S, Swayze V, Cizadlo T, Flaum M, O'Leary D, Ehrhardt JC, Yuh WTC (1994a): Thalamic abnormalities in schizophrenia visualized through magnetic resonance image averaging. *Science* 266:294-298.
- Andreassen NC, Flaum M, O'Leary DS, Flaum M, Swayze V (1994b): Decreased frontal size in schizophrenia measured with volumetric magnetic resonance (MR) imaging. *Soc. Neurosci Abstr* 20:24.
- Arai S, Matsushita M (1977): Symptomatology studies of ichthyosis vulgaris with psycho-neurological symptoms: Report of 8 cases (including 2 autopsied cases) and their families (author's transl.) [Japanese] *Seishin Shinkeigaku Zasshi: Psychiatry et Neurologia Japonica* 79:519-537.
- Arato M, Bagdy G, Perenyi A (1992): Reduced serum dopamine-b-hydroxylase activity in paranoid schizophrenia. *Bio Psychiatry* 17: 853-854.
- Arn PH, Mankinen C, Jabs EW (1993): Mild mandibulofacial dysostosis in a child with a deletion of 3p. *Am J Med Genet* 46:534-536.
- Bale AE, Drum MA, Parry DM, Mulvihill JJ (1985): Familial Sotos syndrome (cerebral gigantism): Craniofacial and psychological characteristics. *Am J Med Genet* 20:613-624.
- Barr CL, Kennedy JL, Lichter JB, Van Tol HH, Wetterberg L, Livak KJ, Kidd KK (1993): Alleles at the dopamine D4 receptor locus do not contribute to the genetic susceptibility to schizophrenia in a large Swedish kindred. *Am J Med Genet* 49:213-22.
- Bauer K, Kornhuber J (1987): Blood-cerebrospinal fluid barrier in schizophrenic patients. *Eur Arch Psychiatry Neurol Sci* 236:257-259.

344 Goodman

- Bezkowska IW, Jenab S, Pickel VM, Inturrisi CE (1994): Effects of chronic retinoic acid (RA) on delta opioid and NMDAR1 gene expression in NG108-15 neuroblastoma hybrid cells. *Soc Neurosci Abstr* 20:746.
- Benomar A, Krols L, Stevanin G, Cancei G, LeGuern E, David G, Ouhabi H, Martin J-J, Durr A, Zaim A, Ravise N, Busque C, Penet C, Van Regenmortel N, Weissenbach J, Yahyouchi M, Chkikl I, Agid Y, Van Broeckhoven C, Brice A (1995): The gene for autosomal dominant cerebellar ataxia with pigmentary macular dystrophy maps to chromosome 3p12-p21.1. *Nature Genetics* 10:84-88.
- Berrard S, Faucon Biguet N, Houhou L, Lamouroux A, Mallet J (1993): Retinoic acid induces cholinergic differentiation of cultured newborn rat sympathetic neurons. *J Neurosci Res* 35:382-389.
- Berrettini WH, Ferraro TN, Goldin LR, Weeks DE, Detera-Wadleigh S, Nurnberger Jr, Gerstner E (1994): Chromosome 18 DNA markers and manic-depressive illness: Evidence for a susceptibility gene. *Proc Natl Acad Sci USA* 91:5918-5921.
- Berson EL, Rosner B, Sandberg MA, Hayes KC, Nicholson BW, Weigel-DiFranco C, Willett W (1993): A randomized trial of vitamin A and vitamin E supplementation for retinitis pigmentosa. *Arch Ophthalmol* 111:761-772.
- Bianer WS, Olson JA (1994): Retinol and retinoic acid metabolism. In Sporn MB, Roberts AB, Goodman DS (eds): "The Retinoids: Biology, Chemistry, and Medicine," 2nd Ed. New York: Raven Press, Ltd., pp 229-255.
- Blomhoff R, Green MH, Berg T, Norum KR (1990): Transport and storage of vitamin A. *Science* 250:399-404.
- Bloom FE (1993): Advancing a neurodevelopmental origin for schizophrenia. *Arch Gen Psychiatry* 50:224-227.
- Bogerts B (1993): Recent advances in neuropathology of schizophrenia. *Schizophr Bull* 19:431-45.
- Boylan JF, Gudas LJ (1991): Overexpression of the cellular retinoic acid binding protein-I (CRABP-I) results in a reduction in differentiation-specific gene expression in F9 teratocarcinoma cells. *J Cell Biol* 112:965-979.
- Braun JT, Franciosi RA, Mastri AR, Drake RM, O'Neil BL (1984): Isotretinoin dysmorphic syndrome. *Lancet* 1:506-507.
- Browning SM, Jones S (1988): Ichthyosis and delusions of lizard invasion. *Acta Psychiatr Scand* 78:766-767.
- Butler PD, Susser ES, Brown AS, Kaufmann CA, Gorman JM (1994): Prenatal nutritional deprivation as a risk factor in schizophrenia: Preclinical evidence. *Neuropsychopharmacology* 11:227-235.
- Camisa C, Eisenstat B, Ragaz A, Weissmann G (1982): The effects of retinoids on neutrophil functions in vitro. *J Am Acad Dermatol* 6:620-629.
- Carlson M, Carlson A (1990): Schizophrenia: A subcortical neurotransmitter imbalance syndrome. *Schizophr Bull* 16:425-432.
- Chen Y, Solurush M (1992): Comparison of Hensen's node and retinoic acid in secondary axis induction in early chick embryo. *Dev Dyn* 195:142-151.
- Chow EWC, Bassett AS, Weksberg R (1994): Velo-cardio-facial syndrome and psychotic disorders: Implications for psychiatric genetics. *Am J Med Genet (Neuropsychiatr Genet)* 54:107-112.
- Conrad AJ, Abebe T, Austin R, Forsythe S, Scheibel AB (1991): Hippocampal pyramidal cell disorder in schizophrenia as a bilateral phenomenon. *Arch Gen Psychiatry* 48:413-417.
- Conrad AJ, Scheibel AB (1987): Schizophrenia and the hippocampus: The embryological hypothesis extended. *Schizophr Bull* 13:577-587.
- Coon H, Holik J, Hoff M, Reimherr F, Wender P, Myles-Worsley M, Waldo M, Freedman R, Byerley W (1994b): Analysis of chromosome 22 markers in nine schizophrenia pedigrees. *Am J Med Genet (Neuropsychiatr Genet)* 54:72-79.
- Coon H, Jensen S, Holik J, Hoff M, Myles-Worsley M, Reimherr F, Wender P, Waldo M, Freedman R, Leppert M, Byerley W (1994a): Genomic scan for genes predisposing to schizophrenia. *Am J Med Genet (Neuropsychiatr Genet)* 54:69-71.
- Craddock N, Owen M, Burge S, Kurian B, Thomas P, McGuffin P (1994): Familial cosegregation of major affective disorder and Darier's disease (keratosis follicularis). *Br J Psychiatry* 164:355-358.
- Creech Kraft J, Nau H, Lammer E, Olney A (1989): Human embryo retinoid concentrations after maternal intake of isotretinoin. *N Engl J Med* 321:262.
- Crocq MA, Mant R, Asherson P, Williams J, Hode Y, Mayerova A, Collier D, Lannfelt L, Sokoloff P, Schwartz JC, et al. (1992): Association between schizophrenia and homozygosity at the dopamine D3 receptor gene. *J Med Genet* 29:358-360.
- Daniels J, Williams J, Mant R, Asherson P, McGuffin P, Owen MJ (1994): Repeat length variation in the dopamine D4 receptor gene shows no evidence of association with schizophrenia. *Am J Med Genet (Neuropsychiatr Genet)* 54:256-258.
- Davis WL, Crawford LA, Cooper OJ, Farmer GR, Thomas D, Freeman BL (1990): Generation of radical oxygen species by neural crest cells treated in vitro with isotretinoin and 4-oxo-isotretinoin. *J Craniofac Genet Dev Biol* 10:295-310.
- Deakin JF, Slater P, Simpson MD, Gilchrist AC, Skan WJ, Royston MC, Reynolds GP, Cross AJ (1989): Frontal cortical and left temporal glutamatergic dysfunction in schizophrenia. *J Neurochem* 52:1781-1786.
- Debonnel G (1993): Current hypotheses on sigma receptors and their physiological role: Possible implications in psychiatry. *J Psychiatry Neurosci* 18:157-172.
- Dedhar S, Robertson K, Gray V (1991): Induction of expression of the alpha v beta 3 integrin heterodimers during retinoic acid-induced neuronal differentiation of murine embryonal carcinoma cells. *J Biol Chem* 266:21846-21852.
- DeGrief G, Lantos G, Bogerts B, Ashtari M, Liebermann J (1992): Abnormalities of the septum pellucidum on MR scans in first episode schizophrenic patients. *AJNR* 13:835-840.
- Delisi LE, Boeco A, Rodan H, Hoff AL, Dorfman A, McClelland J, Kushner M, Van Eyl O, Oden N (1991): Familial thyroid disease and delayed language development in first admission patients with schizophrenia. *Psychiatry Res* 38:39-50.
- Delisi LE, Goldin LR, Hamovit JR, Maxwell ME, Kurtz D, Gershon ES (1986): A family study of the association of increased ventricular size with schizophrenia. *Arch Gen Psychiatry* 43:148-153.
- Deutch AY, Ongur D, Duman RS (1994): Neural systems subserving antipsychotic drug actions: Neuroanatomy and pharmacology of immediate-early gene induction. *Neuropsychopharmacology* 10:245S.
- Devor EJ, Waziri R (1993): A familial/genetic study of plasma serine and glycine concentrations. *Biol Psychiatry* 34:221-225.
- Dingle JT, Barrett AJ, Weston PD (1971): Cathepsin D: Characteristics of immunoinhibition and the confirmation of a role in cartilage breakdown. *Biochem J* 123:1-13.
- Dixon MJ, Read PP, Donnai D, Colley A, Dixon J, Williamson R (1991): The gene for Treacher Collins syndrome maps to the long arm of chromosome 5. *Am J Hum Genet* 49:17-22.
- Donnet A, Samuelian JC (1988): Congenital neuroichthyosis and psychiatric involvement: Apropos of a case. [Review] *Encephale* 14:427-492.
- Drake DP, Gerwe EA, Linney E, La Mantia A-S (1994): Role of retinoid signalling in abnormal forebrain differentiation in the developing mutant mouse Small Eye (Abstract) *Soc Neurosci Abstract* 20:254.
- Fananas L, Moral P, Panadero MA, Bertranpetit J (1992): Complement genetic markers in schizophrenia: C3, Bf and C6 polymorphisms. *Human Hered* 42:162-7.
- Fanjul A, Dawson MI, Hobbs PD, Jong L, Cameron JF, Harley E, Graupner G, Lu X-P, Pfahl M (1994): A new class of retinoids with selective inhibition of AP-1 inhibits proliferation. *Nature* 372:197-199.
- Farpoqui SM (1994): Induction of adenylate cyclase sensitive dopamine D2-receptors in retinoic acid induced differentiated human neuroblastoma SHSY-5Y cells. *Life Sci* 55:1887-1893.
- Fidge NH, Shiratori T, Ganguly J, Goodman DS (1968): Pathways of absorption of retinal and retinoic acid in the rat. *J Lipid Res* 9:103-109.
- Fujita K, Ito T, Maruta K, Teradaira R, Beppu H, Nakagami Y, Kato Y, Nagatsu T, Kato K (1978): Serum dopamine-beta-hydroxylase in schizophrenic patients. *J Neurochem* 30:317-325.
- Gatti S, Serri F (1991): Acute depression from isotretinoin [letter; comment]. *J Am Acad Dermatol* 25:132.
- Genome Data Base (1994): This information was derived from the CDB (TM) Human Genome Data Base at JHU in Baltimore on September 20, 1994 at 2:00 PM Eastern Time.

- Getzler NA, Flint A (1966): Keratosis follicularis: A study of one family. *Arch Dermatol* 93:545-549.
- Goldman-Rakic P (1987): Circuitry of primate prefrontal cortex in regulation of behavior by representational memory. In Plum F (ed): "Handbook of Physiology, The Nervous System, Higher Functions of the Brain." American Physiological Society Vol V, part 1, pp 373-417.
- Goodman AB (1994a): Retinoid dysregulation as a cause of schizophrenia. [Letter] *Am J Psychiatry* 151:452-453.
- Goodman AB (1994b): Elevated risks for amyotrophic lateral sclerosis and blood disorders in Ashkenazi schizophrenic pedigrees suggest new candidate genes in schizophrenia. *Am J Med Genet (Neuropsychiatr Genet)* 54:271-278.
- Goodman AB (1994c): Medical conditions in Ashkenazi schizophrenic pedigrees. *Schizophr Bull* 20:507-517.
- Goodman AB (1995): Disruption of genes in the retinoid cascade may explain the microscopic neuroblastoma in a fetus with a de novo unbalanced translocation (3;10)(q21,q26). [Letter] *Am J Med Genet* 56:123.
- Goodman DS (1984a): Plasma retinoid-binding protein. In Sporn MB, Roberts AB, Goodman DS (eds): "The Retinoids," Vol. 2. New York: Academic Press, pp 41-88.
- Goodman DS (1984b): Vitamin A and retinoids in health and disease. *N Engl J Med* 310:1023-1031.
- Goodman DS (1987): Retinoids and retinoid-binding proteins. In The Harvey Lectures, Series 81. New York: Alan R. Liss, pp 111-132.
- Goodman DS, Blaner WS (1984): Biosynthesis, absorption, and hepatic metabolism of retinol. In Sporn MB, Roberts AB, Goodman DS (eds): "The Retinoids," Vol. 2. Orlando: Academic Press, pp 2-39.
- Gow LG, Kaplan CD, Heines JH, Digre KB, Rutledge SL, Matilla A, Leppert M, Zoghbi HY, Ptacek LJ (1995): Retinal degeneration characterizes a spinocerebellar ataxia mapping to chromosome 3p. *Nature Genetics* 10:89-93.
- Green MF, Satz P, Christenson C (1994): Minor physical anomalies in schizophrenia patients, bipolar patients and their siblings. *Schizophr Bull* 20:433-440.
- Green MF, Satz P, Gaier DJ, Ganzell S, Kharabi F (1989): Minor physical anomalies in schizophrenia. *Schizophr Bull* 15:91-99.
- Gudas LJ, Sporn MB, Roberts AB (1994): Cellular biology and biochemistry of the retinoids. In Sporn MB, Roberts AB, Goodman DS (eds): "The Retinoids: Biology, Chemistry and Medicine," 2nd Ed. New York: Raven Press, pp 444-446.
- Gur RE, Mozley PH, Shtasel DL, Cannon TD, Gallacher T, Turetsky B, Grossman R, Gur RC (1994): Clinical subtypes of schizophrenia: differences in brain and CSF volume. *Am J Psychiatry* 151:343-350.
- Gurevich E, Kung MP, Kung H, Joyce JN (1994): Dopamine D3 receptors are elevated in schizophrenia and Alzheimer's (AD) cases [Abstract]. *Soc Neurosci Abstr* 20:1169.
- Haberfellner EM, Rittmannsberger H, Windgager E (1993): Psychotic manifestation of hypothyroidism: A case report. *Nervenarzt* 64:336-339.
- Hallgren B (1959): Retinitis pigmentosa combined with congenital deafness, with vestibulo-cerebellar ataxia and mental abnormality in a proportion of cases: A clinical and genetic-statistical study. *Acta Psychiatr Scand* 34:1.
- Halter U (1991): [A case from practice (224). Acute exogenous reaction type (delirium) following administration of Tigason] Der Fall aus der Praxis (224). Akuter exogener Reaktionstypus (Delirium) nach Einnahme von Tigason. *Schweizerische Rundschau für Medizin Praxis* 80:883-884.
- Herding PP, Daester G (1992): Retinoic acid activation and thyroid hormone repression of the human alcohol dehydrogenase gene ADH3. *J Biol Chem* 267:14145-14150.
- Harty M, Younkin D, Tang CM, Pleasure J, Shi QY, Williams M, Pleasure D (1994): Expression of non-NMDA glutamate receptor channel genes by clonal human neurons. *J Neurochem* 63:482-483.
- Hart CP, Compton JG, Langley SH, Hunihan L, LeClair KP, Zelent A, Roderick TH, Rudolph FH (1992): Genetic linkage analysis of the murine developmental mutant velvet coat (*Vc*) and the distal chromosome 16 developmental genes *Hox-3.1*, *Rar-g*, *Wnt-1*, and *Krt-2*. *J Exp Zool* 263:83-95.
- Haupt R (1977): Acute symptomatic psychosis in vitamin A intoxication (author's transl) [German] *Nervenarzt* 48:91-95.
- Hawks AP, Mankinen C, Jabs EW (1993): Mild mandibulofacial dysostosis in a child with a deletion of 3p. *Am J Med Genet* 46:534-536.
- Herbert J, Wilcox JN, Pham K-TC, Fremneau RT Jr, Zeviani M, Dwork A, Soprano DR, Makover A, Goodman DS, Zimmerman EA, Roberts JL, Schon EA (1986): Transferrin: A choroid plexus-specific transport protein in human brain. *Neurology* 36:900-911.
- Hoffman C, Etchele G (1984): Retinoids in development. In Sporn MB, Roberts AB, Goodman DS (eds): "The Retinoids: Biology, Chemistry and Medicine," 2nd Ed. New York: Raven Press, pp 387-441.
- Hsu LC, Chang W-C (1991): Cloning and characterization of a new functional human aldehyde dehydrogenase gene. *J Biol Chem* 266:12257-12265.
- Jacob F, Monod J (1961): On the regulation of gene activity. *Cold Spring Harbor Symp Quant Biol* 26:193-209.
- Jacob H, Beckmann H (1986): Prenatal developmental disturbances in the limbic allocortex in schizophrenics. *Neural Transmission* 65:303-326.
- Jamieson CR, van der Burgt I, Brady AF, van Reen M, Eisawi MM, Hol F, Jeffery S, Patton MA, Mariman E (1994): Mapping a gene for Noonan syndrome to the long arm of chromosome 12. *Nature Genet* 8:357-360.
- Javitt DC, Zukin SR (1991): Recent advances in the phenylidone model of schizophrenia. *Am J Psychiatry* 148:1301-1308.
- Johnston MC, Bronsky PT (1991): Animal models for human craniofacial malformations. [Review]. *J Craniofacial Genet Dev Biol* 11:277-291.
- Johnstone EC, Owens DG, Crow TJ, Colter N, Lawton CA, Jagoe R, Kreef L (1986): Hypothyroidism as a correlate of lateral ventricular enlargement in manic-depressive and neurotic illness. *Br J Psychiatry* 148:317-321.
- Kasrier P, Grondons JM, Mark M, Gansmuller A, LeMour M, Decimo D, Vonesch JL, Dille P, Chambon P (1994): Genetic analysis of RXR alpha developmental function: Convergence of RXR and RAR signaling pathways in heart and eye morphogenesis. *Cell* 75:987-1005.
- Keddie KM (1969): Hereditary ataxia presumed to be of the Menzel type complicated by paranoid psychosis, in a mother and two sons. *J Neurol Neurosurg Psychiatry* 32:82-87.
- Kerwin R, Burnett F (1989): Schizophrenia induced by restitution of thyroid function in a predisposed patient. [Letter]. *Lancet* 2:333.
- Keshavan MS, Pettegrew JW, Beckwith K, Bagwell W, Haas GL, Sweeney J, Schooler NR (1994): Gray matter abnormalities in first-episode schizophrenia [Abstract]. *Schizophr Res* 11:136.
- Kirsch DG, Kaufmann CA, Papadopoulos NM, Martin B, Weinberger DR (1985): Abnormal cerebrospinal fluid protein indices in schizophrenia. *Biol Psychiatry* 20:1039-1046.
- Korner J, Rietschel M, Nothen MM, Wilk CM, Bauer R, Propping P, Moller JH (1993): Familial cosegregation of affective disorder and Hailey-Hailey disease. *Br J Psychiatry* 163:109-110.
- Lafou-Cazal M, Pietri S, Culicasi M, Bockaert J (1993): NMDA-dependent superoxide production and neurotoxicity. *Nature* 364:535-537.
- LaMantia A-S, Colbert MC, Linney E (1993): Retinoic acid induction and regional differentiation prefigure olfactory pathway formation in the mammalian forebrain. *Neuron* 10:1035-1048.
- Lammer E (1991): Preliminary observations on isotretinoin-induced ear malformations and pattern formation of the external ear. *J Craniofac Genet Dev Biol* 11:292-295.
- Lammer EJ, Armstrong DL (1992): Isotretinoin-induced malformations of human hindbrain. In Morriss-Kay G (ed): "Retinoids in Normal Development and Teratogenesis." New York: Oxford Science Publications, pp 281-295.
- Lammer EJ, Chen DT, Hoar RM, Agnish ND, Benke PJ, Braun JT, Curry CJ, Fernhoff PM, Grix AW Jr, Lot IT, Richard JM, Sun SC (1985): Retinoic acid embryopathy. *N Engl J Med* 313:837-841.
- Landy D (1985): Fibloktoq (hysteria) and fruit nutrition: Possible implication of hypervitaminosis A. *Soc Sci Med* 21:173-185.
- Lane A, Murphy P, Cassidy B, Colgan R, Kinsella A, Sheppard N, Horgan R, Waddington JL, Larkin C, O'Callaghan E (1994): Disturbed prenatal development in schizophrenia as evidenced by minor physical anomalies. *Schizophr Res (Abstract)* 11:93.

346 Goodman

- Laurent C, Savoye C, Samolyk D, Meloni R, Mallet J, Campion D, Martinex M, D'Amato T, Bastard C, Dollfus S (1994): Homozygosity at the dopamine D3 receptor locus is not associated with schizophrenia [Letter]. *J Med Genet* 31:93-260.
- Lee M-O, Hobbs PD, Zhang X-K, Dawson MI, Pfahl M (1994): A synthetic retinoid antagonist inhibits the human immunodeficiency virus type 1 promoter. *Proc Natl Acad Sci USA* 91:5652-5656.
- Lieberman JA, Koreen AR (1993): Neurochemistry and neuroendocrinology of schizophrenia: A selective review. *Schizophr Bull* 19:371-429.
- Lipton SA, Rosenberg PA (1994): Excitatory amino acids as a final common pathway for neurological disorders. *N Engl J Med* 330:613-622.
- Maden M, Holder N (1992): Retinoic acid and development of the central nervous system [Review]. *Bioessays* 14:431-438.
- Mangelsdorf DJ, Umesono K, Evans RM (1994): The retinoid receptors. In Sporn MB, Roberts AB, Goodman DS (eds): "The Retinoids: Biology, Chemistry, and Medicine," 2nd Ed. New York: Raven Press, pp 319-349.
- Maroun C, Schmeier S, Hutcheon RG (1994): Child with Sotos phenotype and a 5:15 translocation. *Am J Med Genet* 50:291-293.
- McCaffery P, Drager UC (1994): High levels of a retinoic acid-generating dehydrogenase in the meso-telencephalic dopamine system. *Proc Natl Acad Sci USA* 91:7772-7776.
- McCaffery P, Lee M-O, Wagner MA, Sladek NE, Drager UC (1992): Asymmetrical retinoic acid synthesis in the dorsoventral axis of the retina. *Development* 115:371-382.
- McGillivray BC, Bassett AS, Langlois S, Pantzar T, Wood S (1990): Familial 5q11.2-q13.3 segmental duplication cosegregating with multiple anomalies, including schizophrenia. *Am J Med Genet* 35:10-13.
- Meltzer HY (1992): Treatment of the neuroleptic-nonresponsive schizophrenic patient [Review]. *Schizophr Bull* 18:414-542.
- Meltzer HY, Nasr SJ, Tong C (1980): Serum dopamine-b-hydroxylase activity in schizophrenia. *Biol Psychiatry* 15:781-788.
- Meltzer HY, Tong C, Luchins DJ (1984): Serum dopamine-b-hydroxylase activity and lateral ventricular size in affective disorders and schizophrenia. *Biol Psychiatry* 19:1395-1402.
- Mendelsohn C, Ruberte E, Chambon P (1992): Retinoid receptors in vertebrate limb development. *Dev Biol* 152:50-51.
- Mitnick RJ, Belle JA, Shprintzen RJ (1994): Brain anomalies in velocardio-facial syndrome. *Am J Med Genet (Neuropsychiatr Genet)* 54:100-106.
- Mochizuki H, Toba M, Itoi K (1980): A case of ichthyosis vulgaris associated with schizophrenia-like psychosis and spike-wave stupor. *Folia Psychiatrica Neurologica Japonica* 34:392-393.
- Morris GM (1975): Abnormal cell migration as a possible factor in the genesis of vitamin-A-induced craniofacial abnormalities. In Neubert D (ed): "New Approaches to the Evaluation of Abnormal Mammalian Embryonic Development." Berlin: Thieme Verlag, pp 678-67.
- Morris GM, Thorgood PV (1978): An approach to cranial neural crest cell migration and differentiation in mammalian embryos. In Johnson EH (ed): "Development in Mammals," Vol. 3. Amsterdam: Elsevier-North Holland, pp 363-441.
- Morris-Kay G (1993): Retinoic acid and craniofacial development. *Bioessays* 15:9-15.
- Morrow JD, Whitman BY, Accardo PJ (1990): Autistic disorder in Sotos syndrome: A case report. *Eur J Pediatr* 149:567-569.
- Murphy P, Davidson DR, Hill RE, Morris-Kay GM (1992): Retinoid-induced alterations of segmental organization and gene expression in the mouse hindbrain. In Morris-Kay G (ed.): "Retinoids in Normal Development and Teratogenesis." New York: Oxford University Press, pp 230-240.
- Napoli JL (1993): Biosynthesis and metabolism of retinoic acid: Roles of CRBP and CRABP in retinoic acid homeostasis. *J Nutr* 123:362-366.
- Nimgonkar VL, Scott JA, Brar JS, Ganguli R, Chakravarti A (1993): Co-occurrence of schizophrenia and Treacher Collins Syndrome. *Am J Med Genet (Neuropsychiatr Genet)* 48:156-158.
- Nopoulos PC, Flaum MA, Andreasen NC, Swayze VW (1994): Gray matter heterotopias in schizophrenia [Abstract]. *Schizophr Res* 11:136.
- Nylander P-O, Beckman L, Holmgren G, Steen L (1990): Association of C3 and C4a complement types with familial amyloidotic polyneuropathy. *Hum Hered* 40:272-277.
- O'Callaghan E, Larkin C, Kinsella A, Waddington JL (1991): Familial, obstetric and other clinical correlates of minor physical anomalies in schizophrenia. *Am J Psychiatry* 148:479-483.
- Olney JW, Farber NB (1994): Efficacy of clozapine compared with other antipsychotics in preventing NMDA-antagonist neurotoxicity [Review]. *J Clin Psychiatry* 55:43-46.
- Olver J (1986): Keratomalacia on a "healthy diet." *Br J Ophthalmol* 70:357-360.
- Ong DE, Newcomer ME, Chynil F (1994): Cellular retinoid-binding proteins. In Sporn MB, Roberts AB, Goodman DS (eds): "The Retinoids: Biology, Chemistry, and Medicine," 2nd Ed. New York: Raven Press, pp 283-317.
- Park JP, Moeschler JB, Berg SZ, Wurster-Hill DH (1991): Schizophrenia and mental retardation in an adult male with a de novo interstitial deletion 9(q23q34.1). *J Med Genet* 28:282-283.
- Peck G, DiGiovanna JJ (1994): Synthetic retinoids in dermatology. In Sporn MB, Roberts AB, Goodman DS (eds): "The Retinoids: Biology, Chemistry, and Medicine," 2nd Ed. New York: Raven Press, pp 631-658.
- Pedersen WA, Blusztajn JK (1994): Activation of retinoic acid receptor alpha (RARα) mediates the effects of all-trans and 9-cis retinoic acid on the cholinergic properties of a murine septal cell line. *Soc Neurosci Abstr* 20:80.
- Pigg M, Jagell S, Sillen A, Weissenbach J, Gustavson K-H, Wadelius C (1994): The Sjogren-Larsson syndrome gene is close to D17S805 as determined by linkage analysis and allelic association. *Nature Genet* 8:361-364.
- Poli G, Kinter AL, Justement JS, Bressler P, Kehrl JH, Fauci AS (1992): Retinoic acid mimics transforming growth factor beta in the regulation of human immunodeficiency virus expression in monocytic cells. *Proc Natl Acad Sci USA* 89:2689-2695.
- Polymeropoulos MH, Coon H, Byerley W, Gershon ES, Goldin L, Crow JT, Rubenstein J, Hoff M, Holik J, Smith AM, Shields G, Bass NJ, Poulter M, Lofthouse R, Vita A, Morganti C, Merril CR, De Lisi LE (1994): Search for a schizophrenia susceptibility locus on chromosome 22. *Am J Med Genet* 54:93-99.
- Propping P, Friedl W (1988): Genetic studies of biochemical, pathophysiological and pharmacological factors in schizophrenia. In Tsuang MT, Simpson JC (eds): "Handbook of Schizophrenia," Vol. 3: Nosology, Epidemiology and Genetics. New York: Elsevier Science Publishers B.V., pp 579-608.
- Pulver AE, Karayiorgou M, Lasseter VK, Wolyniec P, Kasch L, Antonarakis S, Housman D, Kazazian JH, Meyers D, Nestadt G, et al. (1994): Follow-up of a report of a potential linkage for schizophrenia on chromosome 22q12-q13.1. Part 2. *Am J Med Genet* 54:44-50.
- Ragavan VV, Smith JE, Bilezikian JP (1982): Vitamin A toxicity and hypercalcemia. *Am J Med Sci* 283:161-164.
- Reis A, Hennies HC, Langhein L, Digweed M, Mischke D, Drechsler M, Schrock E, Royer-Pokora B, Franke WW, Sperling K, et al. (1994): Keratin 9 gene mutations in epidermolysis palmaris keratoderma (EPPK). *Nature Genet* 6:174-179.
- Remvig J (1969): Deaf-mutes with mental illness. *Acta Psychiatr Scand Suppl* 210:65-110.
- Restak RM (1972): Pseudotumor cerebri, psychosis, and hypervitaminosis A. *J Nerv Ment Dis* 155:72-75.
- Roca RP, Blackman MR, Ackerley MB, Harman SM, Greggerman RI (1990): Thyroid hormone elevations during acute psychiatric illness: Relationship to severity and distinction from hyperthyroidism. *Endocr Res* 16:415-447.
- Rogaev EI, Rogaeva EA, Gintor EK, Korovaitseva GI, Farrer LA, Shilensky A, Pritkov AN, Mordovtsev VN, St. George-Hysing PH (1993): Identification of the genetic locus for keratosis palmaris et plantaris on chromosome 17 near the RARA and keratin type I genes. *Nature Genet* 5:158-162.
- Rosa FW (1983): Teratogenicity of isotretinoin. *Lancet* 2:513.
- Ross SA, Ahrens RA, De Luca LM (1994): Retinoic acid enhances adhesiveness, laminin and integrin beta 1 synthesis, and retinoic acid receptor expression in F9 teratocarcinoma cells. *J Cell Physiol* 159:263-280.

- Ruberte E, Frierich V, Chambon P, Morriss-Kay G (1993): Retinoic acid receptors and cellular retinoid binding proteins. III. Their differential transcript distribution during mouse nervous system development. *Development* 118:237-252.
- Ruberte E, Frierich V, Morriss-Kay G, Chambon P (1992): Differential distribution of CRABPI and CRABPII transcripts during mouse embryogenesis. *Development* 115:973-987.
- Rudduck C, Beckman L, Franzen G, Lindstrom L (1985): C9 and C6 complement types in schizophrenia. *Hum Hered* 35:255-258.
- Rutter, SC, Cole TRP (1991): Psychological characteristics of Sotos syndrome. *Dev Med Child Neurol* 33:898-902.
- Saari JC (1994): Retinoids in photosensitive systems. In Sporn MB, Roberts AB, Goodman DS (eds): "The Retinoids: Biology, Chemistry, and Medicine," 2nd Ed. New York: Raven Press, pp 361-385.
- Saraiva MJM (1995): Transthyretin mutations in health and disease. *Human Mutation* 5:191-196.
- Scambler PJ, Kelly D, Lindsay E, Williamson R, Goldberg R, Shprintzen R, Wilson DJ, Goodship JA, Cross IE, Burn J (1992): Velo-cardio-facial syndrome associated with chromosome 22 deletions encompassing the DiGeorge locus. *Lancet* 339:1138-1139.
- Schmauss C, Haroutunian V, Davis KL, Davidson M (1993): Selective loss of dopamine D3-type receptor mRNA expression in parietal and motor cortices of patients with chronic schizophrenia. *Proc Natl Acad Sci USA* 90:8942-8946.
- Schrander-Stumpel CT, Fryns JP, Hamers GG (1990): Sotos syndrome and de novo balanced autosomal translocation (4;5) (p21;p11). *Clin Genet* 37:226-229.
- Seeman P, Guan HC, Van Tol HH (1993): Dopamine D4 receptors elevated in schizophrenia. *Nature* 365:441-445.
- Selmanowitz V, Porter MJ (1967): The Sjogren-Larson syndrome. *Am J Med* 42:412-422.
- Shankar KR, Chung CM, Jaskoll T, Melnick M (1994): Effect of in ovo retinoic acid exposure on forebrain neural crest: in vitro analysis reveals up-regulation of N-CAM and loss of mesenchymal phenotype. *Dev Dynamics* 200:89-102.
- Shapiro RM (1993): Regional neuropathology in schizophrenia: Where are we? Where are we going? *Schizophr Res* 10:187-239.
- Sharp CW, Muir WJ, Blackwood DHE, St. Clair DM (1994): A Scottish pedigree with schizophrenia, retinitis pigmentosa and deafness: An association with Usher Syndrome? *Schizophr Res* 11:146.
- Shih TW, Hill DL (1991): Conversion of retinol to retinal by rat liver microsomes. *Drug Metab Dispos* 19:332-335.
- Shprintzen RJ, Goldberg RB, Golding-Kushner KJ (1992): Letter to the editor: Late-onset psychosis in the velo-cardio-facial syndrome. *Am J Med Genet* 42:141-143.
- Sidenberg DG, Berg D, Bassett AS, King N, Petronis A, Kamble AB, Kennedy JL (1994): Genetic linkage evaluation of twenty-four loci in an eastern Canadian family segregating Darier's disease (keratosis follicularis). *J Am Acad Dermatol* 31:27-30.
- Simpson MD, Slater P, Royuston MC, Deakin JF (1992): Regionally selective deficits in uptake sites for glutamate and gamma-aminobutyric acid in the basal ganglia in schizophrenia. *Psychiatr Res* 42:273-282.
- Smith FR, Goodman DS (1976): Vitamin A transport in human vitamin A toxicity. *N Engl J Med* 294:805-808.
- Smith JE, Milch PO, Muto Y, Goodman DS (1973): The plasma transport and metabolism of retinoic acid in the rat. *Biochem J* 132: 321-327.
- Smith TJ, Davis FR, Desiel MR, Davis PJ, Ramsden DB, Schenel M (1994): Retinoic acid inhibition of thyroxine binding to human transthyretin. *Biochim Biophys Acta* 1199:75-80.
- Soprano DR, Blauer WS (1994): Plasma retinol-binding protein. In Sporn MB, Roberts AB, Goodman DS (eds): "The Retinoids: Biology, Chemistry, and Medicine," 2nd Ed. New York: Raven Press, pp 257-281.
- Spurney CF, Murray AM, Hyde TM, Herman MM, Kleinman JE (1994): Differential distribution of M1, M2, and M3 muscarinic receptors in selected brain regions from post-mortem schizophrenic patients compared to normal controls [Abstract]. *Soc Neurosci Abstr* 20:622.
- Suddath RL, Christison GW, Torrey EF, Casanova MF, Weinberger DR (1990): Anatomical abnormalities in the brains of monozygotic twins discordant for schizophrenia. *N Engl J Med* 322:789-793.
- Sulik KK, Cook CS, Webster WS (1988): Teratogens and craniofacial malformations: Relationship to cell death. *Development* 103:213-232.
- Sulik KK, Johnston MC, Smiley SJ, Speight HS, Jarvis BE (1987): Mandibulofacial dysostosis (Treacher Collins syndrome): A new proposal for its pathogenesis. *Am J Med Genet* 27:359-372.
- Sumiyoshi T, Stockmeier CA, Overholser JC, Friedman L, Meltzer HY (1994): Dopamine D4 receptors in postmortem caudate nucleus of subjects with schizophrenia. *Soc Neurosci Abstr* 20:912.
- Swayze VW, Andreasen NC, Ehrhardt JC, Yuh WTC, Alliger RJ, Cohen GA (1990): Developmental abnormalities of the corpus callosum in schizophrenia. *Arch Neurol* 47:805-808.
- Tamaki K, Horie K, Go T, Okuno T, Mikawa H, Hua ZY, Abe T (1980): Sotos syndrome with a balanced reciprocal translocation t(2;12) (q33.3;q15). *Ann Genet* 32:244-246.
- Thiers H, Moulin G, Borneau J, Latache M (1968): Keratodermie palmoplantaire, mélanisation exclusive d'une maladie de Darier. *Lyon Médical* 131:1719-1720.
- Thorogood PV, Smith L, Nicol A, McGinty R, Garrod D (1982): Effects of vitamin A on the behavior of migratory neural crest cells in vitro. *J Cell Sci* 57:33-350.
- Torchard D, Blanchet-Bardon C, Serova O, Langbein L, Navro S, Janin N, Goguel AF, Bernheim A, Franke WW, Lenoir GM, et al. (1994): Epidermolytic palmoplantar keratoderma cosegregates with a keratin 9 mutation in a pedigree with breast and ovarian cancer. *Nature Genet* 6:106-110.
- Torrey EF, Taylor EH, Bracha HS, Bowler AE, McNeil TP, Rawlings RF, Quinn PO, Bigelow LB, Rieckler K, Sjostrom K, Higgins ES, Gottesman II (1994): Prenatal origin of schizophrenia in a subgroup of discordant monozygotic twins. *Schizophr Bull* 20: 423-432.
- Turpin JA, Vargo M, Meltzer MA (1992): Enhanced HIV-1 replication in retinoid-treated monocytes. Retinoid effects mediated through mechanisms related to cell differentiation and to a direct transcriptional action on viral gene expression. *J Immunol* 148: 2539-2556.
- Ulas J, Cotman CW (1993): Excitatory amino acid receptors in schizophrenia. *Schizophr Bull* 350:105-117.
- Vaessen MJ, Meijers JH, Bootsma D, Van Kessel AG (1990): The cellular retinoic-acid-binding protein is expressed in tissues associated with retinoic-acid-induced malformations. *Development* 110:371-378.
- van Horn JD, McManus IC (1992): Ventricular enlargement in schizophrenia: A meta-analysis of studies of the ventricle: brain ratio (VBR). *Br J Psychiatry* 160:687-697.
- Virgo L, de Belleruche J, Barnes T, Mortimer A, Hirsch S (1994): Alterations in the expression of nitric oxide synthase in schizophrenia. *Schizophr Res* 11:122.
- Virgo L, de Belleruche J, Rossi M, Steiner TJ (1992): Characterization of the distribution of choline acetyltransferase messenger RNA in human spinal cord and its depletion in motor neuron disease. *J Neurol Sci* 112:125-132.
- Vogel F, Motulsky AG (1986): Gene action. In Vogel F, Motulsky AG (eds): "Human Genetics: Problems and Approaches." New York: Springer-Verlag, pp 228-333.
- Volz A, Korge BP, Compton JC, Ziegler A, Steinert PM, Mischke D (1993): Physical mapping of a functional cluster of epidermal differentiation genes on chromosome 1q21. *Genomics* 18:99-109.
- Wang S, Sun C, Walczak CA, Ziegler JS, Kippis BR, Goldin LR, Diehl SR (1995): Evidence for a susceptibility locus for schizophrenia on chromosome 6pter-p22. *Nature Genetics* 10:41-46.
- Waziri R, Barush S, Hegwood T, Sherman A (1990): Abnormal serine hydroxymethyltransferase activity in the temporal lobes of schizophrenia. *Neurosci Lett* 120:237-240.
- Webster WS, Johnston MC, Lammer EJ, Sulik KK (1986): Isotretinoin embryopathy and the cranial neural crest: An in vivo and in vitro study. *J Craniofac Genet Dev Biol* 6:211-222.
- Weish EA, Ikeda S, Peluso AM, Bonifas JM, Bare JW, Woodley DT, Epstein BY Jr (1994): Hailey-Hailey disease is not allelic to Darier's disease. *J Invest Dermatol* 102:992-993.
- Weiss M, Meshulam B, Witsenbeek H (1981): The possible relationship between Laurence-Moon-Biedl-Bardet syndrome and a schizophrenic-like psychosis. *J Nerv Ment Dis* 169:359-360.

348 Goodman

- Wilhelmsen KC, Lynch T, Pavlou E, Higgins M, Nygaard TG (1994): Localization of disinhibition-dementia-Parkinsonism-amyotrophy complex to 17q21-22. *Am J Hum Genet* 55:1159-1165.
- Wilkinson WQS, Poswillo DE (1991): Asymmetry in mandibulofacial dysostosis. *J Craniofac Genet Dev Biol* 11:41-47.
- Williamson PC (1992): Schizophrenia as a brain disease. *Arch Neurol* 50:1096-1097.
- Wilson DJ et al. (1993): Noonan's and DiGeorge syndromes with monosomy 22q11. *Arch Dis Child* 68:187-189.
- Wuarin L, Sidell N, de Vellis J (1991): Differential susceptibilities of spinal cord neurons to retinoic acid-induced survival and differentiation. *Dev Biol* 144:429-435.
- Younkin DP, Tang CM, Hardy M, Reddy UR, Shi QY, Pleasure SJ, Lee VM, Pleasure D (1993): Inducible expression of neuronal glutamate receptor channels in the NT2 human cell line. *Proc Natl Acad Sci USA* 90:2174-2178.
- Zeligman I, Houston FM (1971): Ichthyosis hystrix. *Birth Defects* 7: 246.
- Zetterstrom RH, Tomar A, Eklund-Larsson M, Nennesmo I, Eriksson U, Olson L (1994): Localization of retinoid-binding proteins and retinoid receptors suggests a function for retinoic acid in developing and adult dopamine-innervated brain areas. *Soc Neurosci Abstr* 2092:1688.
- Zimarkin SM (1991): Histochemical study of aldehyde dehydrogenase in the rat CNS. *J Neurochem* 56:1-11.

Retinoic Acid Induces Cholinergic Differentiation of Cultured Newborn Rat Sympathetic Neurons

S. Berrard, N. Faucon Biguet, L. Houhou, A. Lamouroux, and J. Mallet

Laboratoire de Génétique Moléculaire de la Neurotransmission et des Processus Neurodégénératifs, Centre National de la Recherche Scientifique, Gif sur Yvette, France

Many studies provide evidence that retinoic acid (RA), an endogenous derivative of vitamin A, plays a role in the development of the nervous system. We now report that RA controls the neurotransmitter phenotype of post-mitotic rat sympathetic neurons in cell culture. RA added to the culture medium increased the specific activity of choline acetyltransferase (ChAT) and the level of acetylcholine (ACh). Concomitantly, RA reduced the specific activities of two catecholamine synthetic enzymes, tyrosine hydroxylase (TH) and dopamine β -hydroxylase (DBH) and the level of norepinephrine (NE). After a 2 week treatment with 5 μ M RA, ChAT was increased by 5–10 fold, whereas TH and DBH were decreased by 10–15 fold and 2–3 fold, respectively, as compared to sympathetic neurons grown in the absence of RA. The modulation of the activity of the three enzymes was dose-dependent and followed a similar time course. The decrease of TH expression was demonstrated to be due to a decreased number of TH molecules. © 1993 Wiley-Liss, Inc.

Key words: neurotransmitter phenotypic plasticity, superior cervical ganglia, choline acetyltransferase, tyrosine hydroxylase, dopamine β -hydroxylase

INTRODUCTION

Sympathetic neurons display considerable plasticity in the determination of their neurotransmitter phenotype. The cellular environment has been shown to be important for inducing the *de novo* expression and modulating existing levels of neurotransmitters both *in vivo* and *in vitro*. *In vivo*, a noradrenergic to cholinergic switch has been observed in the normal postnatal development of sweat gland sympathetic innervation and has been shown to be specified by the target tissue (Landis and Keefe, 1983; Leblanc and Landis, 1986; Landis et al., 1988; Schotzinger and Landis, 1988, 1990). Studies performed on cultured sympathetic neurons have led to the identification of several factors that mediate the ef-

fects of target and/or non-neuronal cells on transmitter expression, and so regulate phenotypic decisions. Both soluble and membrane associated proteins are able to convert catecholaminergic sympathetic neurons into cholinergic cells. Examples of such proteins are a membrane-associated neurotransmitter stimulating factor (MANS) (Wong and Kessler, 1987; Rao et al., 1990), ciliary neurotrophic factor (CNTF) (Saadat et al., 1989), a trophic factor for ciliary neurons, and a cholinergic differentiation factor (CDF) secreted by cultured cardiac and skeletal muscle cells (Patterson, 1978). This last factor has been purified from cardiac cell-conditioned medium (Fukada, 1985), cloned (Yamamori et al., 1989) and found to be identical to leukemia inhibitory factor (LIF), a cytokine well known to influence proliferation and/or differentiation of many cell types from the earliest embryo to the adult (Gough and Williams, 1989). Enzyme regulated by CDF/LIF include choline acetyltransferase (ChAT), the biosynthetic enzyme of acetylcholine, and catecholamine synthetic enzymes such as tyrosine hydroxylase (TH), dopa decarboxylase, and dopamine β -hydroxylase (DBH) (Patterson and Chun, 1977; Swerts et al., 1983; Wolinsky and Patterson, 1983). CDF/LIF also modulates the levels of mRNA encoding both ChAT and TH (Brice et al., 1989; Nava et al., 1991), which suggests that it could regulate the expression of both ChAT and TH genes.

Another regulator of growth and differentiation in mammalian cells is retinoic acid (RA), a natural derivative of vitamin A (Strickland and Mahdavi, 1978; Hausler et al., 1983; Breitman et al., 1980). Moreover, RA is thought to be a natural morphogen involved in directing pattern formation during vertebrate development. In

Received October 22, 1992; revised January 11, 1993; accepted January 29, 1993.

Address reprint requests to Dr. J. Mallet, Laboratoire de Génétique Moléculaire de la Neurotransmission et des Processus Neurodégénératifs, Centre National de la Recherche Scientifique, 1 avenue de la Terrasse, 91198 Gif sur Yvette Cedex, France.

particular, RA specifies the anteroposterior axis during chick limb development (Eichele, 1989) and regulates anteroposterior differentiation within the central nervous system (Durstion et al., 1989; Wagner et al., 1990). The differentiation inducing action of RA is mediated via cytosolic cellular RA binding proteins (CRABPs), which may modulate the accessibility of RA to the nucleus (Maden et al., 1988), and nuclear RA receptors (RARs), which function as RA-dependent transcription factors and regulate gene expression (for review, see Chambon et al., 1991). The presence of CRABPs and RARs in nervous tissues supports a role for RA in regulating neural development (Perez-Castro et al., 1989; Dollé et al., 1989; Zelent et al., 1989; Giguere et al., 1987, 1990).

In the present study, we have investigated whether RA plays a role in the determination of the neurotransmitter phenotype of cultured sympathetic neurons. In particular, we have analyzed the effect of RA on the activity of three neurotransmitter synthetic enzymes (ChAT, TH, and DBH) and on the level of the neurotransmitters acetylcholine (ACh) and norepinephrine (NE) in these neurons. Our results demonstrate that RA induces the expression of a cholinergic phenotype in sympathetic neurons.

MATERIALS AND METHODS

Cell Cultures

Superior cervical ganglia (SCG) were removed from postnatal day 2 or 3 rats (Wistar) and dissociated into single cells by trituration with a reduced bore glass pipette in the presence of 3 mg/ml dispase (Boehringer Mannheim, Indianapolis, IN). Cells were plated at a density of 2 ganglia per well onto 16 mm plastic culture dishes precoated with rat-tail collagen. Cultures were grown in 0.5 ml bicarbonate buffered Leibovitz's L-15 medium (Gibco, Grand Island, NY) supplemented with several additives including 70 ng/ml nerve growth factor (NGF; obtained from Dr. W. Mobley, University of California San Francisco) and 5% (v/v) adult rat serum (Hawrot and Patterson, 1979; Swerts et al., 1983). Cytosine arabinofuranoside (10 μ M, Sigma Chemical Co., St. Louis, MO) was added during the first week of culture to prevent the proliferation of ganglionic non-neuronal cells. Culture medium was renewed every 2–3 days.

Twenty-four hours after plating, cultures were maintained in the same medium in the presence of either no additive, ethanol, RA, or CDF/LIF. All-trans RA (Sigma) was dissolved in ethanol by sonication and diluted into the culture medium such that the volume of ethanol did not exceed 0.1%. Control cultures always contained the same percentage of ethanol, which has no significant effect on the enzyme activities (not shown).

Murine recombinant CDF/LIF (kindly provided by Dr. Austin Smith, University of Edinburgh) was added from a culture supernatant conditioned by exposure to transfected Cos cells that express and secrete this factor (Smith, 1991). CDF/LIF was used at a final concentration of 1,000 U/ml, where 1 unit represents the amount required for minimal inhibition of embryonic stem cell differentiation and corresponds to approximately 0.1 ng of CDF/LIF.

At times indicated, neuron cultures were washed twice with PBS to remove serum proteins, harvested, collected by centrifugation, and stored frozen at -80°C until use.

Enzymatic Assays

Neuronal pellets were homogenized by vortexing in 120 μ l of 0.2% (v/v) Triton X-100, 0.2 M NaCl. Undissolved material was pelleted by centrifugation for 2 min at 10,000g. ChAT activity was measured according to Fonnum (1975) with 5.2 μ M (^3H)AcCoA (3.6 Ci/mmol) without isotopic dilution to increase the sensitivity of the assay (Raynaud et al., 1987). As this cofactor concentration was below the enzyme K_m , ChAT activity was expressed in cpm rather than in pmoles of ACh. TH activity was determined as described by Waymire et al. (1971). DBH activity was measured according to Vayer et al. (1990), except that the cell extracts were not adsorbed on concavalin A sepharose. Proteins were measured by the method Bradford (1976) using bovine serum albumine as standard. Each enzymatic assay was done in duplicate.

Neurotransmitter Assays

ACh assay. ACh was extracted from SCG cultured cells in 5% (v/v) trichloroacetic acid, which was then removed by several ether washings until a pH of 4 was reached. ACh was assayed by the choline oxydase chemiluminescent procedure described by Israël and Lesbats (1982). For each determination, a standard was performed with purified ACh.

NE assay. NE was extracted from SCG cultured cells in 100 μ l of 0.1 M perchloric acid in the presence of 0.1% EDTA and 0.1% $\text{Na}_2\text{S}_2\text{O}_5$. The supernatant was prepurified on an alumina column after addition of 82 pmoles of epinephrine (used as an internal standard) and quantified by an h.p.l.c. analysis. Chromatography was performed on a nucleosil 5C18 column (Spectra-Physics, San Jose, CA, particle size 5 μ m, 250 \times 4.6 mm) thermostated at 30°C the mobile phase was 0.1 M KH_2PO_4 , 0.2 mM sodium octylsulfonate, 5% methanol, pH 4.5 at a flow rate of 1.2 ml/min. Detection was performed with a spectrofluorometer (excitation 280 nm, emission 330 nm).

384 Berrard et al.

Determination of TH Protein Amount

TH protein was quantified by Western blot analysis as described by Labatut et al. (1988) with some modifications. Rabbit anti-TH serum of J. Boy Institut and ^{125}I radiolabelled protein A (30 mCi/mg; Amersham, Arlington Heights, IL) were used. Sixteen micrograms of protein of SCG homogenate were separated on 10% polyacrylamide gel, electrotransferred on Hybond C Extra (Amersham), and exposed after treatment against β -max Hyperfilm (Amersham). Autoradiography was quantified with a Biocom densitometer.

RESULTS

RA Regulates Catecholaminergic and Cholinergic Enzyme Activities

The effect of RA was measured on ChAT, TH, and DBH activities, which are expressed as specific activities, normalized to soluble protein content.

RA addition caused an increase of ChAT specific activity and a parallel inhibition of TH and, to a lesser extent, DBH specific activities. In our different experiments, a 2 week treatment with 5 μM RA stimulated ChAT specific activity up to 5–10 fold while it decreased by 10–15 fold and 2–3 fold TH and DBH specific activities, respectively. RA decreased also the amount of protein per culture dish in a dose-dependent fashion (not shown). Protein content was reduced by $53 \pm 7.1\%$ after 2 weeks in culture in the presence of 5 μM RA in 7 independent experiments.

The modulation of the activities of these enzymes was dependent on RA concentration (Fig. 1). After 15 days of culture, the increase in ChAT activity was significant at a RA concentration of 10^{-9} M and reached maximal value at 10^{-6} M. In contrast, TH and DBH decreases required higher RA concentrations: 10^{-7} M was necessary to detect a significant change in the level of these enzyme activities. The maximal effect of RA was obtained at a concentration of 5×10^{-6} M for both enzymes.

The RA effect showed a slightly slower time course on catecholaminergic enzymes than on ChAT activity (Fig. 2). A significant increase in ChAT level was first observed after a 3 day exposure to 5 μM RA whereas a detectable decrease in TH and DBH activities was measured after 5 days.

In the absence of RA, TH, and DBH activities increased 20 and 11 fold, respectively, between day 0 (where RA was added to the culture medium) and day 13, whereas in the presence of 5 μM RA, TH and DBH were increased only by 1.4 and 3.3 fold, respectively. In this experiment, specific activities of RA treated cultures were decreased 15 fold for TH and 3.4 fold for DBH at

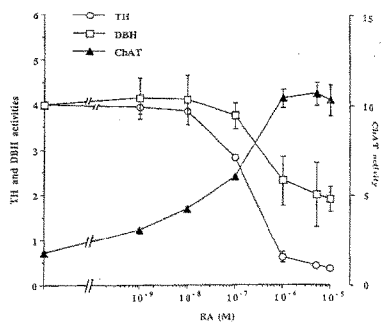


Fig. 1. Dose-response curve of RA effects on ChAT, TH, and DBH specific activities. Neurons were cultured for 15 days in the presence of indicated concentrations of RA or without RA, and processed for the biochemical analysis of ChAT, TH, and DBH activities. ChAT activity is expressed as cpm/min/mg protein (prot) $\times 10^{-3}$, TH activity as pmol/min/mg prot $\times 10^{-3}$ and, in order to standardize the curves, DBH activity as pmol/min/mg prot $\times 0.37$. Points represent the mean \pm SEM of three cultures, each being determined in duplicate.

day 13 as compared to untreated cultures. Note that the inhibitory action of RA was more efficient on TH than on DBH activity.

In contrast, between day 0 and day 13, ChAT activity increased 280 fold in the presence of RA and was 5 fold higher than in untreated cultures at day 13.

In order to determine whether the effect of RA was due to a modulation of the number of enzyme molecules, a Western blot experiment was carried out with TH and ChAT antibodies (no rat DBH antibody is yet available to us). Equal amounts of proteins from neurons grown for 14 days without RA or with 0.1 μM or 5 μM RA were analyzed. As shown in Figure 3, the signal corresponding to TH molecules decreased in the presence of RA in a dose-dependent fashion. Densitometric scanning revealed that the number of TH molecules was reduced 2 times by 0.1 μM RA and 12 times by 5 μM RA. In this experiment, TH activity was decreased by the same order of magnitude. This result suggests that RA regulates TH synthesis or TH stability. ChAT molecules could not be detected when the same blot was treated with a ChAT antibody, ChAT being probably of a too low abundance to be detected by this method.

Effect of RA on ACh and NE Levels

In order to test if RA influences the type of neurotransmitter synthesized by cultured SCG neurons, the

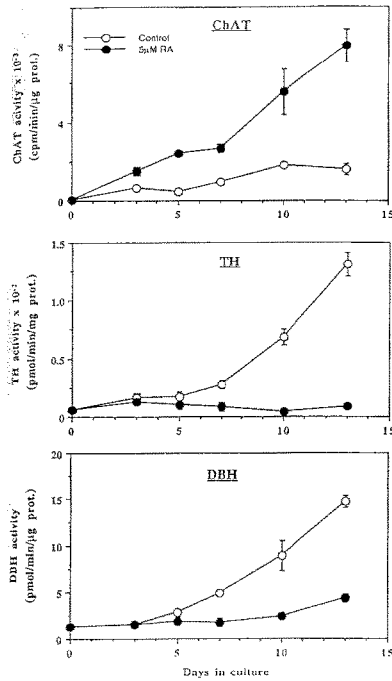


Fig. 2. Time course of the effect of RA on ChAT, TH, and DBH specific activities. SCG cells were cultured either with 5 μ M RA or with 0.1% ethanol (control) that were added 24 hr after plating (day 0). Neurons were harvested at the indicated time points and enzymatic activities were measured. Data points represent means \pm SEM of triplicate cultures, each determined in duplicate.

amounts of ACh and NE were measured in neurons grown for 14 days in control medium and in the presence of 5 μ M RA. As CDF/LIF purified from CM has already been shown to depress catecholamine production and to increase ACh synthesis (Patterson and Chun, 1977; Fukada, 1985), neurotransmitters were assayed in neurons grown in the presence of this factor as a positive control.

As shown on Table I, 5 μ M RA caused a 2.7 fold

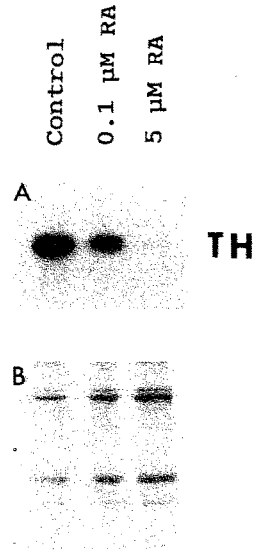

Fig. 3. Western blot analysis. A: 16 μ g proteins of homogenates of SCG neurons grown for 14 days with 0.1% ethanol (control), 0.1 μ M RA, or 5 μ M RA have been separated on a 10% polyacrylamide and gel analyzed by Western blotting. After 4 days exposure against β -Max hyperfilm, the intensity of the signal was quantified. B: After electroblotting, the gel was stained with Coomassie blue and the bands of total proteins visualized are used as control of the amount of material analyzed.

induction of ACh level and at the same time a 6.9 fold decrease of the amount of NE when compared to control cultures. As a result, the ACh/NE ratio, which constitutes a sensitive measure of cholinergic phenotype acquisition, increased considerably (20 fold in this experiment). In this condition, neurons contained a 6.4 fold higher molar amount of ACh than of NE.

On the other hand, in our experimental conditions, CDF/LIF was 2.4 fold more effective than RA to induce ACh, and 3.7 fold less effective to depress NE. Neurons treated with this factor contained 4 fold more ACh than NE, and the ACh/NE ratio was increased by 12.4 fold compared to control.

Together, all these results suggest that RA has a

TABLE I. Effect of RA and CDF/LIF on the Levels of ACh and NE in Cultured SCG Neurons*

Growth conditions	Neurotransmitters (pmol/ μ g proteins)		ACh/NE ratio	Fold induction
	ACh	NE		
Control	4.13 \pm 0.34	12.15 \pm 0.65	0.33	1
RA (5 μ M)	11.7 \pm 1.97	1.75 \pm 0.05	6.38	20
CDF/LIF (\approx 100 ng/ml)	26.47 \pm 4.9	6.50 \pm 0.2	4.08	12.3

*SCG cells were cultured for 14 days in control medium (0.1% ethanol) or in the presence of 5 μ M RA or \approx 100 ng/ml CDF/LIF. Neurotransmitter levels were determined as described in Materials and Methods. Values are expressed as means \pm SEM of 3 cultures.

selective effect on the type of neurotransmitters expressed in cultured sympathetic neurons.

DISCUSSION

The present study reveals that RA induces the expression of a cholinergic phenotype in cultured sympathetic neurons of SCG of newborn rats. Long term exposure of these neurons to RA was found to increase ChAT activity and the level of ACh, and simultaneously to reduce TH and DBH activities and the level of NE. The RA-driven change of sympathetic neuron function reported in this study should help us to dissect the mechanism underlying neuronal plasticity.

Both catecholamine synthetic enzymes, TH and DBH, are pararely down regulated by RA. Several examples in the literature suggest common regulatory mechanisms for TH and DBH in noradrenergic cells. In the adult, transsynaptic stimulation and NGF injection elicit a selective increase of both enzyme activities in SCG and adrenal medulla (Chalazonitis et al., 1980; Otten et al., 1977). During embryonic development, both enzymes are expressed simultaneously and develop in concert within ganglia, adrenal gland, and gut (Teitelman et al., 1979; Black, 1982). Moreover, their expression was coordinately inhibited in cultured sympathetic neurons by partially purified cholinergic factor CDF/LIF (Swerts et al., 1983). Our experimental data with RA reveal another example of the developmental co-regulation of TH and DBH.

Concomitantly to a reduction of catecholaminergic properties, RA treatment stimulated ChAT specific activity and increased the ACh level in cultured sympathetic neurons.

It is of interest to note that RA is an endogenous compound of blood, with a concentration range between 2–10 nM in human serum (Frolik et al., 1978; de Ruyter et al., 1979). In SCG neurons grown in control conditions, ChAT expression has been attributed to the presence in the rat serum of a cholinergic inducing activity, not yet characterized (Wolinsky and Patterson, 1985). This suggests that RA could be one of the serum ele-

ments that induce cholinergic properties in cultured sympathetic neurons.

RA has previously been found to specifically stimulate the expression of cholinergic properties in other cell systems. When treated with RA, embryonal P19 carcinoma cells can differentiate into neurons that synthesize ACh (McBurney et al., 1988). A selective action of RA on ChAT activity has been demonstrated in developing spinal cord neurons and in some human neuroblastoma (Wuarin and Sidell, 1991; Casper and Davies, 1989a,b). In PC12 cells, RA regulates ChAT and TH activities, but to a lesser extent than in sympathetic neurons: ChAT specific activity was increased 2 fold, while the specific activity of TH was decreased 0.5 fold in the presence of 10 μ M RA for 8 days (Matsuoka et al., 1989). Taken together, these results and ours suggest that RA can exert the effects of a cholinergic differentiation factor on developing cultured neurons.

The mechanism by which RA exerts the effects shown in this study is unknown. RA effects might either be due to a direct action on sympathetic neurons, or to an indirect effect involving non-neuronal cells. However, these cells were eliminated from the culture after 1 week treatment with an antimetabolic agent, and when added after this time, RA was able to effectively modulate TH, DBH, and ChAT activities (not shown). Therefore, an indirect effect of RA on sympathetic neurons seems rather unlikely.

This study presents evidence that the deficit in TH activity can be accounted for by an identical deficit in the number of TH molecules. Further work is required to establish whether the variation in the number of TH molecules results from a regulatory mechanism at the level of gene transcription, mRNA stabilization, mRNA translation, or protein stability. Since the modulation of TH, DBH, and ChAT by RA is concomitant, the expression of the three enzymes could be regulated by a similar mechanism acting positively on ChAT and negatively on TH and DBH.

A large body of evidence suggests that RA exerts its biological effects primarily by controlling gene transcription, in a manner similar to that of steroid hor-

mones. RA binds to specific nuclear receptors (RA receptors, RARs, or retinoid X receptors, RXRs), transforming them into active transcriptional factors which in turn regulate the transcription of target genes (for review see Chambon et al., 1991). An abundant expression of RAR- α and RXR- α has recently been detected in chick neural crest cells, supporting a role for RA in the developing peripheral nervous system (Rowe et al., 1991).

In our study, the effect of RA on neurotransmitter synthetic enzyme activities can only be detected after a 3–5 day treatment, which suggests that in sympathetic neurons RA induces a long term regulatory mechanism affecting specific gene transcription. TH, DBH, and ChAT genes could be either primary target genes of RA receptors or indirectly modulated by RA. The characterization of TH, DBH, and ChAT promoter elements (Lewis et al., 1987; Kobayashi et al., 1989; Ibanez and Persson, 1991; Bejanin et al., 1992; Shaskus et al., 1992) will now allow these possibilities to be tested by searching for RA receptor binding sites in the transcriptional control regions of the three genes.

The TH promoter region contains *cis*-acting sequences that, in other systems, have been shown to be involved in mediating gene down regulation by RA. For example, RA can repress gene transcription by blocking transcriptional activation at an AP1 binding site (Nicholson et al., 1990; Schüle et al., 1991). As the TH promoter contains TRE-sites that have been shown to stimulate TH gene transcription (Vyas et al., 1990; Icard-Liepkalns et al., 1992), it is plausible that the down regulation of TH in response to RA could, in sympathetic neurons, result from a similar mechanism. RA has also been demonstrated to down regulate the expression of POU-domain transcription factors (Okamoto et al., 1990). Since a typical octamer motif that binds POU proteins is present in the regulatory region of the TH gene at position -175 (ATGCAATT), it could be that RA indirectly represses the expression of this gene by decreasing the expression of an inducer of transcription within the POU family of proteins. Finally, it should be also underlined that RA has been shown to down regulate gene expression post-transcriptionally by a mechanism involving mRNA stability (Antras et al., 1991).

A number of other substances can also induce cholinergic functions in cultured SCG neurons, the best characterized being endogenous factors, MANS, CDF/LIF and CNTF, and a chemical compound, butyrate (Swerts and Weber, 1984; Wong and Kessler, 1987; Saadat et al., 1989; Rao et al., 1990). The coordinated regulation of TH, DBH, and ChAT by these distinct factors suggests that common regulatory mechanisms do occur for these enzymes in SCG cultured neurons. Increasing evidence suggests that CDF/LIF, CNTF, and also inter-

leukin-6 (IL-6) share common signalling pathways, including tyrosine phosphorylation and involving the IL-6 signal-transducing receptor component gp130 (Gearing et al., 1991; Lord et al., 1991; Ip et al., 1992). The question therefore arises whether RA activates a signal transduction pathway similar to that of CDF/LIF and CNTF.

ACKNOWLEDGMENTS

We thank Simone Vidal and Michel Weber for initiating us into the technique of sympathetic neuron primary culture, Patrick P. Michel for helpful advices on cell culture, Austin G. Smith for providing CDF/LIF, William Mobley for the gift of NGF, Maurice Israël and Bernard Lesbats for helpful discussion and for performing ACh determinations, Riccardo Cervini and Philippe Ravassar for critical discussion, Danielle Samolyk for preparing the rat serum, and Bernard Guibert for advices on hplc technique. We are also grateful to Andrew Hicks and Maurice Israël for critically reading this manuscript. This work was supported by grants from CNRS, Rhône-Poulenc Rorer, INSERM, the Association pour la Recherche contre le Cancer, the French Ministère de la Recherche et des Technologies, and the Institut de Recherche sur la Moelle Epinière.

REFERENCES

- Antras J, Lasnier F, Pairault J (1991): Adiponin gene expression in 3T3-F442A adipocytes is posttranscriptionally down-regulated by retinoic acid. *J Biol Chem* 266:1157–1161.
- Bejanin S, Habert E, Berrard S, Dumas Milne Edwards JB, Loeffler JB, Mallet J (1992): Promoter elements of the rat choline acetyltransferase gene allowing nerve growth factor inducibility in transfected primary cultured cells. *J Neurochem* 58:1580–1583.
- Black IB (1982): Stages of neurotransmitter development in autonomic neurons. *Science* 215:1198–1204.
- Bradford MM (1976): A rapid and sensitive method for the quantitation of microgram quantities of protein utilizing the principle of protein-dye binding. *Anal Biochem* 72:248–254.
- Breitman TR, Selonick SE, Collins SJ (1980): Induction of differentiation of the human promyelocytic leukemia cell line (HL-60) by retinoic acid. *Proc Natl Acad Sci USA* 77:2936–2940.
- Brice A, Berrard S, Raynaud B, Ansieau S, Coppola T, Weber MJ, Mallet J (1989): Complete sequence of a cDNA encoding an active rat choline acetyltransferase: A tool to investigate the plasticity of cholinergic phenotype expression. *J Neurosci* 23:266–273.
- Casper D, Davies P (1989a): Stimulation of choline acetyltransferase activity by retinoic acid and sodium butyrate in a cultured human neuroblastoma. *Brain Res* 478:74–84.
- Casper D, Davies P (1989b): Mechanism of activation of choline acetyltransferase in a human neuroblastoma cell line. *Brain Res* 478:85–94.
- Chalazontis A, Rice PJ, Zigmond RE (1980): Increased ganglionic tyrosine hydroxylase and dopamine- β -hydroxylase activities

- following preganglionic nerve stimulation: Role of nicotinic receptors. *J Pharmacol Exp Ther* 213:139-143.
- Chambon P, Zeleat A, Petkovich M, Meudelsoln C, Leroy P, Krust A, Kastner P, Brand N (1991): The family of retinoic acid nuclear receptors. In Saurat JH (ed): "Retinoids: 10 Years On." Basel: Karger, pp 10-27.
- De Ruyter MG, Lambert WE, De Leenheer AP (1979): Retinoic acid: An endogenous compound of human blood—unequivocal demonstration of endogenous retinoic acid in normal physiological conditions. *Anal Biochem* 98:402-409.
- Dollé P, Rubette E, Kastner P, Petkovich M, Stoner CM, Gudas LJ, Chambon P (1989): Differential expression of genes encoding α , β , γ retinoic acid receptors and CRABP in the developing limbs of the mouse. *Nature* 342:702-705.
- Durston AJ, Timmermans JPM, Hage WJ, Hendriks HFI, de Vries NJ, Heideveld M, Nieuwkoop PD (1989): Retinoic acid causes an anteroposterior transformation in the developing central nervous system. *Nature* 340:140-144.
- Eichele G (1989): Retinoids and vertebrate limb pattern formation. *TIG* 5:246-251.
- Fonnum F (1975): A rapid radiochemical method for the determination of choline acetyltransferase. *J Neurochem* 24:407-409.
- Frolik CA, Tavela TE, Peck GL, Sporn MB (1978): High-pressure liquid chromatographic determination of 13-*cis*-retinoic acid and all-*trans*-retinoic acid in human plasma. *Anal Biochem* 86:743-750.
- Fukada K (1985): Purification and partial characterization of a cholinergic neuronal differentiation factor. *Proc Natl Acad Sci USA* 82:8795-8799.
- Gearing DP, Thut CJ, VandenBos T, Gimpel SD, Delaney PB, King J, Price V, Cosman D, Beckmann MP (1991): Leukemia inhibitory factor receptor is structurally related to the IL-6 signal transducer, gp130. *EMBO J* 10:2839-2848.
- Giguere V, Ong ES, Segui P, Evans RM (1987): Identification of a receptor for the morphogen retinoic acid. *Nature* 330:624-629.
- Giguere V, Lyn S, Yip P, Siu C-H, Amin S (1990): Molecular cloning of cDNA encoding a second cellular retinoic acid-binding protein. *Proc Natl Acad Sci USA* 87:6233-6237.
- Gough NM, Williams RL (1989): The pleiotropic actions of leukemia inhibitory factor. *Cancer Cells* 1:77-80.
- Hausler M, Sidell N, Kelly M, Donaldson C, Altman A, Mangelsdorf D (1983): Specific high-affinity binding and biologic action of retinoic acid in human neuroblastoma cell lines. *Proc Natl Acad Sci USA* 80:5525-5529.
- Hawrot E, Patterson PH (1979): Long-term culture of dissociated sympathetic neurons. *Methods Enzymol* 58:574-584.
- Ibanez CF, Persson H (1991): Localization of sequences determining cell type specificity and NGF responsiveness in the promoter region of the rat choline acetyltransferase gene. *Eur J Neurosci* 3:1309-1315.
- Icard-Liepkalns C, Faucon Biguet N, Vyas S, Robert JJ, Sassone-Corsi P, Mallet J (1992): AP-1 complex and *c-fos* transcription are involved in TPA provoked and trans-synaptic inductions of the tyrosine hydroxylase gene: Insights onto long-term regulatory mechanisms. *J Neurosci Res* 32:290-298.
- Ip NY, Nye ST, Boulton TG, Davis S, Taga T, Li Y, Birren SJ, Yasukawa K, Kishimoto T, Anderson DJ, Stahl N, Yancopoulos GD (1992): CNTF and LIF act on neuronal cells via shared signaling pathways that involve the IL-6 signal transducing receptor component gp130. *Cell* 69:1121-1132.
- Israel M, Lesbats B (1982): Application to mammalian tissues of the chemiluminescent method for detecting acetylcholine. *J Neurochem* 39:248-250.
- Kobayashi K, Kurosawa Y, Fujita K, Nagatsu T (1989): Human dopamine- β -hydroxylase gene: Two mRNA types having different 3'-terminal regions are produced through alternative polyadenylation. *Nucleic Acids Res* 17:1089-1102.
- Labatur R, Buda M, Berod A (1988): Long-term changes in rat brain tyrosine hydroxylase following reserpine treatment: A quantitative immunohistochemical analysis. *J Neurochem* 50:1375-1380.
- Landis SC, Keefe D (1983): Evidence for neurotransmitter plasticity in vivo: Developmental changes in properties of cholinergic sympathetic neurons. *Dev Biol* 98:349-372.
- Landis SC, Siegel RE, Schwab M (1988): Evidence for neurotransmitter plasticity in vivo. II. Immunocytochemical studies of rat sweat gland innervation during development. *Dev Biol* 126:129-140.
- Leblanc GG, Landis SC (1986): Development of choline acetyltransferase (CAT) in the sympathetic innervation of rat sweat glands. *J Neurosci* 6:260-265.
- Lewis EJ, Harrington CA, Chikaraishi DM (1987): Transcriptional regulation of the tyrosine hydroxylase gene by glucocorticoid and cyclic AMP. *Proc Natl Acad Sci USA* 84:3550-3554.
- Lord KA, Abdollahi A, Thomas SM, DeMarco M, Brugge JS, Heffman-Liebermann B, Liebermann DA (1991): Leukemia inhibitory factor and interleukin-6 trigger the same immediate early response, including tyrosine phosphorylation, upon induction of myeloid leukemia differentiation. *Mol Cell Biol* 11:4371-4379.
- Maden M, Ong DE, Summerbell D, Chytil F (1988): Spatial distribution of cellular protein binding to retinoic acid in the chick limb bud. *Nature* 335:733-735.
- Matsuka I, Mizuno N, Kurihara K (1989): Cholinergic differentiation of clonal rat pheochromocytoma cells (PC12) induced by retinoic acid: Increase of choline acetyltransferase activity and decrease of tyrosine hydroxylase activity. *Brain Res* 502:53-60.
- McBurney MW, Reuhl KR, Ally AI, Nasipuri S, Bell JC, Craig J (1988): Differentiation and maturation of embryonal carcinoma-derived neurons in cell culture. *J Neurosci* 8:1063-1073.
- Nawa H, Nakanishi S, Patterson PH (1991): Recombinant cholinergic differentiation factor (leukemia inhibitory factor) regulates sympathetic neuron phenotype by alterations in the size and amounts of neuropeptide mRNAs. *J Neurochem* 56:2147-2150.
- Nicholson RC, Mader S, Nagpal S, Leid M, Rochette-Egly C, Chambon P (1990): Negative regulation of the rat stromelysin gene promoter by retinoic acid is mediated by an AP1 binding site. *EMBO J* 9:4443-4454.
- Okamoto K, Okazawa H, Okuda A, Sakai M, Maranatsu M, Hamada H (1990): A novel octamer binding transcription factor is differentially expressed in mouse embryonic cells. *Cell* 60:461-472.
- Otten U, Schwab M, Gagnon C, Thoenen H (1977): Selective induction of tyrosine hydroxylase and dopamine β -hydroxylase by nerve growth factor: Comparison between adrenal medulla and sympathetic ganglia of adult and newborn rats. *Brain Res* 133:291-303.
- Patterson PH (1978): Environmental determination of autonomic neurotransmitter functions. *Ann Rev Neurosci* 1:1-17.
- Patterson PH, Chun LLY (1977): The induction of acetylcholine synthesis in primary cultures of dissociated rat sympathetic neurons. I. Effects of conditioned medium. *Dev Biol* 56:263-280.
- Perez-Castro AV, Toth-Rogler LE, Wei LN, Nguyen-Huu MC (1989): Spatial and temporal pattern of expression of the cellular retinoic acid-binding protein and the cellular retinol-binding protein during mouse embryogenesis. *Proc Natl Acad Sci USA* 86:8813-8817.
- Rao MS, Landis SC, Patterson PH (1990): The cholinergic neuronal

- differentiation factor from heart cell conditioned medium is different from the cholinergic factors in sciatic nerve and spinal cord. *Dev Biol* 139:65-74.
- Raynaud B, Faucon Biguet N, Vidal S, Mallet J, Weber MJ (1987): The use of tyrosine hydroxylase cDNA probe to study the neurotransmitter plasticity of rat sympathetic neurons in culture. *Dev Biol* 119:305-312.
- Rowe A, Eager NSC, Brickell PM (1991): A member of the RXR nuclear receptor family is expressed in neural-crest-derived cells of the developing chick peripheral nervous system. *Development* 111:771-775.
- Saadat S, Sendtner M, Rohrer H (1989): Ciliary neurotrophic factor induces cholinergic differentiation of rat sympathetic neurons in culture. *J Cell Biol* 108:1807-1816.
- Schotzinger RJ, Landis SC (1988): Cholinergic phenotype developed by noradrenergic sympathetic neurons after innervation of a novel cholinergic target in vivo. *Nature* 335:637-639.
- Schotzinger RJ, Landis SC (1990): Acquisition of cholinergic and peptidergic properties by sympathetic innervation of rat sweat glands requires interaction with normal target. *Neuron* 5:91-100.
- Schüle R, Rangarajan P, Yang N, Kliever S, Ransone LJ, Bolado J, Verma IM, Evans RM (1991): Retinoic acid is a negative regulator of AP-1 responsive genes. *Proc Natl Acad Sci USA* 88:6092-6096.
- Shuskus J, Greco D, Asnani LP, Lewis EJ (1992): A bifunctional genetic regulatory element of the rat dopamine β -hydroxylase gene influences cell type specificity and second messenger-mediated transcription. *J Biol Chem* 267:18821-18830.
- Smith AG (1991): Culture and differentiation of embryonic stem cells. *J Tissue Cultur Methods* 13:89-94.
- Strickland S, Mahdavi V (1978): The induction of differentiation in teratocarcinoma stem cells by retinoic acid. *Cell* 15:393-403.
- Swerts JP, Weber MJ (1984): Regulation of enzymes responsible for neurotransmitter synthesis and degradation in cultured rat sympathetic neurons. III. Effects of sodium butyrate. *Dev Biol* 106:282-288.
- Swerts JP, Le Van Thaf A, Vigny A, Weber, MJ (1983): Regulation of enzymes responsible for the neurotransmitter synthesis and degradation in cultured rat sympathetic neurons. I. Effects of muscle conditioned medium. *Dev Biol* 100:1-11.
- Teitelman G, Baker H, Joh TH, Reis D (1979): Appearance of catecholamine-synthesizing enzymes during development of rat sympathetic nervous system: Possible role of tissue environment. *Proc Natl Acad Sci USA* 76:509-513.
- Vayer P, Lamouroux A, Guibert B, Leviel V, Mallet J (1990): Transient expression of human dopamine- β -hydroxylase cDNA in eukaryotic cells. *Neurosci Res Comm* 6:77-81.
- Vyas S, Faucon Biguet N, Mallet J (1990): Transcriptional and post-transcriptional regulation of tyrosine hydroxylase gene by protein kinase C. *EMBO J* 9:3707-3712.
- Wagner M, Thaller C, Jessell T, Eichele G (1990): Polarizing activity and retinoid synthesis in the floor plate of the neural tube. *Nature* 345:819-822.
- Waymire JC, Bjur R, Weiner N (1971): Assay of tyrosine hydroxylase by coupled decarboxylation of dopa formed from 1-14C-L-Tyrosine. *Anal Biochem* 43:588-600.
- Wolinsky M, Patterson PH (1983): Tyrosine hydroxylase activity decreases with induction of cholinergic properties in cultured sympathetic neurons. *J Neurosci* 3:1495-1500.
- Wolinsky EJ, Patterson PH (1985): Rat serum contains a developmentally regulated cholinergic inducing activity. *J Neurosci* 5:1509-1512.
- Wong V, Kessler JA (1987): Solubilization of a membrane factor that stimulates levels of substance P and choline acetyltransferase in sympathetic neurons. *Proc Natl Acad Sci USA* 84:8726-8729.
- Wuarin L, Sidell N (1991): Differential susceptibilities of spinal cord neurons to retinoic acid-induced survival and differentiation. *Dev Biol* 144:429-435.
- Yamamoto T, Fukada K, Aebersold R, Korsching S, Fann M-J, Patterson PH (1989): The cholinergic neuronal differentiation factor from heart cells is identical to leukemia inhibitory factor. *Science* 246:1412-1416.
- Zelent A, Krust A, Petkovich M, Kastner P, Chambon P (1989): Cloning of murine α and β retinoic acid receptors and a novel receptor γ predominantly expressed in skin. *Nature* 339:714-717.

Comparative Safety of Tetracycline, Minocycline, and Doxycycline

Lori E. Shapiro, MD, FRCPC; Sandra R. Knowles, BScPhm; Neil H. Shear, MD, FRCPC

Background: Because minocycline can cause serious adverse events including hypersensitivity syndrome reaction (HSR), serum sicknesslike reaction (SSLR), and drug-induced lupus, a follow-up study based on a retrospective review of our Drug Safety Clinic and the Health Protection Branch databases and a literature review was conducted to determine if similar rare events are associated with tetracycline and doxycycline. Cases of isolated single organ dysfunction (SOD) attributable to the use of these antibiotics also were identified.

Observations: Nineteen cases of HSR due to minocycline, 2 due to tetracycline, and 1 due to doxycycline were identified. Eleven cases of SSLR due to minocycline, 3 due to tetracycline, and 2 due to doxycycline were identified. All 33 cases of drug-induced lupus were attrib-

able to minocycline. Forty cases of SOD from minocycline, 37 cases from tetracycline, and 6 from doxycycline were detected. Hypersensitivity syndrome reaction, SSLR, and SOD occur on average within 4 weeks of therapy, whereas minocycline-induced lupus occurs on average 2 years after the initiation of therapy.

Conclusions: Early serious events occurring during the course of tetracycline antibiotic treatment include HSR, SSLR, and SOD. Drug-induced lupus, which occurs late in the course of therapy, is reported only with minocycline. We theorize that minocycline metabolism may account for the increased frequency of serious adverse events with this drug.

Arch Dermatol. 1997;133:1224-1230

MINOCYCLINE HAS been reported to cause serious, rare adverse events including the hypersensitivity syndrome reaction (HSR), serum sicknesslike reaction (SSLR), and drug-induced lupus (DIL).^{1,2} We conducted a review to determine if similar events are associated with other tetracycline antibiotics, namely, tetracycline and doxycycline. We also attempted to identify serious single organ dysfunction (SOD) attributable to these antibiotics.

RESULTS

Review of the Drug Safety Clinic database, Health Protection Branch data, and MEDLINE search produced 19 reports of HSR, 11 reports of SSLR, 40 reports of SOD, and 32 reports of DIL attributable to minocycline (**Table 1**).³⁻³⁴ **Table 2** shows data on the mean patient age, mean interval to onset of the reaction, and sex distribution of these reactions. We found no difference in the average daily doses of minocycline in causing the different re-

action patterns. The most common patterns of internal organ involvement seen with minocycline HSR were hepatitis in 15 (79%), lymphadenopathy in 14 (74%), hematologic abnormalities in 13 (68%), and renal and pulmonary abnormalities in 5 (26%) patients each. Three case fatalities have been described.²¹ Three patients who were rechallenged redeveloped symptoms within 48 hours.

Reports of SOD attributable to minocycline include 17 of pneumonitis,^{5,18-23} 4 of hepatitis,^{3,24,25} 2 of antineutrophil cytoplasmic antibody-positive polyarthritides,^{26,27} 1 of nephritis,²⁸ 1 of both fulminant hepatic failure and necrotizing pancreatitis,²⁹ and 1 of severe cutaneous adverse reaction.³⁰

The patients with minocycline-induced lupus erythematosus presented with malaise that was accompanied by myalgia, arthralgia, or arthritis. Eighty-eight percent of cases occurred in women. Ten patients developed elevated serum hepatic transaminase levels. Two patients had livedo reticularis and antineutrophilic cytoplasmic antibodies, and in 2 other patients, precise descriptions of their erup-

From the Divisions of Dermatology (Drs Shapiro and Shear) and Clinical Pharmacology (Drs Shapiro and Shear and Ms Knowles), Drug Safety Research Group (Drs Shapiro and Shear and Ms Knowles), Departments of Medicine (Drs Shapiro and Shear), Pharmacology (Dr Shear), and Pharmacy (Ms Knowles), Sunnybrook Hospital, University of Toronto Medical School, Toronto, Ontario.

MATERIALS AND METHODS

DEFINITIONS OF ADVERSE EVENTS

Specific reaction patterns were identified for inclusion. Hypersensitivity syndrome reaction was defined by fever, skin eruption, and internal organ involvement developing within 8 weeks of initiation of therapy; SSLR was defined by fever, skin eruption (most commonly urticarial or erythema multiforme), arthralgia with or without lymphadenopathy occurring within 6 weeks of treatment, and DIL was defined by the presence of antinuclear antibodies, the presence of at least 1 clinical feature of systemic lupus erythematosus (SLE) that resolves with drug discontinuation, and the absence of idiopathic SLE. Single organ dysfunction was defined as the presence of severe disease in a major organ, eg, pancreatitis, hepatitis.

SOURCES OF CASES

Drug Safety Clinic

We reviewed the records of all patients referred to the Glaxo Wellcome-Sunnybrook Drug Safety Clinic, Toronto, Ontario, from January 1985 through October 1996 who possibly had adverse events attributable to the use of minocycline, tetracycline, or doxycycline.

Health Canada

Reports from the Adverse Drug Reaction Monitoring Division of the Health Protection Branch, Ottawa, Ontario, were requested regarding adverse events possibly attributable to the use of minocycline, tetracycline, or doxycycline from 1966 through October 1996. Cases were classified as HSR, SSLR, DIL, or isolated SOD.

Literature Search

A thorough computer-based MEDLINE search of articles published from 1966 to October 1996 was conducted. Search terms included drug hypersensitivity, tetracycline antibiotics, and liver, kidney, skin, and joint diseases. The reference lists of all pertinent articles also were reviewed to identify any additional articles that might have been missed or that predated the computer search.

Utilization Data

The Institute of Medical Statistics, Toronto, provided us with the most recent statistics from 1994 to identify prescribing patterns for tetracycline antibiotics.

tion were lacking. No patient had renal, neurologic, or vasculitic involvement. All patients' symptoms had improved after discontinuation of the minocycline. Twenty-one patients who were rechallenged with minocycline developed a recrudescence of their DIL. One patient in whom

symptoms developed with minocycline rechallenge remained asymptomatic after doxycycline exposure.³¹

Review of the Drug Safety Clinic database, Health Protection Branch data, and MEDLINE search produced 2 reports of HSR, 3 reports of SSLR, 37 reports of SOD, and no reports of DIL attributable to tetracycline.³⁵⁻⁴¹

Review of the Drug Safety Clinic database, Health Protection Branch data, and MEDLINE search produced 1 report of HSR, 2 reports of SSLR, 6 reports of SOD, and no reports of DIL attributable to doxycycline.⁴²⁻⁴⁹

PRESCRIBING DATA

The Institute of Medical Statistics provided the most recent (ie, 1994) Canadian national statistics regarding the use of tetracycline antibiotics. In 1994, 1 866 000 prescriptions for tetracycline antibiotics were filled (**Table 3**).

COMMENT

Minocycline has been used as successful, safe, long-term therapy for patients with acne vulgaris. However, there are concerns about the safety of minocycline based on recent reports of serious adverse events.^{1,2} These reports of minocycline-induced side effects prompted a complete review of the literature to determine whether these reactions occur with other tetracycline antibiotics.

Twenty-two patients with HSRs attributable to the 3 tetracycline antibiotics were identified, of which minocycline was implicated in 86%. Reports of hepatotoxic effects from excessive serum levels of tetracycline are not included in this report as the mechanism of these reactions is associated with suprapharmacologic doses.⁴⁹⁻⁵³

Of note are additional references in the literature pertaining to tetracycline antibiotic-induced severe isolated SOD. These cases may represent a forme fruste of HSRs. For example, critical detailed information in case reports is often lacking so that the defining criteria of an HSR may not be fulfilled (eg, presence of fever). Another shortcoming with extracting data from case reports is that patients are often taking multiple medications and exact details of timing are missing. Therefore, an accurate assessment of drug causation is more difficult and less reliable.⁵⁴

Isolated SOD attributable to tetracycline and doxycycline is manifest most commonly as severe cutaneous adverse reaction (30% and 71%, respectively), whereas SOD related to minocycline most commonly is manifest as pneumonitis (45%).

Based on the available information, there are more reports of serious adverse events from minocycline use than from the use of other tetracycline antibiotics. We acknowledge that the sources from which we collected our data rely on voluntary reporting, and therefore only a fraction of the true number of reactions are known. Although it is unclear why there are more serious adverse events reported with the use of minocycline, we theorize that this may relate to its unique metabolism.

Tetracycline antibiotics all possess the same basic

Table 1. Summary of Adverse Events to Tetracycline Antibiotics

	Tetracycline			Minocycline			Doxycycline		
	Drug Safety Clinic	Health Protection Branch	Literature	Drug Safety Clinic	Health Protection Branch	Literature	Drug Safety Clinic	Health Protection Branch	Literature
No. referred	166	976		17	160		39	145	
Mild:									
Rash	86	406	0	1	52	0	16	38	0
Urticaria	35	138	0	5	7	0	15	0	0
Angioedema	11	8	0	1	8	0	3	1	0
Photosensitivity	4	10	0	0	0	0	3	4	0
Vomiting/diarrhea	23	159	0	2	53	0	8	17	0
Severe:									
Hypersensitivity syndrome reaction	0	1	1 ⁴⁵	2	4	13 ^{16,18,24,27}	0	0	1 ⁴⁵
Serum-sicknesslike syndrome	0	3	0	2	4	5 ²⁴	11	1	0
Drug-induced lupus	0	0	0	1	0	22 ^{2,3,19,27,31,32}	0	0	0
Single organ dysfunction	2	26	9	0	14	26	0	3	3
Severe cutaneous adverse reaction	1	9	1 ²⁵	0	2	1 ²⁴	0	1	3 ^{25,48}
Hepatitis	1	7	0	0	7	4 ^{2,34,25}	0	0	0
Pneumonitis	0	0	1 ²⁵	0	0	17 ^{8,18,22,33}	0	0	0
Pancreatitis	0	3	4 ^{25,41,43}	0	1	1 ²⁹	0	1	0
Nephritis	0	2	0	0	0	1 ²⁸	0	1	0
Hematologic	0	4	2 ^{39,46}	0	4	0	0	0	0
Parotitis	0	1	0	0	0	0	0	0	0
Myocarditis	0	0	1 ²⁷	0	0	0	0	0	0
Arthritis	0	0	0	0	0	2 ^{26,27}	0	0	0

4-ring carbocyclic structure but differ in the substituents on the ring²² (Figure). Doxycycline has a hydroxyl side chain distinguishing this congener from tetracycline.²⁶ Minocycline shares the basic 4-ring structure of the other commonly used tetracyclines having a substitution of a dimethylamino group in the 7 position.⁵⁷ Whether minocycline metabolism produces a reactive metabolite is unknown, although an iminoquinone derivative may be generated that is a potential reactive electrophilic intermediate. Neither tetracycline nor doxycycline contains this amino acid side chain that has the potential to form this reactive metabolite.

Black pigmentation in the thyroid gland has been seen in patients receiving long-term minocycline treatment and is not seen with other tetracyclines. One explanation for this effect of minocycline is that its strongly electron-donating dimethylamino group possibly increases its reactivity to oxidation. In support of this theory, treatment of minocycline-induced black pigmentation with thyroid peroxidase resulted in the formation of a black product, whereas other members of the tetracycline family were not oxidized to dark products by the same system.⁵⁸

In vitro studies have demonstrated the presence of a minocycline-glutathione conjugate when minocycline is incubated with hypochlorous acid, as is found in neutrophils. This in vitro system serves as a surrogate for oxidation reactions that take place in the liver. These reactions are most commonly mediated by the cytochrome P450 family of heme-containing enzymes. When a reac-

tive metabolite is generated, there are several cellular mechanisms that detoxify this product. One such system is glutathione transferase; therefore, the presence of minocycline-glutathione conjugates implies the formation of potentially toxic metabolites. When tetracycline or doxycycline were incubated in the same system, no glutathione conjugates were detected (J. Utrecht, personal communication, 1996).

The potential reactive metabolites generated by minocycline may bind to tissue macromolecules thereby causing cell damage directly, or they may act as haptens, eliciting an immune response secondarily.⁵⁹ This "hapten hypothesis" is thought to explain HSRs seen with aromatic anticonvulsants, sulfonamide antibiotics, allopurinol, and dapsone, as well as SSI-Rs due to cefaclor.⁶⁰

Minocycline causes DIL and appears to be most common in young women. We found no reports of either tetracycline- or doxycycline-induced lupus. There has been a misperception that tetracycline causes DIL based on a misinterpretation of the 1959 article by Domz et al.⁶¹ In that article, 1 of the 3 case reports describes aminoglutethimide-induced lupus erythematosus and another describes positive lupus erythematosus cells without clinical symptoms after tetracycline and penicillin were separately administered. The third case report describes a patient with active SLE whose underlying disease continued to progress after tetracycline was prescribed and in whom a severe cutaneous adverse reaction, possibly from tetracycline, developed. These cases do not support the concept of tetracycline causing DIL.

Group	Mean±SE Patient Age, y.	Mean±SE Interval to Onset, d (Range)	Sex, No.
Hypersensitivity Syndrome Reaction			
Tetracycline	54	11 (1-21)	2 M
Minocycline	21.2±1.3	24.4±1.5 (4-30)	13 F, 6 M
Doxycycline	18	15 (2-37)	1 F
Serum Sicknesslike Reaction			
Tetracycline		11±3 (8-14)	1 F, 1 M
Minocycline	25±3	16.2±2.7 (8-35)	6 F, 5 M
Doxycycline	35.3±12.3	24.5 (21-28)	2 F, 1 M
Drug-Induced Lupus			
Tetracycline			
Minocycline	21.9±1.5	632.6±104.8 (3-2190)	28 F, 4 M
Doxycycline			
Single Organ Dysfunction			
Tetracycline	41.8±8.0*	5±1.8 (1-50)*	17 F, 18 M
Minocycline	42.6±4.7†	18.3±5.6 (1-720)†	18 F, 9 M
Doxycycline	39.8±10.3‡	13.8±8.5 (1-10)‡	3 F, 3 M

* Denotes values for tetracycline-induced severe cutaneous adverse reactions.

† Denotes values for minocycline-induced pneumonitis.

‡ Denotes values for doxycycline-induced severe cutaneous adverse reactions.

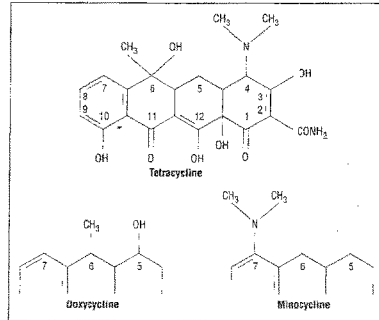
No.	Tetracycline	Minocycline	Doxycycline
Total No. prescriptions (% of total)	855 000 (45.8)	369 000 (19.8)	642 000 (34.4)
New prescriptions, %	68.2	37.2	91.3
Repeated prescriptions, %	31.8	62.8	8.7

* From the Institute of Medical Statistics, Toronto, Ontario.

Several mechanisms for DIL have been suggested and include the possibility that a reactive metabolite binds to the class II major histocompatibility antigen and induces an autoimmune reaction analogous to a graft vs host reaction.⁵² A drug or its potentially reactive metabolites may bind directly to histones and act as haptens, producing an antigenic complex capable of stimulating autoantibody formation.⁶³ Factors that have been implicated in causing DIL include the use of the drug for long-term therapy, dose dependency, and the presence of a functional group that is easily oxidized to a reactive metabolite such as what we hypothesized occurs with minocycline.

The frequency of these reactions attributable to tetracycline antibiotics remains unknown. The incidence or prevalence cannot be estimated without knowing the denominator, ie, the number of patients receiving each of the tetracycline antibiotics. However, the risk of developing symptomatic hepatotoxic effects from tetracyclines has been estimated to be between 1.6 per million and 2.1 per 100 000 treated patients.⁶⁴⁻⁶⁶

In Canada, tetracycline has been licensed since 1959, doxycycline since 1969, and minocycline since 1972. Review of the Institute of Medical Statistics data reveals that although minocycline is the least frequently prescribed



Structure of tetracycline antibiotics.

of the 3 tetracycline congeners, it is the tetracycline antibiotic with the largest fraction of repeated prescriptions. This prescribing pattern likely reflects the fact that minocycline is more commonly used as long-term therapy, particularly in the treatment of acne vulgaris. This may help explain the sole association of minocycline with DIL. Doxycycline and tetracycline are more likely to be prescribed for acute infections in which the duration of treatment is relatively brief. This assumes that prescribing patterns in Canada reflect patterns in other geographic locales. It also assumes that the reason for the long-term use of minocycline is not explained by better tolerance compared with tetracycline and doxycycline.

The diagnosis of these specific reaction patterns rests largely on the presence of a syptom complex. In a recent report of minocycline-induced SSLRs, a migration inhibitory factor assay and mast cell degranulation test were positive in 4 of 5 patients.⁸ No skin, patch, or lymphocyte transformation testing was documented in any of the published reports.

To evaluate the safety of high-dose long-term minocycline therapy, researchers in England studied 700 patients with acne vulgaris treated with 100 mg/d or more of minocycline for a mean of 10.5 months.⁶⁷ Although no laboratory abnormalities were noted, the study population was too small to detect the severe but rare reactions that can occur. A study sample would need to be 3 to 4 times larger to detect hepatitis and DIL that occur in less than 1 in 10 000 patients.⁶⁸

Blood samples from more than 3000 patients receiving minocycline showed no abnormalities in hepatic transaminase levels.⁶⁹ In the United Kingdom, 6.5 million patients have been treated with minocycline on average for 9 months during the last 26 years, and in 1996, 28 million tablets a year of minocycline were taken. The conclusion is that these serious side effects are extremely rare.

Risk management strategies can be applied to various phases of prescribing. These include pretreatment identification of risk factors, risk communication of potential adverse events to patients when the medication is prescribed, monitoring and ascertainment of adverse

Table 4. Risk Management Strategy for Tetracycline Antibiotics*

Minocycline
Common and dose-dependent side effects: gastrointestinal upset, vestibular dysfunction, headache, localized pigmentary disturbances
Serious, rare side effects†: HSR, SSLR, isolated SOD, most commonly manifest as pneumonitis, DIL, and hepatitis
Early reaction patterns: HSRs, SSLRs, and SOD occur on average within 2 mo of treatment and are characterized by fever, malaise, arthralgia with or without major organ involvement.
Late reaction pattern: DIL occurs on average after 2 y of therapy but may be delayed up to 6 y. Occurs predominantly in females, presents with a symmetrical polyarthritides or polyarthralgia in the small joints of the hands and wrists. Some of these patients have concomitant liver disease with biopsy specimens disclosing chronic active hepatitis. Phototoxicity is rare. Benign intracranial hypertension is rare.
Recommendations
<ul style="list-style-type: none"> Minocycline should be avoided in patients with systemic lupus erythematosus (SLE) or in those with a history of SLE in a first-degree relative. Relative contraindications to the use of minocycline include underlying hepatic or renal disease. Patients receiving chronic minocycline therapy should have antinuclear antibody and hepatic transaminase levels assessed only if symptoms develop during the course of treatment. Routine monitoring of patients receiving chronic minocycline therapy is not recommended. Any patient with a serious adverse event such as HSR, SSLR, or DIL should be advised to avoid the class of tetracycline antibiotics. First-degree relatives of patients with a tetracycline-induced HSR may be at higher risk for similar reaction patterns and should avoid tetracycline antibiotics. In patients presenting with an early reaction pattern, the following laboratory values should be assessed: complete blood cell count, hepatic transaminases, urinalysis, urea and creatinine, chest radiograph, thyroid function tests at 3 mo There is no standardized treatment for early reaction patterns. Discontinuation of the offending drug is mandatory. Symptomatic treatment with nonsteroidal anti-inflammatory drugs or corticosteroids may be required. In patients presenting with a late reaction pattern, the following laboratory values should be assessed: antinuclear antibody, hepatic transaminases Treatment of DIL includes discontinuation of the offending drug. Symptomatic treatment with nonsteroidal anti-inflammatory drugs or corticosteroids may be required. Severe adverse reactions should be reported to the appropriate agency such as the US Food and Drug Administration or Canadian Health Protection Branch.

events during therapy, and management of adverse events when they occur (Table 4).

Before physicians prescribe tetracyclines, identification of patients who are at risk for adverse reactions is required. The recent publications of minocycline-induced lupus have prompted a change in the US product labeling adverse reactions section from "transient lupus-like syndrome" to "lupus-like syndrome."⁷⁰ Because minocycline is clearly associated with DIL, prudence would dictate avoidance in patients with underlying SLE or a history of SLE in a first-degree relative. Few data are available to support or negate the use of drugs known to cause DIL in patients with spontaneous lupus.⁷¹ There are no data to support that the natural history of lupus erythematosus is worsened by use of such a drug even if symptoms develop; however, the standard of practice for

Table 4. Risk Management Strategy for Tetracycline Antibiotics* (cont)

Tetracycline
Common and dose-dependent side effects: nausea, vomiting, epigastric burning, photosensitivity, vaginal candidiasis
Serious, rare side effects: HSR, SSLR, benign intracranial hypertension
Recommendations
<ul style="list-style-type: none"> No baseline or periodic investigations are required. Investigations should be done if symptoms develop. Any patient with a serious adverse event such as HSR or SSLR should be advised to avoid the class of tetracycline antibiotics.
Doxycycline
Common and dose-dependent side effects: nausea, vomiting, epigastric burning, photosensitivity, vaginal candidiasis
Serious, rare side effects: HSR, SSLR, benign intracranial hypertension
Recommendations
<ul style="list-style-type: none"> Warn patients about phototoxic potential. No baseline or periodic investigations are required. Investigations should be done if symptoms develop. Any patient with a serious adverse event such as HSR or SSLR should be advised to avoid the class of tetracycline antibiotics.

*Appropriate risk communication for each drug requires (1) informing patients about minor side effects if they are relatively common (>2% of exposed patients) or may be dose dependent; and (2) warning patients about rare side effects that are serious, such as hypersensitivity syndrome reaction (HSR), serum sicknesslike reaction (SSLR), single organ dysfunction (SOD), and drug-induced lupus (DIL).

†These reactions can be divided into 2 groups according to the average time to onset after initiation of therapy, early and late.

rheumatologists is avoidance of drugs that can cause a lupuslike reaction in patients with definite SLE.⁷²

Appropriate risk communication imparts information to the patient about minor side effects that are common and about rare side effects that are serious. It is clear that the serious reaction patterns to tetracycline antibiotics can be categorized into 2 groups—early and late. Early reactions include HSRs, SSLRs, and isolated SOD that occur on average within 2 months of treatment. They are characterized by fever, malaise, and arthralgia with or without major organ involvement. Late reactions include DIL, which occurs on average 2 years after initiation of therapy but may be delayed even up to 6 years. These patients, predominantly female, present with a symmetrical polyarthritides or polyarthralgia in the small joints of the hands and wrist. It is important to recognize this group as it is believed that there is no sex predilection to DIL when compared with idiopathic SLE. This belief comes from earlier reports of antiarrhythmic-induced lupus erythematosus where the population treated reflects the population afflicted with the disease in question.⁶³ Minocycline-induced lupus erythematosus afflicts the same population as idiopathic lupus, and there may be a long interval before onset. Some of these patients had concomitant liver disease with biopsy specimens disclosing chronic active hepatitis.² In these patients, all symptoms and signs promptly resolved with drug discontinuation. To avoid unnecessary interventions, such as liver biopsy or immunosuppressive therapy, this reaction pattern must be promptly recognized.

Appropriate investigations of an early reaction include complete blood cell count to identify an atypical lymphocytosis or eosinophilia, hepatic transaminase lev-

els, urinalysis, urea and creatinine levels, chest radiograph, and thyroid function test 3 months after the acute event.^{59,73} Further evaluation of internal organ involvement will be determined by the patient's history and physical examination findings.

Extrapolating from the literature pertaining to aromatic anticonvulsant HSRs, we suggest that patients with a tetracycline antibiotic-induced HSR and their first-degree relatives avoid the class of tetracycline antibiotics.⁵⁹ A medical alert bracelet should document allergy to the tetracycline antibiotics.

For late reactions, tests for antinuclear antibody and hepatic transaminase levels are appropriate. Based on the rarity of DIL and the lack of large prospective trials, it is not justified to routinely monitor patients receiving long-term minocycline therapy. In one prospective study, 11 patients treated with minocycline showed no difference between pretreatment hepatic transaminase levels and those measured 6 months later.⁷⁴ A recent literature review did not support the practice of routine laboratory monitoring in healthy young patients with acne treated with oral tetracycline or minocycline.⁷⁵ Prospective trials to assess liver function in a large cohort of patients receiving minocycline for acne are under way.³ Patients receiving long-term minocycline therapy should have an antinuclear antibody test and hepatic transaminase levels assessed only if symptoms develop during their course of treatment.

Treatment for these serious adverse reactions is not standardized. Corticosteroid therapy has been widely used without confirmation of its efficacy by controlled studies. Anecdotal experience suggests that treatment with systemic corticosteroids in doses of 0.5 to 1.0 mg/kg improves symptoms and laboratory measurements.⁷⁶ A slow taper over several weeks is suggested as relapses of HSR are common.⁷⁶ Severe adverse reactions should be reported to the appropriate agency such as the Canadian Health Protection Branch or the US Food and Drug Administration.

Reports of idiosyncratic adverse events with tetracycline, doxycycline, and minocycline are infrequent. Although there are published reports stating that patients with serious adverse reactions to minocycline can be subsequently treated with tetracycline, there is minimal evidence to support this claim.⁷⁷ One patient who developed a minocycline-induced pneumonitis on 2 occasions was able to tolerate doxycycline with no relapse.⁶ Another patient who developed minocycline-induced lupus was able to tolerate doxycycline without an adverse event.³¹ Because of the severity of these reactions, patients who experience a serious adverse event while receiving 1 of these tetracycline antibiotics should be advised to avoid all tetracyclines until more information regarding potential cross-reactivity is known.

Accepted for publication June 12, 1997.

This work was supported in part by a grant-in-aid from Medicis Pharmaceutical Corporation, Phoenix, Ariz.

The interpretation of the results does not reflect the opinions or policies of Health Canada. The reproduced information from the Health Protection Branch is raw information and has not been scientifically verified.

Presented at the Canadian Pharmacoeconomics Forum, Hamilton, Ontario, April 28 and 29, 1997.

We thank the Drugs Directorate, Health Protection Branch, Ottawa, Ontario, for providing the data.

Reprints: Neil H. Shear, MD, FRCPC, Drug Safety Research Group, Sunnybrook Health Science Centre, Room E240, 2075 Bayview Ave, Toronto, Ontario, Canada M4N 3M5.

REFERENCES

- Knowles S, Shapiro L, Shear N. Serious adverse reactions induced by minocycline: report of 13 patients and review of the literature. *Arch Dermatol.* 1996; 132:934-939.
- Gough A, Chapman S, Wagstaff K, Emery P, Elias E. Minocycline-induced autoimmune hepatitis and systemic lupus erythematosus-like syndrome. *BMJ.* 1996; 312:369-372.
- Malcolm A, Heap T, Eckstein R, Lunzer M. Minocycline-induced liver injury. *Am J Gastroenterol.* 1996;91:1641-1643.
- Harel L, Amir J, Livni E, Straussberg R, Varsano I. Serum-sickness-like reaction associated with minocycline therapy in adolescents. *Ann Pharmacother.* 1996; 30:481-483.
- Golstein P, Deviere J, Cresmer M. Acute hepatitis and drug-related lupus induced by minocycline treatment. *Am J Gastroenterol.* 1997;92:143-146.
- Sitbon O, Biceil N, Dusopt C, et al. Minocycline pneumonitis and eosinophilia: a report on eight patients. *Arch Intern Med.* 1994;154:1633-1640.
- Davies M, Kersey P. Acute hepatitis and exfoliative dermatitis associated with minocycline. *BMJ.* 1988;298:1523-1524.
- Kaufmann D, Pichler W, Beer J. Severe episode of high fever with rash, lymphadenopathy, neutropenia, and eosinophilia after minocycline therapy for acne. *Arch Intern Med.* 1994;154:1983-1984.
- Min DI, Burke PA, Lewis WD, Jenkins RL. Acute hepatic failure associated with oral minocycline: a case report. *Pharmacotherapy.* 1992;12:68-71.
- Wilkinson S, Stewart W, Spierß E, Pears J. Protracted systemic illness and interstitial nephritis due to minocycline. *Postgrad Med J.* 1989;55:53-56.
- Parneix-Spake A, Bastuji-Garin S, Lobat J, et al. Minocycline as a possible cause of severe and protracted hypersensitivity drug reaction. *Arch Dermatol.* 1995; 131:490-491.
- Inoue C, Kondo Y, Suwabe M, Igarashi Y, Tada K. Minocycline-related lupus in childhood. *Eur J Pediatr.* 1994;153:540.
- Matsuura T, Shimizu Y, Fujimoto H, Miyazaki T, Kano S. Minocycline-related lupus. *Lancet.* 1993;340:1553.
- Byrne PAC, Williams BD, Pritchard MH. Minocycline-related lupus. *Br J Rheumatol.* 1994;33:674-676.
- Quilty B, McHugh N. Lupus-like syndrome associated with the use of minocycline. *Br J Rheumatol.* 1994;33:1197-1198.
- Buigen D. Minocycline-related lupus. *Br J Rheumatol.* 1995;34:398.
- Gordon P, White M, Harriot R, Martin J, Reid D. Minocycline-associated lupus erythematosus. *Br J Dermatol.* 1995;132:120-121.
- Toyoshima M, Sato A, Hayakawa H, Taniguchi M, Imekawa S, Chida K. A clinical study of minocycline-induced pneumonitis. *Intern Med.* 1996;35:176-179.
- Otero M, Goodpasture H. Pulmonary infiltrates and eosinophilia from minocycline. *JAMA.* 1983;250:2602.
- Gullion J-M, Joly P, Astruc B, et al. Minocycline-induced cell-mediated hypersensitivity pneumonitis. *Ann Intern Med.* 1992;117:476-481.
- Kloppenborg M, Dijkmans B, Broedveld F. Hypersensitivity pneumonitis during minocycline treatment. *Neth J Med.* 1994;44:210-213.
- Bando T, Fujimura M, Noda Y, Hirose J-I, Ohta G, Matsuda T. Minocycline-induced pneumonitis with bilateral hilar lymphadenopathy and pleural effusion. *Intern Med.* 1994;33:177-179.
- Bridges A. Minocycline-induced pneumonia. *Ann Intern Med.* 1993;118:749-750.
- Burette A, Finet C, Prigogine T, De Roy G, Delenne M. Acute hepatic injury associated with minocycline. *Arch Intern Med.* 1994;144:1481-1492.
- Gorard D. Late-onset drug fever associated with minocycline. *Postgrad Med J.* 1990;66:404-406.
- Gaffney K, Merry P. Antineutrophil cytoplasmic antibody-positive polyarthritis associated with minocycline therapy. *Br J Rheumatol.* 1996;35:1327.
- Elkayam O, Yaron M, Caspi D. Minocycline-induced arthritis associated with fever, livedo reticularis, and pANCA. *Ann Rheum Dis.* 1996;55:769-771.
- Walker R, Thomson N, Dowling J, Ogg C. Minocycline-induced acute interstitial nephritis. *BMJ.* 1979;1:524.

- hepatotoxicity. *Transplant Proc.* 1993;25:1973.
30. Shoji A, Someda Y, Hamada T. Stevens-Johnson syndrome due to minocycline therapy. *Arch Dermatol.* 1987;123:18-20.
 31. Masson C, Chevallier A, Pascaretti C, Legrand E, Brégeon C, Audran M. Minocycline related lupus. *J Rheumatol.* 1996;23:2160-2161.
 32. Sigmann P. Minocycline-induced pneumonia. *Ann Intern Med.* 1993;118:750.
 33. Yokoyama A, Mizushima Y, Suzuki H, Arai N, Kitagawa M, Yana S. Acute eosinophilic pneumonia induced by minocycline: prominent Kerley B lines as a feature of positive rechallenge test. *Jpn J Med.* 1990;29:195-198.
 34. Puyana J, Urena V, Duice S, Fernandez-Rivas M, Cuevas M, Frai J. Serum sickness-like syndrome associated with minocycline therapy. *Allergy.* 1990;45:313-315.
 35. Burgs S, Dawber R. Stevens-Johnson syndrome and toxic epidermal necrolysis in a patient with systemic lupus erythematosus. *J Am Acad Dermatol.* 1985;13:655-666.
 36. Elmore M, Rogge J. Tetracycline-induced pancreatitis. *Gastroenterology.* 1981;81:1134-1136.
 37. Fenoglio J, McAlister H, Mulick F. Drug-related myocarditis: hypersensitivity myocarditis. *Hum Pathol.* 1981;12:900-907.
 38. Ho D, Tashkin D, Bain M, Sharma O. Pulmonary infiltrates with eosinophilia associated with tetracycline. *Chest.* 1973;76:33-36.
 39. Mazza J, Kryda M. Tetracycline-induced hemolytic anemia. *J Am Acad Dermatol.* 1990;2:506-508.
 40. Simpson M, Pryzybilik J, Innis B, Denham M. Hemolytic anemia after tetracycline therapy. *N Engl J Med.* 1985;312:940-942.
 41. Torrossi J, Vender R. Tetracycline-induced pancreatitis. *J Clin Gastroenterol.* 1987;9:586-581.
 42. Pan C, Quimata A. Doxycycline-induced parotitis. *Postgrad Med J.* 1991;67:313-314.
 43. Lawis-Jones M, Evans S, Thomason C. Erythema multiforme occurring in association with lupus erythematosus during therapy with doxycycline. *Clin Exp Dermatol.* 1988;13:245-247.
 44. Albengres E, Guillaume J, Chevais M, Riant P, Touraine R, Tillement J. Recurrent erythema multiforme following successive treatments with tetracyclines: apropos of a case. *Therapie.* 1983;38:577-579.
 45. Curley R, Verbov J. Stevens-Johnson syndrome due to tetracyclines: a case report (doxycycline) and review of the literature. *Clin Exp Dermatol.* 1987;12:124-125.
 46. Wolkenstein P, Revuz J. Drug-induced severe skin reactions: incidence, management and prevention. *Drug Safety.* 1995;13:56-68.
 47. Chatham W, Ross D. Leukemoid blood reaction to tetracycline. *South Med J.* 1983;76:1195-1196.
 48. Nicolau D, Mengedot D, Kline J. Tetracycline-induced pancreatitis. *Am J Gastroenterol.* 1994;86:1669-1671.
 49. Schütz J, Adenson J, Workman W, Norman T. Fatal liver disease after intravenous administration of tetracycline in high dosage. *N Engl J Med.* 1963;269:993-1004.
 50. Schenker S. Tetracycline hepatotoxicity. *Mate Med Pol.* 1976;2:173-176.
 51. Meinhof W, Pasquale D, Jacoby W. Tetracycline-induced hepatic coma, with recovery: report of a case. *Obstet Gynecol.* 1967;29:260-265.
 52. Combes B, Whalley P, Adams R. Tetracycline and the liver. *Prog Liver Dis.* 1972;4:589-596.
 53. Naranjo C, Busto U, Sellers E, et al. A method for estimating the probability of adverse drug reactions. *Clin Pharmacol Ther.* 1981;30:239-245.
 54. Reboli A, Del Bene V. Oral antibiotic therapy of dermatologic conditions. *Dermatol Clin.* 1988;6:497-520.
 55. Ory E. The tetracyclines. *Med Clin North Am.* 1970;54:1173-1185.
 56. Allen J. Minocycline. *Ann Intern Med.* 1976;85:462-467.
 57. Taurig A, Dorris M, Doerge D. Minocycline and the thyroid: antithyroid effects of the drug, and the role of thyroid peroxidase in minocycline-induced black pigmentation of the gland. *Thyroid.* 1996;5:211-219.
 58. Shear N, Spielberg S. Anticonvulsant hypersensitivity syndrome: in vitro assessment of risk. *J Clin Invest.* 1988;82:1826-1832.
 59. Keams G, Wheeler J, Childress S, Letzig L. Serum sickness-like reactions to cefaclor: role of hepatic metabolism and individual susceptibility. *J Pediatr.* 1994;125:805-811.
 60. Domz C, McNamara D, Holzapfel H. Tetracycline provocation in lupus erythematosus. *Ann Intern Med.* 1989;50:1217-1226.
 61. Uetrecht J. The role of leukocyte-generated metabolites in the pathogenesis of idiosyncratic drug reactions. *Crit Rev Toxicol.* 1992;20:299-366.
 62. Hess E. Drug-related lupus. *N Engl J Med.* 1988;318:1460-1462.
 63. George D, Crawford D. Antibacterial-induced hepatotoxicity: incidence, prevention and management. *Drug Safety.* 1996;15:80-85.
 64. Derby L, Jick H, Henry D, Dean A. Cholestatic hepatitis associated with flucloxacillin. *Med J Aust.* 1993;158:595-600.
 65. Carson J, Strom B, Duff R, et al. Acute liver disease associated with erythromycin, sulfonamides, and tetracyclines. *Ann Intern Med.* 1983;119:576-583.
 66. Goulden V, Glass D, Cunliffe W. Safety of long-term high-dose minocycline in the treatment of acne. *Br J Dermatol.* 1996;134:693-695.
 67. Hanley J, Lippman-Hand A. If nothing goes wrong, is everything all right? interpreting zero numerators. *JAMA.* 1983;249:1743-1745.
 68. Cunliffe W. Doctors should not change the way they prescribe for acne. *BMJ.* 1996;312:1101.
 69. Singer S, Piazza-Hepp T, Girardi L, Moledina N. Lupuslike reaction associated with minocycline. *JAMA.* 1997;277:295-296.
 70. Kale S. Drug-induced systemic lupus erythematosus: differentiating it from the real thing. *Postgrad Med.* 1985;77:231-242.
 71. McDonald E, Marmo C. Drug-induced lupus. *Hospital Pract.* 1993;14.
 72. Gupta A, Eggo M, Uetrecht J, Shear N. Drug-induced hypothyroidism: the thyroid as a target organ in hypersensitivity reactions to anticonvulsants and sulfonamides. *Clin Pharmacol Ther.* 1992;51:56-67.
 73. Hubbard C, Hobbs F, Rist T, et al. Efficacy of minocycline compared with tetracycline in treatment of acne vulgaris. *Arch Dermatol.* 1982;118:389-392.
 74. Jinscoll M, Rothe M, Abrahamian L, Grant-Kels J. Long-term oral antibiotics for acne: is laboratory monitoring necessary? *J Am Acad Dermatol.* 1993;28:595-602.
 75. Ferner R, Moss C. Minocycline for acne. *BMJ.* 1996;312:138.
 76. Lehmerl L, Cooke J, Enck R. Tetracycline-induced aplastic anemia. *South Med J.* 1979;72:358-361.

Current Use and Future Potential Role of Retinoids in Dermatology

Constantin E. Orfanos, Christos C. Zouboulis, Brigitte Almond-Roesler and Christoph C. Geilen

Department of Dermatology, University Medical Center Benjamin Franklin, The Free University of Berlin, Germany

Contents

Summary	359
1. Vitamin A (Retinol), Natural Retinoids and the Skin	360
2. Synthetic Retinoids	361
2.1 Active Groups and Classification	361
2.2 Synthetic Retinoids in Current Use	361
3. Pharmacokinetic Properties and Clinical Relevance	362
3.1 Absorption and Distribution	362
3.2 Metabolism and Elimination	363
3.3 Epidermal Transport and Metabolism	364
4. Mechanisms of Action	364
4.1 Retinoid Receptors and Gene Regulation	364
4.2 Effects on Epidermal Cell Growth and Differentiation	365
4.3 Effects on Sebaceous Gland Activity and Epidermal Lipids	366
4.4 Immunomodulatory and Anti-Inflammatory Properties	367
5. Therapeutic Use	367
5.1 Psoriasis and Related Disorders	367
5.2 Other Disorders of Keratinisation	369
5.3 Seborrhoea, Acne and Acneiform Dermatoses	370
5.4 Retinoids in Skin Cancer	372
5.5 Miscellaneous Disorders	373
6. Adverse Reactions and Tolerability	374
6.1 Mucocutaneous Adverse Effects	374
6.2 Eye Symptomatology and Pseudotumour Cerebri	375
6.3 Serum Lipids and Liver Function	375
6.4 Bone Changes	375
6.5 Arthralgias and Myalgias	376
6.6 Teratogenicity	376
7. Clinical Monitoring	377
7.1 Monitoring of Clinical and Laboratory Parameters	377
7.2 Monitoring of Retinoid Bioavailability and Body Storage	378
8. Topical Treatment with Retinoids	378
8.1 Pharmacokinetics	378
8.2 Clinical Applications of Topical Retinoids	379
9. New Trends and Outlook for the Future	380

Summary

Since their introduction 15 years ago, retinoids have been increasingly used for topical and systemic treatment of psoriasis and other hyperkeratotic and parakeratotic skin disorders, keratotic genodermatoses, severe acne and acne-related dermatoses, and also for therapy and/or chemoprevention of skin cancer and other neoplasia. Oxidative metabolites of vitamin A (retinol) are natural retinoids present at low levels in the peripheral blood. Synthetic retinoids are classified into 3 generations including nonaromatic, monoaromatic and polyaromatic compounds. They are detectable in plasma 30-60 minutes after systemic administration, and reach maximum concentrations 2 to 4 hours later. Elimination half-life is 10 to 20 hours for isotretinoin, 80 to 175 days for etretinate and 2 to 4 days for *trans*-acitretin; the latter, however, partially converts into etretinate. Retinoid concentrations in skin are rather low in contrast to subcutaneous fat tissue.

Intracellularly, retinoids interact with cytosolic proteins and specific nuclear receptors. Two classes of nuclear receptors have been suggested to mediate retinoid activity at the molecular level, RARs and RXRs. The expression of retinoid receptors is tissue specific; skin mainly expresses RAR γ and RXR α . Retinoids affect epidermal cell growth and differentiation as well as sebaceous gland activity and exhibit immunomodulatory and anti-inflammatory properties.

Current retinoid research targets the development of receptor-selective retinoids for tailoring and/or improving their therapeutic profile. Currently, tretinoin is used systemically for acute promyelocytic leukaemia, etretinate and acitretin for psoriasis and related disorders, as well as other disorders of keratinisation, and isotretinoin for seborrhoea, severe acne, rosacea and acneiform dermatoses. Systemic retinoids are also applied for chemoprevention of epithelial skin cancer and cutaneous T cell lymphoma. The major adverse effect of retinoids is teratogenicity; all other adverse effects are dose-dependent and controllable. Contraception is, therefore, essential during retinoid treatment in women of child-bearing age. Clinical monitoring requires physical examination for adverse effects every 3 to 4 weeks and proper laboratory investigations, also including analysis of retinoid bioavailability in selected cases. Topical retinoids are rapidly developing at present and seem promising for the future; their clinical application includes acne, aging, photodamage, precanceroses, skin cancer and disorders of skin pigmentation. The development of receptor-specific retinoids for topical treatment of psoriasis and/or acne may lead to interesting new compounds based on our current concepts of retinoid function.

'Retinoids' is a generic term that includes both naturally occurring molecules and also synthetic compounds showing specific biological activities resembling those of vitamin A (retinol). Such compounds can exhibit their specific biological activity without being vitamin A analogues chemically, i.e. without showing 'four isoprenoid units joined in a head-to-tail manner,' as defined by the IUPAC-IUB (International Union of Pure and Applied Chemistry-International Union of Biochemistry) Joint

Commission on Biochemical Nomenclature.^[1]

Also, not all biologically active synthetic retinoids are carried by cytosolic binding proteins such as cellular retinol binding proteins (CRBP) or cytosolic retinoid acid binding proteins (CRABP), and binding to or activation of nuclear retinoid receptors may not be a necessary precondition for their action.

A series of natural and synthetic retinoids influence epithelial cell proliferation and epidermal dif-

ferentiation, and a few selected compounds also exert sebostimulatory effects. Based on these major properties, the group of retinoids were introduced in 1977/78 into dermatology^[2] and broad spectrum dermatological therapy was envisaged for the 1980s.^[3,4]

During the past decade, retinoids have been increasingly used (a) for treatment of hyperkeratotic and parakeratotic skin diseases, with or without dermal inflammation, and for a series of keratotic genodermatoses; (b) as a standard modality for treating severe acne and acne-related dermatoses; and (c) for treatment and/or chemoprevention of skin cancer and other neoplasia because of their immunomodulating activities, and their properties to promote differentiation and induce apoptosis, not only in epithelial tissues. The role of retinoids in oncology may potentially increase in the future.^[5]

1. Vitamin A (Retinol), Natural Retinoids and the Skin

Vitamin A and its 2 metabolic derivatives, retinaldehyde and retinoic acid, are fat-soluble unsaturated isoprenoids necessary for growth, differentiation and maintenance of epithelial tissues, and also for reproduction. In a reversible process, vitamin A is oxidised *in vivo* to give retinaldehyde, which is important for vision. The normal plasma level of vitamin A in humans is 0.35 to 0.75 mg/L.^[6]

Retinoic acid is a major oxidative metabolite of vitamin A, and can substitute for vitamin A in vitamin A-deficient animals in growth promotion and epithelial differentiation. However, it cannot be a substitute in completely maintaining reproduction. The stereoisomers all-*trans*-retinoic acid and 13-*cis*-retinoic acid are normal constituents of human serum.^[7] Unlike the vitamin A esters which are stored in the liver, retinoic acid is not stored but is rapidly excreted. The normal levels in human plasma are 0.55 to 1.20 µg/L for all-*trans*-retinoic acid and 0.80 to 2.40 µg/L for 13-*cis*-retinoic acid.^[8]

Table 1. Some synthetic first and second generation retinoids

Retinoid	Remarks
First generation: nonaromatic retinoids	
Retinyl palmitate	Included in cosmetic preparations
Retinyl aldehyde	Included in cosmetic preparations
Tretinoin (all- <i>trans</i> -retinoic acid)	Most-studied retinoid: active systemically in acute myeloid leukaemia
Isotretinoin (13- <i>cis</i> -retinoic acid)	Sebostimulatory, anti-inflammatory action; best agent for acne
9- <i>cis</i> -Retinoic acid	RXR-ligand; less active retinoid
α-14-Hydroxy-retinoinol	Sustains B cell growth and T cell activation
Fenretinide [N-(4-Hydroxyphenyl)-retinamide]	Studied in chemoprevention trials
E 5166 (polyprenic acid)	Studied in chemoprevention trials
Second generation: monoaromatic retinoids	
Etretinate	Psoriasis, disorders of keratinization
Acitretin	Psoriasis, disorders of keratinization
Isocitretin (13- <i>cis</i> -acitretin)	Inactive (?) acitretin metabolite
Motretinide	Mild topical agent

Abbreviation: RXR = retinoid X receptor.

Endogenous retinoids are unlikely to be involved in the pathogenesis of common skin diseases, such as acne and psoriasis.^[6,8] In contrast, hypervitaminosis A is associated with a broad spectrum of symptoms resembling the mucocutaneous adverse effects of oral treatment with synthetic retinoids. In humans, 0.8 to 1 mg or 2400 to 3000 IU of vitamin A is required per day (1 IU = 0.3 mg). However, vitamin A intoxication may occur when daily dietary intake of vitamin A exceeds 18 000 to 60 000 IU/day in children and 50 000 to 100 000 IU/day in adults, given over a period of several months.^[9] With restricted liver metabolic capacity, symptoms of intoxication may appear much earlier, within a few months and when smaller doses are taken (10 000 IU/day).

Hypervitaminosis A is signaled by an increase in vitamin A ester levels (normal value is 5 to 8% of vitamin A value) in serum. The vitamin A values rarely increase. Pregnant women and women of childbearing age should not exceed an oral vitamin A intake of 8000 to 10 000 IU/day.

2. Synthetic Retinoids

2.1 Active Groups and Classification

In the search for more biologically active and less toxic compounds, all 3 portions of the vitamin A molecule have been chemically modified.^[10] Three generations – nonaromatic, monoaromatic and polyaromatic retinoids – are known today^[11,12] (see tables I and II).

It was found early on that alterations of the polyene chain may diminish retinoid-activity. Modifications and/or esterification of the carboxylic end group are often associated with reduced toxicity while biologic activity is maintained or even enhanced. Substitutions for the ring were found to yield less toxicity with a marked increase of the biological activity of the molecule. In further developmental work, additional aromatic rings were introduced; some new retinoids barely resemble the original vitamin A molecule, such as the naphthalenecarboxylic acids derivatives,^[10] adapalene^[13,14] (see Adis Drug Evaluation later in this issue^[262]) or tazarotene.^[15]

The discovery of nuclear retinoid receptor protein families and the identification of tissue/cell specificities have led to new concepts such as receptor-selective retinoids; agonists, neutral antagonists and inverse agonists,^[16] with the aim of targeting their action, thus improving the overall

therapeutic profile. However, the existence of retinoids which are biologically active without binding to retinoid transport proteins and to specific nuclear receptors may interfere with this concept.

2.2 Synthetic Retinoids in Current Use

All-*trans* retinoic acid (tretinoin) was the first retinoid to be synthesised. Although this compound is now established for topical therapy, its systemic use did not reveal significant advantages over vitamin A. However, recently the drug showed beneficial effects in acute promyelocytic leukaemia.

13-*cis*-Retinoic acid (isotretinoin) is an extremely effective drug if given systemically in severe forms of acne. It has marked sebostatic activity after oral intake but its topical use strongly diminishes or cancels out sebosuppression. Compared with topical tretinoin, topical isotretinoin and also retinaldehyde exhibit almost identical biological activities, with the exception of a less pronounced irritative effect;^[17,18] in addition, vitamin A palmitate is used as an ingredient in cosmetic preparations.

When the first monoaromatic compound, etretinate, was developed, a real breakthrough in the treatment of severe psoriasis and other dermatoses was achieved. The better ratio between therapeutic efficacy and adverse effects resulted in its widespread clinical use. Its free acid metabolite, acitretin, was later found to be similarly effective, with a much shorter elimination half-life ($t_{1/2}$) that was advantageous for therapeutic use. The fact that re-esterification *in vivo* may convert acitretin into etretinate, however, cancelled out its major advantage when compared to its precursor. Motretinide, an ethylamide of the aromatic compound, is also available in Europe for topical treatment.

Polyaromatic retinoids, also called arotinoids, represent the third synthetic retinoid generation. These compounds have been in animal and clinical research for 15 years, but it was only recently that two of them were almost simultaneously introduced for topical treatment of acne (adapalene)^[19]

Table II. Arotinoids (third generation retinoids) introduced into phase 1 studies and partly in clinical use

Temarotene (Ro 15-0778; nonpolar parent compound)	Apparently inactive
Arotinoid acid (Ro 13-7410)	Activity profile still unknown
Arotinoid ethyl ester (Ro 13-6298)	Potent antipsoriatic agent; also active in keratinising disorders and cutaneous T cell lymphoma?
Arotinoid ethyl sulphone (Ro 15-1570)	Antipsoriatic properties
Arotinoid methyl sulphone (Ro 14-9706)	Activity profile still unknown
Adapalene (CD 271)	Antiacne agent (topical)
Tazarotene (AGN 190168)	Antipsoriatic agent (topical)

Table III. Pharmacokinetic properties of etretinate, *trans*-acitretin and isotretinoin

Parameter	Etretinate	<i>trans</i> -Acitretin	Isotretinoin
Bioavailability	40% (range 30-70%)	20-90%	25%
C _{max}	237-1403 µg/L Dose 50-70mg	196-728 µg/L Dose 50mg	366 ± 159 µg/L Dose 80mg
t _{max}	2-3h	1-4h	3h (1-4h)
Elimination half-life	80-175 days	2-4 days	10-20h
Metabolites	<i>trans</i> -acitretin, 13- <i>cis</i> -acitretin	13- <i>cis</i> -acitretin, etretinate	4-oxo- isotretinoin

Abbreviations: C_{max} = maximum plasma concentration; t_{max} = time to C_{max}.

and psoriasis (tazarotene).^[15] There is increasing evidence that others will follow.

3. Pharmacokinetic Properties and Clinical Relevance

Oral retinoids have been administered for the treatment of skin disease for more than 25 years,^[20] and established preparations are available for dermatological use today. Because of their teratogenic properties, however, considerable concern has been raised during the past decade, requiring a better understanding of their pharmacokinetics (table III) and the relevance of circulating retinoid blood concentrations.^[21-24]

3.1 Absorption and Distribution

The bioavailability of oral isotretinoin is approximately 25%, and can be increased by food 1.5- to 2-fold. After 30 minutes the drug is detectable in the blood, and maximum concentrations are reached 1 to 4 hours after oral intake. In some cases, secondary and tertiary concentration maxima consistent with an enterohepatic circulation may occur.

The main metabolite, 4-oxo-isotretinoin (fig. 1) is present in plasma in a 2- to 4- fold higher concentration 6 hours after a single dose, and steady-state concentrations are reached after 1 week. The t_{1/2β} of isotretinoin ranges from 10 to 20 hours while that of its metabolites ranges from 11 to 50 hours. Isotretinoin crosses the placenta.^[25,26]

The aromatic retinoid ethylester etretinate readily hydrolysed after oral intake to its free carboxylic acid, acitretin, in a *cis-trans*-isomer form. Its bioavailability is about 40%, with large interindividual variations, since retinoid absorption from the gut is enhanced by fat-rich food. In plasma, most synthetic retinoids are bound to lipoproteins; only less than 2% of etretinate circulates as free drug.

One hour after oral administration, etretinate *trans*-acitretin and 13-*cis*-acitretin (fig. 2) can be detected in plasma, reaching maximal levels in 2-4 hours. Remaining amounts of the parent ester compound are stored in the subcutaneous fat compartment, with slow elimination characteristics and a t_{1/2β} of 80 to 175 days after multiple doses. The plasma concentrations during a long term washout period (more than 2 years) are extremely low, but most likely therapeutically ineffective, but potentially teratogenic.^[27] Interestingly, overweight patients tend to have slower elimination rates, maintain higher serum concentrations, and clear etretinate later.^[28]

From the clinical point of view, teratogenicity is the major issue in retinoid treatment because nearly all known retinoid compounds will be transferred through the placenta and be secreted in breast milk as shown in animal studies.^[26,29,30]

Trans-acitretin has a much shorter t_{1/2β} than etretinate – about 2 to 4 days following cessation of

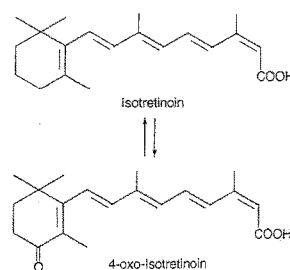


Fig. 1. Isotretinoin and its metabolite 4-oxo-isotretinoin.

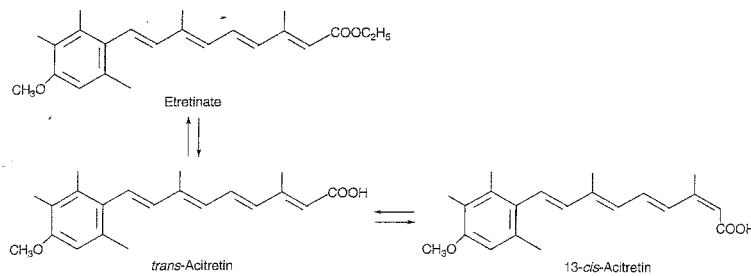


Fig. 2. Etretenate and its metabolites *trans*-acitreten and 13-*cis*-acitreten.

treatment. Similar to other retinoids, *trans*-acitreten is incompletely absorbed, with its oral bioavailability ranging from 20 to 90%. Absorption increases when the drug is administered with food,^[31] and more than 99% of the absorbed drug binds to plasma proteins.^[32]

Trans-acitreten and its metabolite 13-*cis*-acitreten are interconverted, and the individual role of the 2 metabolites in the overall therapeutic effect has not been fully clarified. Steady-state plasma concentrations of *trans*-acitreten are reached within 1 to 2 weeks. One month after cessation of a 2- to 7-month treatment period, the residual plasma concentrations of *trans*- and *cis*-acitreten remain below the detection limit, and the risk for teratogenicity appears minimised.^[33]

3.2 Metabolism and Elimination

The major metabolites of isotretinoin in blood are 4-hydroxy- and 4-oxo-isotretinoin, while several glucuronide conjugates are detectable in the bile.^[34] Since there is interconversion between the 2 isomers isotretinoin and tretinoin *in vivo*, about 10 to 30% of the drug is metabolised via tretinoin. Excretion of isotretinoin occurs after conjugation with the faeces or after metabolism with the urine. The potential clinical activity of the isotretinoin metabolites, including the glucuronides, is under ongoing research.

The metabolism of etretinate includes its hydrolysis to *trans*-acitreten, isomerisation to 13-*cis*-acitreten, oxidation to more water-soluble compounds, and conjugation to glucuronides, followed by biliary excretion: only a small part is excreted via the urine. Pharmacological studies indicate that etretinate may be acting as a prodrug for *trans*-acitreten, but when esterase is added to an *in vitro* system the 2 compounds are equipotent.

While etretinate has a $t_{1/2}$ of 100 days, *trans*-acitreten has a $t_{1/2}$ of only 2 to 4 days.^[32] The latter is metabolised into at least 4 compounds,^[35] one of which is 13-*cis*-acitreten.^[36,37] Because of their polar carboxylic acid group, *trans*- and 13-*cis*-acitreten are less likely than etretinate to accumulate in subcutaneous tissue. Both are widely distributed and are excreted in faeces and urine.

Administration of *trans*-acitreten instead of etretinate was therefore considered as a preferable therapeutic option in psoriasis,^[38-40] based on the assumption that a shorter period of contraception would be advantageous for women. However, partial *in vivo* conversion of *trans*-acitreten into etretinate has been described *in vivo*, and etretinate at concentrations of 5 to 100 $\mu\text{g/L}$ was recently detected in patients treated with oral *trans*-acitreten.^[41,42] Re-esterification does take place under varying conditions in healthy volunteers and patients with psoriasis, as well in animal models and *in vitro*.^[43] Alcohol appears to be an important

contributing factor for the formation of etretinate, but oral intake of alcohol is not a necessary precondition for re-esterification.^[44,45]

3.3 Epidermal Transport and Metabolism

Epidermal concentrations of isotretinoin are rather low,^[46] and no progressive accumulation in serum, epidermis or the subcutis has been found. After discontinuation of therapy, isotretinoin disappears from serum and skin within 2 to 4 weeks. It seems likely that isotretinoin therapy interferes with the endogenous metabolism of vitamin A in the skin because vitamin A levels increased by about 50% and dihydrovitamin A levels decreased by around 80% in some patients.^[46]

Etretinate appears in human epidermis shortly after oral administration. Therapeutic levels are reached within 7 to 10 days, with no evidence of accumulation even after further oral intake. The concentrations are similar in lesional and in non-lesional skin, and also in plasma of patients with psoriasis.

The amount of etretinate and *trans*-acitretin^[47] has little effect on endogenous vitamin A metabolism in skin. When treatment is discontinued, epidermal etretinate decreases rapidly, and mucocutaneous adverse effects associated with high blood drug concentrations disappear in a few days. The drug, however, accumulates in the subcutaneous fat tissue, reaching levels 20 to 30 times higher than those in the epidermis.^[30]

The tissue distribution of etretinate is widespread, including the adrenals and several other organs in low concentrations. Interestingly, adipose tissue contains almost exclusively etretinate, whereas in the liver *trans*-acitretin predominates. *trans*-Acitretin concentrations in subcutaneous fat varied from 15 to 1437 µg/L.^[47,48] Relatively low concentrations of both drugs were detected in suction blister fluid at steady-state, indicating that only minor proportions are free to diffuse outside the vascular space.^[42]

4. Mechanisms of Action

Although vitamin A is assumed to enter the cells by non-receptor-mediated endocytosis, the exact mechanisms of retinoid-induced phenomena, including membrane-associated signal transduction, need to be elucidated.^[49,50] Intracellularly, retinoids interact with cytosolic proteins^[49,50,52] and nuclear receptors.^[49,51,53,54] They induce expression of genes which bear specific DNA sequences recognising the retinoid/receptor complex. These pathways have been well investigated for all-*trans* retinoic acid but they may not be valid for all retinoids.

4.1 Retinoid Receptors and Gene Regulation

Two classes of nuclear retinoid receptors were suggested to mediate retinoid activity at the molecular level [retinoic acid receptors (RARs) and retinoid X receptors (RXRs), members of the steroid-thyroid hormone superfamily. They act as ligand-dependent transcriptional factors. RARs can bind both all-*trans* and 9-*cis*-retinoic acid with high affinity, while RXRs selectively interact with 9-*cis*-retinoic acid. In contrast, 13-*cis*-retinoic acid shows low affinity for RARs. 14-Hydroxy-retroretinol, which specifically induces lymphocyte proliferation, does not bind to or activate retinoid receptors,^[53] acitretin does not bind to but activates RARs, and Ro 40-1349 binds to but does not activate RARs.^[53] These controversial data indicate the existence of other, unknown signalling pathways for retinoid action (table IV).

Recently, RAR α , RAR β and RAR γ have been identified as being encoded by distinct genes mapped on respective chromosomes 17q21.1, 3p24 and 12q13.^[56-58] Each RAR gene generates multiple isoforms. The human RXR family also includes 3 members, RXR α , RXR β and RXR γ ; their genes are mapped on chromosomes 9q34.3, 6p21.3 and 1q22-23, respectively.^[59,60]

The expression of RARs is tissue-specific. Abundant expression of RAR γ and RXR α , low

Table IV. Nuclear and cytosolic receptor binding of synthetic retinoids

Compound	Binding affinity EC ₅₀ (see key below)		
	RARs	RXR _s	CRABP
Agonists			
all- <i>trans</i> -Retinoic acid	1($\alpha = \beta = \gamma$)	4	1
9- <i>cis</i> -Retinoic acid	1($\alpha = \beta = \gamma$)	2	3
4-Oxo-retinoic acid	3		
4-Hydroxy-retinoic acid	4		
E-5186 (polyprenoic acid)	2		2
Arotinoic acid	1		2
CD-367	1		< 1
TTNPB	2($\beta = \gamma > \alpha$)		
LGD-1069 (retinoid oxime)	4	2	
LG-100268	4	2	
Selective agonists			
Am580 (Ro40-6055)	2(α), 4(β, γ)	3	
Adapalene	2(β), 3(γ), 4(α)	—	
Tazarotenic acid	2(β), 3(γ), 4(α)	—	
TTNN (Ro 19-0645)	2(β), 3(α)		
CD-437 (AHPN)	2(γ), 4($\beta > \alpha$)		
CD-2325	2(γ), 4($\alpha = \beta$)		
Ro 26-4453	—	2(α)	
AGN-191701	—	RXR _s	
SR-11217	—	RXR _s	
SR-11237	—	RXR _s	
Antagonists			
Ro 41-5253	RAR α		
AGN-193109	1 ($\alpha = \beta = \gamma$)		
Active compounds without affinity for receptors			
Vitamin A (retinol)	4		3
13- <i>cis</i> -Retinoic acid	3 ^a	—	—
α -14-Hydroxy-retinoic acid	—	—	—
Etretinate	—	—	—
Acitretin	—	—	3
Arotinoid ethyl ester	—	—	—
Arotinoid ethyl sulphone	—	—	—
CD-2398	—	—	—
Anti AP-1-selective compounds			
SR-11327	RAR α > RAR β	RXR <	
	> RAR γ	RAR γ	
SR-11238	RAR β > RAR γ	RXR <	
	> RAR α	RAR γ	
		RAR γ >	
		RXR >	
		RAR α	

a. controversial results, moderate or no binding reported.

Abbreviations and symbols: CRABP = cellular retinoic acid binding protein; EC₅₀ = concentration binding 50% of the receptors; RAR = retinoic acid receptor; RXR = retinoid X receptor; 1 = ≤ 10 nmol/L; 2 = ≤ 100 nmol/L; 3 = ≤ 1000 nmol/L; 4 = ≤ 10000 nmol/L; — = inactive.

amounts of RAR α and no RAR β were shown in normal and psoriatic human epidermis.^[51,61]

Retinoid receptors regulate the transcription of genes bearing short DNA sequences in their promoter regions, known as retinoid-responsive elements (RAREs and RXREs). They are bound by receptor heterodimers (RXR/RAR) or homodimers (RXR/RXR) with higher affinity than for individual receptors.^[62] All-*trans* retinoic acid has been shown to induce several genes bearing retinoid-responsive elements.

Three retinoid receptor/target gene interactions are of particular interest. First, a positive feedback mechanism: all 3 RAR genes contain a retinoid-responsive element and the autoinduction of RAR expression in some tissues could lead to a potential amplification of retinoid effects.^[53] Secondly, a negative feedback mechanism: retinoic acid-induced overexpression of CRABP-I in F9 mouse teratocarcinoma cells led to reduction of a certain subset of retinoic acid-responsive genes. Possibly, retinoid-binding proteins may antagonise retinoid interaction with nuclear receptors.^[63] Thirdly, interaction with other signal transduction mechanisms: interaction with transcription factors activated by other signal transduction mechanisms, e.g. AP-1,^[64] may produce specific retinoid effects. Retinoids with selective inhibition of AP-1 were shown to reduce F9 teratocarcinoma cell growth without influencing cell differentiation.^[65]

These interactions become more complicated since in addition to RAR agonists, RAR neutral antagonists and RAR inverse agonists have been synthesised.^[16] Inverse agonists bind to RARs and repress their basal transcriptional activity. Neutral antagonists do not change the basal activity of RARs but can inhibit the transcriptional activation effects of agonists as well as the transcriptional repression effects of inverse agonists.

4.2 Effects on Epidermal Cell Growth and Differentiation

Retinoids act as modulators of epidermal growth and supervisors of differentiation. They promote cell proliferation in normal epidermis,

both topically and systemically, but act towards normalisation in hyperproliferative epithelia. Psoriatic keratinocytes are down-regulated by retinoids. *In vitro*, retinoic acid has been shown to either stimulate or inhibit epidermal keratinocyte proliferation, depending on the growth-culture conditions.

Possibly, retinoids induce and modulate the expression of growth factors and their receptors. Stimulation of keratinocyte proliferation is associated with induction of cyclic adenosine monophosphate (cAMP), epidermal growth factor (EGF) receptor binding, protein kinase C (PKC) and transforming growth factor (TGF)- α , while TGF- β_2 -regulated inhibition of EGF binding to its receptor leads to down-regulation of cell growth.^[66,67] The effect of retinoic acid on EGF receptor binding is on a region of the EGF promoter, regulated by RAR γ .

Parallel to these effects, retinoids are known to alter terminal differentiation towards a non-keratinising, metaplastic, mucosa-like epithelium.^[68] The glycosylation pattern of normal skin treated with retinoic acid resembles that of a mucosal epithelium,^[69] with a reduction of tonofilaments, decreased corneocyte cohesiveness, impaired function of the permeability barrier, and increased transepidermal water loss, thus explaining the keratolytic effect of retinoids in hyperkeratotic disorders. In contrast, oral and topical retinoids stimulate and maintain terminal differentiation of human epidermal cells, e.g. in the psoriatic plaque.

In vitro, most markers of terminal differentiation (loricrin, transglutaminase, involucrin, filaggrin, keratins 1 and 10) are down-regulated by retinoic acid in a dose-dependent manner. Keratins 19 and 13, markers of nonstratified and wet stratified epithelia, respectively, are induced by retinoic acid.^[68,70] In contrast, natural retinoic acid concentrations (10^{-9} to 10^{-8} mol/L) restored the architecture of the 'epidermis' in the air-medium interface model, which exhibited excessive hyperkeratosis in vitamin A-depleted medium.^[71] Adapalene induced similar effects in this model, despite its dif-

ferent receptor affinity and its inability to bind to CRABP.^[72]

The involvement of retinoid receptors in the modulation of proliferation and differentiation of malignant epithelial tissue was investigated on T47D breast carcinoma ER+ cells *in vitro* (W. Bollag, personal communication). RAR α -selective agonists, but not RAR β , RAR γ and RXR α agonists, inhibited T47D cell growth and induced differentiation. Addition of an RAR α antagonist neutralised the RAR α agonist effects. In contrast, all retinoids induced apoptosis of MCF7 breast carcinoma ER+ cells *in vitro*.

4.3 Effects on Sebaceous Gland Activity and Epidermal Lipids

Isotretinoin is the most effective drug in reducing sebaceous gland size (up to 90%) by decreasing proliferation of basal sebocytes and suppressing sebum production *in vivo*. Marked decrease of wax esters, a small decrease of squalene and a relative increase in cholesterol level have been detected in skin surface lipids. Oral isotretinoin has also been shown to decrease triglyceride fraction, whereas free sterols and total ceramides were increased in comedonal lipids.^[3] All-*trans*-retinoic acid and 9-*cis*-retinoic acid were recently found to be less effective than isotretinoin in sebum suppression.^[73,74]

Current *in vitro* studies have confirmed the pronounced, direct inhibitory effects of isotretinoin on proliferation and lipid synthesis of human sebocytes *in vitro*,^[75-77] controlling their differentiation and antigen expression.^[78] The molecular basis for this antisebotrophic activity has not been elucidated, but the cyclohexenyl ring may be necessary for pronounced sebum suppression. Since isotretinoin has low affinity for nuclear retinoid receptors and retinoic acid-binding proteins, it is likely that sebosuppression is not a directly receptor-mediated retinoid effect. Arotinoids may enhance the antikeratinising activity when bearing a carboxylic acid end group but abolish the sebosuppressive activity in humans.

4.4 Immunomodulatory and Anti-inflammatory Properties

There is some early information concerning the activity of retinoids on immunomodulatory dermal processes.^[79-84] In a more recent *in vitro* study, isotretinoin, etretinate and acitretin were shown to inhibit the proliferation of dermal microvascular endothelial cells, without influencing the expression of human leucocyte antigen (HLA)-DR and intercellular adhesion molecule (ICAM)-1.^[85]

The inhibition of angiogenesis was further investigated in T47D cell-induced tumours (W. Bollag, personal communication). All retinoids tested inhibited angiogenesis, independent of their receptor selectivity, but addition of an RAR α antagonist neutralised the angiostimulatory retinoid effect.

Retinoids are generally thought to stimulate humoral and cellular immunity, although immunoinhibitory effects have been also described. 14-Hydroxy-retro-retinol, a natural retinoid, was identified to be an essential growth factor for lymphoblastoid cells.^[86] Retinoids can enhance antibody production, increasing peripheral blood T helper cells but not natural killer cells. Topically applied tretinoin was shown to prevent Langerhans cell depletion from human epidermis due to UV light,^[87] suggesting that normalisation of Langerhans cell distribution in psoriatic skin during systemic etretinate treatment may be a direct retinoid effect.

Cell surface antigens of T cells and natural killer cells have been reported to increase after retinoid exposure *in vitro*.^[88] Interaction of retinoids and cytokines has been suggested, because of the stronger differentiation response of HL-60 cells to combined tretinoin and cytokines, especially interferon (IFN)- γ .^[89] At the molecular level, the modulation of RAR α gene expression in chicken T lymphocytes by vitamin A and tretinoin indicates that antigen-specific proliferative responses of T lymphocytes may be directly influenced by tretinoin via modulation of RAR α expression.^[90]

Retinoids exhibit anti-inflammatory activity. The loss of neutrophil migration from dermal cap-

Table V. Topical and systemic retinoids in clinical use

Retinoid	Concentration/vehicle	Indications
Topical		
Retinyl palmitate	0.5-5% emulsions	Cosmetic agents
Retinyl aldehyde	0.05% cream	Cosmetic agents
Tretinoin	0.025%-0.1% creams, 0.05-0.1% solutions, 0.025-0.05% gels	Mild forms of acne, photodamaged skin, skin aging
Isotretinoin	0.05% gel	Mild forms of acne
Motretinide	0.1% cream, 0.1% solution	Mild forms of acne
Adapalene	0.1% gel	Mild form of acne
Tazarotene	0.05-0.1% gels	Psoriasis
Systemic		
Tretinoin		Acute promyelocytic leukaemia
Isotretinoin		Severe acne and acne-related dermatoses
Etretinate		Psoriasis, genokeratoses
Acitretin		Psoriasis, genokeratoses

illaries to the epidermis in psoriatic skin with oral etretinate/acitretin or topical retinoid therapy is well documented.^[80,81] In addition, topical isotretinoin was found to be more potent in inhibiting leukotriene B₄-induced migration of polymorphonuclear cells into human skin than tretinoin and arotinoids.^[91] Isotretinoin and tretinoin inhibited nitric oxide and tumour necrosis factor (TNF)- α production by human keratinocytes, and reduced inducible nitric oxide synthase mRNA levels.^[82]

5. Therapeutic Use

The clinical use of several retinoids is now well established^[92-94] (see table V).

5.1 Psoriasis and Related Disorders

Several attempts have been made in the past to treat psoriasis systemically, including the use of arsenic, corticosteroids, methotrexate, psoralens, cyclosporin and other cytotoxic drugs. The topical and also the oral application of retinoic acid and

the first synthetic derivatives was reported by our group as early as 1972.^[95-97]

Today, oral retinoids represent the mainstream of systemic antipsoriatic treatment, particularly in severe pustular and erythrodermic types. Etretinate/acitretin are superior to isotretinoin in their antipsoriatic action. They are administered alone or in combination with other modalities (mild corticosteroids, dithranol, tar) and/or with phototherapies (UVB or PUVA).^[93,98-100]

In plaque-type psoriasis the lesions slowly enlarge, flatten and gradually disappear with oral etretinate/acitretin therapy. The drugs seem appropriate both for initial treatment and for maintenance in low dosage. In pustular types (type Zumbusch, psoriasis inversa, acrolocalised suppurative pustulosis Hallopeau) it was recognised early that oral etretinate/acitretin is the treatment of first choice.^[101] including palmoplantar pustulosis^[102] as a variant.

In pityriasis rubra pilaris,^[103] clinical experience has been somewhat contradictory, but overall there is a beneficial effect, particularly in juvenile types of the disease. In a recent review, the early use of oral retinoids in this variant was seen as offering the best available chance for clearing.^[104]

5.1.1 Antipsoriatic action

The antipsoriatic action of retinoids is not fully understood. Their cutaneous effects are rather non-specific and, therefore, a large spectrum of disorders of keratinisation respond. It seems that the monoaromatic retinoids of the second generation:

- reduce the proliferation rate in acanthotic epidermis by downregulating the number of cycling cells;
- promote terminal differentiation and filaggrin synthesis in malpighian keratinocytes;
- regulate desquamation of the corneocytes restoring normal transglutaminase activity levels.

Their dermal effects consist of modulation of lymphocyte functions and inhibition of neutrophilic migration. Psoriatic inflammation gradually ceases after long term oral treatment over 6 to 12 weeks. It is now well accepted that retinoids work slowly but reliably in psoriasis if the dosage is cor-

rect and the patients remain under careful supervision.

5.1.2 Dosage and Interactions

The dosage required for antipsoriatic treatment is 0.3 to 1.0 mg/kg/day etretinate or acitretin, administered in 1 or 2 daily doses with meals.^[105] The gold standard remains 0.5 to 0.6 mg/kg/day given over a period of 6 to 12 weeks. Drug absorption increased 2- to 5-fold, and is more consistent taken with fatty foods. The initial dose level varies individually according to the needs of the patient, type of the disease, previous treatments and concomitant drug intake.

Retinoid monotherapy is preferred and is always recommended by us, because of various interactions of retinoids, e.g. with ketoconazole, phenytoin, carbamazepine, barbiturates, tetracyclines, aspirin and most likely also with other nonsteroidal anti-inflammatory drugs. No interaction of acitretin with phenprocoumon has been found.^[106] Also, retinoids do not interfere with contraceptive efficacy.^[107]

A major advantage of retinoids in psoriasis disorders of keratinisation is that they act synergistically with other common treatments, such as topical corticosteroids, dithranol, tar and also UVB phototherapies. In combined schedules oral dosage of etretinate or acitretin can be reduced to 0.3 to 0.5 mg/kg/day, thus minimising their adverse effects. The RePUVA (retinoid + PUVA) technique is considered today as a most effective treatment modality for recalcitrant severe psoriasis;^[108,109] over 80 to 90% of all cases can be cleared after 20 to 30 UV sessions and response can be maintained on low-dose oral retinoid treatment. The rate of relapse after withdrawal of therapy however, is 20 to 50% during the first 6 months, comparable to dithranol and UVB treatment. Also, the combinations of topical dithranol and selective UV phototherapy (ReSUP) have been recognised, and are well accepted for treatment of widespread psoriasis (table VI).

5.1.3 Etretinate/Acitretin

In randomised studies comparing the antipsoriatic potential of etretinate with acitretin, o

slight differences concerning efficacy (30 to 50% complete remission of moderate to severe plaque-type psoriasis within 4 to 8 weeks; 71 to 83% marked or complete remission after 12 weeks) and relapse rates (46.7% vs 40.6%, respectively) were registered.^[38,39,111] Etretinate concentrations may persist in plasma after changing therapy to acitretin.^[112] However, the adverse effect profile of acitretin appeared more pronounced at dosage levels exceeding 35 to 40 mg/kg/day. Mucocutaneous adverse effects such as xerosis, palmoplantar desquamation and hair loss were seen at higher rates with acitretin. Thus, most investigators limit the dosage of acitretin to ≤ 40 mg/day: in lamellar ichthyosis ≤ 25 mg/day acitretin was found preferable.^[113] We usually recommend administration of acitretin in 2 daily doses to avoid maximal peaks of absorption and, therefore, increased toxicity.

Since carboxylic acids are not stored in subcutaneous tissue but are more rapidly metabolised, it was originally thought that acitretin would replace etretinate in clinical practice; however, the therapeutic/toxicological profile of etretinate is less pronounced (e.g. adverse effects appear more slowly) and re-esterification does take place *in vivo*, with or without presence of alcohol.^[44,114,115] Both drugs are now in clinical use, and long term contraception over 2 years after drug withdrawal

Table VI. Established treatment of psoriasis with etretinate/acitretin alone or in combination with other modalities. Other combinations of oral etretinate/acitretin with methotrexate, cyclosporin, hydroxycarbamide (hydroxyurea)^[116] etc. do not seem recommendable, even if they work, because of increased toxicity

Plaque-type psoriasis
Monotherapy (or with topical dithranol): 0.5-1.0 mg/kg/day for 4-12wk
Combination with UVB (ReUVB, ReSUP): 0.3-0.5 mg/kg/day for 6wk
Combination with psoralen and UVA (PUVA) [RePUVA]: 0.3-0.5 mg/kg/day for 4-6wk
Erythrodermic psoriasis
Low initial dosage, slowly increasing up to 0.5-0.6 mg/kg/day over 3mo. Maintenance then required for 6mo
Pustular psoriasis
High initial dosage, slowly decreasing to 0.5-0.6 mg/kg/day over 3-6mo. Maintenance then required for 6-12mo

for women of child bearing age is required for both (see section 6.6).

5.2 Other Disorders of Keratinisation

Oral retinoids of the first and second generation including isotretinoin, etretinate and acitretin are effective in several disorders of keratinisation,^[93,116-119] since their action in promoting keratinocytic differentiation is not specific for psoriasis.

Oral retinoids have been shown to normalise hyperkeratotic and dyskeratotic conditions, and to reduce scaling in severe keratotic genodermatoses. Clearing is not complete, but the overall improvement of skin appearance and function justifies their use. Darier's disease,^[120] ichthyosis vulgaris, congenital ichthyosis (particularly the dry lamellar type), various types of palmoplantar keratodermas, and also erythrokeratoderma figurata variabilis (Mendes da Costa) respond well or very well to etretinate/acitretin and represent standard indications for initiating oral retinoid treatment.^[116,117,121] Etretinate or acitretin can be used in these conditions, whichever is available.

Isotretinoin appears inferior to the aromatic compounds because its strong sebostatic action may dry out the skin and cause physical discomfort. In most cases, treatment with a low initial dosage (0.3 to 0.6 mg/kg/day) is preferred in these indications for avoiding mucocutaneous adverse effects such as retinoid dermatitis, intertriginous maceration, oozing and also increased bulla formation, e.g. in epidermolytic hyperkeratosis. Of course, in these disorders treatment with minimal doses is life-long, since the genetic disease itself remains intractable. Therefore, teratogenicity and bone toxicity of oral retinoids should be monitored and controlled carefully in the mostly younger patient group.

Other rare keratotic diseases, such as ichthyosis hystrix, hyperkeratotic verrucous naevi, keratosis lichenoides chronica etc., may respond to standard oral retinoid doses to some degree, producing a reduction of hyperkeratosis and skin smoothening. Because of the rarity of such entities, however,

overall experience is still restricted to a limited number of cases. Finally, in porokeratosis Mibelli of the classical type, inflammatory linear verrucous epidermal naevi (ILVEN), pachyonychia congenita, Netherton's syndrome and monilethrix, the retinoid effect appears to be unsatisfactory.

5.3 Seborrhoea, Acne and Acneiform Dermatoses

5.3.1 Seborrhoea

Systemic isotretinoin is today the regimen of choice in severe seborrhoea, since it reduces sebocyte lipid synthesis by 75% with daily doses as low as 0.1 mg/kg, and by 90% with 0.3 to 0.5 mg/kg after 4 weeks. No other known agent can influence sebum production to the same extent. In addition, the number of proliferating sebocytes and the size of sebaceous glands decreases by 90% of the pretreatment values. In a recent double-blind trial, 9-*cis*-retinoic acid [0.3 mg/kg/day (20 mg/day)] was inferior to isotretinoin at the same dosage in 26 healthy volunteers, who had a high sebum excretion rate, after 4 weeks (37% sebum decrease with 9-*cis*-retinoic acid vs 91% with isotretinoin).^[73] In another trial involving 12 healthy volunteers, oral tretinoin [0.26 mg/kg/day (20 mg/day)] did not affect sebum excretion rates.^[74]

Current *in vitro* studies have confirmed the pronounced, direct inhibitory effects of isotretinoin on proliferation, lipid synthesis, and differentiation of human sebocytes,^[75-77] as well as on reduction of sebaceous gland volume.^[122] Inhibition of sebocyte proliferation and lipid synthesis were found to be independent mechanisms of isotretinoin action. Other nonaromatic retinoids, like tretinoin and 4-hydroxy-tretinoin also inhibited cell proliferation and lipid synthesis but to a lesser extent than isotretinoin, while didehydroretinoic acid and 9-*cis*-retinoic acid were as active as isotretinoin in suppressing proliferation of human sebocytes *in vitro*.^[34,76,77]

In contrast, the second and third generation aromatic retinoids did not significantly reduce sebum synthesis in several clinical studies. Etretinate (1 mg/kg/day for 8 weeks), acitretin (0.3 to 1 mg/kg/

day for 6 weeks) and arotinoid ethylester (1 µg/day for 6 weeks),^[123] esarotene (100 mg/day for 6 weeks),^[124] and temarotene (1 mg/day to 2 g/d for 8 to 12 weeks)^[125,126] did not reveal notable sebosuppressive activity. Arotinoic acid, a very potent inhibitor of sebocyte differentiation in animal models, was inferior to isotretinoin in a few patients tested.^[127] These retinoids were not sebosuppressive when applied topically.

Patients who have received oral isotretinoin therapy for seborrhoea do not usually experience relapse for months or years. However, the duration of the antiseborrhoeic effect seems to be dose dependent. Taking good tolerance into account, a dosage of 0.1 to 0.3 mg/kg/day over 4 weeks is sufficient to produce a sebostatic effect for at least weeks after discontinuation of treatment. In our experience, 5 to 10 mg/day may be sufficient as maintenance sebosuppressive dosage over several years.

5.3.2 Acne

Systemic administration of isotretinoin, introduced in 1979, revolutionised the treatment of severe acne.^[128] Isotretinoin is the only drug that directly suppresses abnormal desquamation of sebaceous follicle epithelium and sebum production. Subsequently, the growth of *Propionibacterium acnes* is greatly diminished.

Isotretinoin affects all 4 pathogenic factors for acne, whereas oral 9-*cis*-retinoic acid (0.3 to 1 mg/kg/day),^[129] etretinate (1 mg/kg/day), acitretin (0.3 to 1 mg/kg/day) and arotinoid ethylester (1 µg/kg/day),^[1-23] esarotene (100 mg/day),^[124] and temarotene (1 mg/day to 2 g/day)^[125] were practically inactive. The clinical course of isotretinoin therapy shows more rapid improvement of inflammatory lesions as compared with comedones. Pustules are cleared earlier than papules or nodules, and lesions localised on the face, upper arms and legs tend to clear more rapidly than trunk lesions.

Some authors favour isotretinoin 0.5 mg/kg/day;^[123] others advocate a higher dosage of 1 mg/kg/day.^[130] A 6-month treatment course is sufficient for 99% of patients, but it has been documented that an initial dosage of 1 mg/kg/day for 3

months, then reduced to 0.5 and, if possible, to 0.2 mg/kg/day for 9 additional months will optimise the therapeutic outcome. Relapses may occur after a single 6-month course. A 22 to 30% relapse rate was noted in patients followed for 10 years after isotretinoin 1 mg/kg/day (or cumulative dose >120 mg/kg) treatment, as compared to 39 to 82% with lower dosage treatment.^[131]

Today, we recommend a 12-month treatment course of isotretinoin 0.5 to 1 mg/kg/day in most cases of severe acne, with a >150 mg/kg cumulative dose. Factors contributing to the need for longer treatment include a low dosage regimen (0.1 to 0.5 mg/kg/day), presence of severe acne lesions, extrafacial involvement and prolonged history of the disease.^[132] Higher dosages are indicated particularly for severe involvement of the chest and back.^[131]

Contraception is essential in women of child-bearing age during isotretinoin treatment at all dosages.^[133,134] Estrogens, antiandrogens and their combinations inhibit sebum production by 12.5 to 65%. A combination of isotretinoin with systemic corticosteroids is initially required in acne fulminans. In contrast to the opinion that isotretinoin may be a frequent precipitating factor, in a series of 24 patients with acne fulminans only 5 had received isotretinoin before the onset of the disease.^[135]

5.3.3 Rosacea and Other Acne-Related Dermatoses

The efficacy of isotretinoin 0.4 to 1 mg/kg/day for 2 to 6 months in severe or recalcitrant rosacea has been well documented.^[93,136-138] Marked regression of skin lesions and recession of concomitant erythema and oedema are seen within 4 to 8 weeks. The anti-inflammatory action of isotretinoin must be considered a possible candidate mechanism for its efficacy in rosacea, since there is no evidence for a follicular disorder and sebum synthesis is normal.

Data on long term remissions in severe rosacea are contradictory; however, remissions of up to 2 years have been documented. The daytime use of a sunscreen is essential. In a recent randomised trial, low-dose systemic isotretinoin (10 mg/day)

reduced inflammatory papules to 30% and erythema to 60% of baseline after 16 weeks of treatment. The effect lasted at least 16 weeks after drug withdrawal. Interestingly, topical tretinoin (0.025% cream at night) also reduced papules to 43% and erythema to 73% of baseline.^[136]

Rhinophyma responds to systemic isotretinoin (0.5 to 1 mg/kg/day for 3 to 6 months), preferably at its early inflammatory stages. Improvement of early rhinophyma probably occurs because of diminution of the sebaceous glands, while fibrotic changes are resistant. Teleangiectasia responds only partially because of the recession of general inflammation. Rhinophyma treatment with isotretinoin 1 mg/kg/day for up to 18 weeks resulted in a 9 to 23% reduction of the nasal volume in 9 patients.^[137]

Gram-negative folliculitis responds well to oral isotretinoin 0.5 to 1.0 mg/kg/day (in individual cases initially ≤ 2.0 mg/kg/day) for 8 to 24 weeks, and usually results in long term remissions. The efficacy of isotretinoin is probably a result of a reduction of the sebaceous gland volume, sebostasis and skin 'drying', which impair the growth conditions of *Klebsiella*, *Enterobacter*, *Citrobacter*, *Escherichia coli* and *Pseudomonas aeruginosa* (Gram-negative folliculitis type I), as well as *Proteus mirabilis* (type II).

Acneiform dermatoses of the elderly, such as sebaceous gland hyperplasia, actinic elastosis with comedones formation (Favre-Racouchot disease), and demodex folliculitis can improve with long term treatment with isotretinoin 2.5 to 10 mg/day. Acne necroticans (isotretinoin 1 mg/kg/day for 5 weeks)^[139] and recalcitrant oil acne (0.5 mg/kg/day for 12 weeks)^[140] may respond to treatment, followed by long term remission, but halogen acne seems resistant.^[141]

Preoperative isotretinoin treatment of inverse acne with 0.8 to 1 mg/kg/day for at least 4 weeks, reducing to 0.5 to 0.7 mg/kg/day for an additional 4- to 8-week period and 0.2 to 0.4 mg/kg/day as a maintenance or postoperative treatment has been recommended in some cases.^[142] Surgical intervention is required in inverse acne; isotretinoin is

by itself, with rare exceptions, insufficient to stop the disease. In hidradenitis suppurativa and steatocystoma multiplex suppurativum, the overall inflammation responds to isotretinoin but the non-inflammatory or cystic lesions remain relatively uninfluenced.

5.4 Retinoids in Skin Cancer

The exact mechanisms by which oral retinoids act beneficially in skin neoplasia and/or prevent skin cancer are still largely unknown, but promotion of terminal epithelial cell differentiation and induction of apoptosis may lead to tumour regression. Also, control of cell growth and cell differentiation may be mediated in part by interactions between different nuclear retinoid receptor species and the respective response elements of DNA. An alternative pathway by which retinoids can mediate signals is by interacting with the transcription factor AP-1. This complex of the 2 proto-oncogenes, *c-fos* and *c-jun*, plays a crucial role in cell cycle progression.^[143] Recent results indicate that inhibition of the AP-1 complex by retinoids decreases the rate of cell proliferation.^[65]

Recently, we demonstrated the significance of the sphingomyelin cycle as a growth and differentiation control mechanism in human skin.^[144] This mechanism leads to elevation of intracellular ceramide levels and, as shown in haemopoietic cell lines, ceramides may represent a new second messenger, leading to inhibition of cell growth, induction of differentiation and apoptosis.^[145] In this context, it may be of importance to note that retinoic acid was shown to elevate intracellular ceramide levels and that this elevation was paralleled by inhibition of cell proliferation.^[146]

5.4.1 Prevention of Skin Cancer

Synthetic retinoids have been administered not only for therapy of skin malignancy, but also in several randomised chemoprevention trials. The data collected suggest that topical or oral administration of synthetic retinoids has a significant effect in reversing premalignant skin lesions and maintaining normal differentiation.^[147-149]

Successful prevention of basal cell carcinoma and squamous cell carcinomas in patients with xeroderma pigmentosum has been described with oral isotretinoin^[41] and oral etretinate.^[150] Isotretinoin was shown to reduce the occurrence of basal cell carcinomas by 80% and of squamous cell carcinomas by 60% over a period of 2 years. Etretinate was seemingly more effective with respect to squamous cell carcinoma prevention, with a reduction rate of 75%.

Both retinoids have also been shown to be beneficial in preventing the appearance of cutaneous tumours in the nevoid basal cell carcinoma syndrome;^[151] Goldberg et al.^[152] concluded that isotretinoin 0.4 mg/kg/day is effective for chemoprevention in these patients. Etretinate 50 mg/day has been advocated for chemoprevention in renal transplant recipients with a more than 20-fold increased risk of developing skin cancer.^[153] Transplant recipients show increased metastatic potential, leading to a 10-fold higher mortality rate from skin cancer. Therefore, the benefit of systemic retinoid therapy by etretinate 25 to 50 mg/day appears an important improvement in managing these patients. Recently, a combination of topical tretinoin and low-dose etretinate (10 mg/day) has been proposed for chemoprophylaxis,^[154] also for reducing the adverse effects of oral medication.

5.4.2 Therapy of Precanceroses and Skin Cancer

Keratoses were the first skin alterations to be treated topically with tretinoin.^[155] Treatment of actinic keratoses, Bowenoid epithelial precancerous lesions, etc., with various retinoids seems well established today. Successful chemoprevention of actinic keratoses with topical tretinoin has been described^[156] and other authors have summarised and commented favourably on its beneficial effect. Systemic administration of etretinate has been also shown to reduce actinic keratoses by 90% but overall, oral intake seemed inferior in comparison to topical treatment.^[157]

Good results were obtained in the treatment of actinic keratoses using topical isotretinoin (0.1%); 40% of all facial lesions disappeared after 2 weeks.^[152] Misiewicz et al.^[159] compared a cream

containing arotinoid methylsulphone versus tretinoin cream in a double blind study, and found that the arotinoid compound was more effective in actinic keratoses and produced less local adverse effects.

Oral leucoplakia has been shown to be retinoid-sensitive (both etretinate and isotretinoin),^[160,161] and good therapeutic results have been achieved; regressions between 61% (isotretinoin) and 92% (etretinate) have been reported.

Keratoacanthoma as a semimalignant tumour has been described to respond in nearly all patients under oral treatment with isotretinoin^[162] or etretinate.^[163] However, relapses may occur after therapy. As a rule, oral retinoids are not recommended as first line treatment for this condition, but postsurgical retinoid administration may prevent relapse in multiple tumours.

Basal cell carcinomas show minor response to oral retinoid treatment, even though some flattening may occur after several weeks or months. The retinoid effect is particularly unsatisfactory in nodular, ulcerous and/or sclerodermiform tumours which still show infiltrative growth.^[164]

In contrast to the benefits of chemoprevention, no satisfactory therapeutic results have been obtained in squamous cell carcinomas either with etretinate or with isotretinoin monotherapy. Recently, however, effective combinations of isotretinoin with IFN α -2a were reported in patients with advanced squamous cell carcinomas. In a group of 34 patients, 8 complete and 14 partial remissions (65%) were observed.^[165,166] Another trial with 13-*cis*-retinoic acid (1 mg/kg/day) and IFN α -2a (3 or 6 MU/day) produced benefit in 68% of the patients.^[167]

5.4.3 Other Skin Neoplasms

Melanomas are not sensitive to retinoids. Monotherapy with isotretinoin, etretinate, tretinoin^[168] and fenretinide^[169] as well as combination of isotretinoin with IFN α -2a^[167,170] have been shown to be ineffective in melanoma. Also, vitamin A does not seem to prevent neoplasia if used as an adjuvant.

Successful monotherapy of cutaneous T cell lymphoma has been early reported with etretinate, isotretinoin^[171-175] and also with the potent arotinoid Ro 13-6298;^[176] however, the combination of etretinate and PUVA appeared to be superior to retinoid alone. Jones and co-workers^[177] successfully treated patients with mycosis fungoides and Sézary syndrome with etretinate (1 mg/kg/day) and electron beam therapy (35Gy), but this combination provided no additional benefit for the course of the disease.^[177] Some synergistic effect was found with the combination of retinoids and chemotherapy in advanced mycosis fungoides.^[172,173,178,179]

A new promising approach for oral treatment of cutaneous T cell lymphoma is the combined administration of etretinate and IFN α -2b^[180-182] or IFN α -2a.^[183] From the results obtained it may be concluded that IFN α -2b is more effective than IFN α -2a since the respective remission rates were 77% and 53%. Also, a good therapeutic effect was seen with isotretinoin and IFN α -2b (a remission rate of 57%).^[184] Here again, it seems that retinoids and IFN may act synergistically: IFNs are thought to induce increased expression of RARs and, vice versa, retinoids may increase the expression of IFN receptors.

Von Roenn and coworkers^[185] reported some beneficial effect of oral tretinoin in patients with HIV-related Kaposi's sarcoma. In a phase II study utilising tretinoin 100 mg/m²/day they found stable disease in 2 of their 8 patients: an increased dosage (175 mg/m²/day) was less effective. In another preliminary study in 7 patients (tretinoin 2 mg/kg/day) 3 partial remissions and 3 stable disease courses were obtained.^[186] Possibly, systemic retinoids may inhibit or reduce endothelial proliferation *in vivo*, as they do *in vitro*.^[85]

5.5 Miscellaneous Disorders

Oral retinoids have been used in other dermatoses. In particular, etretinate/acitretin were found effective in 3 entities of different pathogenetic background:

- in lichen planus,^[187] including oral manifestations of lichen mucosae oris with papillomatous and erosive/bullous lesions;
- in cutaneous variants of lupus erythematosus (LE), particularly the hyperkeratotic lesions of chronic-diskoid LE;
- in lichen sclerosus et atrophicus mostly localised in the anogenital area in women (kraurosis vulvae).

Sometimes, corticosteroids are used topically or systemically in addition, and oral retinoids are helpful for reducing their dose (e.g. in lichen planus, LE). The beneficial effect of retinoids in these entities underlines their immunomodulatory dermal action. Prurigo nodularis may be another entity responding well to oral retinoid treatment. The use of oral retinoids in bullous diseases, and also in pyoderma vegetans, Kyrle's disease etc., remains unsatisfactory. Some effect will be seen^[188,189] in sarcoidosis or sarcoid granulomas and in granuloma annulare disseminatum, but randomised trials or case series reports are lacking.

6. Adverse Reactions and Tolerability

The adverse effect profile of oral retinoids is closely associated with hypervitaminosis A.^[21] It includes a characteristic mucocutaneous symptomatology, alopecia, elevation of serum triglycerides, hyperostosis and extraskeletal calcification. Retinoids are highly teratogenic if given orally during embryogenesis.

Because of these adverse effects, several contraindications for retinoid treatment should be considered and careful clinical monitoring is necessary. Oral retinoid treatment appears today strictly contraindicated in pregnancy, the lactation period and in severe hepatic and renal dysfunction:^[190,191] hyperlipidaemia, diabetes mellitus and severe osteoporosis are relative contraindications. Administration of retinoids with diet or lipid lowering agents is possible in cases of slightly increased serum lipids.^[192] Co-medication with vitamin A (increased toxicity), tetracyclines (cranial hypertension) and high doses of aspirin (potentiation of mucosal damage) should be avoided.

If retinoid therapy is necessary in women of childbearing age, pregnancy tests have to be performed before and during treatment. Oral contraceptives are recommended, since the common retinoids used do not interfere with the antiovarian activity even after prolonged intake.^[107] Before administering the drug it is strictly recommended that the risk of foetal malformations is explained, and information inserts should be signed prior to treatment by women of child bearing age. Despite some experimental and animal data that retinoids may influence spermatogenesis, no impairment of male reproductive capacity in men has been documented. In a recent case report it was assumed that ejaculatory failure may occur with isotretinoin.^[193]

6.1 Mucocutaneous Adverse Effects

The mucocutaneous adverse effects of oral retinoid treatment are well known but are mostly tolerable, if the drug is administered (a) in the proper indications, (b) at the appropriate dose-level, and (c) under careful monitoring by the physician.

Adverse effects include skin and mucosal dryness (xerosis, cheilitis, conjunctivitis, urethritis), skin fragility and/or stickiness, retinoid dermatitis, palmoplantar desquamation, pruritus and hair loss. Nearly all these symptoms are dose-dependent in incidence and severity, and are fully reversible on reducing the daily dose or on drug withdrawal.

Their incidence rates may slightly differ depending on the type of retinoid given and the initial dose used. In our 25 years of clinical experience with oral retinoid therapy, only severe abrupt hair loss may require drug withdrawal in rare instances. Since the frequency of cheilitis is nearly 100%, its appearance 2 to 3 weeks after initiation of treatment is regarded by us as a marker of sufficient absorption. In patients receiving 0.5 to 1.0 mg/kg/day with a lack of or insufficient clinical response to therapy, and who have not experienced mucocutaneous adverse effects (non-responders), we recommend blood concentration monitoring to ensure absorption (see section 7.2).

6.2 Eye Symptomatology and Pseudotumour Cerebri

With or without conjunctivitis, eye dryness may cause considerable discomfort in patients wearing contact lenses, and requires administration of artificial tears. Hemeralopia may occur, possibly because of some interference of retinoids with 11-*cis*-retinaldehyde formation. Also, papillary oedema, corneal abnormalities with opacities and cataract, transient acute myopia and abnormal electroretinograms have been described with retinoid treatment. In some instances, they may require ophthalmological consultation.

Pseudotumour cerebri was initially documented in patients receiving higher dosages of isotretinoin (≥ 1 mg/kg/day), particularly in combination with tetracyclines. No further reports were published with etretinate/acitretin in recommended dosages, but papilloedema should be considered in patients with pre-existing intraocular hypertension or glaucoma.

6.3 Serum Lipids and Liver Function

Hyperlipidaemia occurs more often with increased serum triglycerides (20 to 40%) than with cholesterol increase (10 to 30%).^[194,195] It is possible that retinoids enhance lipoprotein synthesis, decreasing elimination of blood lipids. They may also slightly increase synthesis of lipids. Increased apolipoprotein B and to a lesser extent increased total apolipoprotein A under retinoid treatment support the former hypothesis.

The influence on serum triglyceride and cholesterol levels is proportional to the dose and reverses within 4 to 8 weeks after discontinuation of treatment.^[196] Hyperlipidaemia leads to cessation of treatment in <5% of patients.^[195] Hyperlipidaemia is likely to occur in patients with predisposing factors such as obesity, alcoholism, nicotine abuse, diabetes mellitus, familial hyperlipidaemia, and users of β -blockers, contraceptives and thiazides.^[93]

The greatest increase in triglycerides is associated with the very low density lipoprotein fraction

(VLDL; with isotretinoin and etretinate) and in cholesterol with the low density lipoprotein (LDL) fraction (isotretinoin) and the VLDL and/or LDL fractions (etretinate), with a parallel decrease of the high density lipoprotein (HDL) fraction.^[197]

Hyperlipidaemia during retinoid treatment can be partially managed by an appropriate diet low in fat. A high fish oil diet was found effective in partially reducing hypertriglyceridaemia (27%) and increasing HDL cholesterol (11%) in patients treated with etretinate or acitretin.^[198] Lipid-lowering drugs taken orally are also effective, if required.

Synthetic retinoids have much less affinity for the liver than vitamin A. Most reported retinoid-induced hepatotoxic reactions have occurred with etretinate treatment, probably because of its high tissue-to-blood ratio, but isotretinoin may also be associated with such reactions.^[194] Elevations of liver enzymes have been documented in 20 to 30% of patients usually within 0.5 to 2 months of commencing therapy, but marked alterations are infrequent.^[196] Chronic toxicity resulting from retinoid treatment is a rare event, and long term etretinate treatment is not associated with increased liver toxicity, despite the fact that cases of biopsy-proven hepatitis have been documented.^[191]

6.4 Bone Changes

Changes in bone formation are a well recognised, common adverse reaction seen in chronic vitamin A intoxication.^[9,199,200] These changes include hyperostosis, periostosis, demineralisation, thinning of the bones, and premature closure of the epiphyses. Short term retinoid therapy (≤ 2 years) in children seems to be well tolerated. Data concerning long term retinoid treatment are conflicting. Recent studies of etretinate treatment in large series of children and adolescents at an initial dosage of 1 mg/kg/day for ≤ 11 years did not register significant bone abnormalities,^[201-203] disputing earlier case reports which suggested chronic bone toxicity in children.

Bone abnormalities in children, particularly premature closure of the epiphyses, are indeed as-

sociated with high retinoid doses (>1 mg/kg/day), vitamin A supplementation, and treatment for more than 5 years. Should bone abnormalities occur, they may not resolve upon cessation of treatment. In adult patients, chronic retinoid toxicity confined to bones is commonly assumed to be caused by isotretinoin rather than acitretin/etretinate.

The effects of acitretin on the skeletal system are not yet well documented; however, available data suggest similarities to etretinate.^[106] In a large prospective study, Tangrea et al.^[204] used very low doses of isotretinoin (0.14 mg/kg) compared with placebo for 3 years in the prevention of basal cell carcinoma. They found radiographic evidence for significant progression of pre-existing hyperostotic anomalies (40% with isotretinoin vs 18% with placebo).

High-dose isotretinoin for ≥ 2 years seems to induce skeletal hyperostoses and anterior spinal ligament calcification, similar to those seen in diffuse idiopathic skeletal hyperostosis (DISH). Changes occur in cervical spine more often than in the thoracic and lumbar spine. Some patients have shown extraspinal calcification (ankles, pelvis, knees). Small asymptomatic changes can be detected as early as after 1 year of treatment. Long term etretinate treatment was known to induce extraspinal tendon and ligament calcification and DISH-like involvement. In a further study, 5% of patients treated with acitretin for 1 to 2 years presented with bone changes. While a definite relationship between hyperostoses and cumulative dosage of isotretinoin could not be established, they are likely to occur at a cumulative etretinate dose of >30g.^[205]

Osteoporosis seems to be a toxic effect of long term etretinate but not isotretinoin therapy.^[206] In addition, bone pain and acute arthritis have been rarely documented.^[9,207] Since about 50% of patients with skeletal bone changes are asymptomatic, a single radiograph of the ankle, being the most common site of involvement, is a reasonable test before treatment and then repeated yearly with long term and/or high-dose retinoid treatment. In

addition, growth measurements are required in children.

6.5 Arthralgias and Myalgias

Arthralgias and myalgias may occur in up to 2 to 5% of individuals receiving oral retinoids >0.5 mg/kg/day, with or without calcification of ligaments. Their appearance seems more common in adolescents and young adults, particularly those treated with isotretinoin. In some cases, severe muscle pain and temporary disability with early morning arthralgias were seen. Occasionally, concomitant malaise and fever may occur, and increases of serum enzymes including creatine phosphokinase have been found. In some rare cases 'retinoid hypersensitivity reaction' with myoarthralgias has been suspected.

6.6 Teratogenicity

All known biologically active retinoids are highly teratogenic, both in animal experiments and in humans.^[133,208-211] Their biological action, beneficial for skin disease, seems related to the teratogenic risk, and is particularly high for women exposed to treatment during the first trimester of pregnancy. The indiscriminate transfer of retinoids through the placenta leads to similar concentrations of the drug and its isomers both on the maternal and the fetal site.^[26] Therefore, systemic teratogenicity of retinoids has remained the major concern today and for future retinoid research.

The clinical pattern of abnormalities induced by retinoids is rather characteristic, although some similarities to other teratogenic drugs such as methotrexate may occur. They induce:

- CNS and craniofacial abnormalities with internal ear and eye malformations and facial dysmorphism;
- bone abnormalities with skeletal malformations, occasionally leading to limb defects;
- cardiovascular disorders.

All three are major birth defect phenotypes, in some cases with lethal outcome. In addition, general retardation, thymus hormone abnormalities, parathyroid hormone deficiency, colobomas, choa-

nal atresia, etc., have been described. There are some differences of malformation pattern that may characterise the influence of retinoic acid on the one hand and etretinate/acitretin on the other, but these remain without major clinical relevance.

Today, all known therapeutic schedules with retinoids are regarded as potentially teratogenic. Even though topical treatment with tretinoin/isotretinoin has been previously regarded as 'safe', recent observations after the use of tretinoin cream have raised considerable concern.^[212-214]

After topical application of isotretinoin (0.05%) in hairless rats the plasma concentrations of isotretinoin and its metabolites were below the detection limit.^[134] Nevertheless, all investigators agree today that the topical application of retinoids should be strictly avoided during the first trimester of pregnancy. Since November 1 1994, topical application of 0.05% tretinoin cream/0.05% isotretinoin gel is not permitted during the entire period of pregnancy in Germany, according to a decision of the Federal Drug Commission.

Concerning systemic administration, it has been known that a single oral retinoid dose of 25mg given in pregnancy during the time period of organogenesis (4 to 6 weeks) may be associated with embryonic malformations,^[215] whereas oral retinoids taken during late in pregnancy did not influence the embryo. Despite this difference indicating a time-related teratogenic risk,^[216] all present recommendations require avoidance of any oral administration of isotretinoin, etretinate or acitretin over the entire period of pregnancy.

The minimal dose of circulating retinoids associated with teratogenicity is not sufficiently known. The detection limit by using the reverse phase high performance liquid chromatography (HPLC) technique is regarded as the major parameter, and unmeasurable concentrations of <2 µg/L may be regarded as nonteratogenic. In this respect, some authors have pointed out that endogenous retinoic acid levels may be 2 to 4 µg/L.

Based on pharmacokinetic data, current guidelines include the use of contraception 1 month before initiation of oral treatment with isotretinoin

and etretinate/acitretin and continuation of contraception for 1 to 2 months after isotretinoin and 2 years after etretinate/acitretin treatment.^[217-219] A negative pregnancy test is required in all young women considered for treatment 2 weeks before initiation of treatment and at day 2 or 3 of a normal menstrual cycle.

7. Clinical Monitoring

Oral retinoid treatment requires clinical experience and regular monitoring. Retinoids are not the 'easy' drug for the 'difficult' patient. Initial high-dose retinoid therapy may cause physical discomfort, and the large number of undesired potential adverse reactions to be discussed and explained during the first consultation may limit the enthusiasm of the individual to give his/her consent for treatment.

7.1 Monitoring of Clinical and Laboratory Parameters

Today, clinical monitoring requires physical examination every 4 weeks to manage mucocutaneous adverse effects and to ensure compliance. After administration of isotretinoin and also etretinate/acitretin, elevations of blood sedimentation rate, transaminases (ALT, AST, γ-glutamyl transferase), plasma urea and serum lipid levels may occur. Liver enzymes (transaminases, alkaline phosphatase, γ-glutamyl transferase), serum creatinine and blood glucose should be measured every 4 to 8 weeks. If elevations appear, the retinoid dose given should be reduced by 50% or be interrupted.

Elevations of serum lipids and, more rarely, of cholesterol, were shown early to be occasional adverse effects of oral retinoids.^[12,97,188,194,220] Such elevations are more often seen in older patients, particularly in those with familial predisposition or other risk factors such as diabetes, obesity, heavy smoking, hypertension, oral contraceptives and corticosteroids. Furthermore, it was shown that the amounts of creatine kinase, apolipoprotein B, total cholesterol and LDL cholesterol increased significantly during therapy with isotretinoin.^[221] Triglyceride and cholesterol levels have to be moni-

tored every 4 weeks over a period of 2 to 3 months during the initial phase (12 hours after intake of food) and later on every 8 weeks. Selection of patients and appropriate diet schedules are recommended as necessary precautions for reducing the risk of hyperlipidaemia.

Prior long term therapy with oral retinoids, e.g. in disorders of keratinisation,^[93,117] x-rays of the spine and the long bones should be taken, particularly in adolescents and in young adults. There are no established regulations for the time intervals of skeletal monitoring: the decision should be taken separately for each patient. Particularly in children and adolescents, regular radiological examinations of the skeletal system and the epiphyseal cartilage of tubular bones and measurements of general growth are necessary.^[222]

7.2 Monitoring of Retinoid Bioavailability and Body Storage

Monitoring of retinoid blood concentrations during and after oral retinoid therapy remains of major importance for managing cases of non-responders or considering recommendations for pregnancy. In some patients showing little clinical response the retinoid blood concentrations have been extremely low, and only an increase in dosage up to 1.5 mg/kg/day was followed by target blood concentrations and sufficient clinical response.^[223]

HPLC is the method of choice for highly sensitive and selective retinoid detection and measurements.^[224-226] Following simultaneous extraction with organic solvent, the compounds can be measured by normal or reverse-phase HPLC,^[5,227] with a detection limit of approximately 4 µg/L in plasma. Using a system of column-switching HPLC the limit for measurement can be reduced to 2 µg/L.^[228]

If traces of retinoids are detected in the blood of pregnant women, interruption of pregnancy is recommended. In a few cases, traces of etretinate and acitretin were detected 9 to 18 months after drug withdrawal.^[217,219] It is assumed that plasma levels of isotretinoin below the detection limit of 2 µg/L are not teratogenic because the naturally occurring

13-*cis*-retinoic acid reaches levels between 1.0 and 2.2 µg/L under fasting conditions.^[7] In the absence of these predictors in blood, however, the presence of retinoid traces in tissue is not fully excluded.

When plasma concentrations of etretinate are below the detection limit, etretinate and 13-*cis*-acitretin can be monitored in subcutaneous tissue. The prevalence of detectable etretinate concentrations in subcutaneous tissue was found to be higher (83%) than in plasma (45%), both among current acitretin users and also among those who had stopped acitretin therapy.^[229] Since traces of 13-*cis*-acitretin were found in fat up to 29 months after cessation of treatment, it has been suggested that the recommended contraception period of 2 years should be reconsidered.

8. Topical Treatment with Retinoids

Topical application of retinoids avoids their considerable systemic toxicity and has led to widespread use of these compounds, especially of tretinoin, e.g. for acne vulgaris, photodamage and also for actinic keratoses.^[230,231]

8.1 Pharmacokinetics

Topical application of tretinoin is followed by partial isomerisation to 9-*cis*-retinoic acid and isotretinoin, and to numerous other metabolites within the epidermis.^[232] Approximately 80% of the drug remains on the skin surface, while its penetration through both the stratum corneum and the hair follicles is vehicle dependent.^[233] The initial diffusion into the intact stratum corneum occurs rapidly, within a few minutes.^[234] Further diffusion into the epidermis and subsequently the dermis proceeds more slowly.^[235]

Tretinoin induces the activity of cytochrome P450 retinoic acid-4-hydroxylase in the keratinocytes, which converts tretinoin to its inactive metabolite 4-hydroxy-retinoic acid.^[236]

The cellular retinoic acid binding protein-II (CRABP-II), initially proposed to transport retinoic acid to its nuclear receptors, is the predominant form of CRABP in human skin, found in both keratinocytes and fibroblasts.^[237] Topical applica-

tion of tretinoin up-regulates CRABP-II, whose exact function remains unclear.^[238] The facts that highly homologous proteins are found in all animal species and that a RARE has been identified within the promoter region of the CRABP-II gene suggest that either CRABP-II regulates the bioavailability of retinoids by reducing the free levels available to bind to the specific nuclear receptors, or acts as a co-factor in retinoid metabolism.^[52]

Topical isotretinoin probably also exhibits anti-inflammatory activity as it was shown to significantly inhibit the leukotriene B₄-induced migration of neutrophils in 16 healthy volunteers.^[91] Interestingly, tretinoin, arotinoid methyl sulphone and arotinoid ethyl sulphone were inactive in this study.

Acitretin has been detected in the skin after topical application, whereas concentrations in the skin after a single 24-hour topical application of a saturated acitretin-isopropylmyristate formulation were comparable to those after systemic application in a steady-state situation.^[239] However, topical acitretin was practically ineffective in psoriasis and disorders of keratinisation.

8.2 Clinical Applications of Topical Retinoids

8.2.1 Acne Vulgaris

Topical tretinoin and isotretinoin are effective comedolytic agents.^[17,18] They normalise desquamation of the follicular epithelium, promote drainage of preexisting comedones, and inhibit the formation of new comedones and other lesions.^[240,241] The restored follicular environment impedes the growth of *P. acnes* and minimises the rupturing of comedones into surrounding tissue.

The efficacy of topical isotretinoin 0.05% gel versus vehicle for 14 weeks was examined in a randomised study of 268 patients with acne.^[17] Isotretinoin significantly reduced the inflammatory lesions after 5 weeks and the noninflammatory lesions after 8 weeks, compared with the vehicle. In another double-blind randomised study involving 77 patients, isotretinoin gel was compared with benzoyl peroxide gel 5% and vehicle.^[18] Benzoyl peroxide had a more rapid effect on inflammatory

lesions, but both active treatments were efficacious. A new retinoid, adapalene, has been recently introduced for the topical treatment of acne vulgaris, possibly showing better tolerability than tretinoin (see section 9).

Topical retinoids are regarded today as first-line treatment for both noninflammatory and also inflammatory forms of acne. Substantial clinical improvement is apparent after 6 weeks, with maximal improvement occurring in 3 to 4 months. Long lasting remissions can be maintained with continued application on an infrequent, but regular basis. Topical retinoids may heighten susceptibility to sunlight, and the use of sunscreens is recommended.

Since topical retinoids normalise desquamation of the follicular epithelium and topical antibiotics and antimicrobials inhibit *P. acnes*, neutrophil chemotaxis and the production of free fatty acids, the concomitant use of a retinoid with an antimicrobial agent addresses 3 of the 4 pathogenic factors of acne. Combination therapies utilising retinoids and antimicrobial/antibiotic agents should be sequential, i.e. the antimicrobial/antibiotic preparation being applied in the morning, and the retinoid preferably administered at night.

8.2.2 Photoaging and Aging

Well controlled studies attest to the efficacy of topical tretinoin and isotretinoin in improving the features of photoaging.^[242-246] Retinoids induce epidermal hyperproliferation, compaction of stratum corneum, deposition of glycosaminoglycans in the epidermis and of collagen in the immediate subepidermal region, and slow the rate of collagen breakdown by reducing collagenase levels and by promoting the production of collagenase inhibitors.^[247,248] Epidermal melanin is reduced because of a decrease in the rate of melanosomes transferred from melanocytes to keratinocytes secondary to the increase in epidermal proliferation.

Daily application of 0.1% tretinoin cream leads to significant improvement of wrinkling and hyperpigmentation in 16 weeks.^[246] A 0.05% tretinoin emollient cream applied daily for 24 weeks was also shown to be effective on fine wrin-

ling, mottled hyperpigmentation, and roughness of the skin, as compared to placebo in a double-blind, randomised trial in 296 patients.^[243]

A lower tretinoin dose, 0.025% cream, has been recently shown to be as effective as tretinoin 0.1%, and induced a lower degree of irritation.^[242] Combination of 0.1% tretinoin cream with 0.05% diflorasone diacetate cream for 16 weeks once daily induced striking clinical improvement in wrinkling and caused bleaching in 5 postmenopausal women with severe photoaging changes.^[249] Tretinoin 0.025% was also able to substantially alter the involutonal structural changes in intrinsically aged sun-protected skin of 6 elderly women treated once daily for 9 months.^[250]

8.2.3 Disorders of Pigmentation

Epidermal melasma responds to topical tretinoin, either alone or in combination with hydroquinone and hydrocortisone, in conjunction with a broad-spectrum sunscreen.^[251] Epidermal melanin is reduced by retinoic acid. Possible mechanisms include reduction in the transfer rate of melanosomes to keratinocytes and inhibition of tyrosinase activity leading to reduction of melanogenesis.^[252]

8.2.4 Other Indications

Clinical trials have confirmed the beneficial effect of topical tretinoin and established the efficacy of isotretinoin 0.1% applied twice daily for 24 weeks in the treatment of actinic keratoses.^[158,253] Plane warts in children, especially on the face, responded well to 6-week treatment with tretinoin 0.05% once daily as shown in a randomised study in 50 children.^[254] Also, actinic cheilitis responds well to long term treatment with tretinoin 0.1% gel once or twice daily.^[255] Early stretch marks were found to improve after tretinoin 0.1% cream once daily for 6 months in a double-blind, randomised, vehicle-controlled study involving 22 patients.^[256]

8.2.5 Adverse Effects of Topical Retinoids

It is well known that topical application of retinoids causes a dose-dependent dermatitis with erythema, peeling, dryness and pruritus.^[242,243,245] These effects tend to peak within the first month of

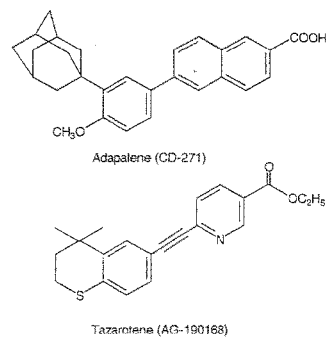


Fig. 3. Adapalene and tazarotene.

treatment and diminish thereafter. Although no evidence exists for embryotoxicity and teratogenicity of topical retinoids in humans, even after continued application over several years,^[213,257,258] treatment has to be interrupted if the patient becomes pregnant (see also section 6.6).

9. New Trends and Outlook for the Future

Most known retinoids initiate a series of biological responses by indiscriminate binding to and/or by activation of several regulatory receptors, both of cytosolic or nuclear localisation. Nevertheless, in spite of the tremendous increase of knowledge on the field, it still remains unclear how transcription of activated genes influences the various retinoid-responsive skin disorders and what the biological significance of the receptor binding is.

Retinoids do not necessarily act by influencing nuclear receptors; it is conceivable that their therapeutic effect is mediated by cell membrane mechanisms or direct pharmacologic action. Nevertheless, further development of receptor-selective retinoid ligands could contribute to better discrimination of their activity either towards keratinising epithelia or to the sebaceous gland, and also help

to enlarge their therapeutic window by minimising adverse effects.

Receptor-selective retinoid agonists and/or antagonists are now the subject of ongoing research, and new, more receptor- and disease-specific retinoids may be discovered in the near future. Recently, oral tretinoin (45 mg/m²/day) has been introduced for the treatment of acute promyelocytic leukaemia. In dermatology, two new arotinoids have been developed for topical use in skin disease, adapalene and tazarotene (fig. 3), and more synthetic compounds may follow (table VII).

Adapalene^[13,14,19] is a new naphthoic acid arotinoid with high chemical and physical (light) stability and lipophilic properties. The drug has comedolytic and anti-inflammatory action. It does not bind to CRABP,^[259] although it enhances its synthesis, and its receptor selectivity appears to be RAR β > RAR γ >> RAR α . The drug is topically effective in acne and has also mild antipsoriatic properties.^[262] In acne, adapalene was found in randomised studies with 0.1% gel preparations to be better or at least equal to 0.025% tretinoin in reducing total or noninflammatory lesions after 12 weeks of treatment.^[19] Local irritation occurs, however, in about 50% of patients, which may limit its long term value. Adapalene has been recently introduced in several European countries as a topical antiacne preparation. Transdermal absorption is very low and the teratogenic risk after topical application appears minimal; however, we do not recommend its use during pregnancy.

Tazarotene^[15] is an acetylenic retinoid of the third generation. It is a poorly absorbed, non-isomerisable arotinoid which is rapidly metabolised to its free carboxylic acid, tazarotenic acid. The latter binds to RAR β > RAR γ >> RAR α , without any affinity for RXRs. It was found to normalise acanthosis with a decrease of hyperproliferative keratins CK 6/CK 16, decrease ECF receptor expression, restore normal expression and distribution of transglutaminase K, and increase filaggrin synthesis in the upper psoriatic epidermis, with low potential for systemic adverse effects. It has

Table VII. New retinoid compounds

Retinoid	Remarks
LGD-1069	RXR panagonist; currently in clinical trials
CD-1599	Chemical and tissue stability, probably less toxic effects
Tamibarotene (Am-80)	Studied as topical antipsoriatic agent in clinical trials
CD-437 (AHPN)	Induction of apoptosis
CD-2398	Up-regulates AP-1 complex, does not bind to RARs; currently in clinical anticancer trials
Ro 23-6457	Immunosuppressive properties
Mofarotene (Ro 40-8757)	Used in chemotherapy; enhances the activity of doxorubicin, cyclophosphamide, fluorouracil, interleukins

Abbreviations: RAR = retinoic acid receptor; RXR = retinoid X receptor.

mild anti-inflammatory properties but is also an irritant in high topical doses.

Tazarotene has just been released in Germany and will be soon released in some other European countries and in the USA/Canada as a topical antipsoriatic agent (0.05 to 0.1 % gel). Clinical responses are seen after 2 weeks, with significant clearing after 6 to 12 weeks of treatment. Combination of tazarotene with less potent corticosteroids may increase the overall therapeutic potential and reduce local irritation, as shown by us at the beginning of the retinoid era.^[203]

In the future, the group of arotinoids which we first introduced for the treatment of skin disease^[260,261] appears promising for consideration as potential anticancer drugs. Better knowledge of the retinoid-induced intracellular events is needed. The next decade will allow further elucidation of how retinoids work and how cell dedifferentiation could be reversed under retinoid supervision.

References

1. IUPAC-IUB Joint Commission on Biochemical Nomenclature. *Eur J Biochem* 1982; 129: 1-5
2. Orfanos CE, Schuppji R. Oral retinoids in dermatology. Proc. Workshop XVth International Congress of Dermatology 1977, Mexico City. *Dermatologica* 1978; 157 Suppl. 1: 1-64
3. Orfanos CE. Oral retinoids: present status. *Br J Dermatol* 1980; 103: 473-81

4. Voorhees JJ, Orfanos CE. Oral retinoids. Broad spectrum dermatologic therapy for the 1980s. *Arch Dermatol* 1981; 117: 418-21.
5. Gollnick H, Rinck G, Bitterling T, et al. Pharmakokinetik von Etretinat, Acitretin und 13-*cis*-Acitretin: neue Ergebnisse und Nutzen der Blutspiegel-orientierten klinischen Anwendung. *Z Hautkr* 1990; 65: 40-50.
6. Safavi K. Serum vitamin A levels in psoriasis: results from the first national health and nutrition examination survey. *Arch Dermatol* 1992; 128: 1130-1.
7. Tang G, Russel RM. 13-*cis*-retinoic acid is an endogenous compound in human serum. *J Lipid Res* 1990; 31: 175-82.
8. Matsuoaka LY, Wortzman J, Tang G, et al. Are endogenous retinoids involved in the pathogenesis of acne? *Arch Dermatol* 1991; 127: 1072-3.
9. Biesalski HK. Comparative assessment of the toxicology of vitamin A and retinoids in man. *Toxicology* 1989; 57: 117-61.
10. Dawson MI, Hobbs PD. The synthetic chemistry of retinoids. In: Sporn MB, Roberts AB, Goodman DS, editors. *The retinoids. Biology, chemistry, and medicine*. 3rd ed. New York: Raven Press, 1984; 5-178.
11. Orfanos CE, Stadler R, Gollnick H, et al. Current developments of oral retinoid therapy with three generations of drugs. *Recent Developments in Clinical Research. Curr Probl Dermatol* 1985; 13: 33-49.
12. Vahlquist A, Rollman O. Etretinate and the risk for teratogenicity: drug monitoring in a pregnant woman for 9 months after stopping treatment. *Br J Dermatol* 1990; 123: 31.
13. Bernard BA. Adapalene, a new chemical entity with retinoid activity. *Skin Pharmacol* 1993; 6 Suppl. 1: 61-9.
14. Verschoore M, Langner A, Wolska H, et al. Efficacy and safety of topical CD 271 alcoholic gels. A new treatment candidate for acne vulgaris. *Br J Dermatol* 1991; 124: 368-71.
15. Esgleyes-Ribot T, Chandraratna RA, Lew-Kaya DA, et al. Response of psoriasis to a new topical retinoid, AGN 190168. *J Am Acad Dermatol* 1994; 30: 581-90.
16. Chandraratna RAS, Johnson AT, Thatcher SM, et al. Retinoid agonists, neutral antagonists and inverse agonists; novel retinoids for the treatment of psoriasis [abstract]. *Br J Dermatol* 1996; 135: 837.
17. Chalker DK, Leshner JL Jr, Smith JG Jr, et al. Efficacy of topical isotretinoin 0.05% gel in acne vulgaris: results of a multicenter, double-blind investigation. *J Am Acad Dermatol* 1987; 17: 251-4.
18. Hughes BR, Norris JFB, Cunliffe WJ. A double-blind evaluation of topical isotretinoin 0.05%, benzoyl peroxide gel 5% and placebo in patients with acne. *Clin Exp Dermatol* 1992; 17: 165-8.
19. Shalita A, Weiss JS, Chalker DK, et al. A comparison of the efficacy and safety of adapalene gel 0.1% and tretinoin gel 0.025% in the treatment of acne vulgaris. A multicenter trial. *J Am Acad Dermatol* 1996; 34: 482-5.
20. Schumacher A, Stüttgen G. Vitamin-A-Säure bei Hyperkeratosen epithelialen Tumoren und Akne. *Dtsch Med Wochenschr* 1971; 96: 1547-51.
21. Allen JG, Bloxham DP. The pharmacology and pharmacokinetics of the retinoids. *Pharmacol Ther* 1989; 40: 1-27.
22. Larsen FG, Jakobsen P, Eriksen H, et al. The pharmacokinetics of acitretin and its 13-*cis*-metabolite in psoriatic patients. *J Clin Pharmacol* 1991; 31: 477-83.
23. Larsen FG, Nielsen-Kudsk F, Jakobsen P, et al. Pharmacokinetics and therapeutic efficacy of retinoids in skin diseases. *Clin Pharm* 1994; 23: 42-61.
24. Lucek RW, Colburn WA. Clinical pharmacokinetics of the retinoids. *Clin Pharmacokinet* 1985; 10: 38-62.
25. Benifla JL, Ville Y, Imbert MC, et al. Fetal tissue dosages of retinoids: experimental study concerning a case of isotretinoin (Roaccutan®) administration and pregnancy. *Fetal Diagn Ther* 1995; 10: 189-91.
26. Reiners J, Lofberg B, Kraft JC, et al. Transplacental pharmacokinetics of teratogenic doses of etretinate and other aromatic retinoids in mice. *Reprod Toxicol* 1988; 2: 19-29.
27. Chalmers RJ. Retinoid therapy - a real hazard for the developing embryo. *Br J Obstet Gynaecol* 1992; 99: 276-8.
28. DiGiovanna JJ, Zech LA, Ruddel ME, et al. Etretinate. Persistent serum levels after long-term therapy. *Arch Dermatol* 1989; 125: 246-51.
29. Rollmann O, Phil-Lundin I. Acitretin excretion into human breast milk. *Acta Derm Venereol* 1990; 70: 487-90.
30. Rollmann O, Vahlquist A. Retinoid concentrations in skin, serum and adipose tissue of patients treated with etretinate. *Br J Dermatol* 1983; 109: 439-47.
31. McNamara PJ, Jewell RC, Jensen BK, et al. Food increases the bioavailability of acitretin. *J Clin Pharmacol* 1988; 28: 1051-5.
32. Brindley C. An overview of recent clinical pharmacokinetic studies with acitretin (Ro 10-1670, etretin). *Dermatologica* 1989; 178: 79-87.
33. Pilkington T, Brogden RN. Acitretin: a review of its pharmacology and therapeutic use. *Drugs* 1992; 43: 597-627.
34. Vane FM, Buggé CJL, Rodriguez LC, et al. Human biliary metabolites of isotretinoin: identification, quantification, synthesis and biological activity. *Xenobiotica* 1990; 20: 193-207.
35. Rubio F, Jensen BK, Henderson L, et al. Disposition of [¹⁴C] acitretin in humans following oral administration. *Drug Metab Dispos* 1994; 22: 211-15.
36. Geiger J-M, Brindley CJ. *Cis-trans* interconversion of acitretin in man. *Skin Pharmacol* 1988; 1: 230-5.
37. Stuck AE, Brindley CJ, Busslinger A, et al. Pharmacokinetics of acitretin and its 13-*cis*-metabolite in patients with haemodialysis. *Br J Clin Pharmacol* 1989; 27: 301-4.
38. Gollnick H, Bauer R, Brindley CJ, et al. Acitretin versus etretinate in psoriasis. Clinical and pharmacokinetic results of a German multicenter study. *J Am Acad Dermatol* 1988; 19: 458-69.
39. Gollnick H, Zaun H, Ruzicka T, et al. Relapse rate of severe generalized psoriasis after treatment with acitretin or etretinate. *Eur J Dermatol* 1993; 3: 442-6.
40. Kingston TP, Matt LH, Lowe NJ. Etretin therapy for severe psoriasis. Evaluation of clinical responses. *Arch Dermatol* 1987; 123: 55-8.
41. Kraemer KH, Di Giovanna JJ, Moshella AN, et al. Prevention of skin cancer in xeroderma pigmentosum with the use of oral isotretinoin. *N Engl J Med* 1988; 318: 1633-7.
42. Larsen FG, Jakobsen P, Knudsen J, et al. Conversion of acitretin to etretinate in psoriatic patients is influenced by ethanol. *J Invest Dermatol* 1993; 100: 623-7.
43. Cbou RC, Wyss R, Huxelton CA, et al. A potentially new metabolic pathway: ethyl esterification of acitretin. *Xenobiotica* 1992; 8: 993-1002.
44. Almond-Roesler B, Orfanos CE. *Trans*-Acitretin wird in Etretinat rückmetabolisiert. Bedeutung für die orale Retinoidtherapie. *Hautarzt* 1996; 47: 173-7.
45. Larsen FG. Pharmacokinetics of etretinate and acitretin with special reference to treatment of psoriasis. *Acta Derm Venereol* 1995; 190: 1-33.

46. Rollmann O, Vahlquist A. Oral isotretinoin (13-*cis*-retinoic acid) therapy in severe acne: drug and vitamin A concentrations in serum and skin. *J Invest Dermatol* 1986; 86: 384-9
47. Laugier JP, Berbis P, Brindley C, et al. Determination of acitretin and 13-*cis* acitretin in skin. *Skin Pharmacol* 1989; 2: 181-6
48. Larsen FG, Vahlquist C, Andersson E, et al. Oral acitretin in psoriasis: drug and vitamin A concentrations in plasma, skin and adipose tissue. *Acta Derm Venereol* 1992; 72: 84-8
49. Giguère V. Retinoic acid receptors and cellular retinoid binding proteins: complex interplay in retinoid signaling. *Endocr Rev* 1994; 15: 61-79
50. Vieira AV, Schneider WJ, Vieira PM. Retinoids: transport, metabolism, and mechanisms of action. *J Endocrinol* 1995; 146: 201-7
51. Fisher GJ, Talwar HS, Xiao J-H, et al. Immunological identification and functional quantitation of retinoic acid and retinoid X receptor proteins in human skin. *J Biol Chemistry* 1994; 269: 20629-35
52. Ross AC. Cellular metabolism and activation of retinoids: roles of cellular retinoid-binding proteins. *FASEB J* 1993; 7: 317-27
53. Apfel C, Crettaz M, Siegenthaler G, et al. Synthetic retinoids: differential binding to retinoic acid receptors. In: Saurat J-H, editor. *Retinoids 10 years on*. Karger: Basel, 1991: 110-20
54. Törnå H, Rollmann O, Vahlquist A. Detection of mRNA transcripts for retinoic acid, vitamin D3, and thyroid hormone (α -*erb*-A) nuclear receptors in human skin using reverse transcription and polymerase chain reaction. *Acta Derm Venereol* 1993; 73: 102-7
55. Mangelsdorf DJ, Umesono K, Evans RM. The retinoid receptors. In: Sporn MB, Roberts AB, Goodman DS, editors. *The retinoids. Biology, chemistry, and medicine*. New York: Raven Press, 1994: 319-49
56. Brand N, Petkovich M, Krust A, et al. Identification of a second human retinoic acid receptor. *Nature* 1988; 332: 850-3
57. Krust A, Kastner P, Petkovich M, et al. A third human retinoic acid receptor, hRAR-gamma. *Proc Natl Acad Sci USA* 1989; 86: 5310-4
58. Petkovich M, Brand NJ, Krust A, et al. A human retinoic acid receptor which belongs to the family of nuclear receptors. *Nature* 1987; 330: 444-50
59. Mangelsdorf DJ, Burgmeyer U, Heyman RA, et al. Characterization of three RXR genes that mediate the action of 9-*cis* retinoic acid. *Genes Dev* 1992; 6: 329-44
60. Mangelsdorf DJ, Ong ES, Dyck JA, et al. Nuclear receptor that identifies a novel retinoic acid response pathway. *Nature* 1990; 345: 224-9
61. Elder J, Åström A, Pettersson U, et al. Differential regulation of retinoic acid receptors and binding proteins in human skin. *J Invest Dermatol* 1992; 98: 573-679
62. Leid M, Kastner P, Lyons R, et al. Purification, cloning, and RXR identity of the HeLa cell factor with which RAR or TR heterodimerizes to bind target sequences efficiently. *Cell* 1992; 68: 377-95
63. Boylan JF, Goudas LJ. Overexpression of the cellular retinoic acid-binding protein-I (CRABP-I) results in a reduction in differentiation-specific gene expression in P9 teratocarcinoma cells. *J Cell Biol* 1991; 112: 965-79
64. Schüle R, Evans RM. Cross-coupling of signal transduction pathways: zinc finger meets leucine zipper. *Trends Genet* 1991; 7: 377-81
65. Fanjul A, Dawson MI, Hobbs PD, et al. A new class of retinoids with selective inhibition of AP-1 inhibits proliferation. *Nature* 1994; 372: 107-11
66. Tong PS, Horowitz NN, Wheeler LA. *Trans*-retinoic acid enhances the growth response of epidermal keratinocytes to epidermal growth factor and transforming growth factor beta. *J Invest Dermatol* 1990; 94: 126-31
67. Zheng Z-S, Polakowska R, Johnson A, et al. Transcriptional control of epidermal growth factor receptor by retinoic acid. *Cell Growth Differ* 1992; 3: 225-32
68. Asselineau D, Darmon M. Retinoic acid provokes metaplasia of epithelium formed by adult human epidermal keratinocytes. *Differentiation* 1995; 58: 297-306
69. Griffiths CEM, Dabelsteen E, Voorhees JJ. Topical retinoic acid changes the epidermal cell surface glycosylation pattern towards that of a mucosal epithelium. *Br J Dermatol* 1996; 134: 431-6
70. Rosenthal DS, Griffiths CEM, Yuspa SH, et al. Acute or chronic topical retinoic acid treatment of human skin *in vivo* alters the expression of epidermal transglutaminase, loricrin, involucrin, filaggrin, and keratins 5 and 13 but not keratins 1, 10, and 14. *J Invest Dermatol* 1992; 98: 343-50
71. Asselineau D, Bernard BA, Bailly C, et al. Retinoic acid improves epidermal morphogenesis. *Dev Biol* 1989; 133: 322-35
72. Asselineau D, Cavey MT, Shroot B, et al. Control of epidermal differentiation by a retinoid analogue unable to bind to cytosolic retinoid acid-binding proteins (CRABP). *J Invest Dermatol* 1992; 98: 128-34
73. Geiger J-M, Hommel L, Harms M, Saurat J-H. Oral 13-*cis* retinoic acid is superior to 9-*cis* retinoic acid in sebosuppression in human beings. *J Am Acad Dermatol* 1996; 34: 513-5
74. Hommel L, Geiger J-M, Harms M, et al. Sebum excretion rate in subjects treated with oral *all-trans*-retinoic acid. *Dermatology* 1996; 193: 127-30
75. Shapiro SS, Hurley J, Vane FM, et al. Evaluation of potential therapeutic entities for the treatment of acne. In: Reichert U, Shroot B, editors. *Pharmacology of retinoids in the skin*. Basel: Karger, 1989: 104-12
76. Zouboulis ChC, Korge B, Akamatsu H, et al. Effects of 13-*cis*-retinoic acid, all-*trans*-retinoic acid, and acitretin on the proliferation, lipid synthesis and keratin expression of cultured human sebocytes *in vitro*. *J Invest Dermatol* 1991; 96: 792-7
77. Zouboulis ChC, Xia L, Korge B, et al. Cultivation of human sebocytes *in vitro*. Cell characterization and influence of synthetic retinoids. In: Saurat J-H, editor. *Retinoids 10 years on*. Basel: Karger, 1991: 254-73
78. Zouboulis ChC, Krieter A, Gollnick H, et al. Progressive differentiation of human sebocytes *in vitro* is characterized by increased cell size and altered antigenic expression and is regulated by culture duration and retinoids. *Exp Dermatol* 1994; 3: 151-60
79. Bauer R, Orfanos CE. Trimethoxyphenylretinoic acid (Ro 10-1670) inhibits mitogen-induced DNA-synthesis in peripheral blood lymphocytes *in vitro*. *Br J Dermatol* 1981; 105: 19-24
80. Bauer R, Orfanos CE. Effects of synthetic retinoids on human peripheral blood lymphocytes and polymorphonuclears *in vitro*. In: Cunliffe WJ, Miller A, editors. *Retinoid therapy*. Lancaster: MTP Press, 1984: 201-18
81. Bauer R, Schütz R, Orfanos CE. Impaired motility and random migration of vital polymorphonuclears *in vitro* after therapy with aromatic retinoid in psoriasis. *Int J Dermatol* 1984; 23: 72-7
82. Béchérel P-A, Mossalayi MD, Le Goff L, et al. Mechanism of anti-inflammatory action of retinoids on keratinocytes. *Lancet* 1994; 344: 1570-1

83. Dubertret L, Lebreton C, Touraine R. Inhibition of neutrophil migration by etretinate and its main metabolite. *Br J Dermatol* 1982; 107: 681-5
84. Orfanos CE, Bauer R. Evidence for antiinflammatory activities of oral synthetic retinoids: experimental findings and clinical experience. *Br J Dermatol* 1983; 109 Suppl. 25: 55-60
85. Imcke E, Ruszczak Zb, Mayer-da-Silva A, et al. Cultivation of human dermal microvascular endothelial cells *in vitro*: immunocytochemical and ultrastructural characterization and effect of treatment with three synthetic retinoids. *Arch Dermatol Res* 1991; 283: 149-57
86. Buck J, Derguini F, Levi E, et al. Intracellular signaling by 14-hydroxy-4,14-retro-retinol. *Science* 1991; 254: 1654-6
87. Halliday GM, Ho KK, Barnetson RS. Regulation of the skin immune system by retinoids during carcinogenesis. *J Invest Dermatol* 1992; 99: 83S-86S
88. Prabhala RH, Maxey V, Hicks MJ, et al. Enhancement of the expression of activation markers on human peripheral blood mononuclear cells by *in vitro* culture with retinoids and carotenoids. *J Leukoc Biol* 1989; 45: 249-54
89. Bollag W. Retinoid and interferon: a new promising combination? *Br J Haematol* 1991; 79 Suppl. 1: 87-91
90. Halewy O, Arazy Y, Melamed D, et al. Retinoic acid receptor-alpha gene expression is modulated by dietary vitamin A and by retinoic acid in chicken T lymphocytes. *J Nutrition* 1994; 124: 2139-46
91. Wozel G, Chang A, Ziltak M, et al. The effect of topical retinoids on the leukotriene-B₄-induced migration of polymorphonuclear leukocytes into human skin. *Arch Dermatol Res* 1991; 283: 158-61
92. Gollnick H, Ehlert R, Rinek G, et al. Retinoids: an overview of pharmacokinetics and therapeutic value. *Methods Enzymol* 1990; 190: 291-304
93. Orfanos CE, Ehlert R, Gollnick H. The retinoids: a review of their clinical pharmacology and therapeutic use. *Drugs* 1987; 34: 459-503
94. Peck GL, Coats-Walton DA. Retinoids in dermatology. Current usage. In: Sober AJ, Fitzpatrick TH, editors. *The Year Book of Dermatology*. St Louis: Mosby, 1995: 1-32
95. Orfanos CE, Schmidt HW, Mahrle G, et al. Retinoic acid in psoriasis: its value for topical therapy with and without corticosteroids. Clinical, histological and electron microscopic studies on forty-four hospitalized patients with extensive psoriasis. *Br J Dermatol* 1973; 88: 167-82
96. Orfanos CE, Schmidt HW, Mahrle G, Runne U. Die Wirksamkeit von Vitamin-A-Säure bei Psoriasis. Topische Kombinationsbehandlung mit Corticoiden. Zwei neue VAS-Präparate zur peroralen Therapie. *Arch Dermatol Forsch* 1972; 244: 424-6
97. Runne U, Orfanos CE, Gartmann H. Perorale Applikation zweier Derivate der Vitamin-A-Säure zur internen Psoriasis-Therapie. 13-cis-beta-Vitamin-A-Säure und Vitamin A-Säure-äthylamid. *Arch Derrn Forsch* 1973; 247: 171-80
98. Lautharanta J, Geiger JM. A double-blind comparison of acitretin and etretinate in combination with bath PUVA in the treatment of extensive psoriasis. *Br J Dermatol* 1989; 121: 107-12
99. Lowe NL, Prystowsky J, Bourget T, et al. Acitretin plus UVB therapy for psoriasis. *J Am Acad Dermatol* 1991; 24: 591-4
100. Ruzicka T, Sommerburg C, Braun-Falco O, et al. Efficiency of acitretin in combination with UV-B in the treatment of severe psoriasis. *Arch Dermatol* 1990; 126: 482-6
101. Orfanos CE, Landes E, Bloch PH. Traitement du psoriasis pustuleux par un nouveau rétinol aromatique (Ro 10-9359). *Ann Dermatol Venerol* 1978; 103: 807-11
102. Lassus A, Geiger JM. Acitretin and etretinate in the treatment of palmoplantar pustulosis: a double-blind comparative trial. *Br J Dermatol* 1988; 119: 755-9
103. Borok M, Lowe N. Pityriasis rubra pilaris. *J Am Acad Dermatol* 1990; 22: 792-5
104. Dieken CH. Treatment of classic pityriasis rubra pilaris. *J Am Acad Dermatol* 1994; 31: 997-1001
105. Gollnick HPM, Orfanos CE. Clinical efficacy of etretinate and acitretin. European experience. In: Psoriasis, Roenigk HH, Maibach HI, editors. New York: Marcel Dekker, 1991: 725-48
106. Hartmann D, Mosberg H, Weber W. Lack of effect of acitretin on the hypoprothrombinemic action of phenprocoumon in healthy volunteers. *Dermatologica* 1989; 178: 33-6
107. Berbis P, Bun H, Geiger JM, et al. Acitretin (Ro 10-1670) and oral contraceptives: interaction study. *Arch Dermatol Res* 1988; 6: 388-9
108. Saurat J-H, Geiger J-M, Amblard P, et al. Randomized double-blind multicenter study comparing acitretin-PUVA, etretinate-PUVA and placebo-PUVA in the treatment of severe psoriasis. *Dermatologica* 1988; 177: 218-24
109. Tanew A, Guggenbichler A, Hoernigsmann H, et al. Photochemotherapy for severe psoriasis without or in combination with acitretin: a randomized, double-blind comparison study. *J Am Acad Dermatol* 1991; 25: 682-4
110. Wright S, Baker H, Warin AP. Treatment of psoriasis vulgaris with a combination of etretinate and hydroxyurea. *J Dermatol Treat* 1990; 1: 211-3
111. Geiger J-M, Czarnetki BM. Acitretin (Ro 10-1670, etretin): overall evaluation of clinical studies. *Dermatologica* 1988; 176: 182-90
112. Lambert WE, De Leenheer AP, De Bersaques JP, et al. Persistent etretinate levels in plasma after changing the therapy to acitretin. *Arch Dermatol Res* 1990; 282: 343-4
113. Steijlen PM, Van Dooren-Greebe RJ, van de Kerkhof PCM. Acitretin in the treatment of lamellar ichthyosis. *Br J Dermatol* 1994; 130: 211-4
114. Jensen BK, Chaws CL, Huselton CA. Clinical evidence that acitretin is esterified to etretinate when administered with ethanol [abstract]. *FASEB J* 1992; 6: A1570
115. Laugier JP, De Sousa G, Bun H, et al. Acitretin biotransformation into etretinate: role of ethanol on *in vitro* hepatic metabolism. *Dermatology* 1994; 188: 122-5
116. Blanchet-Bardon C, Nazzaro V, Roguin C, et al. Acitretin in the treatment of severe disorders of keratinization. Results of an open study. *J Am Acad Dermatol* 1991; 24: 982-6
117. Happle R, Van de Kerkhof PCM, Traupe H. Retinoids in disorders of keratinization: their use in adults. *Dermatologica* 1987; 175 Suppl. 1: 107-24
118. Peck GL, Yoder FW. Treatment of lamellar ichthyosis and other keratinizing disorders with an oral synthetic retinoid. *Lancet* 1976; II: 1172-3
119. Peck GL, Yoder FW, Olsen TG, et al. Treatment of Darier's disease, lamellar ichthyosis, pityriasis rubra pilaris, and basal cell carcinoma with oral 13-cis retinoic acid. *Dermatologica* 1978; 118: 125
120. Christophersen J, Geiger JM, Danneskiold-Samsøe P, et al. A double-blind comparison of acitretin and etretinate in the treatment of Darier's disease. *Acta Derm Venerol* 1992; 72: 150-2

121. Lauharanta J, Kanerva L, Turjanmaa K, et al. Clinical and ultrastructural effects of acitretin in Darier's disease. *Acta Derm Venereol* 1988; 68: 492-8
122. Ridder J, Ferguson D, Kealy T. Organ maintenance of human sebaceous glands: *in vitro* effects of 13-*cis* retinoic acid and testosterone. *J Cell Sci* 1990; 95: 125-36
123. Hurms M, Philippe I, Radeff B, et al. Arotinoid Ro 13-6298 and etretin: two new retinoids inferior to isotretinoin in sebum suppression and acne treatment. *Acta Derm Venereol* 1986; 66: 149-54
124. Geiger J-M. Retinoids and sebaceous gland activity. *Dermatology* 1995; 191: 305-10
125. Strauss JS, Davey WP, Denton SJ, et al. Effect of an orally administered arotinoid, Ro 15-0778, on sebum production in man. *Arch Dermatol Res* 1988; 280: 152-4
126. Vane FM, Chari SS, Shapiro S, et al. Comparison of the plasma and sebum concentrations of the arotinoid Ro 15-0778 and isotretinoin in acne patients. In: Marks R, Plewig G, editors. *Acne and related disorders*. London: Dunitz, 1989: 183-9
127. Saurat J-H, Mérot Y, Borsky M. Arotinoid acid (Ro 13-7410): a pilot study in dermatology. *Dermatologica* 1988; 176: 191-9
128. Peck GL, Olsen TG, Yoder FW, et al. Prolonged remissions of cystic and conglobate acne with 13-*cis* retinoic acid. *N Engl J Med* 1979; 300: 329-33
129. Ott F, Bollag W, Geiger J-M. Oral 9-*cis*-retinoic acid versus 13-*cis*-retinoic acid in acne therapy. *Dermatology* 1996; 193: 124-6
130. Goulden V, Layton AM, Cunliffe WJ. Long-term safety of isotretinoin as a treatment for acne vulgaris. *Br J Dermatol* 1994; 131: 360-3
131. Layton AM, Knaggs H, Taylor J, et al. Isotretinoin for acne vulgaris - 10 years later: a safe and successful treatment. *Br J Dermatol* 1993; 129: 292-6
132. Stainforth JM, Layton AM, Taylor JP, et al. Isotretinoin for the treatment of acne vulgaris: which factors may predict the need for more than one course? *Br J Dermatol* 1993; 129: 297-301
133. Orme M, Back DJ, Shaw MA, et al. Isotretinoin and contraception [letter]. *Lancet* 1984; II (8045): 752-3
134. Santana D, Bun H, Joachim J, et al. Plasma concentrations after three different doses of topical isotretinoin. *Skin Pharmacol* 1994; 7: 140-4
135. Karvonen SJ. Acne fulminans. Report of clinical findings and treatment of twenty-four patients. *J Am Acad Dermatol* 1993; 28: 572-9
136. Ertl GA, Levine N, Kligman AM. A comparison of the efficacy of topical tretinoin and low-dose oral isotretinoin in rosacea. *Arch Dermatol* 1994; 130: 319-24
137. Irvine C, Kumar P, Marks R. Isotretinoin in the treatment of rosacea and rhinophyma. In: Marks R, Plewig G, editors. *Acne and related disorders*. London: Dunitz, 1989: 301-5
138. Schmidt JB, Gebhardt W, Raff M, et al. 13-*cis*-retinoic acid in rosacea. *Acta Derm Venereol* 1984; 64: 15-21
139. Petiau P, Cribier B, Chartier C, et al. Acne necrotica varioliformis: resolution with isotretinoin. *Eur J Dermatol* 1994; 4: 608-10
140. Finkelstein E, Lazarov A, Cagnano M, et al. Oil acne: successful treatment with isotretinoin. *J Am Acad Dermatol* 1994; 30: 491-2
141. Scerri L, Zaki I, Millard LG. Severe halogen acne due to a trifluoromethylpyrazole derivative and its resistance to isotretinoin. *Br J Dermatol* 1995; 132: 144-8
142. Plewig G, Steger M. Acne inversa (alias acne triad, acne tetrad or hidradenitis suppurativa). In: Marks R, Plewig G, editors. *Acne and related disorders*. London: Dunitz, 1989: 345-57
143. Pfahl M. Nuclear receptor/AP-1 interaction. *Endocr Rev* 1993; 14: 651-8
144. Geilen CC, Bektas M, Wieder Th, Orfanos CE. The vitamin D₃ analogue, calcipotriol, induces sphingomyelin hydrolysis in human keratinocytes. *FEBS Lett* 1996; 378: 88-92
145. Hannun YA, Obeid LM. Ceramide: an intracellular signal for apoptosis. *Trends Biol Sci* 1995; 20: 72-7
146. Kalén A, Borchardt RA, Bell RM. Elevated ceramide levels in GH₃C₁ cells treated with retinoic acid. *Biochim Biophys Acta* 1992; 1125: 90-6
147. Bollag W, Holdener EE. Retinoids in cancer prevention and therapy. *Ann Oncol* 1991; 3: 513-26
148. Gollnick H, Orfanos CE. Theoretical aspects of the use of retinoids as anticancer agents. In: Marks R, editor. *Retinoids in cutaneous malignancy*. Oxford: Blackwell, 1991: 41-65
149. Lippman SM, Brenner SE, Hong WK. Cancer chemoprevention. *J Clin Oncol* 1994; 12: 851-73
150. Berth-Jones J, Cole J, Lehmann AR, et al. Xeroderma pigmentosum variant: 5 years of tumour suppression by etretinate. *J Royal Soc Med* 1993; 86: 355-6
151. Hodak E, Ginzburg A, David M, et al. Etretinate treatment of the nevoid basal cell carcinoma syndrome. *Int J Dermatol* 1987; 26: 606-9
152. Goldberg L, Hsu S, Alcalay J. Effectiveness of isotretinoin in preventing the appearance of basal cell carcinomas in basal cell nevus syndrome. *J Am Acad Dermatol* 1989; 21: 144-5
153. Kelly JW, Sabto J, Gurt FW, et al. Retinoids to prevent skin cancer in organ transplant recipients. *Lancet* 1991; 338: 1407
154. Rook AH, Jaworsky C, Nguyen T, et al. Beneficial effect of low-dose systemic retinoid in combination with topical tretinoin for the treatment and prophylaxis of premalignant and malignant skin lesions in renal transplant recipients. *Transplantation* 1995; 59: 714-9
155. Stüttgen G. Zur Lokalbehandlung von Keratosen mit Vitamin A-Säure. *Dermatologica* 1962; 124: 65-80
156. Purcell SM, Pierce DK, Dixon SL, et al. Chemoprevention of actinic keratoses with topical all-*trans* retinoic acid (RA) [abstract]. *J Invest Dermatol* 1986; 86: 501
157. Watson AB. Preventive effect of etretinate therapy on multiple actinic keratoses. *Cancer Detect Prev* 1986; 9: 161-5
158. Alirezai M, Dupuy P, Amblard P, et al. Clinical evaluation of topical isotretinoin in the treatment of actinic keratoses. *J Am Acad Dermatol* 1994; 30: 447-51
159. Misiewicz J, Sendagorta E, Golebiowska A, et al. Topical treatment of multiple actinic keratoses of the face with arotinoid methyl sulfone (Ro 14-9706) cream versus tretinoin cream: a double blind, comparative study. *J Am Acad Dermatol* 1991; 24: 448-51
160. Hong WK, Endicott J, Itri LM, et al. 13-*cis* retinoic acid in the treatment of oral leukoplakia. *N Engl J Med* 1986; 315: 1501-5
161. Toma S, Mangiante PE, Margarino G, et al. Progressive 13-*cis*-retinoic acid dosage in the treatment of oral leukoplakia. *Oral Oncol Eur J Cancer* 1992; 28B: 121-3
162. Shaw JC, White CR. Treatment of multiple keratoacanthomas with oral isotretinoin. *J Am Acad Dermatol* 1986; 15: 1079-82
163. Mensing H, Wagner G. Etretinate-Therapie bei solitären Keratoacanthomen. *Z Hautkr* 1988; 63: 234-6
164. Peck GL. Topical tretinoin in actinic keratosis and basal cell carcinoma. *J Am Acad Dermatol* 1986; 15: 829-35
165. Lippman SM, Parkinson DR, Itri LM, et al. 13-*cis* retinoic acid and interferon alpha-2a: effective combination therapy for advanced squamous cell carcinoma of the skin. *J Natl Cancer Inst* 1992; 84: 241-5

166. Toma S, Palumbo R, Vincenti M, et al. Efficiency of recombinant alpha-interferon 2a and 13-*cis*-retinoic acid in the treatment of squamous cell carcinoma. *Ann Oncol* 1994; 5: 463-5
167. Eisenhauer EA, Lippman SM, Kavanagh JJ, et al. Combination 13-*cis*-retinoic acid and interferon alpha 2a in the therapy of solid tumours. *Leukemia* 1994; 8: 1622-5
168. Schuchter LM, Guerry D, Hamilton R, et al. A phase II study of all-*trans*-retinoic acid in patients with metastatic melanoma. *Proc Am Assoc Cancer Res* 1994; 35: 410
169. Modiano M, Dalton W, Lippman SM, et al. Phase II study of fenretinide (n-(4-hydroxyphenyl)retinamide) in advanced breast cancer and melanoma. *Invest New Drugs* 1990; 8: 317-9
170. Dhingra K, Papadopoulos N, Lippman SM, et al. Phase II study of alpha-interferon and 13-*cis*-retinoic acid in metastatic melanoma. *Invest New Drugs* 1993; 11: 39-43
171. Kessler JF, Jones SE, Levine N, et al. Isotretinoin and cutaneous helper T-cell lymphoma (mycosis fungoides). *Arch Dermatol* 1987; 123: 201-4
172. Molin L, Thomsen K, Volden G, et al. Oral retinoids in mycosis fungoides and Sézary syndrome: a comparison of isotretinoin and etretinate. *Acta Derm Venereol* 1987; 67: 252-6
173. Molin L, Thomsen K, Volden G, et al. Retinoids and systemic chemotherapy in cases of advanced mycosis fungoides. *Acta Derm Venereol* 1987; 67: 179-82
174. Neely SM, Mehlmauer M, Feinstein DI. The effect of isotretinoin in six patients with cutaneous T-cell lymphoma. *Arch Intern Med* 1987; 147: 529-31
175. Zachariae H, Thestrup-Pedersen K. Interferon alpha and etretinate combination treatment of cutaneous T-cell lymphoma. *J Invest Dermatol* 1990; 95 Suppl.: 206-8
176. Tosiagnant J, Raymond GP, Light MJ. Treatment of cutaneous T-cell lymphoma with the retinoid Ro 13-6298. *J Am Acad Dermatol* 1987; 16: 167-71
177. Jones G, McLean J, Rosenthal D, et al. Combined treatment with oral etretinate and electron beam therapy in patients with cutaneous T-cell lymphoma (mycosis fungoides and Sézary syndrome). *J Am Acad Dermatol* 1992; 25: 960-7
178. Gollnick H, Tambaos D, Orfanos CE. Risk factors promote elevations of serum lipids in acne patients under oral 13-*cis*-retinoic acid (isotretinoin). *Arch Dermatol Res* 1981; 271: 189-96
179. Thestrup-Pedersen K, Hammer R, Kaltoft K, et al. Treatment of mycosis fungoides with recombinant interferon-alpha 2a alone and in combination with etretinate. *Br J Dermatol* 1988; 118: 811-8
180. Altomare GF, Capella GL, Pigatto PD, et al. Intramuscular low dose alpha-2b interferon and etretinate for treatment of mycosis fungoides. *Int J Dermatol* 1993; 32: 138-41
181. Dreno B, Celerier P, Litoux P. Roferon-A in combination with Tigason in cutaneous T-cell lymphomas. *Acta Haematol* 1993; 89: 28-32
182. Dreno B, Claudy A, Meynadier J, et al. The treatment of 45 patients with cutaneous T-cell lymphoma with low doses of interferon-alpha 2a and etretinate. *Br J Dermatol* 1991; 125: 455-9
183. Braathen LR, McFadden N. Successful treatment of mycosis fungoides with the combination of etretinate and human recombinant interferon alpha-2a. *J Dermatol Treat* 1989; 1: 29-32
184. Knobler RM, Trautinger F, Radaszkiewicz T, et al. Treatment of cutaneous T-cell lymphoma with combination of low-dose interferon alpha-2b and retinoids. *J Am Acad Dermatol* 1991; 24: 247-52
185. Von Roenn J, von Gunten C, Mullane M, et al. All-*trans* retinoic acid (TRA) in the treatment of AIDS-related Kaposi sarcoma: a phase II Illinois Cancer Center study [abstract]. *Proc Am Soc Clin Oncol* 1993; 12: 51
186. Bonhomme L, Fréj G, Ecstein E, et al. Treatment of AIDS-associated Kaposi's sarcoma with oral tretinoin. *Am J Hosp Pharm* 1991; 51: 2417-9
187. Laurberg G, Geiger JM, Hjorth N, et al. Treatment of lichen planus with acitretin: a double-blind placebo controlled study in 65 patients. *J Am Acad Dermatol* 1991; 24: 434-7
188. Harth W, Richard G. Retinoide in der Therapie des Granuloma anulare disseminatum. *Hautarzt* 1993; 44: 693-8
189. Stavermann T, Adier M, Stadler R. Erfolgreiche Therapie des Granuloma anulare disseminatum mit Etreinat und Prednisolon. *Akt Dermatol* 1990; 16: 76-9
190. Roenigk HH Jr. Liver toxicity of retinoid therapy. *J Am Acad Dermatol* 1988; 19: 199-208
191. Sanchez MR, Ross B, Rotterdam H, et al. Retinoid hepatitis. *J Am Acad Dermatol* 1993; 28: 853-8
192. Vahlquist C, Olsson AG, Lindholm A, et al. Effects of gemfibrozil (Lopid®) on hyperlipidemia in acitretin-treated patients: results of a double-blind cross-over study. *Acta Derm Venereol* 1995; 75: 377-80
193. Colemann R, MacDonald D. Effects of isotretinoin on male reproductive system. *Lancet* 1994; 344: 198
194. Barth JH, MacDonald-Hull SP, Mark J, et al. Isotretinoin therapy for acne vulgaris: a re-evaluation of the need for measurements of plasma lipids and liver function tests. *Br J Dermatol* 1993; 129: 704-7
195. Olsen EA, Weed WW, Meyer CJ, et al. A double-blind, placebo-controlled trial of acitretin for the treatment of psoriasis. *J Am Acad Dermatol* 1989; 21: 681-6
196. Gupta AK, Goldfarb MT, Ellis CN, Voorhees JJ. Side-effect profile of acitretin therapy in psoriasis. *J Am Acad Dermatol* 1989; 20: 1088-93
197. Vahlquist C, Selinus I, Vessby B. Serum lipid changes during acitretin (etretin) treatment of psoriasis and palmoplantar pustulosis. *Acta Derm Venereol* 1988; 68: 300-5
198. Ashley JM, Lowe NI, Borok ME, et al. Fish oil supplementation results in decreased hypertriglyceridemia in patients with psoriasis undergoing etretinate or acitretin therapy. *J Am Acad Dermatol* 1988; 19: 76-82
199. Hohl C, Pelloni F, Sigg C, et al. Prospective study of skeletal changes during short-term acitretin therapy. *Dermatology* 1992; 185: 23-6
200. Silverman AK, Ellis CN, Voorhees JJ. Hypervitaminosis A syndrome: a paradigm of retinoid side effects. *J Am Acad Dermatol* 1987; 16: 1027-39
201. Glover MT, Peters AM, Atherton DJ. Surveillance for skeletal toxicity of children treated with etretinate. *Br J Dermatol* 1987; 116: 609-14
202. Mills CM, Marks R. Adverse reactions to oral retinoids: an update. *Drug Saf* 1993; 9: 280-90
203. Paige DG, Judge MR, Shaw DG, et al. Bone changes and their significance in children with ichthyosis on long-term etretinate therapy. *Br J Dermatol* 1992; 127: 387-91
204. Tangre JA, Kilcoyne RF, Taylor PR, et al. Skeletal hyperostosis in patients receiving chronic, very-low-dose isotretinoin. *Arch Dermatol* 1992; 128: 921-5
205. Simpson KR, Rosenbach A, Lowe NI. Etretinate for retinoid-responsive dermatoses: further observations of long-term therapy. *J Dermatol Treat* 1993; 4: 179-82

206. DiGiovanna JJ, Sollitto RB, Abangan DL, et al. Osteoporosis is a toxic effect of long-term tretinoin therapy. *Arch Dermatol* 1995; 131: 1263-7
207. Callet V, Ochonisky S, Yabres P, et al. Arthrite aiguë au cours d'un traitement par l'isotrétinoïne. *Ann Dermatol Venerol* 1994; 121: 402-3
208. Kistler A. Limb bud cell cultures for estimating the teratogenic potential of compounds: validation of the test system with retinoids. *Arch Toxicol* 1987; 60: 403-14
209. Kochhar DM, Jiang H, Penner JD, et al. The teratogenic activity of 9-*cis*-retinoic acid [abstract]. *Teratology* 1993; 47: 439
210. Kochhar DM, Penner JD, Minutella LM. Biotransformation of tretinoin and developmental toxicity of tretinoin and other aromatic retinoids in teratogenic bioassays. *Drug Metab Dispos* 1989; 17: 618-24
211. Lammer EJ, Chen DT, Hoar RM, et al. Retinoic acid embryopathy. *N Engl J Med* 1985; 313: 837-41
212. Camera G, Pregliasso P. Ear malformation in baby born to mother using tretinoin cream. *Lancet* 1992; 339: 687
213. Jick SS, Terris BZ, Jick H. First trimester topical tretinoin and congenital disorders. *Lancet* 1993; 341: 1181-2
214. Willhite CC, Sharma RP, Allen PV, et al. Percutaneous retinoid absorption and embryotoxicity. *J Invest Dermatol* 1990; 95: 523-9
215. Loeffberg B, Chahoud I, Bochart G, et al. Teratogenicity of the 13-*cis* and all-*trans*-isomers of the aromatic retinoid tretinoin: correlation to transplacental pharmacokinetics in mice during organogenesis after a single oral dose. *Teratology* 1990; 41: 707-16
216. Geiger J-M, Baudin M, Saurat J-H. Teratogenic risk with tretinoin and acitretin treatment. *Dermatology* 1994; 189: 109-16
217. Rinck G, Gollnick H, Orfanos CE. Duration of contraception after tretinoin. *Lancet* 1989; 11: 845-6
218. Stockton DL, Paller AS. Drug administration to the pregnant or lactating woman: a reference for dermatologists. *J Am Acad Dermatol* 1990; 23: 87-103
219. Vahlquist A, Rollmann O. Clinical pharmacology of three generations of retinoids. *Dermatologica* 1987; 175: 20-7
220. Marsden JR. Lipid metabolism and retinoid therapy. *Pharmacol Ther* 1989; 40: 55-65
221. Fex GA, Aronsson A, Andersson A, et al. *In vivo* effects of 13-*cis* retinoic acid treatment on the concentration of proteins and lipids in serum. *Eur J Clin Chem Clin Biochem* 1996; 34: 3-7
222. Halkier-Sørensen L, Laurberg G, Andersen J. Bone changes in children on long-term treatment with tretinoin. *J Am Acad Dermatol* 1987; 16: 999-1006
223. Orfanos CE. Retinoide: der neue Stand. Erhaltungstherapie, Resorptionsstörungen bei 'non-responders', Interaktionen und Interferenzen mit Medikamenten, Behandlung von Kindern und Knochenoxizität. *Acitretin und 13-cis-Acitrein*. *Hautarzt* 1989; 40: 123-9
224. Decker MA, Zimmermann CL. Simultaneous determination of tretinoin, acitretin and their metabolites in perfusate, perfusate plasma, bile or hepatic tissue with reversed-phase high-performance liquid chromatography. *J Chromat B Biomed Appl* 1995; 667: 105-13
225. Leunheer De AP, Lambert WE. High-performance liquid chromatographic determination of tretinoin and all-*trans*- and 13-*cis*-acitretin in human plasma. *J Chromatogr* 1990; 500: 637-42
226. Wyss R. Chromatographic and electrophoretic analysis of biomedically important retinoids. *J Chromatogr B Biomed Appl* 1995; 671: 381-425
227. Jakobsen P. Simultaneous determination of the aromatic retinoids tretinoin and acitretin and their main metabolites by reversed-phase liquid chromatography. *J Chromatogr* 1987; 415: 413-8
228. Wyss R, Bucheli F. Quantitative analysis of retinoids in biological fluids by high-performance liquid chromatography using column switching: II. Simultaneous determination of tretinoin, acitretin and 13-*cis*-acitretin in plasma. *J Chromatogr B Biomed Appl* 1988 431: 297-307
229. Sturkenboom MCJM, de Jong-Van Den Berg LTW, van Voorst-Vader FC, et al. Inability to detect plasma tretinoin and acitretin is a poor predictor of the absence of these teratogens in tissue after stopping acitretin treatment. *Br J Clin Pharmacol* 1994; 38: 229-35
230. Craven NM, Griffiths CEM. Topical retinoids and cutaneous biology. *Clin Exp Dermatol* 1996; 21: 1-10
231. Griffiths CEM, Voorhees JJ. Human *in vivo* pharmacology of topical retinoids. *Arch Dermatol Res* 1994; 287: 53-60
232. Lehmann PA, Malany AM. Evidence for percutaneous absorption of isotretinoin from the photo-isomerization of topical tretinoin. *J Invest Dermatol* 1989; 93: 595-9
233. Lehmann PA, Slatery JT, Franz TJ. Percutaneous absorption of retinoids: influence of vehicle, light exposure, and dose. *J Invest Dermatol* 1988; 91: 56-61
234. Schaefer H. Penetration and percutaneous absorption of topical retinoids. *Skin Pharmacol* 1993; 6 Suppl. 1: 17-23
235. Tavakkol A, Zouboulis ChC, Duell EA, et al. A retinoic acid-inducible skin-specific gene (RIS-1/psoriasis): molecular cloning and analysis of gene expression in human skin *in vivo* and cultured skin cells *in vitro*. *Mol Biol Rep* 1994; 20: 75-83
236. Duell EA, Åström A, Griffiths CEM, et al. Human skin levels of retinoic acid and cytochrome P-450-derived 4-hydroxy-retinoic acid after topical application of retinoic acid *in vivo* compared to concentrations required to stimulate retinoic acid receptor-mediated transcription *in vitro*. *J Clin Invest* 1992; 90: 1269-74
237. Sanquer S, Gilchrist BA. Characterization of human cellular retinoic acid-binding proteins-I and -II: ligand binding affinities and distribution in skin. *Arch Biochem Biophys* 1994; 311: 86-94
238. Elder JT, Cromie MA, Griffiths CEM, et al. Stimulus-selective induction of CRABP-II mRNA: a marker for retinoic acid action in human skin. *J Invest Dermatol* 1993; 100: 356-9
239. Surber C, Laugier JP, Geiger JM, et al. Distribution de l'acitretine dans la peau humaine. *Ann Dermatol Venerol* 1993; 120: 116-22
240. Lavker RM, Leyden JJ, Thorne EG. An ultrastructural study of the effects of topical tretinoin on microcomedones. *Clin Ther* 1992; 14: 773-80
241. Melnik B, Kinner T, Plewig G. Influence of oral isotretinoin treatment on the composition of comedonal lipids. Implications for comedogenesis in acne vulgaris. *Arch Dermatol Res* 1988; 280: 97-102
242. Griffiths CEM, Kang S, Ellis CN, et al. Two concentrations of topical tretinoin (retinoic acid) cause similar improvement of photoaging but different degrees of irritation. *Arch Dermatol* 1995; 131: 1037-44
243. Olsen EA, Katz HI, Levine N, et al. Tretinoin emollient cream: a new therapy for photodamaged skin. *J Am Acad Dermatol* 1992; 26: 215-24
244. Sendagorta E, Lesiewicz J, Armstrong RB. Topical isotretinoin for photodamaged skin. *J Am Acad Dermatol* 1992; 27: S15-18

245. Weinstein GD, Nigra TP, Pochi PE, et al. Topical tretinoin for treatment of photodamaged skin: a multicenter study. *Arch Dermatol* 1991; 127: 659-65
246. Weiss JS, Ellis CN, Headington JT, et al. Topical tretinoin improves photoaged skin: a double-blind, vehicle-controlled study. *JAMA* 1988; 159: 527-32
247. Griffiths CEM, Russman AN, Majumdar G, et al. Restoration of collagen formation in photodamaged human skin by tretinoin (retinoic acid). *New Engl J Med* 1993; 329: 530-5
248. Woodley DT, Zeflickson AS, Briggaman RA, et al. Treatment of photoaged skin with topical tretinoin increases epidermal-dermal anchoring fibrils. *JAMA* 1990; 263: 3057-9
249. Levine N, Kligman AM. A sequential combination of topical tretinoin and a potent topical corticosteroid improves photodamaged facial skin. *J Dermatol Treat* 1996; 7: 23-7
250. Kligman AM, Dogadkina D, Lavker RM. Effects of topical tretinoin on non-sun-exposed protected skin of the elderly. *J Am Acad Dermatol* 1993; 29: 25-33
251. Griffiths CEM, Finkel LJ, Ditre CM, et al. Topical tretinoin (retinoic acid) improves melasma in a vehicle-controlled clinical trial. *Br J Dermatol* 1993; 129: 415-21
252. Bulengo-Ransby SM, Griffiths CEM, Kimbrough-Green CK, et al. Topical tretinoin (retinoic acid) therapy for hyperpigmented lesions caused by inflammation of the skin of black patients. *New Engl J Med* 1993; 328: 1438-43
253. Lippman SM, Meyskens FL. Results of the use of vitamin A and retinoids in cutaneous malignancies. *Pharmacol Ther* 1989; 40: 107-22
254. Kubeyinje EP. Evaluation of the efficacy and safety of 0.05% tretinoin cream in the treatment of plane warts in Arab children. *J Dermatol Treat* 1996; 7: 21-2
255. Ehtert R, Orfanos CE. Lokale Anwendung von Vitamin-A-Säure bei chronischer aktinischer Cheilitis. *Hautarzt* 1989; 40: 728
256. Kang S, Kim KJ, Griffiths CEM, et al. Topical tretinoin (retinoic acid) improves early stretch marks. *Arch Dermatol* 1996; 132: 519-26
257. Buchan R, Eckhoff C, Caron D, et al. Repeated topical administration of all-trans-retinoic acid and plasma levels of retinoic acids in humans. *J Am Acad Dermatol* 1994; 30: 428-34
258. Nau H. Embryotoxicity and teratogenicity of topical retinoic acid. *Skin Pharmacol* 1993; 3 Suppl.: 35-44
259. Griffiths CEM, Elder JT, Bernard BA, et al. Comparison of CD 271 (adapalene) and all-trans retinoic acid in human skin: dissociation of epidermal effects and CRABP II mRNA expression. *J Invest Dermatol* 1993; 101: 325-8
260. Tsambaos D, Orfanos CE. Arotinoid: a new potent oral retinoid. Preliminary results. In Farber, et al., editors. *Psoriasis*. New York: Grune & Stratton, 1982: 515-20
261. Tsambaos D, Orfanos CE. Antipsoriatic activity of a new synthetic retinoid: the arotinoid Ro 13-6298. *Arch Dermatol* 1983; 119: 746-51
262. Brogden RN, Goa KL. Adapalene: a review of its pharmacological properties and clinical potential in the management of mild to moderate acne. *Drugs* 1997 Mar; 53 (3): 511-9

Correspondence and reprints: Prof. Dr *Constantin E. Orfanos*, Department of Dermatology, University Medical Center Benjamin Franklin, The Free University of Berlin, Hinderburgdamm 30, 12200 Berlin, Germany.

J.-P. Ortonne

Service de Dermatologie,
 Hôpital de l'Archet, Nice, France

Oral Isotretinoin Treatment Policy

Do We All Agree?

Key Words

Acne treatment
 Isotretinoin, oral
 Acne treatment guidelines

Abstract

A consensus meeting was held in Brussels in 1995 to review current oral isotretinoin (Roaccutane®/Accutane®) treatment policies among internationally renowned experts and to improve service to needy patients by proposing treatment guidelines based upon a review of 1,000 acne patients who received this therapy. The group agreed that acne conditions warranting oral isotretinoin treatment include severe acne and poorly responsive acne which improves less than 50% after 6 months of therapy with combined oral and topical antibiotics. Furthermore, acne which relapses, scars or induces consequential psychological distress should be treated with oral isotretinoin. Other indications are gram-negative folliculitis, inflammatory rosacea such as rhinophyma, pyoderma faciale, acne fulminans and hidradenitis suppurativa. Treatment was usually initiated at a daily dose of 0.5 mg/kg (but may be higher) and increased to 1.0 mg/kg. Aiming at a total dose of 120–150 mg/kg per treatment course treatment lasted 4–7 months depending upon daily doses. The same dosage guidelines were applied to repeated courses of oral isotretinoin therapy with no evidence of increased risk. Mucocutaneous side-effects were predictable; dose-dependent and systemic side-effects were rarely problematic. Acne patients gain immeasurable physical and emotional relief from isotretinoin treatment and society benefits from limiting bacterial resistance evolution and reducing health care costs.

Twelve dermatologists with special interest in acne treatment, from 7 different countries (10 centres from Australia, France, Germany, Italy, Spain, the UK and the USA) participated in a consensus meeting held in Brussels in 1995 to review current oral isotretinoin treatment policies [1]. Based upon evaluation of the last 100 acne patients treated with oral isotretinoin (Roaccutane®/Accutane®), each participant completed a questionnaire which requested detailed information regarding acne indications, the dose used as well as safety and tolerability. The primary purpose of this survey was to identify the type of acne patients who

were prescribed oral isotretinoin and how the patients were managed. The aim of this paper is to summarize and discuss the conclusions of this international workshop.

Acne Indications

Of the 1,000 patients reviewed, 55% of those who received oral isotretinoin had severe nodular or severe inflammatory acne not responding to conventional treatment (fig. 1). In most countries, the proportion of patients with

KARGER

E-Mail karger@karger.ch
 Fax +41 51 306 12 34
<http://www.karger.ch>

© 1997 S. Karger AG, Basel
 1016-8655/97/1957-0034\$12.00/0

This article is also accessible online at:
<http://BioMedNet.com/karger>

Prof. Jean-Paul Ortonne
 Service de Dermatologie
 Hôpital de l'Archet 2, BP 3079
 F-06202 Nice Cedex 3 (France)

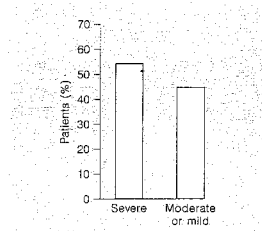


Fig. 1. Acne severity of patients from 7 countries treated with oral isotretinoin (adapted from Cunliffe et al. [1]).

severe acne who were treated with oral isotretinoin varied from 58 to 82%. However, in the Italian clinics and in the UK centres, these percentages were 38 and 15%, respectively [1], which resulted in a mean value of 55% (fig. 1).

The remaining 45% of patients who were prescribed oral isotretinoin had either moderate or mild acne (fig. 1). This subgroup of acne patients represented 85 and 62% in the UK and Italy, whereas in the other countries, the percentage ranged from 18 to 42% [1]. Of the patients with moderate acne, 16.7% had either scars, 18.7% psychological problems or both (64.2%). These figures were 15.5, 19 and 65.5%, respectively, in patients with mild acne non-responsive to long-term antibiotics or appropriate topical therapies [1].

Only 5 patients with acne variants such as acne fulminans, gram-negative folliculitis, rosacea fulminans and acne conglobata were reported in this survey, demonstrating that these unusual forms of acne are rare causes for prescribing oral isotretinoin.

These observations confirmed that the clinical use of oral isotretinoin in the treatment of acne has significantly altered over time. Oral isotretinoin treatment was first introduced as the first-line treatment for patients suffering from severe nodulocystic acne [2, 3]. With increasing clinical experience, however, its use has broadened [4]. All dermatologists participating in the survey agreed that oral isotretinoin should not be limited to patients with severe acne. Patients with moderate or mild acne who respond with <50% improvement after appropriate conventional therapy defined as a 6-month course of oral antibiotics and topical combination therapy should also be prescribed oral isotretinoin.

Acne patients with scarring, a significant psychological disorder or with relapses immediately after alternative therapy are also appropriate candidates for oral isotretinoin therapy. These recommendations are in line with recent studies demonstrating that extent and severity of acne are not the only parameters to be considered for the choice of therapy [4, 5]. The chronic and/or relapsing nature of the disease, the limited benefit of previous conventional therapy, the likelihood of permanent scarring and psychological sequelae should be taken into account when choosing a treatment strategy [6]. The differences in acne types treated with oral isotretinoin are, in part, caused by the way medicine is practised in different countries (availability of oral isotretinoin in hospitals or private offices).

Daily and Cumulative Doses – Duration of Treatment

Although some variation in initial dose was observed between countries, all physicians used a daily dose of 0.5–1 mg/kg, adjusted according to patient tolerability. Most physicians initiated treatment at a daily dose of 0.5 mg/kg and increased it to 1.0 mg/kg either gradually or rapidly. In 2 centres, however, therapy for most patients was started at 1.0 mg/kg/day. All experts agreed that the cumulative dose defined as the total amount of oral isotretinoin taken by the patient during one treatment course is a major factor influencing long-term outcome. The panel also confirmed the commonly held view that optimal results are achieved at a cumulative dose of 120 mg/kg with no further therapeutic gain beyond about 150 mg/kg. The duration of treatment varied from 16 to 30 weeks according to daily doses (table 1).

The clinical experience of all participants supported previous studies demonstrating that optimal benefit is achieved with higher daily doses resulting in long-term remission in 70–80% of patients. Indeed, relapse rates are significantly higher in patients receiving daily doses below 0.5 mg/kg [7, 8]. In patients experiencing a relapse, the same dosages as outlined above for initial therapy apply to repeated courses of isotretinoin therapy with no evidence of increased risk [9].

Side-Effects

Mucocutaneous side-effects, such as dry lips, dry nasal passages and dry eyes, occurred in virtually all patients as was to be expected [10]. Pretreatment counselling and ap-

Table 1. Relationship between daily dose, duration of therapy and cumulative dose

Daily dose, mg/kg	Cumulative dose, mg/kg			
	4 months (120 days)	5 months (150 days)	6 months (180 days)	7 months (210 days)
0.5	60	75	90	105
0.6	72	90	108	126
0.7	84	105	136	147
0.8	96	120	144	168
0.9	108	135	162	189
1.0	120	150	180	210

Adapted from Cunliffe et al. [1].

appropriate information about these predictable and dose-dependent adverse effects were very helpful. In most patients, the regular use of moisturizing agents (e.g. lip salves and artificial tears) usually managed these side-effects quite effectively. Only a small group of patients (4%) experienced troublesome adverse events, in particular headaches, myalgia and arthralgia. These symptoms generally responded to oral paracetamol or non-steroidal anti-inflammatory drugs.

Liver function tests and determination of fasting lipids were performed at baseline by all authors, but the frequency of repeat blood tests varied from centre to centre. Laboratory tests were regularly performed by all but two authors. In none of the 1,000 patients did any laboratory change (mild elevation of fasting lipids and liver enzymes) result in cessation of therapy. The need for regular monitoring of liver function and fasting lipids, provided no changes occur at the end of the first month of treatment, was discussed.

The teratogenic potential of oral isotretinoin requires responsible prescribing physicians and reliable patients. All participants ensured that women of child-bearing potential had a negative pregnancy test when oral isotretinoin therapy was initiated and that reliable contraception was used during and for 1 month after completion of therapy. The 1-month posttherapy contraceptive period includes already a safety margin, since it has now been demonstrated that plasma concentrations of isotretinoin return to physiological levels within 10 days of therapy completion [11].

Cost Savings

Treatment costs for acne patients in a UK centre were evaluated [1]. Actual treatment costs in 364 patients with mild, moderate or severe acne, who were prescribed oral

Table 2. Summary of treatment guidelines

Indications
Severe acne
Moderate acne unresponsive to conventional therapy
Acne relapsing after conventional therapy
Scarring acne
Acne causing significant psychological disorders
Rare acne variants
Dosage
0.5–1.0 mg/kg/day
Cumulative dose: ≥ 120 mg/kg, no further therapeutic gain beyond 150 mg/kg
Duration
From 4 to 7 months according to daily dose
Side-effects
Mucocutaneous side-effects
Appropriate pretreatment counselling
Dose dependency: if necessary, reduction in daily dosage
Teratogenicity
Pregnancy tests prior to treatment
Effective contraception during and for 1 month after therapy

Adapted from Cunliffe et al. [1].

isotretinoin were compared with the theoretical costs of antibiotic treatment revealing cost savings with isotretinoin therapy of approximately 60% over 3 years of rotational antibiotic therapy plus topical agents. This observation is in agreement with previous studies demonstrating the cost-effectiveness of oral isotretinoin in patients with mild, moderate or severe acne [12–15].

Conclusions

The recommendation of the panel was that oral isotretinoin should be prescribed not only to acne patients with severe disease, but also to patients with less severe acne, especially if there is scarring and significant psychological stress associated with their disease (table 2). Patients benefit through improvement in self-esteem, mental health and

social functioning [6, 16, 17]. In economic terms, acne treatment with oral isotretinoin is substantially more cost-effective than conventional therapy, and significant cost savings are well documented- for isotretinoin treatment when the total duration of the disease is taken into account [1, 12-15]. Thus, acne patients should, where appropriate, be prescribed oral isotretinoin sooner rather than later.

References

- Cunliffe WJ, van de Kerkhof PCM, Caputo R, Cavicchini S, Cooper A, Fyrand OL, Gollnick H, Layton AM, Leyden JJ, Mascaro JM, Ortonne JP, Shalita A: Roaccutane treatment guidelines: Results of an international survey. *Dermatology* 1997;194:351-357.
- Jones DH, King K, Miller AJ, Cunliffe WJ: A dose-response study of 13-cis-retinoic acid in acne vulgaris. *Br J Dermatol* 1983;108:333-343.
- Strauss JS, Rapini RP, Shalita AR, Konecny E, Pochi PE, Cornite H, Exner JH: Isotretinoin therapy for acne: Results of a multicenter dose-response study. *J Am Acad Dermatol* 1984;10:490-496.
- Goulden V, Layton AM, Cunliffe WJ: Current indications for isotretinoin as a treatment for acne vulgaris. *Dermatology* 1995;190:284-287.
- Layton AM: Long-term safety and efficacy of oral isotretinoin in less severe acne. *Retinoids Today Tomorrow* 1996;43:6-7.
- Krowchuk DP, Stancin T, Keskinen R, Walker R, Bass J, Anglin TM: The psychosocial effects of acne on adolescents. *Pediatr Dermatol* 1990;8:332-338.
- Layton AM, Cunliffe WJ: Guidelines for optimal use of isotretinoin in acne. *J Am Acad Dermatol* 1992;27:S2-S7.
- Layton AM, Stanforth JM, Cunliffe WJ: Ten years' experience of oral isotretinoin for the treatment of acne vulgaris. *J Dermatol Treat* 1998;4:S2-S5.
- Goulden V, Layton AM, Cunliffe WJ: Long-term safety of isotretinoin as a treatment for acne vulgaris. *Br J Dermatol* 1994;131:360-363.
- Saurat J-H: Side effects of systemic retinoids and their clinical management. *J Am Acad Dermatol* 1992;27:S23-S28.
- Wiegand VW, Cunliffe W, Wyss R, Crevoisier C: Treatment of female patients with isotretinoin: What is the safe post-therapy contraceptive period? *Clin Dermatol* 2000, Vancouver, May 1996, abstract 155.
- Lee ML, Cooper A: Isotretinoin: Cost-benefit study. *Australas J Dermatol* 1991;32:17-20.
- Simpson NB: Social and economic aspects of acne and the cost-effectiveness of isotretinoin. *J Dermatol Treat* 1993;4:S6-S9.
- Wishart J, Villiger J: Cost-benefit of isotretinoin (Roaccutane). *NZ Med J* 1991;104:192.
- Newton J: How cost-effective is Roaccutane? *Dermatology* 1997;195(suppl 1):10-14.
- Berson DS, Shalita AR: The treatment of acne: The role of combination therapies. *J Am Acad Dermatol* 1995;32:S31-S41.
- Rabinow DR, Peck GL, Squillace KM, Gant GG: Reduced anxiety and depression in cystic acne patients after successful treatment with oral isotretinoin. *J Am Acad Dermatol* 1987;17:25-32.

CONTINUING MEDICAL EDUCATION

Pseudotumor Cerebri after Treatment with Tetracycline and Isotretinoin for Acne

Andrew G. Lee, MD, Houston, Texas

Goal

To identify the relationship between pseudotumor cerebri and therapy with tetracycline and vitamin A analogs for acne.

Objectives

1. To describe the most common clinical findings with pseudotumor cerebri.
2. To discuss the long-term effects of concomitant tetracycline and vitamin A analogs.
3. To determine the safest therapy for treatment of acne with combination agents.

CME Test on page 177

Tetracyclines and isotretinoin are widely used treatments for patients with acne. Although generally safe, the use of these agents has been associated with pseudotumor cerebri and combination therapy with these agents may increase the risk for pseudotumor cerebri.

A 14-year-old boy presented with headaches and bilateral visual loss secondary to papilledema. He had been treated with tetracycline and isotretinoin for acne for three weeks prior to presentation and was subsequently diagnosed as having pseudotumor cerebri. He required long-term medical therapy and eventually underwent bilateral optic nerve sheath decompression. The literature regarding pseudotumor cerebri in association with tetracyclines and isotretinoin treatment for acne is reviewed.

Dermatologists should be aware of the risk of pseudotumor cerebri in patients receiving tetracycline or isotretinoin treatment for acne and should be particularly cautious about using both agents simultaneously.

Tetracycline, minocycline, and isotretinoin are widely used, safe, and effective treatments for patients with acne. Several reports, however, have described pseudotumor cerebri after treatment for acne with tetracyclines¹⁻³ such as minocycline, and after vitamin A therapy including isotretinoin (13-cis-retinoic acid, Accutane®).^{4,5} A case of pseudotumor cerebri is described fol-

Dr. Lee is an instructor with the Department of Ophthalmology, Cullen Eye Institute, Baylor College of Medicine, Houston, Texas. REPRINT REQUESTS to the Neuro-Ophthalmology Unit, Cullen Eye Institute, Departments of Ophthalmology, Neurology and Neurosurgery, 6501 Fannin Street, NC-200, Baylor College of Medicine, Houston, Texas 77030.

lowing tetracycline and isotretinoin treatment for acne in a 14-year-old boy. The literature is reviewed on the association of pseudotumor cerebri in patients treated for acne with these agents. The potential increased risk of pseudotumor cerebri following combination therapy with these medicines is emphasized.

Case Report

A 14-year-old white boy was diagnosed with acne by a dermatologist. The patient was treated with oral tetracycline at a dosage of 500 mg per day without complication but the acne did not improve. Nine months later he was treated with isotretinoin at a dosage of 40 mg per day and the tetracycline was discontinued. At the end of that month, the tetracycline was restarted at a dosage of 500 mg per day, and over the next three weeks the patient noted decreased visual function in both eyes. Ophthalmologic examination revealed a visual acuity of 20/30 in each eye and bilateral optic disc edema. The tetracycline and isotretinoin were subsequently discontinued. Magnetic resonance imaging of the brain showed normal findings and a lumbar puncture showed an opening pressure of 28 cm of water but was otherwise normal. He was treated with oral acetazolamide 1000 mg per day. Results of repeat magnetic resonance imaging of the brain, routine chemistries, syphilis serology, complete blood count, chest radiograph, and cerebral arteriography were all normal. Seven months later visual field testing revealed an inferonasal defect in the right eye and a superior paracentral defect in the left eye. Bilateral optic disc edema was still present, however, and prednisone, 60 mg per day, was added to his treatment regimen. A repeat lumbar puncture revealed an opening pressure of 30 cm of water and the patient underwent optic nerve sheath decompression of the left eye, followed one month later by optic nerve sheath decompression of the

TABLE I
TETRACYCLINE TREATMENT FOR ACNE AND PSEUDOTUMOR CEREBRI

Author	Age/Gender	Duration and Dose	Symptoms	Other Treatments for Acne	Treatment	Course
Minocycline						
Debnay	29 F	6 months 250 mg BID	Headache, papilledema OU	Tretinoin ointment Chicken livers	Acetazolamide, furosemide	Resolved after 10 days
Lander	16 F	4 months 200 mg/day	Headache, transient obscurations of vision, visual loss, and papilledema OU	—	Steroids	Improved after 6 weeks, persistent nasal visual field defects
	18 F	18 months 100 mg BID	Headache, transient obscurations of vision, papilledema OU	—	Steroids for 4 weeks, acetazolamide	Resolved after 4 months
	19 F	4 months 100 mg/day	Headache, vomiting, abducens palsy OS, papilledema OU	—	Steroids	Resolved after 2 months
	15 F	3 weeks 100 mg/day	Headache, hesitancy, ataxia, papilledema OU	—	Steroids	Resolved after 6 weeks
Beran	13 F	2 months 100 mg BID	Headache, vomiting, abducens palsy OD, papilledema OU	Tetracycline 250 mg BID x 4 months	—	Resolved after 4 months
Monaco	16 F	2 weeks 200 mg/day	Headache, vertigo, abducens palsy OS, papilledema OU	—	Mannitol, steroids	Resolved after 1 month
Walters	18 F	6 months 100 mg BID	Headache, abducens palsy OU, vomiting, papilledema OU	—	Steroids	Resolved after 3 weeks
Donnet	16 F	6 weeks 100 mg BID	Headache, abducens palsy OS, visual loss, and papilledema OU	—	Lumboperitoneal shunt	Improved at 8 months but persistent visual field loss OU
Lubetzki	19 F	1 month 100 mg/day	Headache, abducens palsy OU, papilledema OU	—	Steroids	Improved after 1 month
Spector	14 F	5 weeks 100 mg BID	Headache, transient visual obscurations, papilledema OU	Excessive doses of isotretinoin (120 mg BID)	—	Improved after 2 weeks Recurred, then resolved after stopping medicine for second time
Tetracycline						
Pierog	15 F	2 weeks 500 mg QID	Headache, diplopia, papilledema OU	—	Steroids	Resolved after 6 weeks
Pearson	18 F	6 months 250 mg TID	Headache, vomiting, abducens palsy OS, papilledema OU	Vitamin A 50,000 U/day	—	Resolved after 2 weeks
Walters	19 F	15 months ? dose	Headache, nausea, tinnitus, unsteady papilledema OU	Vitamin A stopped 8 months prior	Steroids	Resolved at 7 weeks, tetracycline restarted without recurrence at 21 months follow-up
	22 F	1 week 250 mg/day	Headache, blurred vision, and papilledema, OD only	—	Steroids acetazolamide	"Papilledema" OD unchanged 1 year later Symptoms resolved after 5 days
	18 F	6 months 1 gm/day	Headache, vomiting, abducens palsy OU, papilledema OU	Vitamin A 50,000 U/QOD	Steroids	Resolved after 2 weeks
Stuart	14 F	2 months 1 gm/day	Headache, vomiting, abducens palsy OD	—	—	Resolved after 2 weeks
Ohlrich	16 F	2 weeks 250 mg QID	Headache, vomiting, papilledema OU	—	—	Resolved after 2 weeks
Giles	16 F	5 months 150-300mg per day	Headache, vomiting, papilledema OU	—	—	Resolved after 6 weeks
Roytman	16 F	2 months 1 gm/day stopped 2 mos prior	Headaches, decreased night vision, papilledema OU	Isotretinoin 40 mg/day	Steroids	Resolved after 6 weeks
Lee	14 M	3 weeks 250 mg BID	Headache, visual loss, papilledema OU	Isotretinoin 40 mg/day	Acetazolamide, prednisone, optic nerve sheath fenestration OU	Improved Slow recovery after 18 months Visual field defects remain OU Postpapilledema optic atrophy

OS, oculus sinister; OD, oculus dexter; OU, oculus uterque

right eye. The patient experienced improvement in visual function of both eyes postoperatively. The prednisone was discontinued but he continued taking acetazolamide, with gradual improvement of the bilateral disc edema. Visual field testing continued to show a residual nasal field defect in the right eye and a superior arcuate field defect in the left eye. Eight months later, ophthalmologic examination revealed a visual acuity of 20/20 in both eyes, minimal optic disc swelling with postpapilledema optic atrophy, and a stable but unchanged visual field defect in both eyes.

Comments

The clinical features of pseudotumor cerebri include signs and symptoms due to increased intracranial pressure such as headache, nausea, vomiting, transient visual obscurations, unilateral or bilateral abducens nerve palsy, or papilledema; an elevated intracranial pressure with normal cerebrospinal fluid contents; and normal findings on computed tomographic or magnetic resonance scan of the brain.²⁵

Despite the widespread use of tetracyclines and isotretinoin in the treatment of patients with acne, pseudotumor cerebri remains an uncommon adverse effect of these treatments. Askmark and colleagues reported 162 cases of pseudotumor cerebri in association with various medicines and found fifteen cases (9 percent) due to minocycline, nine cases (5.5 percent) due to tetracycline, and two cases (1.2 percent) due to isotretinoin.¹³ Griffin reported twenty-three cases of tetracycline-associated pseudotumor cerebri, of which seven cases were associated with minocycline.²⁶ Despite these reports, these agents are uncommon causes of pseudotumor cerebri. In two large series of pediatric patients with pseudotumor cerebri, Greer²⁸ reported only one case due to tetracycline (2 percent) in forty-eight patients and Grant²⁹ reported only one case due to tetracycline in seventy-nine patients (1.3 percent).

Table 1 summarizes the clinical findings in twenty-one patients documented in the literature who showed pseudotumor cerebri after treatment for acne with tetracyclines with or without vitamin A analogs. Of these twenty-one patients, twenty patients were female (95 percent) and one patient was male (5 percent). Patients' ages ranged from 13 years to 29 years (mean age, 17 years). Headache, which was usually severe, and papilledema were present in all patients (100 percent) and a unilateral or bilateral abducens nerve palsy was present in nine patients (43 percent). Transient or permanent visual loss was reported in seven patients (33 percent).

Seven patients (33 percent) had concomitant vitamin A analog therapy for acne. Of these seven patients, vitamin A supplements were used in three patients, tretinoin ointment and chicken liver in one patient, and isotretinoin in three patients. Most patients were treated medically with agents to lower intracranial pressure, such as steroids, acetazolamide, mannitol, furosemide, or a combination of these agents. Seventeen patients (81 percent) experienced resolution of symptoms several weeks to months after the acne treatments were discontinued. Three patients (14 percent), however, including the patient reported here, had a residual visual deficit and one patient (5 percent) had no symptoms after discontinuing therapy but had persistent papilledema one year later. Two patients required surgical

therapy for pseudotumor cerebri: a lumbar peritoneal shunt in one patient and bilateral optic nerve sheath decompression in the case reported here.

Eleven patients (52 percent) were treated with minocycline and ten patients (48 percent) were treated with tetracycline. Minocycline, a semisynthetic derivative of tetracycline, may be more likely than other tetracyclines to result in pseudotumor cerebri due to the greater lipid solubility, greater penetration of the blood-brain barrier, and higher cerebrospinal fluid levels of this agent.¹

The association of pseudotumor cerebri and tetracyclines does not seem to be dependent on dose or duration of treatment. In fact, acute increased intracranial pressure has been reported in an infant after a single 75 mg dose of tetracycline.²⁸ Among the twenty-one patients listed in Table 1, the duration of treatment ranged from one week to fifteen months (mean, 15.8 weeks). The dosage of minocycline ranged from 100 to 500 mg per day and that of tetracycline ranged from 250 to 1000 mg per day.

Several authors have suggested that patients treated with both tetracycline and vitamin A may be at higher risk for pseudotumor cerebri.^{10,17,23} Shalita and colleagues reported three patients with pseudotumor cerebri associated with isotretinoin who were receiving concomitant minocycline or tetracycline therapy. In a later report, Shalita and colleagues recommended that "patients taking isotretinoin should not receive tetracycline or minocycline, because these drugs have also occasionally produced benign intracranial hypertension."²¹ Bigby and colleagues reported 104 suspected adverse reactions in ninety-three patients taking isotretinoin. Severe headache was the most frequently reported adverse reaction in ten patients; four patients were shown to have pseudotumor cerebri. Three of the reported patients with headache were taking concomitant tetracyclines and one patient had a history of pseudotumor cerebri while taking minocycline.¹⁴ Fraunfelder and colleagues reviewed 237 patients taking isotretinoin and found eighteen patients in whom papilledema occurred when they were taking normal dosages of the medication.¹⁹ Of these eighteen patients, eight were taking concomitant tetracycline or minocycline and seven were diagnosed with pseudotumor cerebri.

Spector and colleagues reported the case of a 14-year-old girl treated with minocycline and excessive amounts of isotretinoin in whom headaches and transient visual obscurations occurred after five weeks. Her condition improved two weeks after discontinuing the medicines but she experienced a recurrence after resuming isotretinoin treatment. Her symptoms subsequently resolved after the medication was discontinued for the second time.¹⁸ Roytman and colleagues reported the case of a 16-year-old girl treated with tetracycline two months before starting treatment with isotretinoin. One month later, she experienced severe headaches, impaired night vision, and dizziness. Papilledema was noted and the patient had a normal computed tomographic scan but refused to undergo a lumbar puncture. She was treated with dexamethasone for two weeks and was asymptomatic after six weeks.⁴

Pseudotumor cerebri in adults is more common in females²⁹ by a ratio of 2:1 to 5:1. There seems to be a similar female preponderance among patients who showed

pseudotumor cerebri after treatment with tetracyclines with or without isotretinoin. This gender bias may represent a selection bias due to the increased percentage of females in the patient population undergoing treatment for acne; a sampling error due to the small numbers of patients reported with this condition; or underlying female, possibly hormonal, risk factors for the occurrence of pseudotumor cerebri in general. Nevertheless, the patient reported here is the first case, to my knowledge, of pseudotumor cerebri occurring after tetracycline and isotretinoin therapy for acne reported in a male patient.

Dermatologists should be aware of the association of tetracycline, minocycline, and isotretinoin with pseudotumor cerebri and should be particularly cautious when using these medications in combination for the treatment of acne. Prompt discontinuation of the offending agent and ophthalmologic consultation should be considered in any patient undergoing treatment with these agents who experiences symptoms of headache, nausea and vomiting, blurred vision, double vision, or transient visual obscurations. Although most patients recover fully after discontinuation of the offending medicines, this case illustrates that chronic medical therapy or even surgical treatment may be required in some patients.

REFERENCES

- Beran RG: Pseudotumor cerebri associated with minocycline therapy for acne. *Med J Aust* 1: 323-324, 1980.
- Delaney RA, Wee D, Narayanaswamy TR: Pseudotumor cerebri and acne. *Milit Med* 155: 511, 1990.
- Donnet A, Dufour H, Gaziani N, et al: Minocycline and benign intracranial hypertension. *Biomed Pharmacother* 46: 171-172, 1992.
- Giles CL, Sobie AR: Intracranial hypertension and tetracycline therapy. *Am J Ophthalmol* 72: 981-982, 1971.
- Monaco F, Agnetti V, Mutani R: Benign intracranial hypertension after minocycline therapy. *Eur Neurol* 17: 48-49, 1978.
- Ohlrich GD, Ohlrich HG: Papilloedema in an adolescent due to tetracycline. *Med J Aust* 1: 334-335, 1977.
- Pearson MG, Littlewood SM, Bowden AN: Tetracycline and benign intracranial hypertension. *Br Med J* 282: 568-569, 1981.
- Pierog SH, Al-Salifi FL, Choti D: Pseudotumor cerebri—a complication of tetracycline treatment of acne. *J Adolesc Health Care* 7: 139-140, 1986.
- Stuart BH, Litt IP: Tetracycline-associated intracranial hypertension in an adolescent: a complication of systemic acne therapy. *J Pediatr* 92: 679-680, 1978.
- Walters BNJ, Gubbay SS: Tetracycline and benign intracranial hypertension: report of five cases. *Br Med J* 282: 19-20, 1981.
- Lander CM: Minocycline induced benign intracranial hypertension. *Clin Exp Neurol* 26: 161-167, 1989.
- Lubetaki C, Sanson M, Cohen D, et al: Benign intracranial hypertension due to tetracyclines. *Rev Neurol (Paris)* 144: 218-220, 1988.
- Askmark H, Lundberg PO, Olsson S: Drug related headache. *Headache* 28: 441-444, 1989.
- Bigby M, Stern RS: Adverse reactions to isotretinoin. A report from the adverse drug reaction reporting system. *J Am Acad Dermatol* 18: 543-552, 1988.
- Farris WA, Erdman JW: Protracted hypervitaminosis A following long-term, low-level intake. *JAMA* 247: 1317-1318, 1982.
- Roytman M, Frumkin A, Bohn TG: Pseudotumor cerebri caused by isotretinoin. *Cutis* 42: 399-400, 1988.
- Shalita AR, Cunningham WJ, Leyden JJ, et al: Isotretinoin treatment of acne and related disorders: an update. *J Am Acad Dermatol* 9: 629-638, 1983.
- Spector RH, Carlisle J: Pseudotumor cerebri caused by a synthetic vitamin A preparation. *Neurology* 34: 1509-1511, 1984.
- Fraunfelder FT, LaBraico JM, Meyer SM: Adverse ocular reactions possibly associated with isotretinoin. *Am J Ophthalmol* 100: 534-537, 1985.
- Griffin JP: A review of the literature on benign intracranial hypertension associated with medication. *Advers Drug React Toxicol Rev* 11(1): 41-58, 1992.
- Shalita AR, Armstrong RB, Leyden JJ, et al: Isotretinoin revisited. *Cutis* 42: 1-19, 1988.
- Lombaert A, Caron H: Benign intracranial hypertension due to hypervitaminosis in adults and adolescents. *Eur Neurol* 14: 340-350, 1976.
- Gross EG, Helfgott MA: Retinoids and the eye. *Dermatol Clin* 10: 521-531, 1992.
- Adverse effects with isotretinoin. *FDA Drug Bull* 13: 21-23, 1983.
- Ahlskog JE, O'Neill BP: Pseudotumor cerebri. *Ann Intern Med* 97: 249-256, 1982.
- Greer M: Benign intracranial hypertension (pseudotumor cerebri). *Pediatr Clin North Am* 14: 819-830, 1967.
- Grant DN: Benign intracranial hypertension. *Arch Dis Child* 46: 651-655, 1977.
- O'Doherty NJ: Acute benign intracranial hypertension in an infant receiving tetracycline. *Dev Med Child Neurol* 7: 677, 1965.

N. Goulden
A.M. Layton
W.J. Cunliffe

Dermatology Department,
General Infirmary at Leeds, UK

Current Indications for Isotretinoin as a Treatment for Acne vulgaris

Key Words

Isotretinoin
Acne vulgaris
Psychological disturbance

Abstract

Background: There is at present little published information on the current indications for isotretinoin as a treatment of acne vulgaris. **Objectives:** To investigate the factors which influence our current prescribing of isotretinoin: acne severity, response to previous therapy, scarring and psychological effect. **Methods:** Data on the factors influencing treatment of 200 patients with isotretinoin between January 1993 and May 1994 were examined. **Results:** 41% of patients were prescribed isotretinoin for partial response to previous therapy, 26% for partial therapy and scarring and 17% for partial response to treatment and psychological disturbance. Only 16 patients received isotretinoin for severe acne. **Conclusion:** Patients who show only partial response to conventional antibiotic therapy should be prescribed isotretinoin in order to minimize scarring and significant psychological disturbance, independently of the severity of the acne.

Over the past 10 years, isotretinoin has revolutionized the treatment of acne vulgaris. It is now established as a uniquely successful therapy with the ability to induce long-term remission [1, 2]. Initially its principal use was in the treatment of severe nodular cystic acne, but in recent years dermatologists have increasingly prescribed isotretinoin to treat patients with moderate or even mild acne, unresponsive to conventional antibiotic therapy. There is, however, little published information on the severity of acne for which isotretinoin is currently being prescribed. Scarring is an important consideration in the early selection of patients as there is no really effective treatment for this problem. The psychological effect of the acne also influences patient selection as it can often impinge on patients' working and social life and in extreme cases lead to frank depression.

The purpose of this study is therefore to investigate the current indications for isotretinoin in patients attending the out-patient dermatology department at Leeds, UK.

Patients and Methods

Two hundred patients, who had attended the out-patient department at Leeds General Infirmary between January 1993 and May 1994 and received a first course of isotretinoin as a treatment for acne vulgaris, were included in the study.

For each patient, the severity and distribution of the acne was recorded, using the Leeds grading technique [3] to assess the acne on the face, back and chest. The scores were then added to give a total acne grade for each patient. The overall duration of the acne prior to treatment with isotretinoin and the factors which had influenced the decision to treat each patient were recorded. These included total acne grade, distribution of the acne, response to previous treatment, scarring and psychological effect. During the period covered by this study it was not yet an established routine to accurately grade acne scarring and formally assess the psychological state of patients. The presence or absence of these factors was therefore recorded for each patient. Statistical analysis was performed using the χ^2 test.

Received:
June 27, 1994
Accepted:
October 27, 1994

Dr. V. Goulden
Department of Dermatology
General Infirmary at Leeds
Great George Street
Leeds LS1 3EX (UK)

© 1995 S. Karger AG, Basel
1018-8665/95/1904-0284
\$ 8.00/0

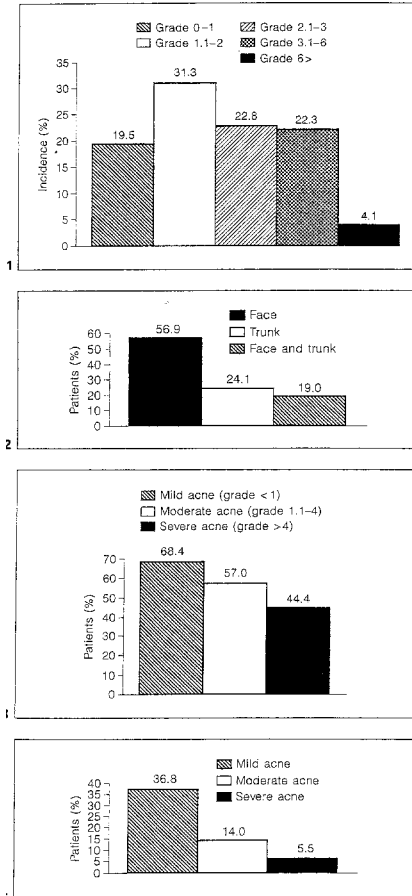


Fig. 1. Range of total acne grades in patients in the study.
Fig. 2. Main site involvement of acne in patients in the study.
Fig. 3. Facial distribution of acne in patients with different acne grades.
Fig. 4. Psychological effect of acne influencing the decision to prescribe isotretinoin in patients with different acne grades.

Table 1. Demographic details of patients in the study

Number of patients	200
Males	109
Females	91
Mean age, years	22.7 (13-42)
Mean total acne grade (0.25-16)	2.65
Mean duration of acne, years	8.3 (2-30)

Figures in parentheses indicate ranges.

Results

Two hundred patients (109 males and 91 females) were included in the study. Their ages ranged from 13 to 42 years (mean 22.7 years). The mean duration of the acne prior to treatment with isotretinoin was 8.3 years (2-30 years). The mean total acne grade was 2.65 (0.25-16; table 1).

Treatment regimens prior to isotretinoin had principally consisted of 3 consecutive courses of antibiotics for a minimum period of 4 months each. The most frequently used regimen consisted of erythromycin or oxytetracycline followed by minocycline and trimethoprim. Doxycycline was also frequently prescribed. Fourteen percent of female patients had also been treated with oestrogen combined with cyproterone acetate (Dianette). Isotretinoin was prescribed at two types of dosage regimens. Patients with severe acne, younger patients and male patients were treated with isotretinoin 1.0 mg/kg/day; patients with less severe acne, especially female patients, and patients with predominantly facial acne were usually prescribed isotretinoin 0.5 mg/kg/day. The dose was altered, if necessary, on review according to response and side-effects. At the end of the treatment period, all patients had shown a >95% improvement in their acne. Twenty-eight percent of patients required longer than 4 months of treatment to obtain a satisfactory response (maximum 8 months). The majority of patients who responded slowly to treatment were found to have macrocomedones which were subsequently treated by light cautery.

Figure 1 shows the proportion of patients with different total acne grades. Just over half the patients had a total acne grade of 2 or less, with 19.5% having a grade of 1 or less. Severe acne (grade > 4) was present in 16% of patients.

Figure 2 shows the distribution of the acne in the patients in the study. Acne distribution showed a significant difference ($p < 0.05$) in patients with different acne grades. Predominantly facial acne was present in 44.4% of patients

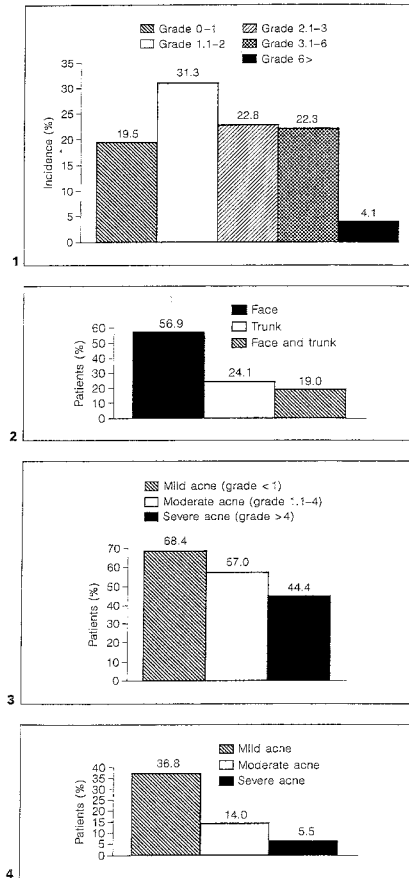


Fig. 1. Range of total acne grades in patients in the study.

Fig. 2. Main site involvement of acne in patients in the study.

Fig. 3. Facial distribution of acne in patients with different acne grades.

Fig. 4. Psychological effect of acne influencing the decision to prescribe isotretinoin in patients with different acne grades.

Table 1. Demographic details of patients in the study

Number of patients	200
Males	109
Females	91
Mean age, years	22.7 (13-42)
Mean total acne grade (0.25-16)	2.65
Mean duration of acne, years	8.3 (2-30)

Figures in parentheses indicate ranges.

Results

Two hundred patients (109 males and 91 females) were included in the study. Their ages ranged from 13 to 42 years (mean 22.7 years). The mean duration of the acne prior to treatment with isotretinoin was 8.3 years (2-30 years). The mean total acne grade was 2.65 (0.25-16; table 1).

Treatment regimens prior to isotretinoin had principally consisted of 3 consecutive courses of antibiotics for a minimum period of 4 months each. The most frequently used regimen consisted of erythromycin or oxytetracycline followed by minocycline and trimethoprim. Doxycycline was also frequently prescribed. Fourteen percent of female patients had also been treated with oestrogen combined with cyproterone acetate (Dianette). Isotretinoin was prescribed at two types of dosage regimens. Patients with severe acne, younger patients and male patients were treated with isotretinoin 1.0 mg/kg/day; patients with less severe acne, especially female patients, and patients with predominantly facial acne were usually prescribed isotretinoin 0.5 mg/kg/day. The dose was altered, if necessary, on review according to response and side-effects. At the end of the treatment period, all patients had shown a >95% improvement in their acne. Twenty-eight percent of patients required longer than 4 months of treatment to obtain a satisfactory response (maximum 8 months). The majority of patients who responded slowly to treatment were found to have macrocomedones which were subsequently treated by light cautery.

Figure 1 shows the proportion of patients with different total acne grades. Just over half the patients had a total acne grade of 2 or less, with 19.5% having a grade of 1 or less. Severe acne (grade >4) was present in 16% of patients.

Figure 2 shows the distribution of the acne in the patients in the study. Acne distribution showed a significant difference ($p < 0.05$) in patients with different acne grades. Predominantly facial acne was present in 44.4% of patients

quently has psychological consequences. Scarring influenced the decision to treat with isotretinoin in 26% of our patients.

The psychological effect of acne on patients should not be underestimated. Acne has been shown to have a significant psychological and social impact on patients. Jowett and Ryan [9] reported that 70% of patients with acne in their study expressed feelings of embarrassment, 63% anxiety and 27% frank depression. Patients also felt that their working lives were affected, with 14% claiming that they experienced limitations of opportunity, 17% functional difficulty and 45% interpersonal difficulties at work. A study carried out in the Leeds area showed that a higher proportion of patients with acne, in the age group from 18 to 30 years, were unemployed compared to matched controls [10]. Psychological effects of the acne influenced the prescribing decision in 17% of patients in our study. Visible acne has been shown to be considered socially unacceptable and disfiguring by acne patients [9]. It is not surprising, therefore, that patients with mild acne, who were treated with isotretinoin, had acne principally distributed on

the face. The majority (75%) of these patients were women. Patients with less severe acne, especially female patients with predominantly facial acne, require lower doses of isotretinoin (0.5 mg/kg/day) to obtain a clearance of their acne. The rate of relapse in this group will be an important issue. However, a follow-up of 3–5 years is necessary to obtain this information and is not yet available in our department.

Our study shows that the indications for isotretinoin have significantly altered over the past several years. The majority of patients now receiving isotretinoin have moderate acne unresponsive to conventional antibiotics. A predominantly facial distribution and the scarring and psychological effect of the acne are important factors in the decision to treat patients with isotretinoin. As might be expected, this uniquely effective drug, for which there is now long-term experience, is being increasingly prescribed for less severe acne unresponsive to other forms of therapy. It remains an expensive drug, but compared to prolonged treatment with systemic antibiotics, it can be considered cost effective [11–13].

References

- Layton AM, Knaggs H, Taylor J, et al: Isotretinoin for acne vulgaris – 10 years later: A safe and successful treatment. *Br J Dermatol* 1993; 129:292–296.
- Lehucher-Ceyrac D, Weber-Buisset MJ: Isotretinoin and acne: A prospective analysis of 188 cases over 9 years. *Dermatology* 1993; 188:123–128.
- Burke BM, Cunliffe WJ: The assessment of acne vulgaris: The Leeds technique. *Br J Dermatol* 1984;111:83–92.
- Goulden V, Layton AM, Cunliffe WJ: Long-term safety of isotretinoin as a treatment for acne vulgaris. *Br J Dermatol* 1994;131: 360–363.
- Cunliffe WJ, Layton AM: Oral isotretinoin: Patient selection and management. *J Dermatol Treat* 1993;4(suppl 2):S10–S15.
- Layton AM, Cunliffe WJ: Guidelines for the optimal use of isotretinoin in acne. *J Am Acad Dermatol* 1992;2:S2–S7.
- Layton AM, Hughes BR, MacDonald Hull S: Seborrhoea: An indicator for poor clinical response in acne patients treated with antibiotics. *Clin Exp Dermatol* 1992;17:173–175.
- Layton AM, Henderson K, Cunliffe WJ: A clinical assessment of acne scarring. *Clin Exp Dermatol*, in press.
- Jowett S, Ryan T: Skin disease and handicap: An analysis of the impact of skin conditions. *Soc Sci Med* 1985;20:425–429.
- Cunliffe WJ: Unemployment and acne. *Br J Dermatol* 1986;115:386.
- Cunliffe WJ, Gray JA, MacDonald Hull S, et al: Cost-effectiveness of isotretinoin. *J Dermatol Treat* 1991;1:285–288.
- Lafange H, Levy PE: Evaluation économique d'une innovation médicamenteuse: le traitement de l'acné sévère par Roaccutane. *J Econ Méd* 1987;5(3):117–127.
- Simpson NB: Social and economic aspects of acne and the cost-effectiveness of isotretinoin. *J Dermatol Treat* 1993;4(suppl 2): S6–S9.

W.J. Cunliffe^a
 P.C.M. van de Kerkhof^b
 R. Caputo^c
 S. Cavicchini^d
 A. Cooper^e
 O.L. Fyrand^f
 H. Gollnick^g
 A.M. Layton^h
 J.J. Leydenⁱ
 J.-M. Mascaró^j
 J.-P. Ortonne^k
 A. Shalita^l

- ^a Leeds General Infirmary, Leeds, and
^b Harrogate District Hospital, Harrogate, UK;
^c University of Nijmegen, The Netherlands;
^d University of Milano, Italy;
^e Royal North Shore Hospital,
 University of Sydney, Australia;
^f Rikshospitalet, Oslo, Norway;
^g University of Magdeburg, Germany;
^h University of Pennsylvania, Philadelphia,
 Pa., and
ⁱ State University of New York at Brooklyn,
 N.Y., USA;
^j University of Barcelona, Spain;
^k Hôpital Pasteur, Nice, France

Key Words

Acne treatment
 Isotretinoin, oral

Roaccutane Treatment Guidelines: Results of an International Survey

Abstract

Background: Oral isotretinoin (Roaccutane®) revolutionized the treatment of acne when it was introduced in 1982. **Methods:** Twelve dermatologists from several countries with a special interest in acne treatment met to formally review the survey of their last 100 acne patients treated with oral isotretinoin. The primary purpose of the survey was to identify the types of acne patients who were prescribed oral isotretinoin and how the patients were managed. **Results:** Of the 1,000 patients reviewed, 55% of those who received oral isotretinoin had those indications treated historically, i.e. severe nodular cystic acne or severe inflammatory acne, not responding to conventional treatment. Forty-five percent of patients who were prescribed oral isotretinoin however had either moderate or mild acne. Most patients in this group had moderate acne (85%). However, 7.3% had mild acne on physical examination. The criteria for prescribing oral isotretinoin in this less severe group of patients included acne that improves <50% after 6 months of conventional oral antibiotic and topical combination therapy, acne that scars, acne that induces psychological distress and acne that significantly relapses during or quickly after conventional therapy. Treatment is usually initiated at daily doses of 0.5 mg/kg (but may be higher) and is increased to 1.0 mg/kg. Most of the physicians aimed to achieve a cumulative dose of >100-120 mg/kg. Mucocutaneous side-effects occur frequently but are manageable while severe systemic side-effects are rarely problematic (2%). The teratogenicity of oral isotretinoin demands responsible consideration by both female patients and their physicians. Significant cost savings when treating acne patients with oral isotretinoin as compared to other treatment modalities were further proven in this study. **Conclusions:** Our recommendation is that oral isotretinoin should be prescribed not only to patients with severe disease but also to patients with less severe acne, especially if there is scarring and significant psychological stress associated with their disease. Acne patients should, where appropriate, be prescribed isotretinoin sooner rather than later.

Introduction

Oral isotretinoin (Roaccutane®) revolutionized the treatment of acne when it was introduced in 1982. More than a decade later, it remains the most effective anti-acne

pharmacotherapy since it is the only treatment that affects all major aetiological factors implicated in acne. Sebum production [1-3], comedogenesis [2], surface and ductal colonization with *Propionibacterium acnes* [1, 2] and monocyte chemotaxis [2, 4] are all significantly reduced by

KARGER

E-Mail karger@karger.ch
 Fax +41 61 305 12 34
 http://www.karger.ch

© 1997 S. Karger AG, Basel
 1018-8665/97/1944-0351\$12.00/0

This article is also accessible online at:
 http://BibMedNet.com/karger

Prof. W.J. Cunliffe
 Department of Dermatology, General Infirmary at Leeds
 Great George Street
 Leeds LS1 3EX (UK)
 Tel: 313 290 3605, Fax 313 234 1154

Table 1. Roaccutane usage

Based on the last 100 patients you treated with Roaccutane:	
(1) How were these patients categorized?	
Severe acne	_____
Moderate acne	_____
With scarring	_____
With psychological complications	_____
With both	_____
With neither	_____
Mild acne	_____
With scarring	_____
With psychological complications	_____
With both	_____
With neither	_____
Other, e.g. pyoderma faciale, acne fulminans, gram-negative folliculitis, vasculitic acne	
(2) What were your dosage recommendations?	
Daily dose, mg/kg	_____
Therapy duration, weeks	_____
Total course dose, mg/kg	_____
Did you vary according to acne severity?	
(3) Do you recommend a total dose (cumulative) to minimize relapse?	yes/no
If yes, please continue	
(3a) What cumulative dose do you prescribe?	_____
(3b) In what proportion of patients (percent) do you administer a total cumulative dose?	_____

isotretinoin therapy. Oral isotretinoin is established as a uniquely successful therapy capable of long-term remission in up to 70–89% of patients [5–9].

When isotretinoin was first introduced in the early 1980s, its use was restricted predominantly to patients suffering with severe nodulocystic acne. With increasing clinical experience, however, its use has been expanded by many physicians to include patients with less severe disease who are responding unsatisfactorily to conventional therapies such as long-term antibiotics and appropriate topical therapies. Currently among some physicians, patients with nodular acne represent only a small proportion of their isotretinoin-treated patient population. Thus, if the prescribing of isotretinoin is limited by other physicians to patients with severe nodular acne, then many patients are not receiving appropriate therapy and many such patients will scar. Unfortunately, more and more patients are failing to respond to long-term antibiotics and appropriate topical therapies because of an increase in resistance of *P. acnes* to many antibiotics, in particular erythromycin and tetracycline [10–13]. Even patients with moderate acne can scar significantly, and currently there is not much successful treatment for the majority of patients who do scar [14–16].

In light of these observations, a review of current isotretinoin usage policies and treatment recommendations

was made among dermatologists with a particular interest in acne. The ultimate objective was to provide treatment guidelines based upon collective clinical experience.

Methods

Based upon evaluation of the last 100 patients treated with oral isotretinoin, each participant completed a questionnaire (cf. table 1) which requested detailed information regarding acne indications treated, dosage used as well as particular safety and tolerability concerns. Since the safety profile of isotretinoin is predictable consisting predominantly of manageable mucocutaneous effects such as cheilitis, dry skin and, less frequently, headaches and arthralgias, the questionnaires focused primarily on indications and dosage.

Since acne classification schemes vary among dermatologists, reaching consensus with respect to which types of acne warrant isotretinoin treatment was greatly enhanced by using representative patient pictures. These pictures covered the whole spectrum of acne physical severity. Many patients with mild or moderate acne, let alone severe acne, scar, and this feature was captured by the questionnaire. The psychological trauma of acne is well documented [17–20] and was also covered by the questionnaire. Acne morbidity is determined by other influencing factors such as the chronic and/or relapsing nature of the disease and the limited benefit of previous conventional therapy.

Isotretinoin has been shown to be cost effective [21–24]. Two centres re-investigated this issue by comparing the actual total costs of isotretinoin therapy with the cost if patients had received other than

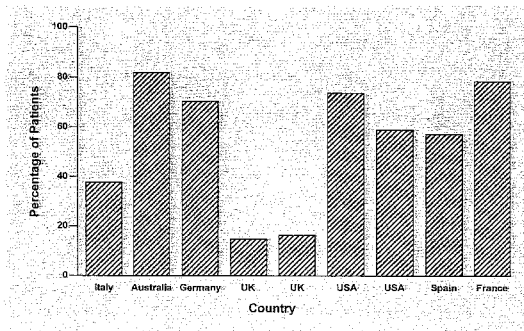


Fig. 1. Percentage of patients treated from 7 countries (10 centres: the Italian data from 2 centres were combined) with severe acne who were treated with oral isotretinoin.

oral isotretinoin therapy. The patients in the Australian cohort have been published elsewhere [22]. The UK data were based on 364 patients who were followed for 3 years from the start of the first course of isotretinoin. Two sets of cost data were calculated as described previously [21]. The data included all costs, i.e. drug, personnel time and overheads. The first set was based on the precise cost for the 364 patients. It included the initial cost of isotretinoin therapy plus any additional drug costs incurred for management of side-effects or acne therapy if the acne flared after the initial course of isotretinoin. The second set was calculated on a theoretical basis, assuming that isotretinoin was not available for these patients. These data assumed that the patient had requested therapy over this 3-year time period. Our approach in the pre-isotretinoin days would have been to prescribe rotational antibiotics, i.e. 6 months each of tetracycline, minocycline, trimethoprim and erythromycin (plus appropriate topical therapy). To both sets of data were added either the real or theoretical costs for all hospital overheads.

Results

Acne Indications

Severe Acne

As shown in figure 1, all physicians prescribed oral isotretinoin in all patients with severe acne, but such patients represented varying proportions of the isotretinoin-treated population. Two physicians did not have accurate records of acne severity. Thus, such data from these two centres were not available. In Australia, 82% of the patients who received oral isotretinoin had severe acne; in France it was 80% and in Germany 70%. In the two USA clinics, the percentage was 60 and 75%. In the UK, only 14–16% of the

patients receiving oral isotretinoin had severe acne; in Spain, the percentage was 58% and in the two Italian centres 38%.

Moderate Acne

All physicians used oral isotretinoin in patients with moderate acne that had failed to respond to long-term antibiotics or appropriate topical therapy (fig. 2). In the UK and Italy, such patients represented the greatest number of patients so treated (UK: 74–76% and Italy: 50%) whereas in Australia, France, Germany and Spain this subpopulation represented 16, 18, 20 and 32%, respectively. In the USA, 21–35% of isotretinoin-treated patients had moderate acne. In this subgroup of moderate acne, combined data from all countries revealed (fig. 3) that many had either scars (16.7%), psychological problems (18.7%) or both (64.2%). The percentage of patients with moderate acne who had scars and psychological problems was similar in most countries.

Mild Acne

All physicians used isotretinoin in patients with mild acne which was non-responsive to long-term antibiotics or appropriate topical therapies. All such patients, however, in this group had either scarring (15.5%) or psychological problems (19%) or both (65.5%). In most countries, this group of 'mild' acne represented less than 5% of oral isotretinoin usage except one centre, where 12% of all acne patients seen had physically mild acne with either scarring or psychological distress or both.

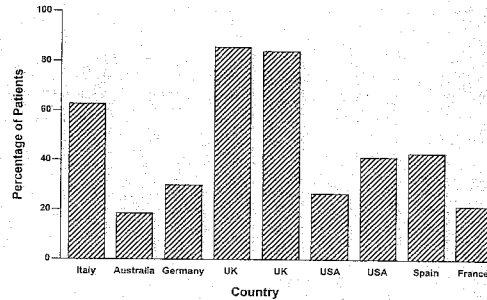


Fig. 2. Percentage of patients from 7 countries with moderate and mild acne who were treated with oral isotretinoin.

Acne variants such as acne fulminans, gram-negative folliculitis, rosacea fulminans and acne conglobata were rare causes for prescribing oral isotretinoin; this reflects the very uncommon nature of these diseases. Only 5 such patients were reported, all of whom required oral isotretinoin.

Dosing Regimen, Side-Effects and Blood Tests

All physicians used a daily dose of 0.5–1.0 mg/kg and adjusted therapy duration to 16–30 weeks, depending upon the daily dose. They also adjusted the daily dose according to tolerability and all used a cumulative dose per course of 100 mg/kg or more. In 7 of the 10 centres, most patients reached a cumulative dose of 120 mg/kg.

Mucocutaneous side-effects were experienced by virtually all patients – as was to be expected. In only 4% (2–15%) were these troublesome and unresponsive to simple moisturizers. In such patients, topical steroids were frequently prescribed as were antibiotics to manage secondary infection. The most common systemic side-effects requiring specific therapy were arthralgias and headaches. Paracetamol or non-steroidal anti-inflammatory drugs were all that were required. In no patient were the side-effects a major problem.

Liver function tests and fasting lipids were performed at baseline by all authors, but the frequency of repeat blood tests varied from centre to centre. Laboratory tests were regularly performed by all but two authors. The time and frequency of blood tests varied. However, in none of the

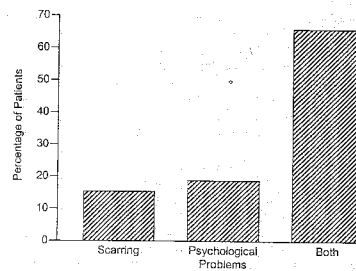


Fig. 3. Percentage of isotretinoin-treated patients with moderate acne who had significant scarring and psychological problems or both.

1,000 patients did any of the minor and expected laboratory changes (mild elevation of fasting lipids and liver enzymes) result in a change of dosage or cessation of therapy.

Cost Savings

The cost of treating patients with oral isotretinoin and any subsequent therapy with the theoretical cost of long-term antibiotics had isotretinoin not been available demonstrated a significant cost saving. This was documented very

Table 2. Mean cost of isotretinoin and any subsequent therapy compared with the theoretical cost if the patient had not been prescribed such therapy for 3 years

Severity of acne	Percentage of patients	Mean cost if treated with isotretinoin, GBP	Mean cost without isotretinoin treatment, GBP	p value
Mild	20	678 ± 45	1,675 ± 291	<0.0001
Moderate	57	732 ± 74	1,520 ± 104.5	<0.0001
Severe	23	803 ± 117	1,856 ± 204.5	<0.0001

GBP = Calculated in British pounds. Means ± 95% confidence limits.

impressively when treatment costs for acne patients in a country such as the UK were evaluated: comparing the precise treatment costs of 364 patients who were prescribed oral isotretinoin with the theoretical costs of antibiotic treatment revealed cost savings of approximately 60% over conventional 4-month rotational therapy with antibiotics plus topical agents (table 2). The savings were similar whether the patient had mild, moderate or severe acne. Since most of the patients with mild acne had psychological problems, an amount for additional counselling and reassurance was added to the theoretical cost. This explains why the theoretical costs of treating mild acne patients are greater than if the patient had moderate acne.

Discussion

These data document for the first time worldwide experience on the overall use of isotretinoin. Isotretinoin should not be limited to patients with severe acne. Acne morbidity is determined by more than the apparent physical appearance. Influencing factors include the extent of the disease (trunk and extremities may be involved in addition to the face), the chronic and/or relapsing nature of the disease, the limited benefit of previous conventional therapy, the likelihood of permanent scarring and the degree of acne-induced psychological trauma.

Patients with severe acne should receive oral isotretinoin as first-line therapy. Patients responding poorly to conventional acne therapy after 6 months are too often prescribed more oral antibiotics before isotretinoin is considered. Many patients fail to respond to antibiotics since propionibacterial strains resistant to one or more antibiotics are increasingly detected [11–13]. Another reason for poor response to long-term antibiotics, in the absence of *P. acnes* resistance, is dilution of what could be otherwise effective therapy by high sebum excretion rates – a characteristic feature of acne [2]. Isotretinoin effectively cures acne, even

in the presence of *P. acnes* resistance, and it markedly suppresses the sebum excretion rate by 90% within 1 month of initiating therapy [6, 25]. Thus, it is not surprising that oral isotretinoin is very effective in patients with moderate acne whatever their reasons for failure. All authors treated some such non-responding patients with isotretinoin. In one clinic, up to 74% of patients treated with oral isotretinoin had moderate and non-responsive acne, whereas at the other extreme it was only 16% so treated. In all clinics, a smaller percentage of patients with mild acne received oral isotretinoin. A high percentage of patients with moderate active acne as so defined had significant scarring and psychological problems. This was even more evident in those patients with mild acne who received oral isotretinoin.

Scarring from acne creates enduring physical and emotional ramifications; it should be a compelling rationale for isotretinoin treatment, since no other treatment is guaranteed to resolve inflammatory acne. Even when conventional antibiotic therapy is effective, its slower onset of action may be too late to preclude permanent scarring [15, 16].

The significant psychosocial impact of acne should not be underestimated and includes depression, anxiety, interpersonal and work-related difficulties, and attempted suicide [17–20]. Therefore, patients with acne-induced psychological distress such as severe depression or dysmorphophobia should be treated with isotretinoin [15] even when such patients display apparently 'mild' acne.

This unnecessary delay of therapeutic response is naturally frustrating for any acne patient seeking medical attention but may be permanently detrimental for those who scar or who suffer acne-induced emotional distress [25, 26]. Although life quality is impaired in patients with acne as with many other diseases, few treatments are as effective at recovering predisease quality of life as is isotretinoin. A recent Oxford study, incorporating four different validated quality-of-life instruments, confirmed that isotretinoin treatment significantly improves social function, mental health and self-esteem among other indicators [27].

Additional indications where isotretinoin is used effectively represent but a small percentage of patients (<1%) and include severe acne variants such as gram-negative folliculitis, inflammatory rosacea (e.g. rhinophyma), acne fulminans, rosacea fulminans and hidradenitis suppurativa.

In this study, the variations in the indication for use of oral isotretinoin are, in part, explained by the variation in ways medicine is practised in different countries. In the UK, all patients with troublesome acne who may require oral isotretinoin are treated by a hospital dermatologist, simply because the drug is only available from hospitals. Thus, the physician is more likely to see a broader group of patients not responding to conventional therapy. In Europe, patients with less severe acne who ought to be prescribed oral isotretinoin are likely to visit a private practising dermatologist rather than a hospital dermatologist, whereas the European hospital/university specialist is more likely to see the more severe cases of acne.

Although there were variations in the doses prescribed, virtually all patients received 0.5–1.0 mg/kg/day. In 4 out of 9 clinics, the dose regimen usually started at 0.5 mg/kg daily and increased to 1.0 mg/kg/day, but in 2 centres most patients were started on therapy at 1.0 mg/kg/day. Published data indicate that optimal benefit is achieved with the higher dose [5, 6, 8, 18, 28, 29]. The term cumulative dose per course refers to the total amount of oral isotretinoin taken by the patient over the duration of therapy; in this study the duration of therapy varied from 16 to 30 weeks. Data on cumulative dose indicate that post-therapy relapse is minimized by a treatment course amounting to a total of at least 120 mg/kg [6–8, 25, 29] with no further therapeutic gain beyond about 150 mg/kg.

Most physicians in this study achieved such a cumulative treatment dose. Table 3 summarizes the relationship between daily dose, duration of therapy and cumulative dose.

Mucocutaneous side-effects such as dry lips, dry nasal passages and dry eyes are predictable and dose-dependent consequences of oral isotretinoin. They were evident in most patients in this series. Pretreatment counselling and the regular use of moisturizing agents and lip salves usually manage these adverse effects quite effectively. In this series, 4% of patients had troublesome mucocutaneous side-effects.

Severe systemic side-effects are rarely a problem. In this series, only 2% of patients suffered troublesome effects, in particular headaches, myalgia and arthralgia; all symptoms responded to oral paracetamol or non-steroidal anti-inflammatory drugs.

While oral isotretinoin is effective in treating acne, its teratogenic risk demands responsible consideration by both

Table 3. Relationship between the daily dose, the duration of therapy and the cumulative dose

Daily dose mg/kg	Cumulative dose, mg/kg			
	4 months (120 days)	5 months (150 days)	6 months (180 days)	7 months (210 days)
0.5	60	75	90	105
0.6	72	90	108	126
0.7	84	105	126	147
0.8	96	120	144	168
0.9	108	135	162	189
1.0	120	150	180	210

female patient and physician [30–32]. Women of child-bearing potential must have a negative pregnancy test as well as practise effective contraception during and for 1 month after completing therapy [31–33]. Formalized educational campaigns by the manufacturer, including pregnancy prevention programmes, have been very successful [32, 33]. Furthermore, the required 1-month post-therapy contraceptive period affords a respectable safety margin since it has now been demonstrated that plasma concentrations of isotretinoin return to physiological levels within 10 days of therapy completion [34].

Significant cost savings over traditional acne therapies are well documented for isotretinoin [9, 35–37]. Rotational antibiotic therapy is not only less effective than isotretinoin, slower in onset of action and a potential public health hazard in terms of bacterial resistance, but substantially increases costs to patients or insurers. Even using an unrealistically short treatment period of 2 years for conventional therapy, French costs were estimated to be 15% lower with isotretinoin [36]. In Australia [22], conventional acne therapy costs for drugs, laboratory tests and physician consultations are 25% higher than for isotretinoin therapy. Considering costs in New Zealand of medicines, laboratory tests and consultation fees, even the highest dose of isotretinoin (1 mg/kg/day) is 50% less expensive than conventional therapy [37]. Our data confirmed the cost effectiveness of isotretinoin in patients with mild, moderate or severe acne.

Professional and governmental health attitudes are focusing more and more on prevention and cost benefit. We therefore conclude that not only do acne patients gain immeasurable physical and psychological relief with almost 100% improvement within 4–6 months of therapy, but society gains by limiting bacterial resistance evolution and reducing health care costs. Thus acne patients should, where appropriate, be prescribed oral isotretinoin sooner rather than later.

References

- King K, Jones DH, Daltry DC, Cunliffe WJ: A double-blind study of the effects of 13-cis-retinoic acid on acne, sebum excretion rate and microbial population. *Br J Dermatol* 1982;107:583-590.
- Leyden JJ: New understandings of the pathogenesis of acne. *J Am Acad Dermatol* 1995;32: S15-S25.
- Hughes BR, Cunliffe WJ: A prospective study of the effect of isotretinoin on the follicular reservoir and sustainable sebum excretion rate in patients with acne. *Arch Dermatol* 1994;130:315-318.
- Pigatto PD, Fioroni A, Riva F, Brugo MA, Morandotti A, Altomare GF, Finzi G: Effects of isotretinoin on the neutrophil chemotaxis in cystic acne. *Dermatologica* 1983;167:16-18.
- Ho V, Schachter D, Miller R, Cloutier R, Marcoux D, Gulliver W, Luzon GJ, Murray E: Acne management for the 90s: Current treatment guidelines. *Can J Diagn* 1995;suppl: 5-25.
- Layton AM, Knaggs H, Taylor J, Cunliffe WJ: Isotretinoin for acne vulgaris - 10 years later: A safe and successful treatment. *Br J Dermatol* 1993;129:252-256.
- Lehacher-Ceyrac D, Weber-Buisset MJ: Isotretinoin and acne: A prospective analysis of 188 cases over 9 years. *Dermatology* 1993;186:123-128.
- Cunliffe WJ, Layton AM: Oral isotretinoin: Patient selection and management. *J Dermatol Treat* 1993;4:S10-S15.
- Shahidullah M, Tham SN, Goh CL: Isotretinoin therapy in acne vulgaris: A 10-year retrospective study in Singapore. *Int J Dermatol* 1994;33:60-63.
- Eady EA, Holland KT, Cunliffe WJ: Should topical antibiotics be used for the treatment of acne vulgaris? *Br J Dermatol* 1982;107: 235-246.
- Nishijima S, Akamatsu H, Akamatsu M, Kurokawa I, Asada Y: The antibiotic susceptibility of *Propionibacterium acnes* and *Staphylococcus epidermidis* isolated from acne patients. *J Dermatol (Japan)* 1994;21:166-171.
- Oakley A, Rtdemaker M, Duffill M, Lerg R, Shewan J: Propionibacterium: Resistance of acne to antibiotics. *NZ Med J* 1995;108:43-44.
- Eady EA, Jones CE, Tipper JL, Cove JH, Cunliffe WJ, Layton AM: Antibiotic resistant propionibacteria in acne: Need for policies to modify antibiotic usage. *Br Med J* 1993;306: 555-556.
- Simpson N: Effect of isotretinoin on the quality of life of patients with acne. *Pharmacoeconomics* 1994;6:108-113.
- Goulden V, Layton AM, Cunliffe WJ: Current indications for isotretinoin as a treatment for acne vulgaris. *Dermatology* 1995;190: 284-287.
- Gupta MA, Gupta AK, Schork NJ, Ellis CN, Voorhees JJ: Psychiatric aspects of the treatment of mild to moderate facial acne. *Int J Dermatol* 1990;29:719-721.
- Krowchuk DP, Stancia T, Keskinen R, Walker R, Bass J, Anglim TM: The psychosocial effects of acne on adolescents. *Pediatr Dermatol* 1991;8:332-338.
- Healy E, Simpson N: Acne vulgaris. *Br Med J* 1994;308:831-833.
- Koo JYM: Psychological impact of acne: Patients' perceptions. *J Am Acad Dermatol* 1995; 32:S26-S30.
- MacDonald-Hull S, Cunliffe WJ, Hughes BR: Treatment of the depressed and dysmorphic acne patient. *Clin Exp Dermatol* 1991;16:210-211.
- Cunliffe WJ, Gray JA, MacDonald-Hull S, Hughes BR, Calvert RT, Burnside CJ: Cost effectiveness of isotretinoin. *J Dermatol Treat* 1991;1: 285-288.
- Lee ML, Cooper A: Isotretinoin: Cost-benefit study. *Australas J Dermatol* 1991;32:17-20.
- Simpson NB: Social and economic aspects of acne and the cost-effectiveness of isotretinoin. *J Dermatol Treat* 1993;4:S6-S9.
- Warren KJ, Cruz PD: Clinical outcome and cost analysis of oral isotretinoin versus conventional regimens in the treatment of moderate acne vulgaris in male patients. *Am Acad Dermatol* Washington 1996, (abstract P-12).
- Layton AM, Cunliffe WJ: Guidelines for optimal use of isotretinoin in acne. *J Am Acad Dermatol* 1992;27:S2-S7.
- Cunliffe WJ: New Approaches to Acne Treatment. Oxford, Dunitz, 1994, pp 56-62.
- Mallon E, Newton JN, Klassen A, Ryan TJ, Finlay A: Standard patient-assessed quality of life instruments can be used to measure the benefits of acne treatment. *Br J Dermatol* 1995; 133:suppl 45:35.
- Harms M, Duvenel T, Williamson C, Masouyé I, Saurat JH: Isotretinoin for acne: Should we consider the total cumulative dose? in Marks R, Plewig G (eds): Acne and Related Disorders. London, Dunitz, 1989, pp 203-206.
- Layton AM, Stamford JM, Cunliffe WJ: Ten years' experience of oral isotretinoin for the treatment of acne vulgaris. *J Dermatol Treat* 1993;4:S2-S5.
- Stern RS: When a uniquely effective drug is teratogenic: The case of isotretinoin. *N Engl J Med* 1989;320:1007-1009.
- Roaccutane Product Information: 1997.
- Mitchell AA, Van Bennekom CM, Louik C: A pregnancy prevention program in women of childbearing age receiving isotretinoin. *N Engl J Med* 1995;333:101-106.
- Pastuszak A, Koren G, Rieder MJ: Use of the retinoid pregnancy prevention program in Canada: Patterns of contraception use in women treated with isotretinoin and etretinate. *Reprod Toxicol* 1994;8:63-68.
- Wiegand UW, Cunliffe WJ, Wyss R, Crevoisier C: Treatment of female patients with isotretinoin: What is the safe post-therapy contraceptive period? *Clinical Dermatology* 2000, Vancouver, 1996.
- Simpson N: Effect of isotretinoin on the quality of life of patients with acne. *Pharmacoeconomics* 1994;6:108-113.
- Lafarge H, Levy PE: Evaluation économique d'une innovation médicamenteuse: le traitement de l'acné sévère par Roaccutane. *J Econ Méd* 1987;5:117-127.
- Wishart J, Villiger J: Cost-benefit of isotretinoin (Roaccutane). *N Z Med J* 1991;104:192.

Hypervitaminosis A in Two Hemodialysis Patients

Steven Fishbane, MD, Gill L. Frei, MD, Mark Finger, MD, Robert Dressler, MD,
and Sharon Silbiger, MD

● We present two cases of hemodialysis patients developing vitamin A toxicity related to excessive consumption of nutritional supplements containing large quantities of vitamin A. In one patient, severe hypercalcemia was the lone presenting sign; in the other, hypercalcemia was associated with unusual neurologic manifestations. We will discuss the reason why hemodialysis patients are at special risk for the development of hypervitaminosis A and review the mechanism leading to the associated hypercalcemia.
© 1995 by the National Kidney Foundation, Inc.

INDEX WORDS: Hemodialysis; hypervitaminosis A; hypercalcemia.

HYPERVITAMINOSIS A is a well-described medical condition with a multitude of potential presenting symptoms and signs. Hemodialysis patients who consume nutritional supplements containing pharmacologic doses of vitamin A may be at special risk for the development of toxicity. We present here two cases of hypervitaminosis A in hemodialysis patients, and review the clinical presentation and pathophysiology of this syndrome.

CASE REPORTS

Case No. 1

A 53-year-old Hispanic man with a long history of hypertension and end-stage renal failure maintained on chronic hemodialysis was admitted to the hospital because of a change in mental status. His past medical history included an anterior wall myocardial infarction in 1983, three-vessel coronary artery bypass surgery in 1990, and gout. There were no recent complaints of chest pain or gouty exacerbations.

The patient had been feeling well for the several months prior to this presentation, except for vague abdominal and back pain. Work-up included a lumbosacral spine radiograph that had unremarkable findings. The patient had no specific complaints of bone pain or muscle aches.

For several months prior to this presentation, serum calcium levels were intermittently elevated (Table 1). This was treated by withholding vitamin D supplements and calcium carbonate tablets. Calcium supplements were reinstated when the calcium level returned to normal, and the patient received one dose of intravenous calcitriol 4 days prior to admission.

From the Division of Nephrology, Winthrop-University Hospital, Mineola, NY; and the Division of Nephrology, Montefiore Medical Center and the Albert Einstein College of Medicine, Bronx, NY.

Received July 19, 1994; accepted in revised form September 19, 1994.

Address reprint requests to Steven Fishbane, MD, Division of Nephrology, Winthrop-University Hospital, 222 Station Plaza N, Suite 510, Mineola, NY 11501.

*© 1995 by the National Kidney Foundation, Inc.
0272-6386/95/2502-0020\$3.00/0*

Outpatient medications included extended-release nifedipine 30 mg once daily, enteric-coated aspirin once daily, allopurinol 100 mg once daily, colchicine 0.6 mg twice daily, one multivitamin tablet daily, folic acid 1 mg once daily, calcium carbonate 650 mg (240 mg elemental calcium) thrice daily, and ferrous sulfate 325 mg thrice daily. The patient had been taking aluminum-containing antacids until they were discontinued by his physician in August 1990.

On the morning of admission, the patient's wife noted him to be drowsy and unable to grasp objects or support his own weight. In addition, he complained of diplopia and occipital headaches.

In the emergency department, the patient was arousable but otherwise very somnolent. Physical examination revealed a blood pressure of 170/100 mm Hg, a heart rate of 100 beats/min, and a respiratory rate of 16 breaths/min. The patient was afebrile. The neurologic examination was nonfocal with an intact cerebellar examination, a normal based gait, and normal deep tendon reflexes. The remainder of the physical evaluation was unremarkable except the finding of for guaiac-positive stools. Laboratory evaluation was significant for a serum calcium of 17.6 mg/dL. An electrocardiogram showed a normal sinus rhythm, with no changes when compared with previous outpatient tracings.

The patient was treated with 3 hours of hemodialysis using a 2.5 mEq/L calcium bath. Afterward, serum calcium decreased to 14.0 mg/dL. With repeated hemodialysis treatments, the serum calcium returned to normal, as did the patient's mental status.

The patient subsequently acknowledged ingesting cod liver oil tablets, up to nine per day, for at least 1 to 2 months. Two days after admission, when the information regarding the cod liver oil ingestion was obtained and the serum calcium had returned to normal, the level of vitamin A was 220 µg/dL (normal, 30 to 95 µg/dL). Other laboratory values at that time included a 1,25-dihydroxyvitamin D₃ level of 20 pg/mL (normal, 12 to 40 pg/mL), a 25-hydroxyvitamin D₃ level of 83 ng/mL (normal, 16 to 74 pg/mL), an intact parathyroid hormone (PTH) level of 24 pg/mL (normal, 10 to 65 pg/mL), and a random aluminum level of 10 µg/L. Thyroid function tests were normal.

The patient was discharged with a serum calcium level of 8.9 mg/dL and was instructed not to take any further cod liver oil or multivitamin tablets. No further episodes of hypercalcemia have occurred.

Case No. 2

A 40-year-old Hispanic hemodialysis patient presented with a gradual change in personality. One week prior to

Table 1. Relevant Laboratory Values for Patient No. 1

Date	Calcium (mg/dL)	Phosphate (mg/dL)	PTH (pg/mL)	Alkaline Phosphatase (IU/L)	Serum Aluminum (μ g/L)
January 10	9.4	3.9	105	64	12
April 4	8.4	7.2	374	71	8
June 25	13.0	5.1	—	66	—
July 12	11.0	5.1	14	62	18
September 5	8.0	5.2	—	56	—

Abbreviation: PTH, parathyroid hormone.

admission he began to believe that insects were crawling over his body. This was associated with severe pruritus, which the patient treated with various lotions. On the day prior to admission he tried to cut off his son's hair with a razor, believing that insects had infested his son's body. He was brought to the hospital by his wife.

The patient's end-stage renal disease was due to hypertension. There were no other significant current medical problems. There was no prior history of psychiatric or neurologic disease. The patient had not experienced pruritus in his previous years on dialysis. Recent urea kinetic modelling indicated that adequate dialysis was being achieved, with a Kt/V of 1.21.

For several months there had been recurrent episodes of hypercalcemia whenever the patient was placed on low-dose calcium carbonate therapy. In each case the hypercalcemia resolved when the calcium supplement was discontinued. In the weeks immediately prior to admission, the patient had experienced several episodes of blurred vision, for which he did not seek medical care. There were no other presenting symptoms.

Medications included minoxidil 2.5 mg once daily, extended-release nifedipine 30 mg once daily, rocaitrol 0.25 μ g once daily (which had been discontinued several days earlier), and a multivitamin pill.

There was no history of alcohol or drug abuse. The patient was married, had one child, and was monogamous.

On physical examination at presentation, the patient was found to be very agitated. Blood pressure was 155/85 mm Hg, pulse rate was 88 beats/min, and temperature was 98.7°F. The skin was covered diffusely with excoriations on all body surfaces except those areas the patient could not reach. No other skin lesions were noted, and no insects were found. The conjunctiva were injected bilaterally. On neurologic examination, the patient was alert and oriented to person, place, and time; both short- and long-term memory were intact. He insisted that insects were crawling over his body. Motor and sensory examinations were nonfocal. Deep tendon reflexes were symmetric. Cranial nerves were intact. Cerebellar examination revealed poor finger-to-nose coordination, and an ataxic gait. The findings of the remainder of the physical examination were normal.

The complete blood cell count was normal. Chemistry levels were sodium 143 mEq/L, potassium 4.7 mEq/L, chloride 104 mEq/L, bicarbonate 22 mEq/L, blood urea nitrogen 73 mg/dL, creatinine 8.2 mg/dL, calcium 10.9 mg/dL, phosphorus 6.2 mg/dL, and magnesium 4.7 mg/dL. Liver function test findings were within normal limits. Serum PTH was 63

pg/mL, 25-hydroxyvitamin D₃ was 67 ng/mL, and 1,25-dihydroxyvitamin D₃ was 17 pg/mL.

A brain computed tomography scan and magnetic resonance imaging were normal. A sample of spinal fluid had normal chemistry results and cell count.

The patient acknowledged that he had been taking several nutritional supplements. These were found to be an assortment of different minerals, vitamins, and fish oils. The total vitamin A dose per day was greater than 50,000 units.

The serum vitamin A level was found to be 380 μ g/dL. After discontinuing the supplements the patient gradually improved, without further episodes. One month after discharge, the level of vitamin A was 95 μ g/dL and serum calcium was normal while the patient was taking 650 mg of calcium carbonate thrice daily.

RESULTS

The manifestations of vitamin A toxicity in the two patients were quite different. In the first patient severe hypercalcemia was the dominant feature; in the second, the clinical presentation included bizarre neuropsychiatric symptoms and signs, severe pruritus, and episodic hypercalcemia.

In patient no. 1, the hypercalcemia was temporally related to the administration of small amounts of calcium carbonate. The extreme magnitude of the hypercalcemia, however, suggested that a factor in addition to calcium intake was the major contributor. A significant finding in the evaluation of this patient was the markedly elevated serum vitamin A level. This was the likely etiology, as the episodes of hypercalcemia ended when vitamin A was discontinued.

Patient no. 2 was a healthy young man who developed delusions and ataxia. His diagnosis remained something of a mystery until it was learned that he was taking (as in the case of patient no. 1) large quantities of vitamin supplements. The serum vitamin A level was markedly elevated, and his symptoms resolved when the vitamin A-containing compounds were discontinued.

DISCUSSION

The manifestations of vitamin A toxicity in adults are variable, and whether chronic renal failure impacts on these manifestations is unclear. Neurologic symptoms may include ataxia, visual disturbances, irritability, psychosis, and, in severe cases, pseudotumor cerebri with headaches. Skin findings include alopecia, brittle nails, and pruritus. The association of hypervitaminosis A and hypercalcemia is discussed below, and may be accompanied by bone pain and hyperostoses. Other findings include anemia, conjunctivitis, dysuria, edema, hepatotoxicity, nausea, polydipsia, and splenomegaly.¹

Of the above-listed manifestations, patient no. 1 had hypercalcemia, diplopia, and headaches. Patient no. 2 displayed several findings that appear to have been clearly due to vitamin A toxicity, including ataxia, visual disturbances, and psychosis. Some of his other symptoms were less specific, but also may have been due to vitamin A, including pruritus, conjunctivitis, hypercalcemia, and irritability.

The association between elevated vitamin A levels and chronic renal failure has been recognized since the 1940s.² Werb et al found average vitamin A levels in hemodialyzed patients to be significantly higher than those in age-matched controls ($102.29 \pm 26.95 \mu\text{g/dL}$ v $40.98 \pm 6.71 \mu\text{g/dL}$).³ Other investigators have found similar relationships.^{4,5}

Vitamin A is absorbed in the intestine in association with chylomicrons⁶ and is stored primarily in the liver. In individuals with high vitamin A intake, liver biopsies show hyperplasia of the vitamin A storage cells.⁴ The vitamin is mobilized from the liver in its free alcohol form, retinol, and circulates in plasma bound to a specific transport protein, retinol binding protein (RBP). This protein has a molecular weight of 21,000 d and normally circulates as a complex with prealbumin (molecular weight, 55,000 d).⁷

In renal failure, RBP plasma levels are increased.^{5,8} The reason for high circulating RBP levels is thought to be primarily related to decreased glomerular filtration of free RBP. Less filtration results in decreased tubular catabolism. Since serum levels of RBP increase in renal failure, vitamin A that is mobilized from the liver is increasingly bound, leading to increased serum

vitamin A levels. In cases of vitamin A toxicity, levels in plasma exceed the binding capacity of RBP, and the vitamin circulates in plasma in loose association with lipoproteins, increasing the exposure (and, therefore, toxicity) to cellular membranes.

Farrington et al examined the effect of consuming multivitamin preparations on serum vitamin A levels in hemodialysis patients.⁵ These investigators found mean vitamin A levels in patients taking a multivitamin (containing 2,500 IU of vitamin A) of $150.0 \pm 54.0 \mu\text{g/dL}$ compared with $112.6 \pm 36.0 \mu\text{g/dL}$ in those not taking multivitamin preparations ($P < 0.05$). Praga et al⁴ found increased serum vitamin A levels in hemodialysis patients taking 25,000 U/d of vitamin A, but not in patients taking 10,000 U/d.

The multivitamin patient no. 1 was taking contained 5,000 U of vitamin A. Each cod liver oil capsule contained 7,500 U. He claimed to be taking up to nine capsules of cod liver oil a day, so his total daily vitamin A consumption may have been as great as 72,500 U. Patient no. 2 was taking six different vitamin supplements that provided him with more than 50,000 U/d of vitamin A. The current daily allowance recommended by the Food and Drug Administration for adults is 5,000 IU/d. Toxicity in nonuremic adults has been recognized with consumption of more than 25,000 U/d.¹

In chronic renal failure, most studies have shown an association between serum vitamin A levels and serum calcium.³⁻⁵ Farrington et al found mean serum vitamin A levels of $160.5 \pm 59.0 \mu\text{g/dL}$ in hypercalcemic patients, compared with $114.4 \pm 36.0 \mu\text{g/dL}$ in normocalcemic patients ($P < 0.005$).⁵ Praga et al documented mean serum calcium levels of 9.36 mg/dL in patients with normal vitamin A levels, compared with 9.76 mg/dL in those with elevated vitamin A levels ($P < 0.05$).⁴

The mechanism of vitamin A-induced hypercalcemia is not entirely clear, but is most likely related to increased release of calcium from bone. In bone tissue culture, vitamin A has been shown to induce osteolysis and to increase the osteolytic effect of PTH.⁹ In rats, vitamin A toxicity has been shown to increase bone resorption.¹⁰ In humans, hypervitaminosis A causes extensive skeletal changes, with radiographic evidence of hyperostosis,¹¹ increased bone resorption, and

decreased bone formation.¹² It is of interest that in our patient no. 1 a lumbosacral spine radiograph did not demonstrate evidence of significant bone disease.

The effect of vitamin A on PTH secretion is unclear. An early study found that vitamin A stimulated PTH secretion in both human and bovine parathyroid tissue.¹³ In contrast, a recent study found that retinoic acid suppressed PTH secretion in bovine tissue.¹⁴ In vivo, no change in PTH levels is noted after withdrawal of supplemental vitamin A from patients with renal failure.¹⁵ In our patients, PTH levels were not elevated.

We have presented two cases of hypervitaminosis A in hemodialysis patients. Both patients were originally from Central America, and consumed unprescribed fish oil tablets (a common nutritional supplement in this community). In view of the risk of hypervitaminosis A in end-stage renal disease patients, supplements and multivitamin preparations containing vitamin A must be used with caution in this population. In addition, hypervitaminosis A should be considered in the differential diagnosis of hemodialysis patients with hypercalcemia or with unexplained neurologic abnormalities.

REFERENCES

- Hathcock JN, Hattan DG, Jenkins MY, McDonald JT, Ramnathan Sundaresan P, Wilkening VL: Evaluation of vitamin A toxicity. *Am J Clin Nutr* 52:183-202, 1990
- Popper H, Steigmann F, Dyniewicz HA: Plasma vitamin A levels in renal diseases. *Am J Clin Pathol* 15:272-275, 1945
- Werb R, Clark WF, Lindsay RM, Jones EOP, Linton AL: Serum vitamin A levels and associated abnormalities in patients on regular dialysis treatment. *Clin Nephrol* 12:63-68, 1979
- Praga M, Rubio PD, Morales JM, Canizares F: Implications of hypervitaminosis A on the calcium-phosphate metabolism and on blood lipids in hemodialysis. *Am J Nephrol* 7:281-286, 1987
- Farrington K, Miller P, Varghese Z, Baillood RA, Moorhead JF: Vitamin A toxicity and hypercalcemia in chronic renal failure. *BMJ* 282:1999-2002, 1982
- Goodman DeWS, Blomstrand R, Werner B: The intestinal absorption and metabolism of vitamin A and beta-carotene in man. *J Clin Invest* 45:1615-1623, 1966
- Kleiner-Bossaler A, DeLuca HF: Formation of retinoic acid from retinol in the kidney. *Arch Biochem Biophys* 142:371-377, 1971
- Arnaud CD: The parathyroid glands, hypercalcemia, and hypocalcemia, in Wyngaarden JB, Smith LH (eds): *Cecil Textbook of Medicine*. Philadelphia, PA, Saunders, 1988, pp 1486-1507
- Raisz LG: Bone resorption in tissue culture. Factors influencing the response to parathyroid hormone. *J Clin Invest* 44:103-116, 1965
- Barnicot NA, Datta SP: Vitamin A and bone, in Bourne GH (ed): *The Biochemistry and Physiology of Bone*. London, UK, Academic, 1972, pp 197-229
- Caffey J: Chronic poisoning due to excess of vitamin A. *AJR Am J Roentgenol* 65:12-26, 1951
- Jowsey J, Riggs BL: Bone changes in a patient with hypervitaminosis A. *J Clin Endocrinol* 28:1833-1835, 1968
- Chertow BS, Williams JA, Norris RM, Baker GR, Hargis GK: Vitamin A stimulation of parathyroid hormone: Interactions with calcium hydrocortisone, and vitamin E in bovine parathyroid tissues and effect of vitamin A in man. *Eur J Clin Invest* 7:307-314, 1977
- MacDonald PN, Ritter C, Brown AJ, Slatopolsky E: Retinoic acid suppresses parathyroid hormone (PTH) secretion and PreproPTH mRNA levels in bovine parathyroid cell culture. *J Clin Invest* 93:725-730, 1994
- Rylance PB, Brown IRF, Howells DW, Nisbet JA, Stone AN, Eastwood JB: Relationship between vitamin A and bone disease in chronic renal failure. *Nephron* 36:131-135, 1984

Safety of vitamin A^{1,2}

Adrienne Bendich and Lillian Langseth

ABSTRACT Vitamin A adequacy is discussed in terms of the recommended allowances appropriate for the needs of the majority of individuals. Deficiency can result in xerophthalmia and permanent blindness and in increased mortality rates among children. Toxicity has been associated with the overconsumption of vitamin A supplements. Acute hypervitaminosis A may occur after ingestion of $\geq 500\,000$ IU (over 100 times the RDA) by adults or proportionately less by children. Symptoms are usually reversible on cessation of overdosing. Factors influencing chronic hypervitaminosis A include dosing regimen, physical form of the vitamin, general health status, dietary factors such as ethanol and protein intake, and interactions with vitamins C, D, E, and K. Both excess and deficiency of vitamin A in pregnant animals was shown to be teratogenic. In humans, congenital malformations associated with maternal overuse of high doses of vitamin A were reported but no cause-and-effect relationship has been established. Deficiency of the vitamin during pregnancy has also been associated with congenital abnormalities. Reported incidences of vitamin A toxicity are rare and have averaged fewer than 10 cases per year from 1976 to 1987. *Am J Clin Nutr* 1989;49:358-71.

KEY WORDS Vitamin A, vitamin deficiency, hypervitaminosis A, toxicity, birth defects

Introduction

Vitamin A is an essential nutrient for humans because it cannot be synthesized de novo within the body. It is provided by the diet in two forms: preformed vitamin A, found naturally only in animal products; and carotenoid vitamin A precursors (provitamin A), found primarily in foods of plant origin.

The term *vitamin A* is used generically for all β -ionone derivatives (other than carotenoids) that have the biological activity of all-*trans* retinol. Forms of vitamin A include retinol, retinal (also called retinaldehyde), and various retinyl esters (1). Retinoic acid can perform some but not all of the biological functions of vitamin A. The focus of this report will be the safety of oral intake of naturally occurring compounds with vitamin A activity. In this regard, many of the levels of vitamin A cited in this paper have been given in IU rather than retinol equivalents. In many instances the authors of the original papers did not indicate the vitamin A ester consumed by their subjects. Thus, it would not be accurate to calculate retinol equivalents or milligrams of retinol based solely upon information given in IU.

Vitamin A function and metabolism

Vitamin A is necessary for vision, reproduction, the integrity of membrane structures, the normal functioning of body cells, growth, and development.

Storage

Vitamin A, a fat-soluble vitamin, is stored in the body to a much greater extent than the water-soluble vitamins. The storage capacity of the human body for this vitamin is generally large enough to satisfy the normal requirement for 1-2 y (2). The vitamin is stored primarily in the liver: > 90% of total body stores are found in this organ (3).

Transport

Vitamin A is normally transported in plasma bound to a specific transport protein called retinol-binding protein (RBP). The vitamin is mobilized from the liver and delivered to the tissues in the form of the retinol-RBP complex. The mobilization and delivery of retinol are controlled in part by processes that regulate the rates of synthesis and secretion of RBP by the liver (4).

Formation from carotenoids

Carotenoid precursors are converted to vitamin A mainly in the small intestine during absorption. The rate of conversion is relatively slow and the efficiency of ca-

¹ From the Department of Clinical Nutrition, Hoffmann-La Roche Inc, Nutley, NJ and the Nutrition Research Newsletter, Palisades, NY.

² Address reprint requests to A Bendich, Hoffmann-La Roche Inc, 76/412-N, 340 Kingsland Street, Nutley, NJ 07110-1199.

Received September 21, 1987.

Accepted for publication March 15, 1988.

SAFETY OF VITAMIN A

359

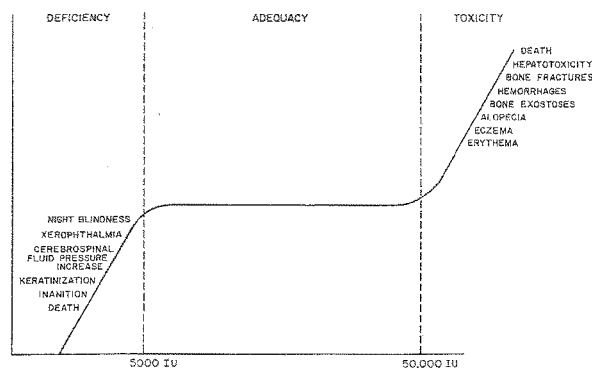


FIG 1. Range of vitamin A intake for adults. Adapted from reference 8.

retinoid absorption in the intestine decreases as carotenoid intake increases (5). The efficiency of carotenoid conversion varies among individuals (3). There are more than 400 known carotenoids but only an estimated 50–60 of these have provitamin A activity. β -Carotene has the greatest provitamin A activity of all known carotenoids. Other carotenoids with provitamin A activity include α -carotene, γ -carotene, and cryptoxanthin (6). The conversion of β -carotene to vitamin A is regulated so that excess vitamin A is not absorbed from carotene sources (7).

Vitamin A deficiency

In humans the most obvious and clinically important manifestation of vitamin A deficiency is the eye disease xerophthalmia, which can lead to permanent blindness (Fig 1) (8). The early stages of xerophthalmia, including the characteristic symptom of night blindness, are reversible but the condition becomes irreversible upon ulceration of the eye tissue (5). The clinical aspects were recently reviewed by Wittpenn and Sommer (9).

Deficiency in industrially underdeveloped countries

Vitamin A deficiency is a major public health problem particularly in industrially underdeveloped countries. Worldwide it is the second most prevalent nutritional disease after protein-calorie malnutrition. Vitamin A deficiency is especially common in tropical and subtropical regions (10). Each year an estimated 1–5 million people throughout the world, usually infants and preschool children, develop vitamin A deficiency and 100 000–250 000 become permanently blind (11).

The deficiency of vitamin A has also been identified as a major killer of children in developing countries. Chil-

dren suffering from this deficiency were found to have substantially increased overall morbidity and mortality rates, mainly from increased rates of respiratory disease and diarrhea (12). Recently, supplementation was shown to decrease mortality and morbidity associated with measles infections in marginally vitamin A-deficient children (13).

Administration in underdeveloped countries

In industrially underdeveloped countries where regular supplementation is generally impractical, high supplementary oral doses of vitamin A are given to children two to four times yearly preferably spaced at even intervals. In these instances each dose would be 100 000 IU for infants aged < 1 y and 200 000 IU for children aged > 1 y. This type of vitamin A supplementation is of great benefit in preventing vitamin A-deficiency blindness and reducing mortality in children (11). Intermittent supplementation of this kind occasionally produces transient symptoms of hypervitaminosis A in susceptible individuals; however, this is medically acceptable under such circumstances because there are no serious or long-lasting effects (14). Other prophylactic intervention measures are vitamin A fortification of food and increased consumption of fruits and yellow and green vegetables.

Deficiency in industrially developed countries

The habitual vitamin A intake of most people in North America and Western Europe is sufficient to result in a rise in liver vitamin A concentrations with each decade of life (15). Nevertheless, some individuals are deficient in vitamin A and the problem may go unrecognized. In two major nutrition surveys—the First Health and Nutrition Examination Survey (NHANES I, 1971–74) (16) and the US Department of Agriculture (USDA) Nation-

TABLE 1
IU and RE equivalents

1 IU = 0.3 μ g preformed retinol
= 0.6 μ g β -carotene
= 1.2 μ g other mixed carotenoids
1 RE = 1.0 μ g retinol
= 6.0 μ g β -carotene
= 12 μ g other mixed carotenoids
= 3.3 IU activity from retinol
= 10 IU activity from β -carotene

wide Food Consumption Survey (1977-78) (17)—vitamin A was found to be a problem nutrient, ie, one in which $\geq 20\%$ of the population surveyed was obtaining $< 70\%$ of the Recommended Dietary Allowance (18) (RDA). These data were confirmed more recently in NHANES II data, which were extended to include black and Hispanic populations (10). It is obvious, therefore, that a significant proportion of the US population is receiving lower than recommended levels of vitamin A.

Vitamin A adequacy

Vitamin A adequacy is usually discussed in terms of recommended allowances designed to meet or exceed the needs of the majority of individuals. Adequacy is based on maintenance of the normal range of vitamin A in serum or plasma (0.70–2.79 μ mol/L).

Vitamin A is expressed either as international units (IU) or retinol equivalents (RE). In the United States the RDA for vitamin A is now given in RE (18). Because food composition tables still employ the more widely used IU, however, this unit is still used in applied nutrition. Table 1 shows the IU and RE equivalents. To evaluate diets, the following formula is applicable:

$$\text{RE} = \mu\text{g retinol} + \mu\text{g } \beta\text{-carotene} \times 0.167 \\ + \mu\text{g other mixed carotenoids} \times 0.083 \quad (1)$$

For comparison, the equivalent IU values can be calculated by multiplying the RE values by 3.33 (6). Because each system employs different assumptions about the efficiency of conversion of carotene to vitamin A in the body, conversion from IU to RE is not straightforward. The ambiguity lies in the fact that the term vitamin A is used both for preformed vitamin A and for dietary vitamin A, which consists of a mixture of provitamin A carotenoids and vitamin A. Thus, the RDA of 1000 RE for adult males is equivalent to 5000 IU of dietary vitamin A when the intake consists of 2500 IU of preformed vitamin A and 2500 IU of β -carotene equivalents. In terms of preformed vitamin A alone, the RDA is 3333 IU. When considering supplements of preformed vitamin A, the latter value should be used. The 1980 RDAs for vitamin A for the different age and sex groups, including pregnant and lactating women, are listed in Table 2 (18).

The allowances are intended to provide for individual variation among most normal persons as they live in the United States under usual environmental stresses.

In the 1974 tables (19) vitamin A activity is given as REs and IUs. In the 1980 edition (18) only REs are given. The differences between the RE and IU values are based on the assumption that the RE for infants aged < 6 mo is all as retinol in milk during the first 6 mo of life. All subsequent intakes are assumed to be half as retinol and half as β -carotene when calculated from IUs. As REs, three-fourths are as retinol and one-fourth as β -carotene.

Vitamin A Toxicity

Perspective

Worldwide the incidence of vitamin A excess, or hypervitaminosis A, is a very minor problem compared with the incidence of vitamin A deficiency. An estimated 200 cases of hypervitaminosis A occur annually whereas an estimated 1 million people develop vitamin A deficiency each year (5).

Over the last 50 y the number of reported cases of hypervitaminosis A has remained relatively constant despite the significant growth in production and use of vitamin A supplements. As indicated in Figure 2, higher incidences occurred in 1952–55 and again in 1970–72 (5, 20–38). The earlier rise coincided with the use in Europe of two very potent vitamin A-vitamin D supplement preparations administered by prescription to infants primarily in France and Spain. The second involved many cases in which high doses of vitamin A were taken for dermatological disorders either by prescription or by self-medication.

The potential for high intake of vitamin A does exist. The vitamin is available without prescription in concentrations of 25 000 IU per capsule; four of these capsules taken every day would provide approximately 20 times the RDA, which over a period of months might eventu-

TABLE 2
Recommended daily dietary allowances of vitamin A*

Sex-age group	RDA	
	RE	IU
Infants aged < 6 mo	420	1400
Infants aged 6 mo–1 y	400	2300
Children aged 1–3 y	400	2300
Children aged 4–6 y	500	2500
Children aged 7–10 y	700	3300
Boys and men aged ≥ 11 y	1000	5000
Girls and women aged ≥ 11 y	800	4000
Additional allowance for pregnancy	+200	+1000
Additional allowance for lactation	+400	+2000

* From reference 18.

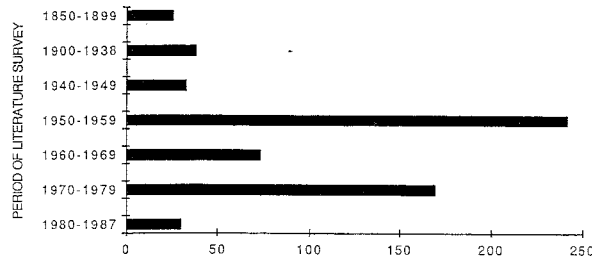


FIG 2. Cases of overt signs of hypervitaminosis A reported in the literature resulting from food and/or supplements. Cases reported between 1850 and 1979 were cited in Bauernfeind (5). Cases reported between 1980 and 1987 are taken from data of Farris and Erdman (20) ($n = 1$), Ramachandran et al (21) ($n = 11$), Misbah et al (22) ($n = 1$), Bush and Dahms (23) ($n = 1$), LaMantia and Andrews (24) ($n = 1$), James et al (25) ($n = 1$), Wason and Lovejoy (26) ($n = 1$), Fumich and Essig (27) ($n = 1$), Baadgaard and Thomsen (28) ($n = 1$), Forouhar et al (29) ($n = 1$), White (30) ($n = 1$), Rosenberg et al (31) ($n = 1$), Schurr et al (32) ($n = 1$), Bürgi et al (33) ($n = 1$), Silverman and Leeks (34) ($n = 1$), Weber et al (35) ($n = 1$), Hatoff et al (36) ($n = 1$), Ellis et al (37) ($n = 1$), and Inkeles et al (38) ($n = 2$).

ally cause toxicity symptoms in some individuals. Several scientists (6, 20, 39) expressed concern over the possibility that publicity about the use of vitamin A and its synthetic analogues in the treatment of acne and other dermatological problems and certain cancers as well as its possible role in cancer prevention might lead to inappropriate self-medication with vitamin A supplements.

In 1980 the Food and Drug Administration conducted a national telephone survey of an age-stratified random sample of 2991 adults to determine total usage of vitamin-mineral supplements as well as intake of specific nutrients. With the exception of pregnant and lactating women, 40% of the population consumed one or more vitamins and/or mineral supplements. Data on intake of specific nutrients by supplement users showed that median vitamin A intake in all groups was between 100 and 200% of the RDA. Maximum intakes (395–500% of the RDA) were recorded in ~5% of all supplement users (40). Even with 5% of the supplement users consuming three to five times the RDA, symptoms of hypervitaminosis A were not reported at these levels.

Hypervitaminosis A can be divided into two categories: acute, resulting from ingestion of a very high dose over a short period of time, and chronic, resulting from continued ingestion of high doses for months or even years.

Acute hypervitaminosis A

Biochemical basis

High intakes (over five times the RDA) of vitamin A over short periods of time (2–3 wk) raise steady-state serum vitamin A values from a normal range of between 0.70 and 2.79 $\mu\text{mol/L}$ to levels $> 2.79 \mu\text{mol/L}$. Levels

$> 62.8 \mu\text{mol/L}$ have been reported. When vitamin A intake is discontinued, levels rapidly return to normal.

Excess retinol causes changes in biological membranes, an effect believed to be due to retinol's surface-active properties. Retinol, however, does not show surface-active effects when it is bound to RBP (4). Therefore, toxicity appears to occur only when the amount of vitamin A present exceeds the capacity of RBP to bind to it. Vitamin A that is not bound to RBP binds to lipoproteins, and in this form it has toxic effects when it comes into contact with membranes and body cells (5). In other words, in vitamin A toxicity, plasma RBP levels are normal but concentrations of vitamin A not bound to the specific RBP are increased (41).

Symptoms of acute hypervitaminosis A

Table 3 lists the most common symptoms of hypervitaminosis A as identified by Bauernfeind (5) in a survey of 200 literature reports. Each symptom listed in the table was mentioned in at least 25 reports. Typical symptoms of acute hypervitaminosis A include bulging fontanels in infants and headache in adults (both presumably resulting from increased intracranial pressure), nausea, vomiting, and occasionally fever, vertigo, and visual disorientation (6). Peeling of the skin may also occur (42). The symptoms are generally transient and do not lead to permanent adverse effects (6). The symptoms of hypervitaminosis A may differ depending on the age of the victim and on whether the condition is acute or chronic.

Natural food causes

Cases of acute hypervitaminosis A caused by natural food sources are rare but they have a very long history. It has been hypothesized that pathological changes found in a *Homo erectus* skeleton (prehuman ancestor) from

TABLE 3
The most commonly reported symptoms of hypervitaminosis A*

Symptom	Number of mentions in 200 case reports
Nausea, vomiting	68
Fatigue, malaise, lethargy, somnolence, weakness, asthenia	64
Headache	56
Bulging fontanel	51
Elevated serum vitamin A	50
Anorexia	46
Mouth or lip fissures or chapping	41
Irritability	37
Ataxia (vertigo, dizziness, giddiness, equilibrium or walking problems)	34
Dry or dry scaly skin	34
Elevated CSF pressure, cranial hypertension, pseudotumor cerebri	33
Allopecia	32
Hepatomegaly, palpable or tender liver	32
Tenderness, aching, or swelling of the extremities	31
Pruritis	29
Double, distorted, or blurred vision	27
Hemorrhages, petechia (bleeding gums, membrane, nose, skin)	25
Joint pains	25

* Adapted from Bauernfeind (5).

1.5 million years ago were caused by hypervitaminosis A attributable to the consumption of carnivore livers. Because carnivores derive and store large amounts of preformed vitamin A from livers of their prey, their own livers may contain $> 3.41 \mu\text{mol/g}$ (43). Normal levels of vitamin A in carnivores are difficult to establish. The range observed over time and in different species varies from a low of $0.92 \mu\text{mol/g}$ in the livers of antarctic huskies (44) to $36.14 \mu\text{mol/g}$ in baiibut liver (45). Consumption of the livers of carnivorous animals or large fish has caused severe acute illness in more recent times (21, 22, 44-46).

The livers of herbivores (plant-eating animals, such as chickens, cows, and lambs) contain $\sim 0.17 \mu\text{mol}$ vitamin A/g. These are generally safe when consumed in moderation as part of a mixed diet; however, regular consumption of large quantities of liver might contribute to excess vitamin A intakes (43).

Supplement overdose

Most cases of acute hypervitaminosis A result from overdose of supplements rather than from ingestion of food sources: of the 579 cases reported from 1850 until 1980, only 129 resulted from consumption of unusual types of animal liver. The majority resulted either from misuse of vitamin A supplements by the consumer or from overprescribing of supplements by a physician. Overdosing of children by parents or grandparents was the primary example of hypervitaminosis A caused by the consumer, accounting for 25% of cases (5).

Bush and Dahms (23) described a fatal case of hypocalcemia, hyperphosphatemia, bleeding disorders, and pulmonary insufficiency in a newborn baby who had received more than 60 times the recommended amount of vitamin A per day for 11 d. The baby's parents had administered an incorrect amount of a prescribed supplement of vitamin A in an aqueous solution.

Some of the preconceptions or misunderstanding that led to overdosing by the public in these reports may have included the belief that if a little is good, more should be better; confusion about product potency; confusion over instructions (eg, drops vs droppersful); an self-medication for dermatological conditions or other miscellaneous reasons.

Prescription-related hypervitaminosis A occurred when physicians failed to stress to patients or parents the dangers of excessive vitamin A levels (for appropriate level, see Table 2), chose to accept some hypervitaminosis A symptoms in exchange for therapeutic benefits, or failed to warn dermatological patients not to exceed the recommended time period for taking high doses of vitamin A. Circumstances causing hypervitaminosis A in case reports published since 1980 are described in Table 4. Representative or recent cases of acute hypervitaminosis A resulting from abnormal vitamin consumption pattern in adults and children are described in Table 5.

Chronic hypervitaminosis A

Chronic hypervitaminosis A is more common than acute hypervitaminosis A. Its symptoms (Fig 1) are highly variable but anorexia, dry itchy skin, loss of hair (more prominent in adults), increased intracranial pressure, hepatomegaly (more prominent in children), and fatigue are among the most common manifestations. Women may show menstrual disturbances and children often show bone changes (subperiosteal new bone growth and cortical thickenings, especially of the small bones of the hands and feet and the long bones) that do not occur in adults (5). Elevated blood lipid levels are sometimes observed in patients with chronic hypervitaminosis A (51, 52).

Chronic hypervitaminosis A often goes unrecognized unless a careful history is taken and serum vitamin A is determined (23). Serum levels of vitamin A are generally $> 3.49 \mu\text{mol/L}$ and there are increased levels of the unbound retinol resulting in a change in the ratio of free retinol to retinol bound to RBP as well as increases in retinyl esters (6).

A review of the literature suggests that among adult vitamin A toxicity is uncommon at doses $< 100,000$ IU/d (5). Most of the literature deals with reported cases of hypervitaminosis A in which dose is not totally reliable. However, there are several reports of controlled studies: Waid et al (53), 36,000 IU/d for 6 mo; Kinley and Kraus (54), 36,000 IU/d for ≤ 6 mo; Dubin and Hazen (55), 100,000 IU/d for ≤ 23 mo; and Van Bruggen and Straumfjord (56), 100,000 IU/d for ≤ 36 mo. Minor symptomatic and physical changes affecting the skin and mucous membranes, all of which are known to be revers-

TABLE 4
Causes of vitamin A overdose in cases reported since 1980

Reference	Patient	Dose	Circumstances leading to overdose
LaMantia and Andrews, 1981 (24)	62-y-old man	4 000 000 IU vitamin A and 10 mg vitamin D	Patient ingested a veterinary vitamin preparation on impulse.
Farris and Erdman, 1982 (20)	16-y-old boy	50 000 IU/d	Self-medication for acne.
James et al, 1982 (25)	5-y-old girl	Capsules containing 25 000 IU vitamin A and 250 µg vitamin D	Supplements given by mother: in attempt to improve eyesight. Child later took more of the vitamin without supervision.
Silverman and Lecks, 1982 (34)	6-y-old boy	20 000 IU vitamin A	Supplements given by nonmedical practitioners to patient on very restricted protein diet in an effort to treat allergies.
Wasoa and Lovejoy, 1982 (26)	7-y-old boy	25 000-50 000 IU vitamin A/d for 1 y plus unspecified multivitamins	Supplements administered by parents who customarily took large doses of vitamins themselves.
Furnich and Essig, 1983 (27)	15-y-old boy	≈100 000 IU/d	Patient hoped to improve athletic performance.
Baadsgaard and Thomsen, 1983 (28)	35-y-old woman	60 000-100 000 IU/d for 6 y	Self-treatment of psoriasis
Forouhar et al, 1984 (29)	37-y-old woman	75 000 IU for 4 y and 150 000 IU for 2 y	Self-prescribed supplements for self-diagnosed problems with night vision.
Bush and Dahms, 1984 (23)	Newborn	90 000 IU/d for 11 d	Parents accidentally administered excess doses of prescribed supplement.
White, 1984 (30)	44-y-old man	150 000 IU/d	Prescribed for skin lesions. Patient permitted to continue treatment indefinitely.
Bürgi et al, 1985 (33)	62-y-old woman	≈250 000 IU/d for 5 y	Over-the-counter preparation taken to gain vitality.

ible, were reported in the low-dose study by Wald (53). No toxic effects were reported in the other three studies.

Fatal toxicity in adults was only reported in two cases and both were complicated by extenuating circumstances and concurrent illnesses. These cases associated

with chronic hypervitaminosis A are discussed later in this paper under the section entitled General Health Status.

Among children, chronic hypervitaminosis A appears to occur at dosages in the range of 12 000 to > 500 000

TABLE 5
Representative cases of acute hypervitaminosis A

Age range of subjects	Number of subjects	Dose	Major adverse effects	Reference
Infants to 7 y	23	300 000-750 000 IU	Bulging fontanel, headache, nausea, vomiting	Marie and Sée, 1953 (47) Marinoni and Panizon, 1954 (48)
9-10 y	2	5 000 IU and 300 000 IU	Pleural effusion, ascites, EEG abnormalities, seizure, bone changes	Rosenberg et al, 1982 (31) Schurr et al, 1983 (32)
Females 25-37 y	3	75 000 IU, 1 000 000 IU, and 1 300 000 IU	Headache, vomiting, splenomegaly, ascites, dermatitis, visual disturbances	Furman, 1973 (49) Misbah et al, 1984 (22) Forouhar et al, 1984 (29)
Males 30-62 y	3	150 000 IU, 4 000 000 IU, and 51 000 000 IU	Headache, vomiting, visual disturbances, anemia, dermatitis, hyperglycemia, hepatomegaly, hypercalcemia, high serum vitamin A	Goeckenjan et al, 1972 (50) LaMantia and Andrews, 1981 (24) White, 1984 (30)

TABLE 6
Factors influencing vitamin A toxicity

Factor	Effect	Reference
Vehicle of administration	Toxicity more rapid when vitamin administered in aqueous rather than oily solution.	Koerner and Voellm, 1973 (57)
Liver disease	Excess stores of vitamin A in liver increase risk of hypervitaminosis A during liver disease.	Hatoff et al, 1982 (36)
Hemodialysis therapy	Patients may have elevated vitamin A levels and anemia; hypercalcemic subjects have higher serum vitamin A levels than do normocalcemic subjects.	Farrington et al, 1981 (58) Blumberg et al, 1983 (59) Ono, 1984 (60)
Ethanol	Animal studies suggest interaction between ethanol and vitamin A causing liver damage; no such data available on humans.	Leo and Lieber, 1983 (61)
Vitamin C Protein malnutrition	High doses of vitamin A reduce tissue storage of ascorbic acid. Vitamin A linked with protein metabolism; protein malnutrition increases risk of hypervitaminosis.	Bauernfeind, 1980 (5) Weber et al, 1982 (35) Süverman and Lecks, 1982 (34)
Vitamin D toxicity	Vitamin A reduces hypercalcemia and other adverse effects of vitamin D toxicity in experimental animals.	Arnrich, 1978 (62) Bauernfeind, 1980 (5)
Vitamin E	Vitamin E protects against disruption of membrane lipoprotein structure (in animals) and reduced number of congenital anomalies produced by vitamin A in rats; no data in humans.	Glauer et al, 1963 (63) Lucy and Dingle, 1964 (64) Soliman, 1972 (65) Bauernfeind, 1980 (5)
Vitamin K	Possible antagonism between vitamins A and K; animals and humans with hypervitaminosis A manifest hypoprothrombinemia (a sign of vitamin K deficiency).	Bauernfeind, 1980 (5)

IU/d, depending upon the size and weight of the child (5).

Many reports of hypervitaminosis A depend on patients' estimates of the doses taken, which may not be accurate. Toxic manifestations are unlikely to occur at some of the lower vitamin A intakes reported. In the instances where vitamin A was administered under the supervision of a physician (thus resulting in a more accurate estimate of intake), manifestations of hypervitaminosis A were abstract or slight, indicating a higher tolerated dose and duration (5).

There are great variations in response between individuals and, in addition, a wide range of health and dietary factors can influence susceptibility to chronic hypervitaminosis A. Among these factors (shown in Table 6) are dosing regimen and form in which the vitamin is given, age and body weight of the consumer, general health status and concurrent health problems (such as anemia, malnutrition, liver, and kidney disease) that can compromise response patterns, and dietary factors, such as ethanol intake, nutrient interactions (eg, with vitamins D, E, C, and K), and protective nutrient factors.

Dosing regimens associated with chronic hypervitaminosis A

An examination of 75 cases of chronic hypervitaminosis A in adults showed that symptoms develop in a shorter period of time when higher levels of the vitamin are consumed (5). For a dose of 100 000 IU, the response

time was 6–108 mo; for 150 000–200 000 IU, 6–85 mo; for 400 000–700 000 IU, 1–36 mo; and for 1 000 000 IU, days to weeks.

Form of the vitamin

Aqueous dispersions of vitamin A cause higher plasma vitamin A values than do oily solutions (5) and at comparable doses symptoms of toxicity appear sooner after the administration of vitamin A in the aqueous form (57).

Age and body weight

Hypervitaminosis A in children corresponds to basic toxicologic principles: lower body weight results in toxicity at lower doses than those observed in adults with higher body weights. In children, however, hypervitaminosis A develops quickly and usually resolves quickly. Farris and Erdman (20) reported a severe and prolonged case of vitamin A toxicity in a 16-y-old boy who had consumed 50 000 IU vitamin A/d for 2 y (chronic usage).

General health status

Anemia. One of the two fatalities in adults that has been in part attributed to chronic hypervitaminosis A occurred in a 62-y-old woman with hemolytic anemia (33). The patient had taken up to 17 capsules of a multivitamin preparation daily (each containing 15 000 IU vitamin A) for 5 y, corresponding to an intake of 250 000 IU vitamin A/d or 300 million IU over 5 y. The multivita-

min preparation had been taken by the woman because she thought it would increase vitality.

Protein malnutrition. There is a close link between vitamin A metabolism and protein metabolism because an adequate protein intake is necessary for normal synthesis and functioning of all proteins, including RBP (5). There are two recent reports of cases in which low doses of vitamin A led to hypervitaminosis A in protein-deficient patients. Silverman and Lecks (34) described a case of vitamin A toxicity and protein-calorie deficiency in a 6-y-old boy; 20 000 IU vitamin A and 800 IU vitamin D were administered daily for 1 y before hospitalization. Weber et al (35) described a 62-y-old man who developed hypervitaminosis A that presented as liver dysfunction after ingesting 40 000–50 000 IU/d for 7 y. The patient also suffered from protein deficiency because of an abnormal diet. When he was placed on a normal diet and ingestion of 40 000–50 000 IU of vitamin A was stopped, the vitamin A toxicity symptoms gradually disappeared.

Liver disease. Individuals with excess stores of vitamin A in the liver are at higher risk of developing hypervitaminosis A. A 79-y-old man who had consumed 50 000 IU vitamin A/d for 17 y but showed no signs of hypervitaminosis A had vitamin A levels in his liver 40 times higher than normal (66). Hatoff et al (36) described a 42-y-old male vegetarian who developed hypervitaminosis A after an infection from viral hepatitis. Upon questioning, it was revealed that he had consumed 25 000 IU of vitamin A/d for 10 y as well as an additional 25 000 IU/d from food. He had discontinued use of vitamin A at the time of being diagnosed with hepatitis. It is assumed that the patient probably had mild, unrecognized chronic hypervitaminosis A before his acute illness; he had noted dry skin, cracked lips, and fatigue for the year preceding hospital admission. It is known that the level of RBP is reduced during viral hepatitis. Because vitamin A is more toxic when not bound to RBP, it has been hypothesized that the viral hepatitis was responsible for the unmasking of hypervitaminosis A in this patient. Of the two fatal cases associated with chronic hypervitaminosis A in adults, the second was associated with liver disease. Leitner et al (67) described a fatal case of cirrhosis in a 48-y-old man who had consumed large but variable quantities of carrot juice over a long period of time and who intermittently took retinol supplements as well. Starting with 3000 IU/d as retinyl acetate he gradually increased this amount to 5 000 000 IU/d. Hypervitaminosis A may therefore have played a part in his death (68). However, it was suggested by Sinclair (69) that falcariinol or some other toxic substance found in carrots, might have been responsible. In fact, death was attributed by the coroner to carrot juice addiction (70).

Kidney disease. Patients undergoing hemodialysis for renal failure appear to be at increased risk of hypervitaminosis A. Investigators (58–60) found higher than normal serum vitamin A levels in patients undergoing hemodialysis and recommend monitoring of serum vitamin A in this population group.

Hyperlipoproteinemia. It is possible that hyperlipopro-

teinemia may be associated with high serum vitamin A levels. In a study by Ellis et al (37) it was found that eight out of nine type V hyperlipoproteinemic subjects had retinol present in the chylomicron-very-low-density lipoprotein (VLDL) fraction whereas the nine control subjects did not. None of the subjects was using vitamin A supplements and none had any clinical symptoms of hypervitaminosis A. This observation could be explained by the fact that hyperlipoproteinemia type V is defined as a mixed hyperlipoproteinemia of the two lipoproteins that deliver fat and fat-soluble vitamins to the body. Individuals with this condition may therefore have a higher vitamin A content in this lipoprotein fraction.

Dietary factors

Ethanol intake. In rats, amounts of vitamin A that were innocuous when administered alone caused severe liver damage when the animals were also given ethanol on a chronic basis (61). The liver lesions included types of damage that are not produced in rats by ethanol alone: necrosis, inflammation, and fibrosis. Whether a similar interaction occurs in humans is unknown.

Nutrient interactions. 1) Interactions between vitamins A and D. Because vitamins A and D are often consumed together, it can be difficult to separate the symptoms of the two hypervitaminoses. Some symptoms listed for hypervitaminosis A may actually be caused by hypervitaminosis D (for example, hypercalcemia). Symptoms common to both hypervitaminoses include, among others, weakness, fatigue, lassitude, headache, nausea, vomiting, diarrhea, polydipsia, anorexia, weight loss, and conjunctivitis (5).

2) Interactions between vitamins A and E. Although many symptoms of hypervitaminosis A may be mitigated by vitamin E, interactions between these two vitamins are not without unfavorable effects as well. Animal studies over a wide range of dosages showed that vitamin A can reduce vitamin E activity by as much as 30% and can also decrease plasma and liver vitamin E levels (71). In a human study, however, 25 000 IU/d of vitamin A given for 16 wk (as a retinyl palmitate supplement) did not affect plasma vitamin E levels (72).

3) Interactions between vitamins A and C. There may be an interaction between hypervitaminosis A and vitamin C deficiency in species requiring vitamin C (ascorbic acid). In guinea pigs hypervitaminosis A is associated with reduced liver and serum vitamin C levels and administration of ascorbic acid reduces hypervitaminosis A symptoms. In humans high intakes of vitamin A appear to reduce tissue storage of ascorbic acid (5).

4) Vitamin K. There may be an antagonism between vitamin A and K as is indicated by the appearance of hypoprothrombinemia, a sign of vitamin K deficiency, in both animals and humans with hypervitaminosis A (5).

Protective nutrient factors. 1) Vitamin D. When vitamins A and D are both taken in excess, they appear to protect against some of the other's adverse effects. Large doses of vitamin A have reduced hypercalcemia and

other adverse effects of vitamin D toxicity in experimental animals (5, 62). Experimental animals dosed with large quantities of both vitamins showed less disruption of bone metabolism than expected.

2) Vitamin E. In animal models vitamin E protects against the disruption of membranes caused by hypervitaminosis A (63, 64). In experimental animals administration of vitamin E eliminated some toxic effects of vitamin A; in one experiment it reduced the number of congenital anomalies produced by vitamin A in rats (65). The addition of a small amount of vitamin E to the vitamin A preparations used in intermittent high-level dosing in developing countries has been judged to be a justifiable practice (5).

Reversal of hypervitaminosis A. In most cases, when vitamin A intake is discontinued, many symptoms of hypervitaminosis A are relieved within a few days or a week. Full recovery usually follows within weeks or months (5) although there appear to be individual differences in the recovery time from hypervitaminosis A even when patients have all consumed similar doses (19, 22).

Long-term or irreversible effects of hypervitaminosis A include bone changes and cirrhosis. Of all the chronic hypervitaminosis A symptoms, bone changes are among the most lasting although permanent bone malformations appear to be relatively rare (5). There is also some evidence that hypervitaminosis A can cause irreversible damage to the liver (73). Long-term follow-up studies have documented the appearance of cirrhosis that was histologically similar to alcohol-induced cirrhosis in patients who took very high levels of vitamin A for very long periods of time (74). Inkeles et al (38) reported cirrhosis in a nondrinking subject who had consumed large amounts of beef liver over a period of 8 or 9 y. After initiation of a low-vitamin A diet, the patient's liver function returned to normal.

Teratogenesis

Animals

Hypervitaminosis A. Very high doses of vitamin A have been shown to produce more than 70 types of congenital anomalies in experimental animals. The dosage varies among species.

In rats 25 000 IU/d during critical periods of organogenesis produced malformations. Correcting for the interspecies difference in body weight, this dose of vitamin A is equivalent to > 25 million IU for a human. The recommended intake of vitamin A in rats is 100 IU/d (75). The offspring of rats given a single large dose of vitamin A in early pregnancy (75 000–150 000 IU on days 9, 10, and 11) had abnormalities including absence of the brain, absence or abnormality of the eyes, cleft palate, malformations of the extremities, labial fissures, dental anomalies, and cataracts (2).

In a 1973 study by Hutchings et al (76), pregnant rats were given 60 000 IU vitamin A (~230 000 IU/kg) on

days 14 and 15 of gestation. In a 1974 study Hutchings and Gaston (77) gave pregnant rats 90 000 IU vitamin A (~280 000 IU/kg) on days 17 and 18. No congenital malformations were observed in either study; however, behavioral deficits (including delay in learning time) were observed, especially among offspring of animals dosed at days 14 and 15. The behavioral teratogenesis was attributed to damage to the hippocampal and cerebellar areas in the brain (77). The behavioral effects of prenatal hypervitaminosis A on rats have been reviewed by Arnrich (62), Vorhees and Butcher (78), and Hutchings (79).

Teratogenicity was demonstrated in mice, hamsters, guinea pigs, rabbits, and pigs (80). In a dose-response study in hamsters, it was found that the lowest dose of vitamin A that produced gross malformations was 100 times the requirement for the vitamin in this species (81).

In a study by Cohan (82) the dosage of vitamin A that was required to cause teratogenicity in rats and mice was equivalent on a weight basis to 4.6 million IU vitamin A given to an adult female (55 kg). If the dosage comparison utilized surface area equivalents, the dosage of vitamin A would be equivalent to 3.7 million IU in the adult female. The correlation from animal studies to humans would therefore result in a potential teratogenic dosage of vitamin A that would be 462 times the current US RDA for vitamin A for pregnant women, which is 1000 RE/d. Although it is not possible to make direct extrapolations from animal to human data, such studies can serve as a point of reference providing an idea of the probable expected level at which equivalent dose ranges might prove teratogenic in humans because there are no data that define a teratogenic level of vitamin A.

Vitamin A deficiency. Vitamin A deficiency can also cause birth defects in animals. Carefully controlled animal studies using vitamin A-deficient diets have resulted in incomplete pregnancies. If the animals were given diets marginally deficient in vitamin A, severe congenital malformations were found in the offspring (14).

Humans

Excessive intake during pregnancy. Five cases of birth defects were reported where unusually large doses of vitamin A had been taken during pregnancy. It should be emphasized, however, that no clear cause-and-effect relationship was demonstrated in any of these cases. Pilotti and Scorta (83) described a case in which a physician prescribed a daily regimen of 40 000 IU vitamin A and 15 mg vitamin D to a woman from about day 40 to day 70 of the pregnancy. The woman gave birth to a child with urinary tract abnormalities. Bernhardt and Dorsey (84) reported a case in which a woman who had taken a fish-oil product daily that contained 25 000 IU of vitamin A during the first trimester of pregnancy and 50 000 IU from months four through nine gave birth to a child with congenital abnormalities of the urinary tract. Stange et al (85) reported a case of malformations of the central nervous system, hypoplastic kidneys, and small adrenal glands in a neonate born in the 42nd week who died

shortly after delivery. The mother had taken 150 000 IU vitamin A/d from gestation day 19 to day 40 for treatment of acne. No symptoms of hypervitaminosis had been reported during the pregnancy. Von Lennep et al (86) described a fetus with partial sirenomelia detected by prenatal diagnostic techniques in a mother who had taken large doses of vitamin A and vitamin E daily (150 000 IU vitamin A and 210 mg vitamin E) from 2 wk before until 2 wk after the presumed date of conception. Sirenomelia is a congenital anomaly characterized by fusion of the legs. Mounoud et al (87) described a 2-y-old boy with Goldenhar's syndrome (oculoauriculovertebral dysplasia) whose mother, a laboratory assistant, had accidentally swallowed 10 mL of an oily solution of vitamin A—IUs not specified but estimated at 500 000 by Rosa et al (88)—in her second month of pregnancy.

In a recent review of teratogenicity of vitamin A congeners, Rosa et al (88) listed 12 unpublished cases of birth defects associated with use of high levels of vitamin A during pregnancy. Two of the cases occurred before 1984 and involved excessive maternal vitamin A exposure (40 000 IU and 60 000 IU/d). Nine of the 10 additional unpublished cases that occurred since 1984 were associated with high doses of vitamin A with long-term exposure before and after conception often in combination with high dosages of other vitamins.

Safe doses of vitamin A during pregnancy and lactation. The overall evidence suggests but does not prove that excessive intake of vitamin A could be teratogenic in humans. In view of the potential for possible adverse effects, Bauernfeind (5) made a cautionary recommendation that pregnant women should not be included in massive-dose supplementation programs used as a public health measure in some developing countries unless future research shows that there is no risk to the fetus. He recommended that vitamin A doses given during pregnancy should not exceed 10 000 IU/d. The safety of this dosage level is supported by the work of Pereira and Begum (89), who reported that vitamin A supplements of 10 000 IU/d maintained blood vitamin A levels in the mother without increasing blood levels in the newborn infant.

Hrubetz et al (90) administered vitamin A to women in the last 3 mo of pregnancy and throughout lactation in doses of 50 000, 100 000, and 200 000 IU/d. Although these dosages far exceed current recommendations, there was no evidence of any deleterious effects to the mothers or the offspring. A statistically significant increase in the vitamin A content of breast milk was observed at the two higher dosages; however, at 50 000 IU the increase was only observed in the first 10 d of lactation and just reached statistical significance. The authors concluded that administration of supplemental vitamin A to nursing mothers affects the vitamin A content of their milk only if the dose exceeds a certain threshold. That threshold appears to be ~50 000 IU/d. Nursing mothers unknowingly may become pregnant before weaning the current nursing and hence high vitamin A levels should

not be given beyond the first prenatal month as a precautionary measure (14).

The safety of the near-universal practice of giving multivitamin supplements to pregnant women was debated in a series of letters to the *British Medical Journal* in which some authors contended that this might increase the risk of malformations because of vitamin A toxicity (91–93). In a prospective case-control study (94) fewer birth defects were observed in a group of mothers who used a daily vitamin supplement containing 4000 IU vitamin A before conception and during early pregnancy than in a control group not receiving vitamins. Both cases and controls were mothers who had previously given birth to offspring with neural-tube defects.

In an earlier 12-y study of 87 mothers who had given birth to offspring with cleft lip and/or cleft palate, Conway (95) reported no abnormalities in 59 subsequent pregnancies among 39 mothers who received vitamin-mineral supplementation (including 12 500 IU vitamin A) during the first trimester. Four abnormalities occurred in 78 pregnancies of 48 mothers who did not receive vitamin therapy. Whether vitamin A played a role in these beneficial effects is not known; however, at the level of vitamin A intake reported in this study, no teratogenic effects were observed.

The present review suggests that prenatal use of a daily multivitamin supplement containing vitamin A may result in fewer birth defects. There has never been a single reported case worldwide of teratogenicity associated with the level of vitamin A present in the prenatal vitamin supplements given to pregnant women in the United States. The supplements usually contain 4000–8000 IU vitamin A. In 1980 the National Academy of Sciences (NAS)—National Research Council (NRC) Recommended Daily Dietary Allowance for pregnant women was set at 1000 RE (3300 IU retinol/d) (18). In 1986 the International Vitamin A Consultative Group recommended an intake of 650 RE/d during pregnancy (96).

Many women of childbearing age do not consume the recommended amount of vitamin A. The National Center for Health Statistics showed that the 50th percentile level of consumption is only 2369–2698 IU (97). The same survey also showed that the female, income-below-poverty-level group had an even lower vitamin A status. This survey data indicating a low maternal vitamin A status may, in part, be an explanation for the number of preterm infants born with very low plasma vitamin A levels. A strong association was found between vitamin A deficiency in preterm infants and the incidence and severity of bronchopulmonary dysplasia (98–100).

Vitamin A deficiency and human birth defects. There is also a possibility that vitamin A deficiency during pregnancy may be associated with human teratogenesis (101). Sarma (102) described a baby with microcephaly and anophthalmia who survived for only 24 h. The mother herself was vitamin A deficient and was blinded by xerophthalmia. Another case involved a child born with eye defects, including microphthalmia and coloboma (103).

Summary. On the basis of all of the current evidence, it is recommended that information about the possible hazards of both deficient and excessive levels of vitamin A be communicated as widely as possible to women of childbearing age. There appears to be little risk of teratogenicity associated with the correct use of the vitamin supplements prescribed for pregnant women. In many cases these supplements may be of significant benefit to both mother and child.

Carotenoids

Overconsumption of carotenoids does not result in hypervitaminosis A presumably because the body converts carotene to retinol in a regulated manner (68). Carotene supplements, when taken in quantities large enough to triple plasma carotenoid levels, did not increase plasma retinol levels (72). Consumption of 30 mg/d of carotenoid supplements may cause hypercarotenemia, a condition characterized by high serum carotenoid levels, large amounts of carotenoids in the liver, and carotenoid deposits in the skin that cause yellow-orange pigmentation particularly in the palms and soles (6). The pigmentation of hypercarotenemia differs from that of jaundice in that the whites of the eyes remain white in carotenemia (2).

Hypercarotenemia is of medical significance because it sometimes results from conditions other than carotene overconsumption and these conditions may require treatment. It may occur in patients with an inherited inability to convert carotene to retinol; such patients may develop vitamin A deficiencies while eating normal diets (68). Hypercarotenemia may also occur as a result of diabetes mellitus, hypothyroidism, and anorexia nervosa (42).

Hypercarotenemia has not been shown to have any adverse systemic effects. There was a single report associating carotenemia with amenorrhea in some nonanorectic women (104). However, in women taking high levels of β -carotene (> 180 mg/d) for long periods of time, no disruption in menstrual function was observed (105) and it was suggested that substances other than carotene in vegetables might be responsible. Carrots, in particular, contain several substances that might be toxic in high doses (69). The hypercarotenemia reported in the amenorrhic women (104) was due to overconsumption of carotene-containing vegetables not to the use of pure carotene supplements; this is also true for most other reported cases of hypercarotenemia.

Summary

Vitamin A is an essential nutrient necessary for vision, reproduction, the integrity of membrane structures, the normal functioning of body cells, growth, and development. Deficiency is a major public health problem in some areas of the world and results in xerophthalmia, permanent blindness, and excess mortality rates among

children. On a global basis reports of vitamin A toxicity are rare and there are few reported fatalities.

Vitamin A adequacy is discussed in terms of recommended allowances appropriate for the needs of the majority of individuals: RDAs established in 1980 are 1000 RE for men and 800 RE for women with extra allowances for women during periods of pregnancy and lactation.

Acute hypervitaminosis A may result from natural food sources (excessive consumption of livers of carnivorous animals or large fish) or more frequently from overconsumption of vitamin A supplements. Acute hypervitaminosis A may occur after ingestion of 500 000 IU (100 times the RDA) or more by an adult (or proportionately smaller doses by children) over a short period of time. The most common symptoms include nausea and vomiting, fatigue, headaches, bulging fontanel (in infants), elevated serum vitamin A, and anorexia. All of these symptoms are usually reversible on cessation of overdosing.

Chronic hypervitaminosis A may occur when excessive amounts of vitamin A are consumed over long periods of time. Many cases of hypervitaminosis go unnoticed so that the levels and duration of intake that may result in chronic hypervitaminosis are controversial: in adults it is doubtful whether symptoms can occur at doses < 100 000 IU/d; in children the range is from 12 000 to > 500 000 IU/d depending on body size and weight. Factors influencing chronic hypervitaminosis A include dosing regimen, physical form of the vitamin, general health status (anemia, malnutrition, liver and kidney diseases, and hyperlipoproteinemia), dietary factors (such as ethanol and protein intake), and interactions with vitamins C, D, E, and K.

Vitamin A given at very high levels (100 times NRC levels) is teratogenic in animals and a deficiency of the vitamin during pregnancy can also cause birth defects. Several cases of human congenital malformations associated with maternal overuse of high doses of vitamin A have been reported but no cause-and-effect relationship has been established. It is recommended that vitamin A doses given during pregnancy should not exceed the US RDA level of 2424 RE/d. Nursing mothers should not receive > 15 152 RE/d to avoid excess vitamin A content of their milk. Deficiency of vitamin A in pregnancy has also been associated with human congenital abnormalities.

Overdosing by the general public may result from confusion over product potency or dosing instructions or from inappropriate self-medication. Prescribed supplements may lead to hypervitaminosis A if physicians do not communicate the dangers of excess consumption to patients. **2**

References

1. Sporn MB, Roberts AB. Biological methods of analysis and assay of retinoids—relationships between structure and activity. In:

- Sporn MB, Roberts AB, Goodman DS, eds. *The retinoids*. Vol 1. New York: Academic Press, 1984:236-81.
2. National Nutrition Consortium, Inc. *Vitamin-mineral safety, toxicity, and misuse. Report of the Committee on Safety, Toxicity, and Misuse of Vitamins and Trace Minerals*. Chicago: American Dietetic Association, 1978.
 3. Olson JA. Vitamin A. In: *Nutrition reviews' present knowledge in nutrition*. 5th ed. Washington, DC: The Nutrition Foundation, 1984:176-91.
 4. Goodman DS. Plasma retinol-binding protein. In: Sporn MB, Roberts AB, Goodman DS, eds. *The retinoids*. Vol 2. New York: Academic Press, 1984:41-88.
 5. Bauernfeind JC. The safe use of vitamin A: a report of the International Vitamin A Consultative Group. Washington, DC: The Nutrition Foundation, 1980.
 6. Underwood BA. Vitamin A in animal and human nutrition. In: Sporn MB, Roberts AB, Goodman DS, eds. *The retinoids*. Vol 1. New York: Academic Press, 1984:281-392.
 7. Underwood BA. Vitamin A intoxication. *JAMA* 1985;254:232-3(letter).
 8. Miller DR, Hayes KC. Vitamin excess and toxicity. In: Hathcock JN, ed. *Nutr Toxicol* New York: Academic Press, 1982:81-134.
 9. Wittmann J, Sommer A. Clinical aspects of vitamin A deficiency. In: Bauernfeind JC, ed. *Vitamin A deficiency and its control*. Orlando, FL: Academic Press, 1986:177-206.
 10. Anonymous. Vitamin A deficiency—a global disease. *Nutr Rev* 1985;43:240-3.
 11. McLaren DS. Global occurrence of vitamin A deficiency. In: Bauernfeind JC, ed. *Vitamin A deficiency and its control*. Orlando, FL: Academic Press, 1986:1-18.
 12. Eckholm E. Diet deficiency of vitamin A is revealed as a major killer. *New York Times* 1985 Sept 3:C1(col 5, 6), C12(col 5, 6).
 13. Barclay AJG, Foster A, Sommer A. Vitamin A supplements and mortality related to measles: a randomised clinical trial. *Br Med J* 1987;294:294-6.
 14. Wallingford JC, Underwood BA. Vitamin A deficiency in pregnancy, lactation and the nursing child. In: Bauernfeind JC, ed. *Vitamin A deficiency and its control*. New York: Academic Press, 1986:101-52.
 15. McLaren DS. The luxur vitamins—A and B12. *Am J Clin Nutr* 1981;34:1611-6.
 16. United States Department of Health, Education and Welfare, Public Health Service. *First health and nutrition examination survey (NHANES I), 1971-1974*. Rockville, MD: National Center for Health Statistics, 1979. (PHS 79-1657.)
 17. United States Department of Agriculture, Human Nutrition Information Service. *Nationwide food consumption survey*. Hyattsville, MD: USDA, 1980. (Preliminary report 2.)
 18. Committee on Dietary Allowances, Food and Nutrition Board, National Research Council. *Recommended dietary allowances*. Washington, DC: National Academy Press, 1980.
 19. Committee on Dietary Allowances, Food and Nutrition Board, National Research Council. *Recommended dietary allowances*. Washington, DC: National Academy Press, 1974.
 20. Farris WA, Erdman JW Jr. Protracted hypervitaminosis A following long-term, low-level intake. *JAMA* 1982;247:1317-8.
 21. Ramachandran S, Premachandra P, Silva DKD. Clinical curio: acute vitamin A toxicity from ingesting fish liver curry. *Br Med J* 1983;287:897.
 22. Mstbah SA, Peiris JB, Atukorala TMS. Ingestion of shark liver associated with pseudotumor cerebri due to acute hypervitaminosis A. *J Neurol, Neurosurg Psychiatry* 1984;47:216(letter).
 23. Bush ME, Dahms BB. Fatal hypervitaminosis A in a neonate. *Arch Pathol Lab Med* 1984;108:838-42.
 24. LaMantia RS, Andrews CE. Acute vitamin A intoxication. *South Med J* 1983;74:1012-4.
 25. James MB, Leonard JC, Fraser JJ Jr, Stuenkel JH. Hypervitaminosis A: a case report. *Pediatrics* 1982;69:112-5.
 26. Wason S, Lovejoy FH Jr. Vitamin A toxicity. *Am J Dis Child* 1982;136:174(letter).
 27. Fumich RM, Essig GW. Hypervitaminosis A. Case report in an adolescent soccer player. *Am J Sports Med* 1983;11:34-7.
 28. Baadsgaard O, Thomsen NH. Chronic vitamin A intoxication. Portal hypertension without hepatic cirrhosis in a patient with chronic vitamin A intoxication. *Dan Med Bull* 1983;30:51-2.
 29. Forouhar F, Nadel MS, Gondos B. Hepatic pathology in vitamin A toxicity. *Ann Clin Lab Sci* 1984;14:304-10.
 30. White JM. Vitamin-A-induced anaemia. *Lancet* 1984;2:573(letter).
 31. Rosenberg HK, Berezin S, Heyman S, Witzleben C, Watkins JB. Pleural effusion and ascites: unusual presenting features in a pediatric patient with vitamin A intoxication. *Clin Pediatr (Phila)* 1982;21:435-40.
 32. Schurr D, Herbert J, Habibi E, Abrahamov A. Unusual presentation of vitamin A intoxication. *J Pediatr Gastroenterol Nutr* 1983;2:705-7.
 33. Bürgi W, Kaufmann H, Fehr HF, Muhlethaler JP. Chronische, letal verlaufende vitamin-A-vergiftung mit hamolytischer anämie. *Schweiz Med Wochen Schr* 1985;115:526-8.
 34. Silverman SH, Lecks HI. Protein-calorie deficiency and vitamin indiscretion in an atopic child who developed hypervitaminosis A. *Clin Pediatr (Phila)* 1982;21:172-4.
 35. Weber FL Jr, Mitchell GE Jr, Powell DE, Reiser BJ, Banwell JG. Reversible hepatotoxicity associated with hepatic vitamin A accumulation in a protein-deficient patient. *Gastroenterology* 1982;82:118-23.
 36. Hatoff DE, Gerler SL, Miyai K, Parker BA, Weiss JB. Hypervitaminosis A unmasked by acute viral hepatitis. *Gastroenterology* 1982;82:124-8.
 37. Ellis JK, Russell RM, Makrauer FL, Schaefer EJ. Increased risk for vitamin A toxicity in severe hypertriglyceridemia. *Ann Intern Med* 1986;105:877-99.
 38. Inkeles SB, Connor WE, Illingworth DR. Hepatic and dermatologic manifestations of chronic hypervitaminosis A in adults. Report of two cases. *Am J Med* 1986;80:491-6.
 39. Dubick MA, Rucker RB. Dietary supplements and health aids—a critical evaluation. Part 1—vitamins and minerals. *J Nutr Ed* 1983;15:47-53.
 40. Stewart ML, McDonald JT, Levy AS, Schucker RE, Henderson DP. Vitamin/mineral supplement use: a telephone survey of adults in the United States. *J Am Diet Assoc* 1985;85:1585-90.
 41. Smith FR, Goodman DS. Vitamin A transport in human vitamin A toxicity. *N Engl J Med* 1976;294:805-8.
 42. McLaren DS. Vitamin A deficiency and toxicity. In: *Nutrition reviews' present knowledge in nutrition*. 5th ed. Washington, DC: Nutrition Foundation, 1984:192-208.
 43. Walker A, Zimmerman MR, Leakey REF. A possible case of hypervitaminosis A in homo erectus. *Nature* 1982;296:248-50.
 44. Bernstein RE. Liver and hypervitaminosis. *N Engl J Med* 1984;311:604(letter).
 45. Nater JP, Doeglas HMG. Halibut liver poisoning in eleven fishermen. *Acta Derm Venereol (Stockh)* 1970;50:109-13.
 46. Rodahl K, Moore T. The vitamin A content and toxicity of bear and seal liver. *Biochem J* 1943;37:166-8.
 47. Marie J, Sée G. Acute hypervitaminosis A of the infant. *Am J Dis Child* 1953;87:731-6.
 48. Marinoni J, Panizon F. Sul cosiddetto idrocefalo acuto da vitamina A. *Acta Paediatr Lat (Parma)* 1954;7:309-17.

49. Furman KI. Acute hypervitaminosis A in an adult. *Am J Clin Nutr* 1973;26:575-7.
50. Goeckjan G, Goerz G, Poettgen W, Grabensee B, Herms W. Lebensbedrohliche komplikationen der hochdosierten vitamin-A-behandlung bei psoriasis. *Dtsch Med Wochenschr* 1972;97:1424-9.
51. Dicken CH. Elevation of blood triglyceride levels secondary to administration of vitamin A. *Arch Dermatol* 1981;117:189-90(letter).
52. Murray JC, Gilgor RS, Lazarus GS. Serum triglyceride elevation following high-dose vitamin A treatment for pityriasis rubra pilaris. *Arch Dermatol* 1983;119:675-6.
53. Wald NJ, Cuckle HS, Barlow RD, et al. The effect of vitamin A supplementation on serum retinol and retinol binding protein levels. *Cancer Lett* 1985;29:203-13.
54. Kinley LJ, Krause RF. Influence of vitamin A on cholesterol blood levels. *Proc Soc Biol Med* 1959;102:353-5.
55. Dubin WB, Hazen BM. Relation of keratosis seborrheica and keratosis senilis to vitamin A deficiency. *Arch Dermatol Syphilol* 1948;57:178-83.
56. Van Bruggen JT, Straumfjord JV. High vitamin A intake and blood levels of cholesterol, phospholipids, carotene, and vitamins C, A, and E. *J Lab Clin Med* 1948;33:67-74.
57. Koerner WF, Voelml J. New aspects of the tolerance of retinol in humans. *Int J Vitam Nutr Res* 1975;45:363-72.
58. Farrington K, Miller P, Varghese Z, Bailod RA, Moorhead JF. Vitamin A toxicity and hypercalcaemia in chronic renal failure. *Br Med J* 1981;282:1999-2002.
59. Blumberg A, Hancs A, Sander G. Vitamin nutrition in patients on continuous ambulatory peritoneal dialysis (CAPD). *Clin Nephrol* 1983;20:244-50.
60. Ono K. Hypervitaminosis A toxicity in regular hemodialysis patients. *Trans Am Soc Artif Intern Organs* 1984;30:40-3.
61. Leo MA, Lieber CS. Hepatic fibrosis after long-term administration of ethanol and moderate vitamin A supplementation in the rat. *Hepatology* 1983;3:1-11.
62. Arnrich L. Toxic effects of megadoses of fat-soluble vitamins. In: Hathcock JN, Coon J, eds. *Nutrition and drug interrelations*. New York: Academic Press, 1978:751-71.
63. Glauert AM, Daniel MR, Lucy JA, Dingle JT. Studies on the mode of action of excess of vitamin A. VII Changes in the fine structure of erythrocytes during haemolysis by vitamin A. *J Cell Biol* 1963;17:111-21.
64. Lucy JA, Dingle JT. Fat-soluble vitamins and biological membranes. *Nature* 1964;204:156-60.
65. Soliman MK. Vitamin-A-uberdosierung. I Mögliche teratogene wirkungen. *Int Z Vitam Ernahrungsforsch [Beih]* 1972;42:389-93.
66. Krause RF. Liver lipids in a case of hypervitaminosis A. *Am J Clin Nutr* 1965;16:455-7.
67. Leitner ZA, Moore T, Sharman IM. Fatal self-medication with retinol and carrot juice. *Proc Nutr Soc* 1975;34:44A-5A.
68. Sharman IM. Hypercarotenaemia. *Br Med J* 1985a;290:95-6.
69. Sincclair H. Hypercarotenaemia. *Br Med J* 1985;290:561(letter).
70. Sharman IM. Hypercarotenaemia. *Br Med J* 1985b;290:561(letter).
71. Anonymous. α -Tocopherol influences tissue levels of vitamin A and its esters. *Nutr Rev* 1985;43:55-6.
72. Willett WC, Stampfer MJ, Underwood BA, Taylor JO, Hennekens CH. Vitamins A, E, and carotene: effects of supplementation on their plasma levels. *Am J Clin Nutr* 1983;38:559-66.
73. Hruban Z, Russell RM, Boyer JL, Glagov S, Bagheri SA. Ultrastructural changes in livers of two patients with hypervitaminosis A. *Am J Pathol* 1974;76:451-68.
74. Russell RM, Boyer JL, Bagheri SA, Hruban Z. Hepatic injury from chronic hypervitaminosis resulting in portal hypertension and ascites. *N Engl J Med* 1974;291:435-40.
75. National Research Council. *Nutrient requirements of laboratory animals*, 3rd ed. Washington, DC: National Academy Sciences, 1978.
76. Hutchings DE, Gibbon J, Kaufman MA. Maternal vitamin excess during the early fetal period: effects on learning and development in the offspring. *Dev Psychobiol* 1973;6:445-7.
77. Hutchings DE, Gaston J. The effects of vitamin A excess administered during the mid-fetal period on learning and development in rat offspring. *Dev Psychobiol* 1974;7:225-33.
78. Vorhees CV, Butcher RE. Behavioural teratogenicity. In: Snell ED, ed. *Developmental toxicology*. London: Croom Helm Ltd. Press, 1982:247-98.
79. Hutchings DE. Behavioral teratology: a new frontier neurobehavioral research. In: Johnson EM, Kochhar DM, ed. *Handbook of experimental pharmacology*. Vol 65. Berlin: Springer-Verlag, 1983:207-15.
80. Kamm JJ, Ashenfelter KO, Ehmann CW. Preclinical and clinical toxicology of selected retinoids. In: Sporn MB, Roberts A, Goodman DS, eds. *The retinoids*. Vol 2. New York: Academic Press, 1984:287-326.
81. Willhite CC. Dose-response relationships of retinol in production of the Arnold-Chiari malformation. *Toxicol Lett* 1984;20:257-62.
82. Cohan SQ. Congenital anomalies in the rat produced by excessive intake of vitamin A during pregnancy. *Pediatr* 1954;13:556-67.
83. Piotti G, Scorta A. Ipervitaminosi a gravida e malformazioni neonatali dell'apparato urinario. *Minerva Ginecol* 1965;8:1103-8.
84. Bernhardt IB, Dorsey DJ. Hypervitaminosis A and congenital renal anomalies in a human infant. *Obstet Gynecol* 1974;4:750-5.
85. Stänge L, Carlstrom K, Eriksson M. Hypervitaminosis A in early human pregnancy and malformations of the central nervous system. *Acta Obstet Gynecol Scand* 1978;57:289-91.
86. Von Lennep E, El Khazen N, DePierreux G, Amy JJ, Rodesch I, Van Regemorter N. A case of partial sirenomyelia and possible vitamin A teratogenesis. *Prenat Diagn* 1985;5:35-40.
87. Mounoud R-L, Klein D, Weber F. A propos d'un cas de syndrome de Goldenhar: intoxication aigue a la vitamine A chez la mere pendant la grossesse. *J Genet Hum* 1975;23:135-54.
88. Rosa FW, Wilk AL, Kelsey FO. Teratogen update: vitamin A congeners. *Teratology* 1986;33:355-64.
89. Pereira SM, Begum A. Vitamin A deficiency in Indian children. *World Rev Nutr Diet* 1976;24:192-216.
90. Hrubetz MC, Deuel HJ Jr, Hanley BJ. Studies on carotenoid metabolism. V The effect of a high vitamin A intake on the composition of human milk. *J Nutr* 1945;29:245-54.
91. Bound JP. Spina bifida and vitamins. *Br Med J* 1983;286:147(letter).
92. Smithells RW. Spina bifida and vitamins. *Br Med J* 1983;286:388-9(letter).
93. Read AP, Harris R. Spina bifida and vitamins. *Br Med J* 1983;286:560-1(letter).
94. Smithells RW, Sheppard S, Schorah CJ, et al. Possible prevention of neural-tube defects by periconceptional vitamin supplementation. *Lancet* 1980;2:339-40.
95. Conway H. Effect of supplemental vitamin therapy on the

- limitation of incidence of cleft lip and cleft palate in humans
Plast Reconstr Surg 1958;22:450-3.
96. Underwood BA. The safe use of vitamin A by women during the reproductive years. A report of the International Vitamin A Consultative Group. Washington, DC: Nutrition Foundation, 1986.
 97. Carroll MD, Abraham S, Dresser CM. Dietary intake source data: United States, 1976-80. Washington, DC: US Government Printing Office, 1983. (Vital and health statistics series 11 231. [DHHS publication (PHS) 83-1681].)
 98. Huestad VA, Gutcher GR, Anderson SA, Zachman RD. Relationship of vitamin A (retinol) status to lung disease in the preterm infant. *J Pediatr* 1984;105:610-5.
 99. Chytil F. Vitamin A and lung development. *Pediatr Pulmonol* 1985;1(suppl):115-7.
 100. Shenai JP, Chytil F, Stahlman MT. Vitamin A status of neonates with bronchopulmonary dysplasia. *Pediatr Res* 1985;19:1185-8.
 101. Schardein JL. Chemically induced birth defects. New York: Marcel Dekker, Inc, 1983;704-9.
 102. Sarna V. Maternal vitamin A deficiency and fetal microcephaly and anophthalmia. *Obstet Gynecol* 1959;13:299-301.
 103. Lamba PA, Sood NN. Congenital microphthalmus and colobomata in maternal vitamin A deficiency. *J Pediatr Ophthalmol Strabismus* 1968;115-7.
 104. Kemmann E, Pasquale SA, Skaf R. Amenorrhea associated with carotenemia. *JAMA* 1983;249:926-9.
 105. Mathews-Roth MM. Amenorrhea associated with carotenemia. *JAMA* 1983;250:731(letter).

49. Furman KI. Acute hypervitaminosis A in an adult. *Am J Clin Nutr* 1973;26:575-7.
50. Goeckenjan G, Goerz G, Poetgen W, Grabensee B, Herms W. Lebensbedrohliche komplikationen der hochdosierten vitamin-A-behandlung bei psoriasis. *Dtsch Med Wochenschr* 1972;97:1424-9.
51. Dicken CH. Elevation of blood triglyceride levels secondary to administration of vitamin A. *Arch Dermatol* 1981;117:189-90(letter).
52. Murray JC, Gilgor RS, Lazarus GS. Serum triglyceride elevation following high-dose vitamin A treatment for pityriasis rubra pilaris. *Arch Dermatol* 1983;119:673-6.
53. Wald NJ, Cuckle HS, Barlow RD, et al. The effect of vitamin A supplementation on serum retinol and retinol binding protein levels. *Cancer Lett* 1985;29:203-13.
54. Kintley LJ, Krause RF. Influence of vitamin A on cholesterol blood levels. *Proc Soc Biol Med* 1959;102:353-5.
55. Dubin WB, Hazen BM. Relation of keratosis seborrheica and keratosis senilis to vitamin A deficiency. *Arch Dermatol Syphilol* 1948;57:178-83.
56. Van Bruggen JT, Straumfjord JV. High vitamin A intake and blood levels of cholesterol, phospholipids, carotene, and vitamins C, A, and E. *J Lab Clin Med* 1948;33:67-74.
57. Koerner WF, Voellm J. New aspects of the tolerance of retinol in humans. *Int J Vitam Nutr Res* 1973;45:363-72.
58. Farrington K, Miller P, Varghese Z, Bailod RA, Moorhead JF. Vitamin A toxicity and hypercalcaemia in chronic renal failure. *Br Med J* 1981;282:1999-2002.
59. Blumberg A, Hanck A, Sander G. Vitamin nutrition in patients on continuous ambulatory peritoneal dialysis (CAPD). *Clin Nephrol* 1983;20:244-50.
60. Ono K. Hypervitaminosis A toxicity in regular hemodialysis patients. *Trans Am Soc Artif Intern Organs* 1984;30:40-3.
61. Leo MA, Lieber CS. Hepatic fibrosis after long-term administration of ethanol and moderate vitamin A supplementation in the rat. *Hepatology* 1983;3:1-11.
62. Arnrich L. Toxic effects of megadoses of fat-soluble vitamins. In: Hathcock JN, Coon J, eds. *Nutrition and drug interrelations*. New York: Academic Press, 1978:751-71.
63. Glauert AM, Daniel MR, Lucy JA, Dingle JT. Studies on the mode of action of excess of vitamin A. VII Changes in the fine structure of erythrocytes during haemolysis by vitamin A. *J Cell Biol* 1963;17:111-21.
64. Lucy JA, Dingle JT. Fat-soluble vitamins and biological membranes. *Nature* 1964;204:156-60.
65. Soliman MK. Vitamin-A-überdosierung. I Mögliche teratogene wirkungen. *Int Z Vitam Ernährungsforsch [Beih]* 1972;42:389-93.
66. Krause RF. Liver lipids in a case of hypervitaminosis A. *Am J Clin Nutr* 1965;16:455-7.
67. Leitner ZA, Moore T, Sharman IM. Fatal self-medication with retinol and carrot juice. *Proc Nutr Soc* 1975;34:44A-5A.
68. Sharman IM. Hypercarotenaemia. *Br Med J* 1985a;290:95-6.
69. Sinclair H. Hypercarotenaemia. *Br Med J* 1985;290:561(letter).
70. Sharman IM. Hypercarotenaemia. *Br Med J* 1985b;290:561(letter).
71. Anonymous. α -Tocopherol influences tissue levels of vitamin A and its esters. *Nutr Rev* 1985;43:55-6.
72. Willett WC, Stampfer MJ, Underwood BA, Taylor JO, Hennekens CH. Vitamins A, E, and carotene: effects of supplementation on their plasma levels. *Am J Clin Nutr* 1983;38:559-66.
73. Hruban Z, Russell RM, Boyer JL, Glagov S, Bagheri SA. Ultrastructural changes in livers of two patients with hypervitaminosis A. *Am J Pathol* 1974;76:451-68.
74. Russell RM, Boyer JL, Bagheri SA, Hruban Z. Hepatic injury from chronic hypervitaminosis resulting in portal hypertension and ascites. *N Engl J Med* 1974;291:435-40.
75. National Research Council. *Nutrient requirements of laboratory animals*, 3rd ed. Washington, DC: National Academy of Sciences, 1978.
76. Hutchings DE, Gibbon J, Kaufman MA. Maternal vitamin A excess during the early fetal period: effects on learning and development in the offspring. *Dev Psychobiol* 1973;6:445-7.
77. Hutchings DE, Gaston J. The effects of vitamin A excess administered during the mid-fetal period on learning and development in rat offspring. *Dev Psychobiol* 1974;7:225-33.
78. Vorhees CV, Butcher RE. Behavioural teratogenicity. In: Snell K, ed. *Developmental toxicology*. London: Croom Helm Ltd. Press, 1982:247-98.
79. Hutchings DE. Behavioral teratology: a new frontier in neurobehavioral research. In: Johnson EM, Kochhar DM, eds. *Handbook of experimental pharmacology*. Vol 65. Berlin: Springer-Verlag, 1983:207-15.
80. Kamm JJ, Ashenfelter KO, Ehmann CW. Preclinical and clinical toxicology of selected retinoids. In: Sporn MB, Roberts AB, Goodman DS, eds. *The retinoids*. Vol 2. New York: Academic Press, 1984:287-326.
81. Willhite CC. Dose-response relationships of retinol in production of the Arnold-Chiari malformation. *Toxicol Lett* 1984;20:257-62.
82. Cohlant SQ. Congenital anomalies in the rat produced by excessive intake of vitamin A during pregnancy. *Pediatrics* 1954;13:556-67.
83. Piliotti G, Scorta A. Ipervitaminosi a gravidica e malformazioni neonatali dell'apparato urinario. *Minerva Ginecol* 1965;87:1103-8.
84. Bernhardt IB, Dorsey DJ. Hypervitaminosis A and congenital renal anomalies in a human infant. *Obstet Gynecol* 1974;43:750-5.
85. Stänge L, Carlstrom K, Eriksson M. Hypervitaminosis A in early human pregnancy and malformations of the central nervous system. *Acta Obstet Gynecol Scand* 1978;57:289-91.
86. Von Lennep E, El Khazen N, DePierreux G, Amy JJ, Rodesch F, Van Regemorter N. A case of partial sirenomelia and possible vitamin A teratogenesis. *Prenat Diagn* 1985;5:35-40.
87. Mounoud R-L, Klein D, Weber F. A propos d'un cas de syndrome de Goldenhar: intoxication aigue a la vitamine A chez la mere pendant la grossesse. *J Genet Hum* 1975;23:135-54.
88. Rosa FW, Wilk AL, Kelsey FO. Teratogen update: vitamin A congeners. *Teratology* 1986;33:555-64.
89. Pereira SM, Begum A. Vitamin A deficiency in Indian children. *World Rev Nutr Diet* 1976;24:192-216.
90. Hrubetz MC, Deuel HJ Jr, Hanley BJ. Studies on carotenoid metabolism. V The effect of a high vitamin A intake on the composition of human milk. *J Nutr* 1945;29:245-54.
91. Bound JP. Spina bifida and vitamins. *Br Med J* 1983;286:147(letter).
92. Smithells RW. Spina bifida and vitamins. *Br Med J* 1983;286:388-9(letter).
93. Read AP, Harris R. Spina bifida and vitamins. *Br Med J* 1983;286:560-1(letter).
94. Smithells RW, Sheppard S, Schorah CJ, et al. Possible prevention of neural-tube defects by periconceptual vitamin supplementation. *Lancet* 1980;2:339-40.
95. Conway H. Effect of supplemental vitamin therapy on the

- limitation of incidence of cleft lip and cleft palate in humans. *Plast Reconstr Surg* 1958;22:450-3.
96. Underwood BA. The safe use of vitamin A by women during the reproductive years. A report of the International Vitamin A Consultative Group. Washington, DC: Nutrition Foundation, 1986.
 97. Carroll MD, Abraham S, Dresser CM. Dietary intake source data: United States, 1976-80. Washington, DC: US Government Printing Office, 1983. (Vital and health statistics series 11 231. [DHHS publication (PHS) 83-1681].)
 98. Husted VA, Gutcher GR, Anderson SA, Zachman RD. Relationship of vitamin A (retinol) status to lung disease in the preterm infant. *J Pediatr* 1984;105:610-5.
 99. Chytil F. Vitamin A and lung development. *Pediatr Pulmonol* 1985;1(suppl):115-7.
 100. Shenai JP, Chytil F, Stahlman MT. Vitamin A status of neonates with bronchopulmonary dysplasia. *Pediatr Res* 1985;19:1185-8.
 101. Schardein JL. Chemically induced birth defects. New York: Marcel Dekker, Inc, 1985:704-9.
 102. Sarma V. Maternal vitamin A deficiency and fetal microcephaly and anophthalmia. *Obstet Gynecol* 1959;13:299-301.
 103. Lamba PA, Sood NN. Congenital microphthalmus and colobomata in maternal vitamin A deficiency. *J Pediatr Ophthalmol Strabismus* 1968;115-7.
 104. Kemmann E, Pasquale SA, Skaf R. Amenorrhea associated with carotenemia. *JAMA* 1983;249:926-9.
 105. Mathews-Roth MM. Amenorrhea associated with carotenemia. *JAMA* 1983;250:731(letter).

Evaluation of Retinoids as Therapeutic Agents in Dermatology

Anita H. Lewin,^{1,3} Mary E. Bos,¹
F. Christopher Zusi,² Xina Nair,² Gary Whiting,²
Pamela Bouquin,² Geraldine Tetraut,² and
F. Ivy Carroll¹

Received May 11, 1993; accepted August 5, 1993

Evaluation of 13-*cis*-12-substituted analogues of retinoic acid in a series of dermatologic screens has revealed that structural modifications can lead to selectivity and specificity. An analogue, 11-*cis*,13-*cis*-12-hydroxymethylretinoic acid, δ -lactone, has been found to have good activity and to be devoid of topical and systemic toxicity.

KEY WORDS: retinoids; antihyperkeratinization; antihyperproliferation; antihyperactive sebaceous gland; hypervitaminosis A.

INTRODUCTION

Since vitamin A and its analogues, in particular retinoic acid, appear to be involved in the proliferation and differentiation of epithelial tissues, these compounds have been, and continue to be, used in the treatment of dermatological disorders such as acne, psoriasis, and hyperkeratosis (1). However, the known toxicity and teratogenicity of this class of compounds (1) have prompted a continuing search for retinoids with decreased undesirable side effects.

We have been interested in identifying retinoids effective topically against various cutaneous disorders. To this end we examined a group of 12-substituted retinoids (2–5). This report describes the synthesis and biological evaluation of 11 derivatives of 12-carboxyretinoic acid (1–11) and their comparison to retinoic acid (16) and its 13-*cis*-isomer (17).

MATERIALS AND METHODS

Chemistry

All syntheses were performed under dim red light. Melting points were determined on a Thomas Hoover capillary tube apparatus. Nuclear magnetic resonance (NMR) spectra were recorded on a Bruker WM-250 spectrometer using tetramethylsilane as internal standard. Thin-layer chromatography (TLC) was carried out on Whatman silica gel (SiO₂) 60 plates using 1:1 ethyl acetate (EtOAc) and hexane, with visualization by ultraviolet (UV) and/or iodine. High-performance liquid chromatography (HPLC) was carried out

using a system equipped with two M6000 Waters reciprocating pumps, a septumless Waters U6K injector, an automated gradient controller, and a Waters 490 UV detector in the maxplot mode recording at 20-nm intervals between 220 and 440 nm. The HPLC conditions are summarized in Table I. UV spectra were recorded using a Varian 2290 spectrophotometer, and mass spectrometry was performed in the electron impact (EI) mode on a MS9 spectrometer. Ethanol solutions of all the compounds were stable under dim red light (or in the dark) and under argon for at least 24 hr at room temperature and for at least 1 week when refrigerated (~10°C).

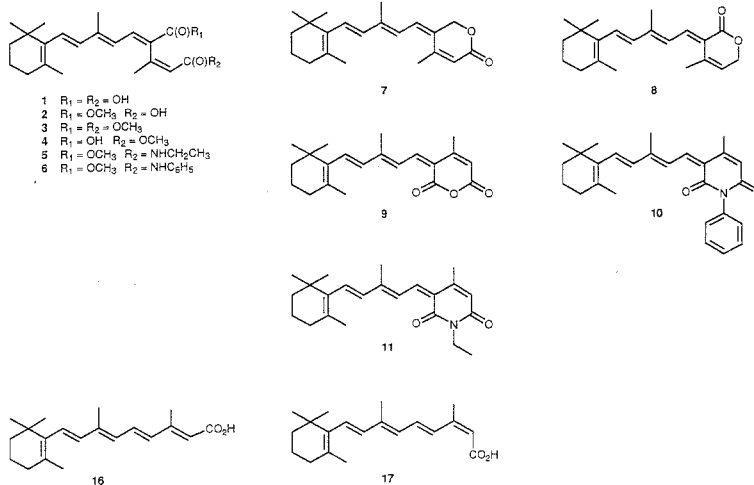
N-Ethyl-11-*cis*,13-*cis*-12-carbomethoxyretinoylamide (5). A solution of 11-*cis*,13-*cis*-12-carbomethoxyretinoic acid (2) (3) (8.000 g, 0.0223 mol) in freshly distilled toluene (75 mL) containing dry triethylamine (3.16 mL, 0.0223 mol) in a round-bottomed flask sealed with a septum equipped with a syringe needle was cooled to 0°C, and isobutyl chloroformate (2.90 mL, 0.023 mol) was added. Copious amounts of triethylamine hydrochloride fell out of solution. After stirring at 0°C for 35 min, ethylamine (1.46 mL, 0.023 mol) was added, resulting in an immediate pressure buildup. HPLC analysis using a C₁₈ Radial Pak cartridge and a linear gradient from 60% acetonitrile (CH₃CN)/40% [1% aq ammonium acetate (NH₄OAc)] to 100% CH₃CN over 10 min at 2 mL/min and monitoring at 350 nm showed the presence of unreacted starting material 2 and of a less polar substance. After storage overnight in the freezer, there was no apparent change in the product mixture. Removal of the volatiles under vacuum left a residue (10 g) which was subjected to low-pressure chromatography for purification. Using 300 g SiO₂ (470 mesh) in hexane, the column was eluted with a slow gradient of hexane to EtOAc; 250-mL fractions were collected. Fractions 25–27, which contained the more polar material in reasonably pure form were combined, concentrated, and refrigerated overnight to yield 3.35 g of crystals. The mother liquor was evaporated to give 2.42 g of impure product as an oil. The solid was dissolved in EtOAc by sonication at 45°C and hexane was added to induce crystallization. Filtration and drying afforded 2.62 g of a pale yellow powder which was 100% pure by HPLC. Additional crops were obtained from the mother liquors, for a total of 3.93 g (46% yield). The compound had mp 116°C and λ_{max} 339 nm [ε 26,000 methanol (CH₃OH)]. ¹H NMR (dioxane-d₆) δ: 0.98 (t, *J* = 7.2 Hz, 3, CH₂CH₃), 1.02 (s, 6, H-1a), 1.47 (m, 2, H-2 or H-3), 1.61 (m, 2, H-3 or H-2), 1.69 (s, 3, H-5a), 1.92 (s, 3, H-13a), 1.98 (m, 2, H-4), 2.01 (s, 3, H-9a), 3.12 (dq, *J* = 7.2 Hz, 5.5, CH₂CH₃), 5.79 (s, 1, H-14), 6.00 (d, *J* = 12.3 Hz, 1, H-10), 6.14 (d, *J* = 16.1 Hz, 1, H-8), 6.35 (d, *J* = 16.1 Hz, 1, H-7), 6.44 (t, *J* = 5.5 Hz, 1, NH), 7.43 (d, *J* = 12.3 Hz, 1, H-11); *m/z* calcd for C₂₄H₃₃NO₃, 385.2617; found, 385.2614.

N-Phenyl-11-*cis*,13-*cis*-12-carbomethoxyretinoylamide (6). In a manner analogous to the preparation of 5, the monoester 2 (5.99 g, 0.0167 mol) was treated with aniline (distilled from zinc dust, 0.974 mL, 0.0166 mol). Low-pressure chromatography on SiO₂ (330 g, 470 mesh) at 70 mL/min using a gradient of hexane to 20% EtOAc in hexane and collection of 150-mL fractions showed pure product in fractions 24–29 (2.55 g). Recrystallization from EtOAc gave

¹ Chemistry and Life Sciences, Research Triangle Institute, P.O. Box 12194, Research Triangle Park, North Carolina 27709.

² Dermatology Research, Bristol-Myers Squibb Company, Pharmaceutical Research and Development Division, Buffalo, New York 14213.

³ To whom correspondence should be addressed.



2.15 g (30%) pure material with mp 110–113°C. ¹H NMR (dioxane-d₆) δ: 1.01 (s, 6, H-1a), 1.47 (m, 2, H-2 or H-3), 1.59 (m, 2, H-3 or H-2), 1.67 (s, 3, H-5a), 1.99 (m, 2, H-4), 2.00 (s, 3, H-13a), 2.01 (s, 3, H-9a), 5.99 (s, 1, H-14), 6.01 (d, *J* = 11.1 Hz, 1, H-10), 6.14 (d, *J* = 16.0 Hz, 1, H-8), 6.36 (d, *J* = 16.0 Hz, 1, H-7), 6.97 (t, *J* = 7.5 Hz, 1, *p*-Ar), 7.21 (t, *J* = 7.6 Hz, 2, *m*-Ar), 7.43 (d, *J* = 12.0 Hz, 1, H-11), 7.49 (d, *J* = 8.0 Hz, 2, *o*-Ar), 8.39 (s, 1, NH); *m/z* calcd for C₂₈H₃₂NO₃, 433.2617; found, 433.2613.

3-methylglutaconic acid (6.00 g, 0.042 mol) and aniline (4.00 g, 0.043 mol) was heated under nitrogen (N₂) at 150°C for 40 min. Treatment of the resulting yellow resin with diethyl ether (Et₂O) led to the precipitation of a white solid which was washed copiously with Et₂O (150 mL) and dried to give 3.71 g (44%) of 14, mp 160–163°C [lit. (6), 164°C]. ¹H NMR (90 MHz, CD₃OD) δ: 2.1 (s, 3, CH₃), 3.5 (s, 2, CH₂), 6.1 (s, 1, CH), 7.0–7.6 (m, 5, Ar).

N-Ethyl-3-methylglutaconimide (15). Following the procedure reported for the *N*-phenyl analogue (6), a solution

Table 1. HPLC Conditions

Compound	Column	Eluant A	Eluant B	Program	Flow rate (ml/min)
1	C-18	H ₂ O	75% CH ₃ CN/25% (1% NH ₄ OAc in H ₂ O)	37 → 50% B over 4 min	2
2	C-18	H ₂ O	75% CH ₃ CN/25% (1% NH ₄ OAc in H ₂ O)	37 → 50% B over 4 min; hold 8 min; → 80% B over 1 min	2
3	C-18	H ₂ O	75% CH ₃ CN/25% (1% NH ₄ OAc in H ₂ O)	37 → 50% B over 4 min; hold 8 min; → 80% B over 1 min; hold 7 min; → 100% B over 1 min	2
4	SiO ₂ C-18	Hexane H ₂ O	Et ₂ O 75% CH ₃ CN/25% (1% NH ₄ OAc in H ₂ O)	Isocratic 5% B 37% → 50% B over 4 min; hold 8 min; → 80% B over 1 min	2 2
5	C-18 SiO ₂	CH ₃ CN MeOH	60% CH ₃ CN/40% (1% NH ₄ OAc in H ₂ O) 1:9 Et ₂ O/hexane	0–100% A over 10 min Isocratic 95% B	2 2
6	C-18	CH ₃ CN	60% CH ₃ CN/40% (1% NH ₄ OAc in H ₂ O)	0–100% A over 10 min	2
7	SiO ₂	Hexane	<i>t</i> -Butyl methyl ether	Isocratic 20% B	2
8	SiO ₂	MeOH	1:9 Et ₂ O/hexane	Isocratic 99% B	2
9	SiO ₂	MeOH	1:9 Et ₂ O/hexane	Isocratic 95% B	2
10	SiO ₂	Hexane	<i>t</i> -Butyl methyl ether	25 → 50% B over 5 min	2
11	SiO ₂	Hexane	<i>t</i> -Butyl methyl ether	25 → 50% B over 5 min	2

of ethylamine (13.0 mL, 0.04 mol) in toluene (15 mL) was added to a slurry of 3-methylglutaconic anhydride (5.0 g, 0.04 mol) in toluene at 0°C. Immediately after the addition, the ice bath was removed; some solid was still observed in the flask. After a few minutes, two distinct layers appeared. The addition funnel was replaced by a Dean-Stark trap and the reaction was brought to reflux. After 2 hr an additional portion (1 mL) of ethylamine was added to replace the material lost by evaporation. After an additional 45 min, the reaction appeared to be complete (TLC: SiO₂, 1:1 acetone/hexane). After dilution with EtOAc to dissolve the gummy solid that had formed, the reaction mixture was washed with 5% hydrochloric acid (HCl) (2 × 150 mL) and water (100 mL) and evaporated. The solid residue was treated with CH₃OH, resulting in a yellow solution and a white solid. The solid (3.69 g, 60%) had mp 133.8–135.8°C. ¹H NMR (dimethyl sulfoxide-d₆) showed the presence of keto-enol tautomers. The keto tautomer (70%) had δ: 1.02 (t, *J* = 7 Hz, 3, CH₂CH₃), 1.93 (s, 3, CH₃), 3.47 (s, 2, CH₂), 3.71 (q, *J* = 7 Hz, 2, CH₂CH₂), 5.99 (s, 1, CH). The enol form (30%) had δ: 1.11 (t, *J* = 7 Hz, 3, CH₂CH₃), 2.02 (s, 3, CH₃), 3.95 (q, *J* = 7 Hz, 2, CH₂CH₂), 5.53 (s, 1, CH), 6.00 (s, 1, CH); *m/z* calcd for C₈H₁₁NO, 153.0790; found, 153.0792.

N-Phenyl-13-cis-12-carboxyretinimide (10). To an ice-cooled solution of *N*-phenyl-3-methylglutaconimide (14) (6.02 g, 0.03 mol) in dry tetrahydrofuran (THF) (25 mL) under argon was added, through a septum, *trans*-β-ionylidene-acetaldehyde (13) (6.5 g, 0.03 mol) in dry THF (30 mL), followed by the dropwise addition of pyridine (0.57 mL). The ice bath was removed and TLC (SiO₂, 1:1 EtOAc/hexane) after 15 min showed the formation of product. Continued monitoring showed no change after an additional 40 min so the reaction mixture was placed in a warm water bath and 1 mL pyridine was added. After 5 hr, starting material was still observed but the reaction was worked up by twofold dilution with Et₂O, washing with 1 *N* HCl (2 × 50 mL), washing with water, and drying over sodium sulfate (Na₂SO₄). After removal of the drying agent, the solution was evaporated to leave a gum. This material was chromatographed on SiO₂, eluting with 5% *n*-butyl methyl ether in hexane to remove unreacted starting materials. The fractions containing fast-eluting material (TLC) were combined and evaporated. The dark oil which resulted was dissolved in hexane and the solution was refrigerated overnight. The solid which was formed appeared to consist mainly of one component. It was recrystallized from hexane/EtOAc to give 10 as a light powder, mp 115°C and λ_{max} 434.5 nm (ε 40,000, CH₃OH). ¹H NMR (dioxane-d₆) δ: 1.05 (s, 6, H-1a), 1.48 (m, 2, H-2 or H-3), 1.60 (m, 2, H-3 or H-2), 1.73 (s, 3, H-5a), 2.00 (m, 2, H-4), 2.15 (s, 3, H-9a), 2.25 (s, 3, H-13a), 6.12 (s, 1, H-14), 6.41 (d, *J* = 16.0 Hz, 1, H-8), 6.63 (d, *J* = 16.0 Hz, 1, H-7), 7.10 (d, *J* = 6.5 Hz, 2, *o*-Ar), 7.38 (m, 3, *m*-, *p*-Ar), 7.58 (d, *J* = 12.3 Hz, 1, H-10), 7.95 (d, *J* = 12.4 Hz, 1, H-11); *m/z* calcd for C₂₇H₃₁NO₂, 401.2355; found, 401.2353.

N-Ethyl-13-cis-12-carboxyretinimide (11). The procedure described for 10 was followed starting with *N*-ethyl-3-methylglutaconimide (15) (3.69 g, 0.024 mol), *trans*-β-ionylideneacetaldehyde (13) (5.25 g, 0.024 mol), and pyridine (0.51 mL). After 4 days, during which 1 mL additional pyridine was added, the reaction was worked up by twofold dilution with Et₂O, washing with sat. sodium carbonate

(Na₂CO₃) (emulsion), 1 *N* HCl (2 × 50 mL), and water, and drying over Na₂SO₄. After removal of the drying agent, the solution was evaporated to leave a sludge. This material was azeotroped twice with cyclohexane to remove any water, leaving an oil which was dissolved in EtOAc with a small amount of hexane and left in the freezer overnight. The resulting crystals appeared pure by TLC and HPLC and had mp 101°C and λ_{max} 429 nm (ε 28,000, CH₃OH). ¹H NMR (dioxane-d₆) δ: 1.07 (s, 6, H-1a), 1.08 (t, *J* = 7.0 Hz, 3, CH₂CH₃), 1.50 (m, 2, H-2 or H-3), 1.66 (m, 2, H-2 or H-3), 1.77 (s, 3, H-5a), 2.07 (m, 2, H-4), 2.14 (s, 3, H-9a), 2.17 (s, 3, H-13a), 3.90 (q, *J* = 7.0 Hz, 2, CH₂CH₂), 5.99 (s, 1, H-14), 6.46 (d, *J* = 16.1 Hz, 1, H-8), 6.64 (d, *J* = 16.1 Hz, 1, H-7), 7.50 (d, *J* = 12.2 Hz, 1, H-10), 8.02 (d, *J* = 12.2 Hz, 1, H-11); *m/z* calcd for C₂₃H₂₇NO₂, 353.2355; found, 353.2352.

Biology

Animals. Nine- to 14-week-old female hairless rhino mice (hr^{hr}) were purchased from the Skin and Cancer Hospital, Temple University Health Sciences Center (Philadelphia, PA). Female hairless mice (HRS/J), age 6 to 8 weeks, were purchased from Jackson Laboratories (Bar Harbor, ME). Golden Syrian male hamsters, age 10 weeks, were purchased from Charles River Labs (Lakeview, NJ). Female albino CD-1 mice, 5 to 6 weeks of age, were purchased from Charles River Breeding Laboratories (Wilmington, MA). Male New Zealand white rabbits, 10 to 12 weeks of age, were purchased from Beckens Farm (Sanborn, NY). Male albino Harley guinea pigs weighing 350–400 g were purchased from Elm Hill Breeding Laboratory (Chelmsford, MA).

Animals were housed in accordance with the National Institutes of Health guidelines (U.S. Department of Health and Human Services, 1985). Animals had free access to food and water. The quarantine period was at least 7 days, except for hairless mice, for which it was at least 6 days.

Test Materials. *Trans*- and 13-*cis* retinoid acids were obtained from the Eastman Kodak Company (Rochester, NY); 12-*O*-tetradecanoyl-phorbol-13-acetate (TPA) and L-[¹⁴C]ornithine hydrochloride (sp act, 57 mCi/mmol) were purchased, respectively, from Sigma Chemical Company (St. Louis, MO) and Amersham (Arlington Heights, IL). Retinoid solutions in ethanol were prepared weekly and stored in amber vials under refrigeration. The vials were topped with argon gas to retard oxidation.

Retinoid Treatments. Retinoids were applied topically in an ethanol vehicle in all experiments unless otherwise indicated. The retinoid solutions were applied evenly to the dorsal skin of the animals at a dose of 2 μg/cm². All of the procedures were under yellow light to minimize photooxidation of the retinoids. During treatment, all animals were housed individually.

Rhino Mouse Utricle Reduction Model. The test solutions were applied to the dorsal skin of each mouse once daily, 5 days/week, for 4 weeks. Intraperitoneal (ip) administration was made once daily, 5 days/week, for 2 weeks.

Two days after the final topical or ip treatment, the mice were sacrificed by carbon dioxide (CO₂) gas. Utricle diameter of rhino mouse skin was assessed in horizontal epidermal sheets (7). At sacrifice, a ¼-in.-diameter circular area of

the dorsal skin was removed by arch punch and bisected. The epidermal sheet from one-half of the biopsy was separated from the dermis after incubation of skin in 0.5% acetic acid for 10 to 20 hr at 4°C. These epidermal sheets were fixed in formalin, dehydrated with ethanol, and cleared with xylene.

To assess utricle diameter, each epidermal sheet was placed on a glass slide in a few drops of xylene. The diameter of 40 utricles was measured in each epidermal specimen with an image analyzer (Image Measure, Microscience, Federal Way, WA). The data are expressed as percentage reduction of mean utricle diameter relative to vehicle control.

The other half of the biopsy was placed in 10% buffered formalin immediately after sacrifice and was processed for preparation of H&E-stained, 5- μ m-thick vertical sections.

Hamster Flank Test. The hair over the region of the mature flank organs of Golden Syrian male hamsters was close clipped as needed to expose the region for topical treatment and evaluation.

The flank organs of each hamster were treated topically once daily, 7 days/week, for 3 weeks with 20 μ l of either acetone or retinoids in acetone. One day following the last treatment, the animals were sacrificed with CO₂ gas, and a 5/16-in. punch biopsy of each flank organ was taken from the center of the organ, weighed, and fixed in 10% buffered formalin for histological evaluation. The sections were evaluated for sebaceous gland size and activity as determined by the presence of lipid content of the glands (8).

Epidermal Ornithine Decarboxylase (ODC) Activity in Hairless Mice. Retinoids (0.1 mL) in acetone were applied topically to the dorsal skin of hairless mice 1 hr before topical application of 17 nmol of TPA. Mice were sacrificed by CO₂ gas inhalation 4 hr after treatment with TPA and epidermal ODC activity was measured as described previously (9). ODC activity was determined by the measurement of release of ¹⁴CO₂ from L-[¹⁴C]ornithine (results expressed as CO₂ release per milligram of protein per hour) incubated with the epidermal samples.

Hypervitaminosis A (HVA) in CD-1 Mice. HVA signs in CD-1 mice were evaluated after ip administration of retinoids. Retinoids were suspended in peanut oil and injected at 8 mL/kg, once daily, 5 days/week, for 2 consecutive weeks.

The severity of the toxicity signs was evaluated (10) on a 0 to 4 scale (Table II). Mice were graded daily during treatment using the criteria given in Table II. At the end of the experiment, an animal was defined as having HVA syndrome when the addition of the grades from all four of the individually graded signs totaled at least 3.0.

On the third day after the last treatment, mice were sacrificed and necropsy performed. Portions of the major organs including skin, sternum, and hindlimbs were placed in 10% buffered formalin for histopathological examination.

Repeat Application Skin Irritation in Rabbit and Guinea Pig. The hair of rabbits or guinea pigs was clipped closely at four sites on the back with an electric hair clipper. Each site was a 2 \times 2-cm square.

The retinoids in 0.2 mL of ethanol were applied once daily for 14 or 28 days. Each day before applying drug solutions, the degree of erythema, scaling, and edemas was assessed visually using the Draize 0 to 4 grading method (11). The results were also expressed as average daily Draize

Table II. HVA Grading System

Sign and degree of severity	Grade
Loss of body weight	
1 g	0
1-3 g	1
4-6 g	2
7-9 g	3
>10 g	4
Skin scaling and hair loss	
None	0
Slight	1
Moderate	2
Severe	3
Very severe	4
Number of bone fractures in extremities	
0	0
1	1
2	2
3	3
4	4

scores to allow statistical comparisons of the treatments. The average daily Draize scores were calculated by taking cumulative scores over 14 or 28 days for each parameter and dividing by 14 or 28.

On day 15 or 29, animals were sacrificed by CO₂ inhalation, treated sites were excised, and a strip was placed in 10% buffered formalin. These were processed, stained with H&E, and evaluated for microscopic signs of inflammation.

Statistics

Data were analyzed for significant differences by analysis of variance and Tukey's Studentized range test for multiple comparisons (12).

RESULTS

Chemistry

Compounds 1-4 and 7-9 were prepared as described previously (2-4). The amides 5 and 6 were prepared from the activated ester 12, which was obtained by treatment of the monomethyl ester 2 with isobutyl chloroformate in the presence of triethylamine (Fig. 1). Treatment of the ester 12 with ethylamine and aniline gave the amido esters 5 and 6, respectively. The imides 10 and 11 were prepared by condensation of *trans*- β -ionylideneacetaldehyde (13) with *N*-phenyl and *N*-ethyl-3-methylglutaconimide (14 and 15, respectively) (Figs. 2 and 3).

The configurations of the retinoid amides (5, and 6) and imides (10 and 11) were determined by their ¹H NMR spectra. The 11-*cis*,13-*cis* configuration of 5 and 6 was confirmed by the close resemblance of their ¹H NMR parameters to those of other 11-*cis*,13-*cis*-12-carboxyretinoic acids (2-4). Similarly, assignment of the 13-*cis* configuration to 10 and 11 was based primarily on the 1.5-ppm downfield shift of H-10. We showed previously that the downfield shift of H-10 was associated with the anisotropy of the coplanar 12 α -carboxyl group in the 13-*cis* configuration (2,3). In agreement with previous observations on 13-*cis*-12-carboxyretinoic anhy-

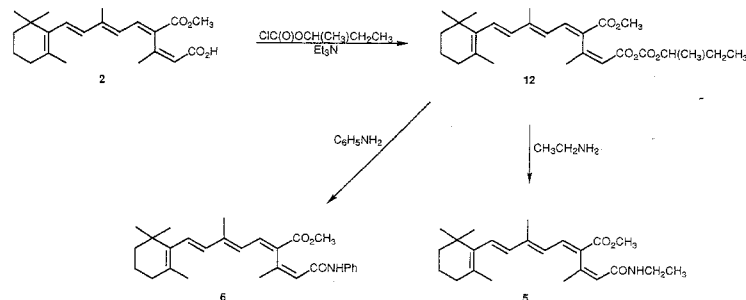


Fig. 1.

dride (3), the imides 10 and 11 were both light sensitive, producing isomeric imides. These transformations were reversible, the initial imide being reformed after several hours in the dark.

Biological

The compounds were evaluated topically for activity against hyperkeratinization (rhino mouse model) (7,13-15), hyperactive sebaceous glands (hamster flank/ear model), and epidermal ODC activity (16-19). Retinoids that were active in these models were evaluated further for local irritation by repetitive application and for systemic toxicity measured by symptoms of HVA.

Rhino Mouse Test. Utricles are hair-derived, keratin-filled, superficial cysts in skin resembling human comedones. Utricle diameter of rhino mouse skin was assessed in whole mounts of the horizontal epidermal sheets (7); the

results are shown in Table III. Compounds that reduced the size of the utricles also showed reductions in the size of surface cysts or pseudocomedones. Histological evaluation also showed that these compounds stimulated an increase in epidermal thickness, especially of the granular layer. Only the lactones 6 and 7 and the 12-carbomethoxyaniide 8 had any activity in this assay. The lactone 7 had activity comparable to that of *trans*- and 13-*cis*-retinoic acid (16 and 17, respectively). Interestingly, although both 16 and 17 exhibited a 10 to 40% reduction in utricles on the control-treated contralateral site, compound 7 showed little or no effect on the contralateral side.

Hamster Flank Test. The effects of subcutaneous administration of compounds 1-11 were compared to those of *trans*- and 13-*cis*-retinoic acid (16 and 17, respectively) on suppression of the development of the male Golden Syrian hamster flank organ sebaceous gland in terms of size and activity, as determined by histopathological examination of

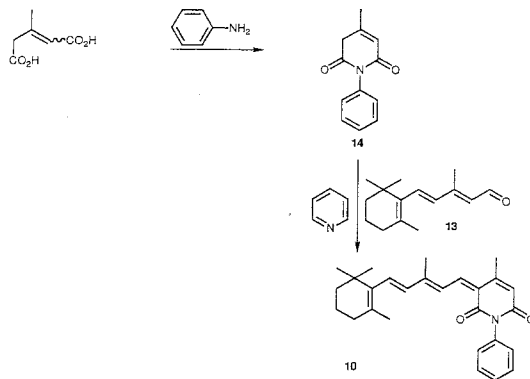


Fig. 2.

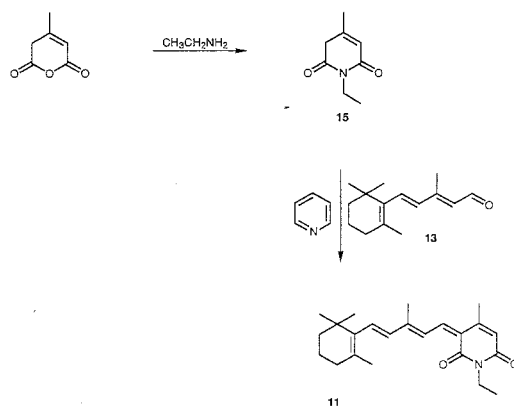


Fig. 3.

the glands (8). For the controls, 13-*cis*-retinoic acid (17) at doses of 5 to 150 mg/kg reduced the size and activity of the sebaceous gland; *trans*-retinoic acid (16) at 10 and 50 mg/kg reduced the size and lipid content of the gland. At doses higher than 50 mg/kg, toxic effects such as weight loss, anal bleeding, and lethargy were noted. In addition, a high inci-

dence of mortality (30–40%) was observed for the 13-*cis*-retinoic acid (17)-treated (75 mg/kg) animals as well as for the animals treated (50 mg/kg) with *trans*-retinoic acid (16) (100%). Compounds 1–11 showed no activity in this screen.

Epidermal ODC Activity in Hairless Mice. The inhibitory effect of compounds 1–11 against ODC activity, which is a measure of epidermal hyperplasia, was evaluated in TPA-stimulated hairless mouse skin by the topical application of an acetone solution 1 hr before topical application of TPA. After 4 hrs the animals were sacrificed and ODC activity was determined by the measurement of carbon-14-labeled CO₂ released upon incubation of separated epidermal samples with carbon-14-labeled ornithine. Only four of the compounds tested showed any inhibition (Table III); compound 7 had activity close to that of 13-*cis*-retinoic acid (17).

HVA Test. Only compound 7, which was quite active in both the hyperkeratotic activity and the ODC activity screens, was tested for HVA. The following symptoms were graded on a 0–4 scale (10) (Table IV): weight loss, skin scaling, hair loss, bone fractures, and death. Animals were defined as having HVA syndrome when the addition of the grades from the individually graded signs totaled 3.0 or more.

All animals on 13-*cis*-retinoic acid (17) began to show overt signs of toxicity (unkempt appearance with oily or greasy hair, decreased spontaneous activity) by the fifth dose. During the second week 13-*cis*-retinoic acid (17)-treated groups showed definite hair and body weight losses. With the 400 mg/kg dose, four of nine mice were found dead on day 7 and the remainder had died by day 9. In the group dosed with 200 mg/kg of 13-*cis*-retinoic acid (17), 100% mortality was observed after 14 days. Treatment with *trans*-retinoic acid (16) at 100 mg/kg showed marked body weight loss with a 70% mortality rate. In contrast, animals treated with the lactone 7 could not be differentiated from the vehicle-treated or from the untreated control groups.

Table III. Effect of Topically Applied Retinoids on hyperkeratotic Activity^a and TPA-Induced ODC Activity^b in the Epidermis

Compound	% inhibition of	
	Utricles at 0.1% ^c	ODC activity ^d
1	0	0
2	0	37
3	0	0
4	0	16
5	0	0
6	15	0
7	50	71
8	10	0
9	0	20
10	0	0
11	0	0
16	55–70	97–99
17	33–51	84

^a Evaluated by the reduction in size of the utricles in the rhino mouse.

^b In hairless mice.

^c Topical application to rhino mouse skin (5–10 animals/group) daily for 4 weeks. Percentage reduction based on vehicle control.

^d Topical application of 50 nmol retinoid to hairless mouse skin (6 animals/group) 1 hr before 17 nmol TPA in acetone. Percentage inhibition based on acetone control.

Table IV. Hypervitaminosis A Test in Swiss Webster Mice: Comparison of the Effects of 13-*cis*-Retinoic Acid (17) and 11-*cis*,13-*cis*-12-Hydroxymethylretinoic Acid, δ -Lactone (7)

Treatment ^a	Dose (mg/kg)	(N)	Mean daily hypervitaminosis A grade \pm SD ^b										
			1	2	3	4	5	6	7	8	9	10	
Vehicle control	NA	(5)	0	0	0	0	0	0	0	0	0	0	0
Treated control	NA	(5)	0	0	0	0	0	0	0	0	0	0	0
17	400	(9)	0	0	0.6 \pm 0.5	1 \pm 0	2.6 \pm 0.5	3.7 \pm 1.0	7.1 \pm 4.7	8.1 \pm 4.6	12 \pm 0	12 \pm 0	12 \pm 0
17	200	(9)	0	0.1 \pm 0.3	0.1 \pm 0.3	0.6 \pm 0.5	2.0 \pm 0.5	2.8 \pm 0.7	3.1 \pm 0.6	3.4 \pm 0.5	3.7 \pm 0.7	4.3 \pm 0.8	4.3 \pm 0.8
7	200	(9)	0	0.1 \pm 0.3	0.2 \pm 0.4	0.4 \pm 0.5	0.1 \pm 0.3	0	0	0.1 \pm 0.3	0	0	0

^a All test material suspended in peanut oil and administered intraperitoneally once daily, 5 days/week, for 2 weeks. Peanut oil administered at 8 mL/kg.

^b Hypervitaminosis A = sum of symptom grades (body weight loss, skin scaling, hair loss), yielding at least 3. Each symptom graded on a 0-4 scale, and death graded as a maximum score of 12. (See Materials and Methods for more details.)

Skin Irritation Models. Skin irritation due to repeat skin application in rabbits and guinea pigs was evaluated for compound 7 compared to compounds 16 and 17 (Tables V and VI). Animals were observed daily during the four week treatment period and for one week thereafter. Test sites were assessed visually for signs of irritation and for scaling using the Draize (11) 0-4 grading method. Both *trans*- and 13-*cis*-retinoic acid caused moderate to severe erythema and scaling in rabbits which peaked around the second week and declined throughout the remaining weeks (Tables V and VI). No evidence of irritation was apparent at the untreated or the vehicle-treated sites. The two acids had equivalent edema and scaling scores but the *trans* acid showed slightly higher erythema scores. In guinea pigs the irritation reactions were delayed, peaking at week 3; less erythema was observed. Both scaling and erythema declined rapidly at week 4. Histological changes observed in rabbits and guinea pigs for both acids included a thickening of the epidermal layer to two to three times normal. Inflammatory infiltrate was present in skins, ranging from minimal to moderate, and was more severe in the application sites. This inflammatory response was accompanied by congestion and hemorrhage. In contrast, the lactone 7 caused minimal to slight erythema and scaling in rabbits and guinea pigs. This reaction peaked at the second or third week and then declined slowly. Epi-

dermal thickening to two to three times normal were also observed for 7, however, it was accompanied by very little or no inflammatory infiltration into the skin.

DISCUSSION

Retinoids are known to reduce the size of sebaceous glands as well as sebum secretion, making them attractive agents for the treatment of skin disorders. However, the mechanism involved remains unknown and since the effectiveness of only a small number of compounds has been reported, no conclusions about the relationship of structure to activity and/or toxicity can be drawn. Since 13-*cis*-retinoic acid (17) has a considerably higher therapeutic index than the isomeric *trans*-acid 16, we had undertaken the examination of a series of 13-*cis*-12-substituted retinoids. Among these were compounds constrained to 13-*cis*-stereochemistry by the incorporation of the 13,14 double bond in a six-membered ring.

The models used as tests for antihyperkeratinization (rhino mouse, topical), antihyperproliferation (ODC, topical), antihyperactive sebaceous gland activity (hamster flank organ, subcutaneous), HVA (ip), and repeat-application irritation (topical) were validated by the results obtained with *trans*- and 13-*cis*-retinoic acid (16 and 17, respectively).

Table V. Skin Irritation in Rabbits and Guinea Pigs: Erythema Resulting from Repeat Application of 13-*cis*-Retinoic Acid (17), *trans*-Retinoic Acid (16), and 11-*cis*,12-Hydroxymethylretinoic Acid, δ -Lactone (7)

Treatment ^a	Species (N)	Weekly mean cumulative erythema score \pm SD ^b				
		1	2	3	4	5
17	Rabbit (4)	15 \pm 3.1	24 \pm 1.6	14 \pm 2.6	12 \pm 3.4	9 \pm 2.3
16	Rabbit (4)	17 \pm 1.7	25 \pm 1.3	17 \pm 2.4	16 \pm 3.6	12 \pm 2.6
7	Rabbit (4)	8.9 \pm 1.5	12.2 \pm 4.4	8.1 \pm 3.0	9.0 \pm 4.0	2.2 \pm 1.8
17	Guinea pig (4)	1 \pm 1.3	8 \pm 3.6	17 \pm 2.8	16 \pm 2.9	8 \pm 0.7
16	Guinea pig (4)	2 \pm 1.8	10 \pm 4.5	16 \pm 3.7	17 \pm 3.1	10 \pm 2.3
7	Guinea pig (4)	0	0	4.0 \pm 2.7	8.0 \pm 1.5	0

^a Skin sites (4 \times 4 cm) of animals were treated with 0.2 mL/site of a 0.1% (w/v) solution, 7 days/week, for 4 weeks. Week 5 was a recovery week.

^b Scores were determined by daily grading of the treated site, on a scale of 0-4 erythema, according to the Draize scoring system: 0 = none, 1 = minimal, 2 = slight, 3 = moderate, and 4 = severe. Cumulative weekly scores were obtained and the mean was determined for each site. Maximum cumulative score = 28.

Table VI. Skin Irritation in Rabbits and Guinea Pigs: Scoring Resulting from Repeat Application of 13-*cis*-Retinoic Acid (17), *trans*-Retinoic Acid (16), and 11-*cis*-12-Hydroxymethylretinoic Acid, δ -lactone (7)

Treatment ^a	Species (N)	Weekly mean cumulative erythema score \pm SD ^b				
		1	2	3	4	5
17	Rabbit (4)	0.2 \pm 0.4	21.7 \pm 6.4	21.4 \pm 9.0	14.1 \pm 10.4	7.0 \pm 4.3
16		2.5 \pm 1.6	24.2 \pm 3.4	21.5 \pm 7.6	21.4 \pm 6.6	14.2 \pm 2.7
7		1.6 \pm 1.0	6.7 \pm 1.4	3.6 \pm 1.6	3.5 \pm 3.0	0
17	Guinea pig (4)	0	8.6 \pm 3.0	24.1 \pm 2.8	21.9 \pm 5.8	12.2 \pm 3.0
16		0	10.9 \pm 5.2	24.6 \pm 3.9	24.7 \pm 3.4	10.2 \pm 1.5
7		0	0	4.8 \pm 1.7	7.0 \pm 0	3.5 \pm 0.5

^a Skin sites (4 \times 4 cm) of animals were treated with 0.2 mL/site of a 0.1% (w/v) solution, 7 days/week, for 4 weeks. Week 5 was a recovery week.

^b Scores were determined by daily grading of the treated site, on a scale of 0-4: 0 = none, 1 = minimal, 2 = slight, 3 = moderate, and 4 = severe. Cumulative weekly scores were obtained and the mean was determined for each site. Maximum cumulative score = 28.

Thus, in agreement with reported results (20), *trans*-retinoic acid (16), with a mean ED₅₀ of 0.001%, is more potent than 13-*cis*-retinoic acid (17), with a mean ED₅₀ of 0.015%, in reducing the size of utricles in the rhino mouse test. As expected, both 16 and 17 showed activity in the hamster flank organ screen and in ODC inhibition. Similarly, symptoms of both HVA and skin irritation due to repeat applications appeared to be more severe with *trans*-retinoic acid (16) than with the 13-*cis* isomer (17), as expected (1).

Since retinoids 1-11 showed no activity in the flank organ test, the usefulness of this model as a screen for assessing retinoid effects on sebaceous gland size and activity may be questionable. However, it should be borne in mind that as a group, retinoids 1-11 showed little activity in the other assays as well. In fact, only one compound, the lactone 7, was active both in reducing the size of utricles and in inhibiting TPA-induced ODC. Thus, the lactone 8 and the anilide 6, which had some activity in utricles reduction, were devoid of activity in the inhibition of TPA-induced ODC. Conversely, the monomethyl esters 2 and 4 and the anhydride 9 exhibited some activity in ODC inhibition but had no effect on utricule reduction. Interestingly, although the monoesters 2 and 4 had activity, both the diacid 1 and the dimethyl ester 3 were completely inactive in both assays.

The results obtained with the lactone 7 were of particular interest. Although its activity was slightly less than that observed for either *trans*- or 13-*cis*-retinoic acid (16 and 17, respectively) in both utricule reduction and ODC inhibition, it exhibited no systemic toxicity when injected intraperitoneally (200 mg/kg) once daily for 2 weeks to Swiss Webster mice. It is also noteworthy that the apparent systemic effects elicited by 16 and 17 on the control-treated contralateral side in the rhino mouse test were absent in the animals treated with the lactone 7. Similarly, topical application for 4 weeks to rabbits or guinea pigs produced directionally less local irritation than either 16 or 17. These results suggest that it may be possible to separate the beneficial therapeutic effects of retinoids from their toxicity.

CONCLUSIONS

The activities of 12-substituted retinoic acid analogues in animal models suggests that structural modifications may

lead to selective activity. Specifically, (a) whereas both isomers of retinoic acid (16 and 17) reduced the size of hyperactive sebaceous glands, none of the 12-substituted analogues did; (b) some compounds active in utricule reduction (6 and 8) were inactive in the inhibition of TPA-induced ODC, while others (2, 4, 9) exhibited the opposite selectivity; and (c) an analogue (7) with good activity in both utricule reduction and ODC inhibition was devoid of topical and systemic toxicity.

ACKNOWLEDGMENT

The assistance of Mr. J. Wilson is gratefully acknowledged.

REFERENCES

1. L. Packer (ed.), *Methods in Enzymology*, Academic Press, San Diego, CA, 1990, Vol. 190.
2. A. H. Lewin, F. I. Carroll, and C. G. Moreland. 12-*s-cis*-a novel conformation of retinoids. *J. Am. Chem. Soc.* 103:6527-6529 (1981).
3. A. H. Lewin, M. G. Whaley, S. R. Parker, F. I. Carroll, and C. G. Moreland. 12-Carboxyretinoic acids. *Synthesis and structure*. *J. Org. Chem.* 47:1799-1807 (1982).
4. A. H. Lewin, D. H. Rector, S. R. Parker, M. C. Wani, and F. I. Carroll. Configurationally locked retinoids. 13-*cis*- δ -lactones of 12-carboxyretinol and 12-(hydroxymethyl)retinoic acid. *J. Org. Chem.* 48:222-227 (1983).
5. A. H. Lewin, D. R. Rector, S. R. Parker, M. C. Wani, and F. I. Carroll. Synthesis and characterization of *trans*-, 13-*cis*-, and 11-*cis*-, 13-*cis*-12-(hydroxymethyl)retinoids. *J. Org. Chem.* 49:649-652 (1984).
6. R. H. Wiley and C. L. De Silva. 2-Pyrones. XXII. β Methylglutamic acid, β -methylglutaramic acids and related diamides, pyridones and pyridazones. *J. Am. Chem. Soc.* 78:4683-4689 (1956).
7. J. A. Mezick, M. C. Bhatia, L. M. Shea, E. G. Thorne, and R. J. Capetola. Antiacne activity of retinoids in the rhino mouse. In H. I. Maibach and N. J. Lowe (eds.), *Models in Dermatology*, Basel, Switzerland, Karger, 1985, Vol. 2, pp. 59-63.
8. E. C. Gomez and P. Frost. Hamster flank organ: Relevance of studies with topically applied anti-androgens. In H. I. Maibach (ed.), *Animal Models in Dermatology. Relevance to Human Dermatopharmacology and Dermatotoxicology*, a symposium held at University of California Medical School in San Francisco, Churchill Livingstone, New York, 1975, pp. 190-202.
9. E. G. Astrup and J. E. Paulsen. Effect of retinoid acid pretreatment of 12-O-tetradecanoylphorbol-13-acetate-induced cell

- population kinetics and polyamine biosynthesis in hairless mouse epidermis. *Carcinogenesis* 3:313-320 (1982).
10. W. Bollag. Therapeutic effects of an aromatic retinoic acid analog on chemically induced skin papillomas and carcinomas of mice. *Eur. J. Cancer* 10:731-737 (1974).
 11. J. H. Draize, G. Woodard, and H. O. Calver. Methods for the study of irritation and toxicity of substances applied topically to the skin and mucous membranes. *J. Pharmacol.* 82:377-390 (1944).
 12. M. R. Stoline. Status of multiple comparisons: Simultaneous estimation of all pairwise comparison in one-way ANOVA designs. *Am. Stat.* 35:134-141 (1981).
 13. E. J. Van Scott. Experimental animal integumental models for screening potential dermatologic drugs. In W. Montagna, E. J. Van Scott, and R. Stoughton (eds.), *Pharmacology of the Skin*. Appleton-Century-Crofts, New York, 1972, pp. 523-523.
 14. L. H. Kligman and A. M. Kligman. The effect on rhino mouse skin of agents which influence keratinization and exfoliation. *J. Invest. Dermatol.* 73:354-358 (1979).
 15. R. E. Ashton, M. J. Connor, and N. J. Lowe. Histologic changes in the skin of the rhino mouse (hr^b/hr^b) induced by retinoids. *J. Invest. Dermatol.* 82:632-635 (1984).
 16. U. Lichti, E. Patterson, H. Hennings, and S. H. Yuspa. The tumor promoter 12-O-tetradecanoylphorbol-13-acetate induced ornithine decarboxylase in proliferating basal cells but not in differentiating cells from mouse epidermis. *J. Cell. Physiol.* 107:261-270 (1981).
 17. A. K. Verma and R. K. Boutwell. Vitamin A acid (retinoic acid), a potent inhibitor of 12-O-tetradecanoyl-phorbol-13-acetate-induced ornithine decarboxylase activity in mouse epidermis. *Cancer Res.* 37:2196-2201 (1977).
 18. J. Janne, H. Poso, and A. Raina. Polyamines in rapid growth and cancer. *Biochim. Biophys. Acta* 473:241-293 (1978).
 19. J. Breeding, M. Sakamoto, N. Lowe, and M. Phuvel. Epidermal ornithine decarboxylase and DNA synthesis activity following different stimuli in the hairless mouse. *Clin. Res.* 30:156A (1982).
 20. N. J. Lowe, M. J. Connor, R. Ashton, and M. Wortzman. Animal assays for anti psoriatic, retinoid and sun protective agents. *Br. J. Dermatol.* 111 (Suppl. 27):98-108 (1984).

PIBLOKTOQ (HYSTERIA) AND INUIT NUTRITION: POSSIBLE IMPLICATION OF HYPERVITAMINOSIS A*

DAVID LANDY

Professor of Anthropology, Department of Anthropology, University of Massachusetts,
 Boston, MA 02125, U.S.A.

Abstract—The hysterical reaction among Eskimo peoples known as *pibloktoq*, one of a group of aberrant behaviors occurring among Arctic and Circumarctic societies termed 'arctic hysterias', has been explained by a variety of theories: ecological, nutritional, biological-physiological, psychological-psychoanalytic, social structural and cultural. This study hypothesizes the possible implication of vitamin intoxication, namely, hypervitaminosis A, in the etiology of some cases of *pibloktoq*. Its biocultural approach implicates elements of several explanatory classes, which are not mutually exclusive.

Experimental and clinical studies of nonhumans and humans reveal somatic and behavioral effects of hypervitaminosis A which closely parallel many of the symptoms reported for Western patients diagnosed as hysterical and Inuit sufferers of *pibloktoq*. Eskimo nutrition provides abundant sources of vitamin A and lays the probable basis in some individuals for hypervitaminosis A through ingestion of livers, kidneys, and fat of arctic fish and mammals, where the vitamin often is stored in poisonous quantities. Possible connections between *pibloktoq* and hypervitaminosis A are explored.

A multifactorial framework may yield a more compelling model of some cases of *pibloktoq* than those that are mainly uncausal, since, among other things, the disturbance has been reported for males and females, adults and children, and dogs.

INTRODUCTION

For centuries Europeans exploring and trading in the Polar and Circumarctic regions have reported certain emotional aberrations among the indigenous populations. One cluster of these behavioral phenomena have come to be called 'arctic hysterias', and one type of explosive outburst has been termed *pibloktoq* among the Inuit (Eskimo) and by other names in Siberia and elsewhere [1-6]. While a number of theories have been proposed to explain the etiology and dynamics of *pibloktoq*, the present essay has been stimulated by a hypothesis advanced by Wallace [7] and Foulks [8] proposing a link with hypocalcemia. This study offers an alternative hypothesis: vitamin A intoxication (hypervitaminosis A) may be involved in some cases of *pibloktoq*.

*This is a substantial revision of an earlier paper presented in part in a symposium, "New Approaches to Culture-Bound Syndromes", at the International Congress of Anthropological and Ethnological Sciences, Vancouver, B.C., August 1983; and in part at the Society for the Study of Psychiatry and Culture, Newport, RI, October 1983. A number of colleagues in the United States and Canada either read an earlier draft or heard one of the preceding presentations, and generously offered their comments, compelling a rethinking and sharpening of many points. Not all suggestions and criticisms could be included here but will be dealt with subsequently. I am especially grateful to Abram Center, Edward Foulks, Milton M. R. Freeman, Lawrence S. Greene, Zachary Gussow, H. H. Draper, K. C. Hayes, Sol Katz, Michael Kenney, Arthur Kleinman, Setha Low, Fred A. Milan, Alan Morinis, Gretel H. Pelto, Alan Walker and Anthony F. C. Wallace.

Meanings of technical terms herein are based on interpretations of their use in sources referenced or on definitions in *Dorland's Illustrated Medical Dictionary* (Edited by Argy L. B. et al.), 23rd edition. W. B. Saunders, Philadelphia, 1960.

Although no existing explanation of *pibloktoq* has been completely satisfactory, there is potential merit in many, and the ultimate goal is to produce a multifactorial model along the lines suggested by Foulks [8] and Wallace [7, 9]. The staggering complexity of human behavior suggests that the principle of parsimony may not necessarily lead to a viable and cogent model for comprehending the arctic hysterias. When dealing with the bewildering array of factors enmeshed in any sample of human action, the simplest theory is not inevitably the most efficient.

Unlike certain other 'culture-bound' syndromes such as *windigo* among some Canadian Algonkian-speaking Indians, which may be factual or mythicized and fancified [10], *pibloktoq* has been reported by so many observers, and validated in the field by Foulks [8], that there can be scant skepticism regarding its actuality. The critical question for medical anthropology and transcultural psychiatry is how best to understand its etiology and significance in the cultural and ecological settings in which it occurs.

Explanations of 'theories' of the arctic hysterias may be grouped into six classes:

(1) *Ecological*: e.g. the long arctic days and nights; the extreme cold; the barrenness, bleakness and silence of the polar wastes; intense brilliance of the sunlight due to refraction and reflection of the sun's rays against the endless snow and ice; interrupted circadian rhythms.

(2) *Nutritional*: e.g. calcium deficiency; vitamin D₃ deficiency; malnutrition; undernutrition (starvation).

(3) *Biological-physiological*: e.g. hyperventilation; sudden pain; physical shock; chorea; epilepsy; a 'racial' or hereditary predisposition to the latter two diseases; *otitis media*; syphilitic sequelae.

(4) *Psychological-psychoanalytic*: e.g. a seeking of attention; a cry for help; an expression of repressed sexuality, traumatic fright; an unexpected experience;

social contagion (group panic); startle reaction; suggestion; hypnotic suggestion; mimicry.

(5) *Social structural*: e.g. male-female roles; male dominance/female subordination.

(6) *Cultural*: e.g. religio-magical beliefs and practices that conduce toward behavioral paroxysms and hysterical outbursts, as in shamanism; crowded, extended confinement in snow houses and huts during long winters; effects of Eskimo socialization and modal personality.

These factors are not mutually exclusive, and two or several may transact with each other. This is not the place for a comprehensive assessment and critique of these theories, but a preliminary appraisal appears elsewhere [11, pp. 283-300] and the writer hopes, to report more fully in the future.

Wallace's summary description of *pibloktoq* is concise:

1. *Prodrome*: In some cases a period of hours or days is reported during which the victim seems to be mildly irritable or withdrawn.
2. *Excitement*: Suddenly, with little or no warning, the victim becomes wildly excited. He may tear off clothing, break furniture, shout obscenely, throw objects, eat feces, or perform other irrational acts. Usually he finally leaves shelter and runs frantically onto the tundra or ice pack, plunges into snow drifts, climbs onto icebergs, and may actually place himself in considerable danger, from which pursuing persons usually rescue him, however.
3. *Convulsions and stupor*: The excitement is succeeded by convulsive seizures in at least some cases, by collapse, and finally by stuporous sleep or coma lasting for up to twelve hours.
4. *Recovery*: Following an attack, the victim behaves perfectly normally; there is amnesia for the experience. Some victims have repeated attacks; others are not known to have had more than one [7, pp. 371-372].

This composite portrait does not exhaust the variety of behaviors reported, and it should be emphasized that not all cases replicate all symptoms.

HYSTERIA AMONG THE ESKIMOS

Some anthropologists, for example Wallace [7, 9] and Gussow [12], have assumed that epidemiologically the *pibloktoq* phenomenon occurred only in north-western Greenland, but more recently Foulks [8, pp. 10-23] discovered several cases among Eskimos in North Alaska and noted that arctic hysterias and related disorders have been reported in other parts of the Arctic, in Canada, and among the Ainu of Japan. The latah-type reaction has been widely observed in both Old and New World regions [1-6, 8, 13]. It is difficult to approximate the incidence of *pibloktoq*, although Foulks attempts a rough epidemiological estimate [8, pp. 24-36], as well as a historical sketch of ethnographic observations [8, pp. 10-23]. Many Polar explorers did not report on *pibloktoq*, including, for example, in their own accounts, some of the men who accompanied Peary to the North Pole. But Peary himself noted it for women, men and dogs and suggests it was quite prevalent:

Aside from rheumatism and bronchial troubles, the Eskimos are fairly healthy; but the adults are subject to a peculiar nervous affection they call *piblokto*—a form of hysteria. I

have never known a child to have *piblokto*; but some one among adult Eskimos would have an attack every day or two, and one day there were five cases [14, p. 165].

Pibloktoq as a form of Inuit 'arctic hysteria' has been reported by, among others, Czaplicka [3], DePoncinis [15], Foulks [8], Freuchen [16], Jenness [17, 18], Holtved [19], Macmillan [20], Malaurie [21], Novakovsky [22], Peary [14, 23, 24], Steensby [25], Stefansson [26], the Rasmussens (Knud and Neils) [12, 27, 28], Weyer [29] and Whitney [30]. In addition, a large number of observers, including some of the historically earliest ones [31-37], remark on the occurrence of 'madness' or 'insanity' among Eskimo groups, but one cannot conclude that these are hysterical episodes since the observations are presented in vague and indeterminate language. Some observers assert that hysteria is an element of the shamanistic performance. Spencer, who does not mention *pibloktoq* in a large monograph on the North Alaskan Inuit, describes hysteria as being a crucial selective ingredient for becoming a shaman [38, pp. 301-302 ff.]. But why this should be so, and how the controlled dissociative states of the shaman differ from the apparently uncontrolled outbursts of laypersons, is not specified. An example of the employment of such hazy concepts as 'nervous' or 'mental' disturbances is seen in Birket-Smith's ethnography of the Inuit of the Egedesminde District in Greenland.

Disturbances of the nervous system are not uncommon. Thus epilepsy sometimes occurs. 'Kayak-fear,' i.e., a nervous fear of kayaking, has of late attracted considerable attention for social reasons. Whether it is really a new disease is perhaps doubtful. Mental diseases also occur. Bordering on insanity is the overstrained state of mind, which results in the patient becoming *quivitoq*. . . . During epileptic fits the helpers make the sufferer sit upright and hold him in this position; they also frequently press his stomach with great force, and try to straighten out his hands. Various kinds of delirium (febrile, hysterical, etc.) are treated with a kind of incantation which, however, first came into use with Christianity. Thus I heard that crosses are to be drawn around demented patients, in order to keep away the Evil One. Decoctions of *Thymus serpyllum* are supposed to have a quieting effect [37, pp. 423, 426].

Such cloudy and unspecific ethnographic description is maddening and basically unreliable. What is meant by 'social reasons'? How do we know that what Birket-Smith terms 'epilepsy' is really not an hysterical explosion? What is meant by 'an overstrained state of mind'? What is actually going on during the 'febrile, hysterical, etc.' conditions of 'delirium'? What kinds of behaviors cause the Inuit (or their observers) to describe them as 'demented patients', 'maniacs' and similar value-loaded and uninformative terms? Could *quivitoq* in fact be the equivalent of *pibloktoq*? Freeman [39] suggests it is not, that it is a type of alienation and estrangement. Foulks seems to concur and terms it 'hermiting behavior' [8, p. 21]. The semiotics of the concept *pibloktoq* cannot be explored here, but there is some linguistic evidence to indicate that more than one word may be used to describe comparable phenomena, depending perhaps upon the dialect of the group in which they occur. There are many reasons why Europeans and Americans in the Arctic failed to note, described casually and ambiguously, or dis-

orted and misinterpreted the emotional side of Eskimo life; some are considered later in this paper.

It is significant that early observers reported *pibloktoq* as afflicting Eskimo dogs as well as humans. Some have used the same term as the emotional disturbance among humans, while others have spoken of 'lunacy', 'insanity' or 'that strange disease' that struck teams of huskies [14, 20, 23, 24, 27, 29, 31, 32, 34, 40]. Since the dogs were frequently in a near-starvation condition when some would be killed to feed others, the dogs would ravenously devour almost anything, including their traces.

When *pibloktoq*, or as Peary termed it, 'that dreaded dog disease, *piblokto*', broke out in a pack, usually many in the pack would be infected, and often, perhaps because the desperate dogs ate to excess, most of the pack would suffer 'fits', 'convulsions' and 'irritability', Macmillan [20, pp. 230 ff.] believed that "'piblock-to' [is] a strange disease rightfully dreaded by every explorer; it is a form of rabies and fatal". But in fact elsewhere he notes that it was not invariably fatal, that afflicted dogs did not attack humans, and that he frequently attempted personally to nurse the dogs back to health; hardly the signs of rabies. According to both Macmillan and Peary, the Eskimos used the term *piblock-to* to refer to this disturbance among dogs as among themselves. After an attack the dog would become spent and lie down too exhausted to move, or drop off to sleep. Sometimes dogs did die of the disease, probably due to the same variables that will be identified subsequently as involved in humans and other animals contracting vitamin A intoxication.

VITAMIN A AND INUIT NUTRITION

Vitamin A is one of a group of food elements necessary to sustain a healthy human organism. As with most vitamins, it performs highly complex and still imperfectly understood biochemical functions in mammalian and fish physiology. "Naturally occurring vitamin A is found only in the animal organisms although provitamins [substances from which the animal organism can form vitamins, e.g. carotene for vitamin A] occur in the vegetable kingdom" [41, p. 42; 14-17]. Vitamin A is an alcohol (retinol) very sensitive to acids, oxygen and ultraviolet rays. Its role in vision is fairly well understood and a form of night-blindness is due to vitamin A deficiency, which "can be cured, often in twelve hours, eating foods rich in vitamin A, such as liver" [42, p. 211].

Vitamin A is soluble in fats, oils and most organic solvents [42, p. 213]. It maintains some potency in heated butter although "when heated, many fats develop an 'anti-vitamin A' factor which destroys the biological activity" [42, p. 215]. However most Inuit groups tended to eat flesh and fat raw, frozen, or semi-cooked, thus very likely preserving much of their vitaminic strength. For hundred of years arctic explorers have remarked on the Eskimos' freedom from scurvy and often, although tragically not always, they sought fresh meat for its anti-scorbutic properties. Scurvy was a frequency cause of illness and death among Europeans who depended on salted meat and preserved foods. The greater the amounts

of fats and oils in the diet, the greater the absorption of vitamin A, which unlike certain other vitamins, for example C, is partially cumulative in the organism, especially the liver and kidneys where it may be retained in massive quantities.

While the presumed process of physiological transport to the mucosal cells and organs is too detailed to be described here, the largely carnivorous Inuit diet was well designed for the optimal, perhaps maximal, transport and absorption of vitamin A. This may have provided the basis for the excellent eyesight of the Eskimos and may have been an adaptive advantage in enhancing vision for winter hunts in the dim arctic night. The fat-rich diet probably contributed to their frequently observed high health status and strong dentition [43, 44], at least in the period before they became acculturated to Western dietary patterns and to the malnutrition resulting from poverty and altered nutritional practices as they became wage-laborers dependent upon European and American employers [21, 43-48]. For example, in addition to technological protective devices (clothing, shelters), traditional Eskimo diet has been held to play a role in cold adaptation through producing a high basal metabolic rate [43]. Eskimos traditionally seem to have suffered few vitamin deficiency diseases (except through starvation), although hypocalcemia may be significant among the Canadian Igloolik [43, p. 75] and possibly among Alaskan Inuit [7, 8]. But vitamin A deficiency is a feature of populations whose diets are low in fresh meats, fats and certain vegetables, resulting in a number of serious disease conditions. Almost every organ and glandular system, including the central nervous system, may be damaged. In central Africa, South and East Asia, India, Bangladesh, Latin America, the Middle East and many other regions where fat comprises a very small fraction of the diet, vitamin A deficiency related diseases are rampant [14, p. 259; 41, pp. 35-38]. By contrast, classical Eskimo nutrients probably contained one of the highest loads of vitamin A in the world.

And it is not vitamin A deficiency that occupies our present attention, but a much less widespread disease condition, a superabundant concentration of this vitamin resulting in an intoxicated state known as hypervitaminosis A. It is the author's contention that the major sources of Eskimo diet make it likely that this condition may have been more widespread among these peoples than hitherto reported or suspected and that it may have been a precipitating, and possibly a causal, factor in some cases of *pibloktoq*.

HYPERVITAMINOSIS A IN HUMANS AND OTHER ANIMALS

It is well-known that certain marine and arctic mammals contain extremely high concentrations of vitamin A, mainly in their livers and fat [49-57]. For centuries, arctic explorers and travellers have reported symptoms of drowsiness, irritability, severe headaches, nausea and other ailments within several hours of eating the livers of polar bears, seals and, when driven by starvation, husky dogs [49-51; 58, p. 289; 59, 60, pp. 453-454]. In the third voyage to arctic regions of the Dutch explorer, William Barents,

in 1596, after killing a polar bear, "... wee fleaed her, and found her skinne to be twelve foote long; which done, wee eate some of her flesh; but wee brookt it not well" [61, p. 76]. Despite this, after a bitter winter of near starvation in 1597, the men killed a polar bear that attacked them, and, driven by hunger, they ate some of it.

... But her death did vs more hurt then her life, for after we ript her belly, we drest her liver and eate it, which in the taste liked vs well, but it made vs all sicke, specially three that were exceeding sicke, and we verily thought that we should have lost them, for all their skins came of from the foote to the head, but yet they recouered againe, for which we gave God heartie thanks, for if as then we had lost these three men, it was a hundred to one that we should neuer have gotten from thence, because we should have too few men to draw and lift our neede [61, pp. 183-84].

The men were all ill for five or more days, and described as extremely weak, nauseous, irritable and irrational. In 1630 during a winter in Greenland of extreme privation, eight English seamen separated from their ship killed a polar bear:

And upon this Beare we fed some twenty dayes, for shee was very good and better than our Venison. This only mischance wee had with her, that upon the eating of her Liver our very skinnes peeled off, for my owne part, I being sicke before, by eating of that Liver, though I lost my skinne, yet recover'd I my health upon it [62, p. 279].

In 1853-1855 an American navy physician and arctic explorer, Elisha Kane, despite his knowledge of Eskimo prohibitions on eating polar bear liver,

... satisfied myself that it was a vulgar prejudice to regard the liver of the bear as poisonous. I ate of it freely and succeeded in making it a favorite dish with the mess. But I find to my cost that it may sometimes be more savory than safe. The cub's liver was my supper last night, and today I have the symptoms of poison in full measure—vertigo, diarrhoea, and their concomitants. ... I repeated the experiment several times afterward, and sometimes, but not always, with the same result. I remember once, near the Great Glacier, all our party sickened after feeding on the liver of a bear we had killed; and a few weeks afterward, when we were tempted into a similar indulgence, we were forced to undergo the same penance. The animal in both cases was old and fat. The dogs ate to repletion without injury [31, Vol. I, pp. 392-393; dogs and humans seem to be variously and differentially affected, as discussed later in the present essay].

In the early 20th century, Lindhard described the symptoms of all members of an expedition who had eaten a stew of polar bear liver, heart and kidneys, as drowsiness, irritability, severe headaches, vomiting, overwhelming desire to sleep and skin peeling off 'from head to foot' [cited in 60, p. 453]. On the other hand, Isaac Hayes, another physician on the mid-19th century Kane expedition heading a different party, reported eating bear liver without ill effects, but this was probably small amounts, described by Hayes as 'kernels' of liver [32, pp. 210, 227, 239, 247].

In several antarctic expeditions in more recent times, similar episodes have occurred. In the 1911-1914 Australian National Antarctic Expedition, the leader, Sir Douglas Mawson, and his crew became severely ill shortly after eating the livers of seals, which they had grown to like, and the livers of husky dogs when they were reduced to near star-

vation by severe cold and scant game. The dogs had themselves starved until only their livers seemed to offer a sufficient meal. Among the symptoms the men developed were severe abdominal cramps, tingling and parasthesias in their extremities, inflammations and skin lesions, dysentery, loss of appetite, desquamation or peeling of the skin, convulsions, dementia and delirium. They quickly developed frost-bites and infections, and suffered bouts of vertigo [49-52, 59, 63].

Scientists experimenting with laboratory animals have found a number of drastic effects from the administration of heavy doses of vitamin A, either in synthesized form or directly in the livers of polar bears, seals, arctic wolves, foxes and husky dogs [41, 42, 49, 58-60]. Among experimental animals severe physical symptoms included inflammation of the eyes, spontaneous bone fractures and other skeletal lesions, congestion of lungs and viscera, hemorrhages, marked loss of weight and appetite, hyperesthesia (excessive sensitiveness of touch and other sense organs) [60], exophthalmos (abnormal protrusion of the eyeball), reduced bone growth and many other damaging effects. All animals became sluggish and irritable and some died.

Among humans comparable effects have been noted, and many others as well (e.g. distention of the fontanelle in infants) [41, 42, 55, 57-57, 64-83]. Of special interest to this study are the behavioral and neurological changes in humans. These include drowsiness, vertigo, irritability, severe headaches, hypersensitivity to tactile stimuli, tremors in all extremities, clonic and convulsive movements, anorexia, pruritis (intense itching), night sweats, delirium, dementia, convulsions, 'flames' before the eyes and so on (see references in this and the preceding paragraph). Most important here are the clinical observations on the similarities in behavioral effects of hypervitaminosis A and those of brain tumors, epilepsy, psychotic or neurotic disorders, encephalitis, arthritis, cirrhosis, hypercalcemia, etc., probably because the condition frequently results in increased cerebrospinal fluid pressure and intracranial pressure [60, 67, 70, 72, 74, 76, 78, 79]. For example, physicians reported on three adolescent girls stricken with hypervitaminosis A as suffering from 'pseudo-tumor cerebri' [65; see also 41, 42, 51, 55, 58, 64, 65, 67, 69, 74, 76, 78]. Among the observed findings were skin roughness and desquamation, hypomenorrhea, hair loss, enlargement of liver and spleen, migratory bone pain, papilledema (edema of the optic papilla, optic neuritis), intracranial pressure, increasing irritability, double vision, somnolence and anorexia. Brain tumors were at first suspected until it was discovered that each patient has been overdosing for several months on vitamin A. When vitamin A intake was stopped, the symptoms began to diminish.

While hypervitaminosis A as a clinical entity has been relatively infrequently reported in the West, its prevalence is probably greater among children and adults than hitherto suspected [68, 69, 73-77, 80, 83]. Due to easy accessibility of vitamins commercially, the tendency of many persons for self-diagnosis and self-prescription, food faddism and the often careless and irresponsible prescribing by physicians and non-medical healers of megadoses of vitamins for a wide

variety of poorly understood health problems, hypervitaminosis A is probably occurring with a much higher than recognized incidence. The tendency of some physicians and some parents to overdose their children or themselves with vitamins and multivitamins reached a magnitude sufficient to prompt the Nutrition Committee of the Canadian Paediatric Society to issue an official warning [75] on the 'Use and Abuse of Vitamin A'.

Societies with a high consumption of meats, fish and dairy products may have been more susceptible to hypervitaminosis A than previously known. Not only members of urbanized industrialized societies, but agriculturalists with a heavy intake of dairy foods and meat, and hunter-gatherers subsisting on a mainly meat and fish diet, which would include the Inuit but not those like the !Kung with a predominately vegetable nutrition, could be vulnerable to this disease. It is worth noting that "... in certain parts of West Africa where palm oil is produced, hypervitaminosis A is reported to be occurring" [41, p. 37]. On the basis of skeletal analysis of *Homo erectus* in East Lake Turkana, Kenya, dated at 1.6 ± 0.1 million years, Walker, Zimmerman and Leakey have recently inferred the presence of hypervitaminosis A, probably due to a "high dietary intake of animal liver, most probably that of carnivores" as the hominids of this period increased the meat proportion of their nutrition [84]. Thus, the disease may have struck early in human evolution as part of the cost of a carnivorous diet, and I suggest it may have afflicted nonhuman carnivores themselves in an even more distant epoch.

POTENTIAL SOURCES OF HYPERVITAMINOSIS A IN INUIT NUTRITION

In the Arctic "Various sequences of predation concentrate vitamin A through a food chain until a large concentration exists in seals, sharks, and mammals" [51, p. 96]. The Inuit are the final link in the series. According to Knudson and Rothman:

... This strange drifting community [is] called plankton, comprised of minute sea organisms and the microscopic plants which sustain them. . . . The food chain leads on from the plankton to the schools of plankton-feeding fishes like the herring and the mackerel; to the fish-eating fishes like the bluefishes, tuna, and sharks; to the pelagic squids that prey on fishes, and to the great whales. In the Arctic waters there exist dense plankton swarms with copepods and swimming snails that lure the herring and mackerel, the whales and the seals. In the larger fish the carotene of the aquatic plants and certain pigments which originate from carotene become converted and stored as vitamin A. And, lastly, it is the polar bear that feeds chiefly on the seals, fishes and other animals [59, p. 318].

One of the earliest clinical reports on vitamin A poisoning stated: "It has long been known among Eskimos and arctic travellers that the ingestion of polar bear liver by men and dogs causes severe illness. It has also been reported that the liver of a certain seal (*Phoca barbata*) is poisonous, although opinion on this point is less than unanimous" [51, p. 166]. An extensive review for this study of the corpus of observations and interpretations on Inuit life and culture indicates that the evidence is ambiguous both with respect to the depth of Inuit belief regarding

polar bear livers as well as the degree to which this prohibition is in fact implemented or disregarded. (It should be noted that inhibitions about eating its liver do not extend in any instance to the remainder of the bear's flesh.)

Elisha Kane's previously noted references to 'prejudices' regarding polar bear liver in the mid-nineteenth century referred to Eskimo beliefs and those of Europeans influenced by them. McClintock, who was in the arctic at the same time as Kane, states: "The Greenlanders [Inuit] are fond of bear's flesh, but never eat either the heart or liver, and say that these parts cause sickness" [85, p. 103]. Hayes during the same epoch reports that "... the Esquimaux will not eat [bear's liver], but we were glad enough to get it" [32, p. 227] and reported no ill effects on this and two other occasions. Charles Francis Hall, who lived with the Eskimo in the 1860s, stated:

The liver of the polar bear is never eaten by the Inuits. Of course, they know the general effect of eating this part to be as if one were poisoned. They say it makes them feel very sick, especially in the head, the hair dropping off, and the skin peeling from their faces and bodies. They do not allow their dogs to eat it, because it makes them also sick, and causes all their hair to come off. They either bury the liver or cast it into the sea. Even after this precaution, dogs sometimes succeed in getting hold of it, and it really poisons them [33, Vol. II, pp. 81, 273-274].

In the 1913-1918 Canadian Arctic Expedition Jenness reported that among the Copper Eskimo, "The [polar bear] liver is said to produce illness and therefore is never eaten" [17, pp. 101-102]. H. R. Thornton, a missionary in Wales, Alaska in 1890-1893, noted that the Eskimo he tried to convert "... say that if the lining membrane of the [polar bear] liver be taken off, it loses its poisonous properties and may be eaten with impunity", but he reports also that a deserting sailor "made himself ill by eating bear's liver" [86, p. 212], without describing any symptoms. One could infer that these Eskimos did eat bear's liver with the membrane removed.

Commanding the expedition of which Jenness was a member, Stefansson [87, pp. 479-482] states that whether polar bear liver was poisonous was a matter of 'much speculation' among arctic explorers and whalers and that they had probably obtained this information through hearsay from Eskimos. When Stefansson first inquired of Eskimos, they confirmed the point but, "when after years with the Eskimos I finally got reasonable command of their religious ideas and ceremonial language, I discovered that what they meant to say was that bear liver was taboo and that some misfortune, perhaps taking the form of illness or death, will come upon the eater of it as a punishment, somewhat as mediaeval Christians might have expected illness or death to follow the profane use of the sacrament" [87, pp. 479-480]. The religious inference seems to be Stefansson's rather than his informants'. The Eskimos also claimed bear's liver caused whitening of the skin or even death.

After this, Stefansson, somewhat in the tradition of Dr Kane earlier, sought to prove experimentally whether bear liver was indeed poisonous and fed some to himself and his crew on several occasions. While they all reacted with some of the symptoms

described by contemporary physicians for hypervitaminosis A, each individual seemed to undergo a different reaction. Some became seriously ill, some moderately and some mildly. Stefansson wondered whether the fat in which the liver was cooked may have been implicated or whether the particular livers they ate were infected, since later he ate some bear liver with impunity. Long after this, in a report prepared for the United States Army Air Corps, Stefansson's comments on poisonous effects of polar bear liver seem equivocal and indecisive [26, pp. 98, 230–231, 282–283]. Nevertheless, it remains crucial that a highly variable individual response to hypervitaminosis A has been noted repeatedly in scientific reports, both among laboratory animals and among human cases treated medically. Moore [60, p. 143] states: "The quantities of vitamin A accumulated by mammals, and stored in their livers, vary widely between species, and also between individuals in the same species". Some writers have suggested that the condition of the animal (not only polar bears, but seals and other mammals) when it is killed, for example, whether it is fat and heavy before hibernation or thinned out by hunger, may make a difference in the degree of toxicity of the vitamin A content in its liver and other organs. But the livers of husky dogs, eaten when the dogs had been almost completely emaciated by hunger, were not only unshrunk in size through starvation, but highly poisonous in amounts of vitamin A.

While *pibloktoq* among Eskimos has been reported during all seasons, most cases seem to occur during the late winter and early spring, which may be just the point at which arctic mammals are at their lowest weight, but also when their livers may not have decreased in size. Indeed, since in a normal animal the liver releases vitamin A to the body blood and tissues [60, pp. 585–586], it may have to store the vitamin in very high concentrations as the animal loses weight, and thus at this time be maximally poisonous. Unfortunately, it is not clear from the scientific literature whether this seasonal difference actually obtains, so for now this question remains unsettled. Normally the Inuit, like other humans and all mammals, can store large amounts of vitamin A in their livers to be used as required [60, pp. 208, 209, 233, 545–546]. Obviously each individual must have some threshold which, when breached through ingestion of high concentrations of vitamin A, overcomes the protective functions of the liver, and renders the person vulnerable to an overdose.

What does seem evident is that animals of the same species, for whatever reasons, appear to differ in the amounts of vitamin A accumulating in their organs; apparently sometimes the loads are hypervitaminic and sometimes they are not. Similarly, Degerbøl and Freuchen [40] noted that both humans and dogs sometimes refused to eat polar bear or shark liver and sometimes they would not; when they did consume it, sometimes they would become ill and sometimes seemed not to be harmed; and when affected, sometimes people and dogs would shed their hair and skin. The question begs further research. Also likely to be decisive in whether a particular person or nonhuman acquires hypervitaminosis A are the amounts of liver, kidney, fat and blood ingested, the time span over

which doses are consumed, and individual immunological and other genetic and acquired differences. Females in most mammal species seem to store and retain larger quantities of vitamin A than males [60, pp. 499–511]. Thus, sexual dimorphism, with a generally larger body volume for males, may play a role in affording males greater assimilative capacity than females. This may be a significant factor in the reportedly more frequent occurrences of hypervitaminosis A in human females than males, and similarly of *pibloktoq* in females than in males among the Inuit.

Whatever the actual intake and consequences of polar bear livers by Inuits, the fact remains that all without exception ate huge quantities of many species of fish, shellfish, fowl, whales, walrus, foxes, wolves, caribou and above all, seals of several species. Most especially they were fond of seal livers. It has been demonstrated through assay and testing that the livers of the following animals that form the dominant portion of Eskimo diet carry poisonous, though not necessarily fatal, loads of vitamin A: polar bears, bearded seals, Greenland seals, Atlantic gray seals, arctic foxes, wolves and many species of fish including arctic salmon [49, 50–54, 59]. In addition, Eskimos, as Europeans, not infrequently were forced to eat their huskies and these animals have vitamin A toxic livers [54, 56, 63]. There is also some historical evidence from early explorers and traders that aboriginally Eskimos may have been fond of dog flesh (whether dog livers were eaten is not specified in these sources) [88, p. 137; 89, Vol. 2, pp. 11, 36].

Seals' livers have about half as much vitamin A as polar bears' livers, but still enough to cause hypervitaminosis. If the Inuit really were aware of the toxicity of bear livers, they must also have been aware of similar effects from seal livers. But most anthropologists' and explorers' reports indicate just the contrary. A few examples follow:

Macmillan on the Polar Eskimo: "Seal meat is the Eskimo's turkey, his staple food; a seal's flipper is his entrée, and a seal's liver his ice-cream" [20, p. 258].

Zagorskin [90, p. 123] in the 1840s comments on Eskimos in the Yukon and Kuskokwin valleys as eating entire bearded seals, throwing away nothing that could be consumed.

Balicki [91, pp. 76–77] on the Netsilik: "This was the signal for all the hunters to assemble and partake of a minor feast. An incision was made in the seal's belly, the liver and some blubber removed, and these parts shared and eaten by the gathered hunters on the spot".

Freuchen [16, p. 142] on the Polar Eskimo, notes that seal liver was "particularly desirable".

Jenness [17, p. 100] on the Copper Eskimo states that when seals are killed, "The liver and kidneys are always eaten raw, generally unfrozen, while the intestines of the bearded seal are considered a delicacy".

Boas [92, p. 155] on the Greenland Central Eskimos eating seals: "Liver is generally eaten raw and is considered a tidbit".

Målaure [21, p. 191], living and hunting with the Thule Eskimos in the 1950s: "After drinking [tea] they proceeded to eat [polar] bear, a rough fibrous meat. They returned for more bear, then seal liver. What a dessert! . . . They ate; they filled their bellies

for a month. The feast continued. They went on talking of bear. Would they ever stop?"

No source in this research has noted any sort of Inuit prohibition for seal liver. Furthermore, all have reported that while for some groups polar bears were not a major dietary item, they were eaten when caught and in only some instances had a specific refusal to eat the livers been recorded. Eskimo bands frequently faced starvation and often were forced to eat even their boots and to drink precious seal oil that might be needed for heat in their lamps (and which they did not like except as a purgative). They also are reported as having no compunction about eating rotted meat or fish (and often preferred it). Therefore, when in desperate straits, they probably did consume all edible parts of bears they might bring down and chance sickness that might follow, since they must have known that while often devastating in its side effects, bear liver was rarely fatal. At a meeting of the Society for the Study of Psychiatry and Culture in October 1983, Dr Edward F. Fouls, having read an earlier draft of this paper, showed photographs of an Alaskan Inuit shaman whom he knew. This man, despite knowledge of the poisonous effects of polar bear liver, had eaten one in order to share in the admired animal's great power, and as a consequence his hair and skin turned white, and he had shed much of both, but survived a long time afterward. Dr F. A. Milan [personal communication] also knew of this man, claims he suffered from an idiopathic melanin disorder (vitiligo) and "rationalized his color change" as due accidentally to swallowing liver fluid while kinning a bear.

The Eskimos also ate huge quantities of fat, not only because they deemed it a desirable part of the animals they hunted, but because it was adaptive in the extreme cold. Indeed Europeans working or travelling for an extended time in the Arctic soon developed a need and craving for fat and learned to prize it as did the Eskimos [14, 16, 20, 23, 26, 27, 5, 87, 92, 93]. Since vitamin A is fat-soluble, in addition to its storage in livers and kidneys, it seems safe to assume that Inuits would be more vulnerable to hypervitaminosis A than almost any other human population. Even one-half of a seal's liver could precipitate the condition. It has been estimated that 0 g of polar bear liver or 80 g of bearded seal liver could contain more than 1,000,000 international units (I.U.) of vitamin A and thus constitute a heavily poisonous dose [50, p. 760]. Eighty grams of seal liver is the equivalent of 2.82 oz. (1 g = 0.035274 oz.) which "is capable of being exceeded several times over at a single meal" [50, p. 760] since the Inuits are voracious eaters, as attested by every observer.

SOMATIC AND BEHAVIORAL CONCOMITANTS OF HYSTERIA

It has long been known that a host of somatic and behavioral derangements were concomitants of hysteria and hysteriform disorders, preceding, accompanying, and/or following hysterical episodes. Veith's [4] history of hysteria demonstrates that the disease is undergone a thorny evolution, diagnosis, prognosis, and treatment varying with prevailing philosophical and cultural currents of time and place (see

also [95-97]). Veith's account begins with ancient Egypt, where a notion of a wandering womb and repressed sexuality (especially in women) was transformed by the Greeks into a full-fledged nosological entity named after their term for uterus, *hysteria*. While hysteria was usually associated with women who were frequently victimized and maltreated because of the sexual connotations ascribed to the 'weaker', more 'lascivious' gender, many physicians in different periods also recognized male hysteria, often termed 'hypochondriasis', which originally had a different meaning than it was later to assume. Furthermore, almost without exception, they recognized a broad spectrum of organic complaints as integral to a diagnosis of hysteria [94-97].

Reviewing the torturing and killing of witches in the Middle Ages, Veith concludes that "... many, if not most, of the witches as well as a great number of their victims were simply hysterics who suffered from partial anesthesia, mutism, blindness, and convulsions, and, above all, from a variety of sexual delusions". Indeed, "Pricking the skin for areas of anesthesia was a frequent test; regions of insensitivity were considered satanic stigmata, confirmatory of bewitchment" [94, pp. 61-65]. Other symptoms included tics, tremors, 'fits' (seizures), nausea and vomiting (of needles, 'little devils', etc.) and subsequent amnesia.

Freud, with neurological training, was acutely aware of the bodily signs of hysteria, as were his predecessors and followers. In his early papers on the subject [98], and in his joint book with Breuer [99] he noted a large range of organic and behavioral concomitants of hysteria. Among others one finds anesthesia, parasthesia, contractures, epileptiform convulsions, paralysis, 'tic-like affections', anorexia, nausea, vomiting, visual and auditory hallucinations, pain in joints and muscles, 'contraction of the visual field', psychic and physical trauma, paraphasia, hearing disturbances (including deafness), occipital pain, diplopia, anemia, disorganized speech, confused and disoriented behavior, suicidal impulses, somnambulism, persistent coughs, neuralgias, etc. After each episode, amnesia.

As Freud moved away from a neurological orientation, he came to attach a psychogenic origin to the somatic and behavioral derangements. Repressed memories of traumatic events, too painful to be admitted to consciousness, were converted into bodily expressions, symbols of the person's distress in socially more acceptable forms. And yet, though Freud and Breuer claimed that the physical disorders ceased after psychotherapy had brought repressed conflicts to consciousness, even they admitted that not all somatic symptoms were always terminated:

The motor phenomena of the hysterical attack can in part be interpreted as the memory of the general forms of reaction to the accompanying affect (like the fidgeting of the whole body to which the infant always resorts), in part as a direct motor expression of this memory, and in other parts they, like the hysterical stigmata in the personal symptoms, elude this explanation [99, p. 11; emphasis added].

Some practitioners continued to try to isolate and understand the role of organic involvement in hysteria and other psychoneuroses [100, pp. 445-490;

101, pp. 848-850], although psychiatry generally sought for psychogenic explanations of most emotional disturbances. By the 1950s there was a trend toward seeking social and cultural factors, and by the 1960s, as Wallace [7] has noted, a reversal again toward uncovering biochemical and organic etiological constituents or causes.

POSSIBLE LINKAGES BETWEEN PIBLOKTOQ AND HYPERVITAMINOSIS A

Most, though not all, symptoms described clinically for hypervitaminosis A have also been reported for hysteria, hysteriform states and similar diatheses; many have also been reported for persons consuming polar bear or husky dog livers; and several have been noted for Inuits who became *pibloktoq*. The kinds of verbally abusive behaviours described for *pibloktoq*, and often for hysteria in Western societies, have also been described for victims of hypervitaminosis A in the Arctic and Antarctic. Just as Freud, Breuer and others claimed that most, though not necessarily all, signs of clinically diagnosed hysterics dissipated soon after they broke through the patients' defenses in psychoanalysis, so physicians treating victims of hypervitaminosis A invariably report that as soon as overdosing with vitamin A was discontinued the symptoms began to attenuate, and in most cases partial or full recovery occurred in days or weeks. After an eruption of *pibloktoq* most victims, like most hysterics and hypervitaminosis A patients, are overcome with drowsiness and sink into sleep or a stuporous state. Afterwards, amnesia for the episode is typical. A connection, then, between hypervitaminosis A and some instances of *pibloktoq*, and indeed hysteria in other cultural regions, seems reasonably probable.

The cries and actions of Eskimos who have become *pibloktoq* seem to be those of persons in great distress, physically and psychically. Where hypervitaminosis A may have been involved, the victim was expressing responses to the ravages of this excruciating disease. The painful effects of many different symptoms of the disease have already been described. The severe headaches, apparently an invariable symptom, could drive the victim beyond lethargy to fear and anguish. But the net effect of several symptoms, for example, joint pains, intracranial pressure, nausea, vertigo and so on, could have pushed the individual beyond the edge of fear into a loss of self-control and a demented outburst that vented torment and rage.

Furthermore, the context of the episode in Eskimo ecology, environment, culture, and social structure helped to determine, or at least prefigure the particular emotional tone and behavioral stance. As Gussow [12], Parker [102], Wallace [9], Foulks [8] and others have suggested, the ethnic personality configuration strongly colored the quality and content of the outburst, the expression of which was syntonic with Eskimo culture. Gussow [12, pp. 231-232] notes that *pibloktoq* "may be precipitated by a sudden fright, unusual mental shock, brooding over absent or dead relatives, fear of the future, imagined or actual abuse, and so forth". For example, Eskimos on Peary's ship panicked at losing site of land, and at least one became *pibloktoq*. Another releasing mechanism, I

suggest, could be an attack of hypervitaminosis A. This does not preclude some of these other 'triggering situations' also being in the etiological constellation.

Several earlier observers to the contrary, Gussow dismisses the effect of the long, dark arctic nights as a causal factor, suggesting this "represents nothing more than a projection of what the European in the Arctic may experience, and in no way accounts for Eskimo psychopathology" [12, p. 231]. Nevertheless, he also states that, "... *unconsciously* winter is perceived by the Eskimo traumatically, not for reasons of darkness, oppressiveness or environment, etc., but rather that winter, more than any other season, intensifies Eskimo insecurity and hence their proneness to derangement, because increased threats of starvation, high accident rates, etc., are inherent, though perhaps psychologically denied, features of the Polar winter" [12, p. 232]. It was, of course, starvation that frequently forced the Inuit to kill and eat their highly valued huskies, and possibly polar bear livers and other hypervitaminotic foods (e.g. foxes and wolves), and thus, as suggested, laid themselves open to hypervitaminosis A. In extreme conditions, cannibalism sometimes occurred, although normally it was much feared and strongly prohibited.

In some instances the social position of the women in Inuit society may have constituted a predisposing or causal factor in an hysterical eruption. Many observers seem to feel that for all her supposed freedom, the Inuit woman had much to fear besides starvation and accidents. Peter Freuchen, Knud Rasmussen and others who lived intimately with Eskimos for many years report numerous instances where husbands seemed to display scant affection for wives and not infrequently abused them. In such accounts the woman's worth was measured by how well she accommodated her husband's needs and wishes, and, with some exceptions, women were dependent upon men for food. By the end of their third decade, Inuit women began to age, their teeth worn down by years of incessant chewing of skins. While occasionally a woman left her husband for another lover, the husband always had the freedom to cast her from the household, and such instances were not rare. These observers weighed the evidence in favor of male domination [103]. For example, Jenness describes one of his male informants as forcing his wife outdoors naked, where she remained fearfully for a long interval, and notes another man "who had disciplined his wife by tearing her coat from top to bottom". [18, pp. 182-183]. The often-described practice of 'wife-lending', a mark of the man's hospitality, meant that a woman could, without ceremony, be ordered to sleep with a visitor, whatever her personal desires. It is presumed female inequality that leads Gussow to hypothesize that going *pibloktoq* "is a regressive act, a dramatic, though thoroughly unconscious invitation to be pursued, i.e. to be attended to, taken care of... an expression of control over, denial of, and compensation for, feelings of helplessness and deep anxiety... in a psychologically primitive and infantile, but characteristically Eskimo manner..." [12, pp. 233-234].

Not all observers accept this interpretation. Some feel that the Eskimo male-female equation is much more one of equality and interdependence, that in

fact the woman does most of the basic work necessary to sustain the family, except for hunting, and that indeed, it may be the man, more than the woman, who has a sense of dependency in the face of the woman's strength and independence. Freeman [39] believes that the inference of male dominance and female subordination is due to ethnographers and other observers having been mainly men, and their informants having been mainly Inuit men, offering male-biased data to male recorders. The egalitarian view is actually more supportive of the present writer's hypothesis, as will be discussed, although a definitive judgment in the debate may not be possible.

One cluster of somatic reactions to hypervitaminosis A requires special mention: the abdominal cramps, joint pains and clonic, tetanic-like convulsions. Wallace suggests that hypocalcemia or low level blood serum calcium may be responsible for *pibloktoq*. His hypothesis is complex and brilliantly argued and deserves more discussion than we can offer here. But he notes the resemblance between clinical tetany and hysteria, suggests that the two phenomena were probably frequently confused in nineteenth century Europe and that both diseases seemed to fade out by the early twentieth century.

And it may be the result of culturally determined changes in such matters as style of dress, hours of work, methods of lighting, and diet, which could affect, in particular, calcium intake and utilization in persons vulnerable to tetany and rickets. Certainly rickets has become more rare in precisely those groups most prone to grand hysteria: the Western European urban populations [7, p. 380].

Wallace points out that Freud could not have known that tetany and hypocalcemia might be at the bottom of some of the physiological and psychological behaviors he studied since their connection was not discovered scientifically until 1921. And he also suggests, as other have, that hysteria may not have necessarily vanished in Western populations, but simply been replaced with other nosological labels more fitting for contemporary cultural and social styles and outlooks. Now severe convulsive reactions seem as characteristic of hypervitaminosis A as of tetany and hysteria. Is it possible that in Europe hypervitaminosis A was confused with tetany or hysteria? Perhaps, but clinical and experimental evidence seems to point in a different direction, for hypervitaminosis A appears to be associated with hypercalcemia rather than hypocalcemia [49, 55, 57, 59, 65-68, 70-73, 75-84]. Indeed, some of the skeletal effects of hypervitaminosis A have been confused with those of hypervitaminosis D, but careful differential diagnosis can apparently distinguish the characteristic bone lesions of each hypervitaminic condition [73, 82, 84].

Finally, it is worth pointing to the finding by Fouks that all ten cases of his sample of *pibloktoq* victims not only had histories of serious organic disease and traumata, but also suffered from chronic middle ear disease (*otitis media*) [8, pp. 98-99]. Furthermore, several cases included family members with the same ailment, which is apparently quite prevalent in Inuit populations [8, Chap. VIII]. As Fouks notes, "chronic *otitis media* can affect the central nervous system more generally by several other means"

[8, p. 99]. Needless to add, so can excessive ingestion of vitamin A. The most common symptoms of *otitis media* are vertigo and auditory impairment, conditions also frequently reported for sufferers of hypervitaminosis A and of hysteria. Thus, severe vertigo in middle-ear infections or hypervitaminosis A may result not only in loss of equilibrium, but disorientation, confusion, and fear, prodromal elements of an hysterical detonation.

CONCLUSIONS AND INTERPRETATIONS

This study has proposed that a biochemical factor, concentrated vitamin A in quantities sufficient to constitute a poisonous dose, may have been a contributory element in bringing about some cases of Eskimo *pibloktoq*, a variant of a more general class of 'arctic hysterias' affecting Arctic and Circumarctic peoples. The essential function of vitamin A in the human diet has been shown, how it is manufactured in the animal organism, and how in deficient amounts it has caused many dreadful organic and behavioral disorders in the economically impoverished regions of the world. Its concentration increments cumulatively through a food chain in arctic waters that begins with aquatic plants and microorganisms and culminates in the livers, kidneys, fat and blood of mammals and fishes that formed the fundamental Inuit diet.

Eskimo nutrition is rich in vitamin A, which has probably afforded the adaptive advantage of keen eyesight and night vision, a boon to a basically hunting culture. Furthermore, it probably contributed enormously to their general health status. But, I suggest that eating the livers and fat of seals, possibly polar bears and other arctic mammals, as well as fish and, in extreme circumstances, husky dogs, could bring about a condition known as hypervitaminosis A, resulting from a superabundant toxic concentration of this vitamin.

The somatic and psychological sequelae of vitaminic intoxication appear to possess marked equivalences to the organic and behavioral elements of historically observed and clinically diagnosed hysteria, and of the reported Inuit version of this disorder. It seems likely that at least some cases of *pibloktoq* may have been caused, or precipitated, by hypervitaminosis A. This finding may easily complement some of the existing psychodynamic, ecological, and social structural hypotheses. And it may stimulate us constructively to reexamine, and perhaps modify or enlarge upon them.

Studies of the diet of contemporary Eskimo groups indicate that, however much it has been changed by the addition of Western foods, it continues to depend heavily on most of the arctic fishes, fowl and sea and land mammals eaten in earlier times. It has been found to contain fats and vitamin A in abundance, even though calcium and certain other vitamins, B and C for example, were deficient in some groups [43, 44, 48, 104, pp. 31-72].

As in earlier studies of *pibloktoq*, many questions have been left unanswered. Some are beyond the scope of this article, but a few may be addressed.

First, there is the problem of certain physical effects of hypervitaminosis A which were not, so far

as this writer is able to determine, also reported for *pibloktoq*. It may be that these and other somatic sequelae were overlooked by foreign investigators since the more dramatic psychopathological symptoms overwhelmed their attention. Even such sympathetic observers as Stefansson, Rasmussen, Peary, and Freuchen, after many years of intimate living and friendship with Eskimos, still regarded them as 'savage', 'primitive' and 'childlike' people, and frequently explained organic and behavioral traits simply as 'racial'. In his classic inquiry into *pibloktoq* Brill [105] raises the question of why somatic concomitants are not reported for Inuit hysteria. Like his mentor, Freud, he assumes the bodily derangements of hysteria are the 'phenomena of conversion', and he says that his own clinical experience demonstrated that

in all cases of lasting conversions, such as atasia abasias, paralyzes, aphonias, etc., I always dealt with persons of very complex psychic organization who were usually suffering for a long time before the conversion took place. Almost all of them belong to that class of patients who suffer in silence without letting anyone know about it. I also recall a great many patients who were of the talkative kind who showed their attacks through laughing, crying and screaming. They did not show as complex a mental organization as the former patients. It is also significant that one rarely encounters conversion hysterics in children . . . Peary says: "Eskimos are children in their grief, as in their pleasure". Their motor reactions to unattainable wishes are also childlike. Instead of a complicated hysterical attack or a chronic hysterical symptom like paralysis or aphonia, the attack usually follows the injury and manifests itself in an emotional outburst of the most primitive type. There is hardly anything more childish than the imitation of the dog or bird, or the running away into the hills singing or crying [105, pp. 519-520].

Brill concludes that despite the apparent differences in hysterical manifestations between these 'childlike', 'primitive' people and Europeans they 'are both the same under the skin' and that hysteria is hysteria universally. Nevertheless, he betrays the same ethnocentrism, sexism, and perhaps even racism of most other earlier observers. He explained the apparent rarity of *pibloktoq* among males and presumed absence among children as proof that it constituted hysteria and not epilepsy.

Most descriptions of *pibloktoq* have been based largely on observations and interpretations of adult female sufferers, and on the basis of reported cases, it usually has been concluded that women victims outnumber men. This, too, may be in part a function of ethnographic ethnocentrism and sexism, as suggested previously, with a reluctance to attribute susceptibility to hysteria to both genders. Veith [94] records a similar hesitation, down through the ages, to recognize or admit male hysteria. If indeed the female-male differential is an artifact of repertorial bias or indifference and not necessarily an epidemiological fact, this would require some revision of existing theories. The psychodynamics and sociodynamics of male hysteria would also require comprehension, and could lead to modifications in the largely female-based explanatory models by mainly male theorists.

In fairness it should be acknowledged that most observers also admit that some males become

pibloktoq. Moreover, in the ten carefully described clinical cases of *pibloktoq* that form the basis of Foulks' [1] study, 6 or 60% of the total were males! Furthermore, four of the ten were children, two of them under 10 years of age and two in their teens. Since nearly every earlier observer reported no cases of children and many asserted quite positively that *pibloktoq* did not happen to children, Foulks' findings both refute these earlier dogmatic generalizations and provide support for my hypothesis of a nutritionally-involved etiology in some cases.

Since several observers reported that Eskimo dogs as well as people suffer *pibloktoq* this should throw up a warning flag in regard to purely psychodynamic, sociodynamic, or even ecological theories, while strengthening the biocultural approach of Wallace, Foulks and myself.

Whatever the independence of Inuit women, their offspring were not abused. Eskimo socialization was notably permissive [102, 106], so much so that often European explorers, missionaries, and even earlier anthropologists frequently viewed Eskimo children as overindulged, even 'spoiled'. Hypervitaminosis A, like hypocalcemia, is known adversely to affect children as well as adults, and in fact more cases of children have been reported by Western physicians [59, 64-66, 68, 72, 75, 78, 81]. Furthermore, Eskimo huskies, as their masters, subsisted on much the same diet, though of course they were usually thrown the less-valued portions of mammals and fish. And, as has been described, they also tended to contain poisonous levels of vitamin A in their own livers. On the other hand, low serum calcium levels or rickets are not reported by Wallace and Foulks as affecting these dogs, which may seem to detract from their hypothesis, but to strengthen mine. Of course, Inuit dogs could indeed have suffered hypocalcemia.

We have not dealt, except in passing, with the problems of data control, almost insurmountable except for Foulks' unique study, the only one dealing specifically with *pibloktoq* that includes detailed clinical, physiological, biochemical, psychological, sociological and cultural data. Nor have we examined the question of culture-specific vs universal emotional disorders in the human species. While the concept of 'culture-bound' syndromes is controversial, for the purposes of this paper *pibloktoq* has been accepted as an Inuit aberration, though it is obvious that it has much in common with similar behavioral disturbances elsewhere.

Clearly, given the conditions of contemporary Inuit life, it would not be easy to test the hypothesis of the *pibloktoq*-vitamin A link more systematically. An experimental design including a control group is ruled out since neither hypervitaminosis A nor hysteria can be predicted, and it would be difficult to assume that each individual Inuit would have an equal chance of contracting either condition. Indeed a high degree of individual variability and susceptibility has been argued here. Foulks' data suggest that *pibloktoq* was probably much more common in the past than presently, and that hysterical reactions have been largely supplanted by what some have termed 'diseases of civilization': alcoholism, schizophrenia and paranoia. Still, in a survey cited by Foulks [8, pp. 32-36] a treated prevalence of 5% conversion

hysterias and 21% 'anxiety neuroses' is shown for North Alaskan villages under 500 population, although it is not clear what proportion are in fact Inuits, and it is even less certain which, if any, of such cases could be labeled *pibloktoq*. Certainly if cases of *pibloktoq* could be identified, an inquiry might then be made regarding the occurrence in such persons of hypervitaminosis A, or at least a measure of the amount of vitamin A in the blood together with other medical tests.

Another possibility, though the evidence would be indirect, would be a study of Inuit skeletal material from the past, to estimate, as Walker *et al.* [84] have done, evidence of characteristic hypervitaminosis A bone lesions. Radiological and other measures could also be taken of the bones of living Inuits as well. And contemporary nutritional studies could be most helpful.

While the thrust of this study, as the earlier ones by Wallace and Foulks, is toward a multifactorial, synthetic theory of the arctic hysterias in general, and of *pibloktoq* in particular, I have not here developed such a model or attempted to apply those of my predecessors. This must be left for future consideration. What should be evident is that anthropology and medicine may profit by a biocultural approach to emotional disturbances. Indeed, anthropologists are uniquely qualified for the task. Thus, an attempt has been made to explain the facial paralysis in Comanche ghost sickness as having a biological, as well as psychogenic and cultural etiology, at least for some individuals [107]. And another anthropologist has cogently argued that Evans-Pritchard's interpretation of Azande witchcraft substance as 'nothing more than undigested food' may overlook the possibility that the Zande were in fact conveying to the anthropologist "the oncological description of a teratoma", a form of cancer [108].

REFERENCES

1. The arctic hysterias also include a type of echolalic, echopraxic reaction closely resembling *latah* in Southeast and Southwest Asia. See Yap P. M. The *latah* reaction: its pathodynamics and nosological position. *J. ment. Sci.* **98**, 515, 1952. While the present analysis excludes this variant, future consideration of a possible role for biochemical or physiological factors may be warranted. See also Refs [2-6, 14].
2. Aberle D. F. Arctic hysteria and *latah* in Mongolia. *Trans. N.Y. Acad. Sci.*, **14**, 291, 1952.
3. Czaplicka M. A. *Aboriginal Siberia: A Study in Social Anthropology*, pp. 307-325. Oxford University Press, London, 1914. Czaplicka suggests that 'arctic hysterias' is a misnomer since hysterical behaviors are found in so many different cultural settings. However, when she attempts to except the *latah*-like syndrome known in Siberia as *amurakh*, her argument, while containing some significant points, becomes somewhat uncertain. See also Kennedy J. G. Cultural psychiatry. In *Handbook of Social and Cultural Anthropology* (Edited by Honigsmann J.), pp. 1119-1198, especially pp. 1152-1156, 1165-1168. Rand, McNally, Chicago.
4. Jochelson W. The Koryak. *Mem. Am. Mus. Nat. Hist.* **XI**, E. J. Brill, Leiden, 1908. Also The Yukaghir and the Yukaghirized Tungus. *Mem. Am. Mus. Nat. Hist.* **IX**, E. J. Brill, Leiden, 1926.
5. Black L. The Nivkh (Gilyak) of Sakhalin and the Lower Amur. *Arctic Anthropol.* **10**, 1, 1973.
6. Bogoras W. The Chukchee. *Mem. Am. Mus. Nat. Hist.* **XI**, E. J. Brill, Leiden, 1909. References [4] and [6] are reprinted from reports of the Jesup North Pacific Expedition. References [3-6] comprise a small sample of a large literature on the Siberian peoples.
7. Wallace A. F. C. Mental illness, biology, and culture. In *Psychological Anthropology* (Edited by Hsu F. L. K.), revised edition, pp. 363-402. Shenkman, Cambridge, MA, 1972. An earlier version appeared in the first edition of the same work, published by the Dorsey Press, Homewood, IL, 1961.
8. Foulks E. F. *The Arctic Hysterias of the North Alaskan Eskimo*. Anthropological Studies, No. 10. American Anthropological Association, Washington, DC, 1972.
9. Wallace A. F. C. and Ackerman R. E. An interdisciplinary approach to mental disorder among the Polar Eskimos of Northwest Greenland. *Anthropologica* **11**, 1, 1960.
10. Preston R. J. The witiko: Aiglonkian knowledge and Whiteman knowledge. In *Manlike Monsters on Trial: Early Records and Modern Evidence* (Edited by Halpin M. J. and Ames M. M.), pp. 111-131. University of British Columbia Press, Vancouver, 1980. Also in the same volume, Fogelson R. D. Windigo goes south: Stoneclad among the Cherokees, pp. 111-131. Several contributions in this collection are relevant to the question of myth vs reality of culture-bound disorders. The fullest treatment in this regard will be found in Marano L. Windigo psychosis: the anatomy of an emic-etic confusion. *Curr. Anthropol.* **23**, 385, 1982.
11. Landy D. Medical anthropology: a critical appraisal. In *Advances in Medical Social Science* (Edited by Ruffini J. L.), Vol. 1, pp. 185-314. Gordon & Breach, New York, 1983.
12. Gussow Z. *Pibloktoq* (hysteria) among the Polar Eskimo: an ethnopsychiatric study. In *The Psychoanalytic Study of Society* (Edited by Muensterberger W. and Axelrod S.), Vol. 1, pp. 218-235. International Universities Press, New York, 1960. Contains several case histories of *pibloktoq*, including some previously unpublished ones based on interviews by Gitel Steed with Niels Rasmussen, son of Knud Rasmussen, the famous arctic explorer and trader. I am indebted to Dr Gussow for making a copy of the extensive Rasmussen-Steed interviews, as well as other materials and commentaries, available to me.
13. Kenny M. G. *Latah*: the symbolism of a putative mental disorder. *Cult. Med. Psychiat.* **2**, 209, 1978; Also *Paradox lost: the latah problem revisited*. *J. nerv. ment. Dis.* **117**, 159, 1983; and Simons R. C. The resolution of the *latah* paradox. *J. nerv. ment. Dis.* **168**, 195, 1980. See also Refs [1-3].
14. Peary R. E. *The North Pole*. Frederick A. Stokes, New York, 1910.
15. De Poncins G. *Kabloona*. Reynal & Hitchcock, New York, 1941.
16. Freuchen P. *The Book of the Eskimo*. Bramhall House, New York, 1961. (See also *Arctic Adventure: My Life in the Frozen North*. Farrar & Rinehart, New York, 1953).
17. Jenness D. *The Life of the Copper Eskimo*, Vol. XL, Part A. Report of the Canadian Arctic Expedition, 1913-1918. Ottawa, 1922.
18. Jenness D. *The People of the Twilight*. Macmillan, New York, 1928 (Reprinted by University of Chicago Press, 1959).
19. Holtved E. Contributions to Polar Eskimo ethnography. *Meddeleser om Grønland*, Vol. 182, No. 2. C. A. Reitzels Forlag, København, 1967.
20. Macmillan D. B. *Four Years in the White North*, revised edition. The Medical Society of America, Boston, 1925.
21. Maulaurie J. *The Last Kings of Thule: A Year Among*

- the Polar Eskimos (Translated by Freeman G.). Allen & Unwin, London, 1956.
22. Novakovsky S. Arctic of Siberian hysteria as a reflex of the geographic environment. *Ecology* 5, 113-127, 1924.
 23. Peary R. E. *Nearest the Pole*, 2 vols. Doubleday, Page, New York, 1907.
 24. Peary R. E. *Northward Over the Great Ice*, 2 vols. Methuen, London, 1898.
 25. Steensby H. P. Contributions to the ethnology and anthropogeography of the Polar Eskimos. *Meddeleser om Grønland*. XXXIV, 255-407, 1910.
 26. Stefansson V. *Arctic Manual*. Macmillan, New York, 1944.
 27. Rasmussen K. *Intellectual Culture of the Copper Eskimos*, Vol. 9. Report of the Fifth Thule expedition, 1921-1924. Copenhagen, 1932; *The Netsilik Eskimos: Social Life and Spiritual Culture*, Vol. 8. Report of Fifth Thule Expedition, 1921-1924. Copenhagen, 1931; *The People of the Polar North* (Edited by Herring G.). AMS Press, New York, 1976 (Originally published 1908).
 28. Rasmussen K. *Grønland. Foran Dagans Øje*, Vol. 1. Copenhagen, 1915.
 29. Weyer E. *The Eskimos: Their Environment and Folkways*. Yale University Press, New Haven, 1932.
 30. Whitney H. *Hunting with the Eskimos*. The Century, New York, 1910.
 31. Kane E. K. *Arctic Explorations in the Years 1853, 1854, 1855*, 2 vols. Childs & Peterson, Philadelphia, 1856.
 32. Hayes I. I. *An Arctic Boat Journey in the Autumn of 1854*, revised edition. Ticknor & Fields, Boston, 1868.
 33. Hall C. F. *My Life with the Esquimaux: The Narrative of Capt. Charles Francis Hall—29 May 1860 to 13 September 1862*, 2 vols. Sampson Low, Son & Marsden, London, 1864.
 34. Hayes I. I. *The Open Polar Sea: Narrative of a Voyage of Discovery Towards the North Pole*. Hurd & Houghton, New York, 1867.
 35. Kneely R. N. *In Arctic Seas: The Voyage of the "Kite"*. Rufus C. Hatranft, Philadelphia, 1893.
 36. Sutherland P. C. *Journal of a Voyage in Baffin's Bay and Barrow Straits in the Years 1850-1851*, 2 vols. Longman, Brown, Green & Longmans, London, 1852.
 37. Birket-Smith K. *Ethnography of the Egedesminde District*. Bianco Lunos Bogtrykkeri, København, 1924.
 38. Spencer R. F. *The North Alaska Eskimo: A Study in Ecology and Society*. Smithsonian Institution, Washington, DC, 1959.
 39. Freeman M. M. R. Personal communication.
 40. Degerbøl M. and Freuchen P. *Mammals*, Vol. II. Report of the Fifth Thule Expedition, 1921-1924. Copenhagen, 1935.
 41. Marks J. *The Vitamins in Health and Disease: A Modern Reappraisal*. Little, Brown, Boston, 1968.
 42. Barker B. M. and Bender D. A. *Vitamins in Medicine*, 4th edition, Vol. 2. William Heinemann Medical Books, London, 1982.
 43. So J. K. Human biological adaptation to arctic and subarctic zones. In *Annual Review of Anthropology* (Edited by Siegel B. J. et al.), Vol. 9, pp. 63-82. Annual Reviews, Palo Alto, 1980.
 44. Draper H. H. The aboriginal Eskimo diet. *Am. Anthropol.* 79, 309, 1977.
 45. Dyson J. *The Ho! Arctic*. Little, Brown, Boston, 1979.
 46. Chance N. *The Eskimos of North Alaska*. Holt, Rinehart & Winston, New York, 1966.
 47. Hughes C. Under four flags: recent culture change among the Eskimo. *Curr. Anthropol.* 6, 3, 1965. See also Klausner S. Z. and Foulks E. F. *Eskimo Capitalists: Oil, Politics, and Alcohol*. Totowa, NJ, 1982.
 48. Freeman M. M. R. Tradition and change: problems and persistence in the Inuit diet. In *Coping with Uncertainty in Food Supply* (Edited by de Garine I. and Harrison G. A.). Cambridge University Press, Cambridge. In press.
 49. Rodahl K. and Moore T. The vitamin A content and toxicity of bear and seal liver. *Biochem. J.* 37, 166, 1943.
 50. Cleland J. B. and Southcott R. V. Illnesses following the eating of seal liver in Australian waters. *Med. J. Aust.* 1, 760, 1969.
 51. Southcott R. V. Marine toxins. In *Handbook of Clinical Neurology* (Edited by Vinken P. J. and Bruyn G. W.), Vol. 37, Part II, pp. 27-106. North-Holland, Amsterdam, 1979.
 52. Southcott R. V., Chesterfield N. J. and Lugg D. J. Vitamin A content of the livers of huskies and some seals from Antarctic and Subantarctic regions. *Med. J. Aust.* 1, 311, 1971.
 53. Rodahl K. Hypervitaminosis A and scurvy. *Nature* 164, 531, 1949.
 54. Rodahl K. Toxicity of polar bear liver. *Nature* 164, 530, 1949.
 55. Vedder E. B. and Rosenberg C. Concerning the toxicity of vitamin A. *J. Nutr.* 16, 57, 1938.
 56. Maddock C. L., Wolbach B. and Maddock S. Hypervitaminosis A in the dog. *J. Nutr.* 39, 117, 1949.
 57. Bergin D. and Kiawans H. L. Vitamin A. In *Handbook of Clinical Neurology* (Edited by Vinken P. J. and Bruyn G. W.), Vol. 28, Part II, pp. 43-47. North Holland, Amsterdam, 1976.
 58. Sebrell W. H. Jr and Harris R. S. (Eds) *The Vitamins: Chemistry, Physiology, Pathology, Methods*, 2nd edition, Vol. 1. Academic Press, New York, 1967.
 59. Knaudson A. G. and Rothman P. E. Hypervitaminosis A: a review with a discussion of vitamin A. *Am. J. Dis. Child.* 85, 316, 1953.
 60. Moore T. *Vitamin A*. Elsevier, Amsterdam, 1957. The most comprehensive treatment of vitamin A and, while in need of updating, extremely useful.
 61. Devere G. *The Three Voyages of William Barents to the Arctic Regions (1594, 1595, 1596)*, 2nd edition (1st edition 1853). The Hakluyt Society, London (Reprinted, n.d., Burt Franklin, New York).
 62. White A. *A Collection of Documents of Spitzbergen and Greenland*. (originally published 1694, 1676). The Hakluyt Society, London (Reprinted n.d., Burt Franklin, New York).
 63. Cleland J. and Southcott R. V. Hypervitaminosis A in the Australian Antarctic expedition of 1911-1914: a possible explanation of the illnesses of Mertz and Mawson. *Med. J. Aust.* 1, 1137, 1969. The suffering and heroism of Mawson, a geologist-explorer, and Mertz, a Swiss ski champion, lawyer, and caretaker of the expedition's huskies, based upon diaries and reports, is told with dramatic force in Bickel L. *Mawson's Will: The Greatest Survival Story Ever Told*. Stein & Day, New York, 1977. Bickel cites biochemical evidence discovered in Australia in 1971 (reference unnamed) that the liver of the Greenland husky used by Mawson "revealed that four ounces of the dog liver contained a toxic dose of Vitamin A for an adult man". Since the average husky liver weights two pounds, and Mawson and Mertz shared the livers of six dogs, "between them [they] swallowed some 60 toxic doses of Vitamin A. It was an intake made all the more debilitating and dangerous by the lack of other normal foods that would transport the substance to excretion" (pp. 128-132). See also Shearman D. J. C. Vitamin A and Sir Douglas Mawson. *Br. med. J.* 1, 283, 1978.
 64. Josephs H. W. Hypervitaminosis A and carotemia. *Am. J. Dis. Child.* 67, 33, 1944.
 65. Morrice G. Jr, Havener W. H. and Kapetansky F.

- Vitamin A intoxication as a cause of pseudomotor cerebri. *J. Am. med. Ass.* 173, 1802, 1960.
66. Hofman K. J., Milne F. J. and Schmidt C. Acne, hypervitaminosis A, and hypercalcemia: a case report. *S. Afr. med. J.* 54, 579, 1978.
 67. Sulzberger M. B. and Lazar M. P. Hypervitaminosis A: report of a case in an adult. *J. Am. med. Ass.* 146, 788, 1951.
 68. Lonie T. C. Excessive vitamin A as a cause of food poisoning. *New Engl. J. Med.* 49, 680, 1950.
 69. Muenter D., Perry H. O. and Ludwig J. Chronic vitamin A intoxication in adults: hepatic, neurologic, and dermatologic complications. *Am. J. Med.* 50, 129, 1971.
 70. Shaw E. W. and Niccolo J. Z. Hypervitaminosis A: report of a case in an adult male. *Ann. intern. Med.* 39, 131, 1953.
 71. Russell R. N., Boyer J. L., Bagheri S. A. and Hruban Z. Hepatic injury from chronic hypervitaminosis A resulting in portal hypertension and ascites. *New Engl. J. Med.* 291, 435, 1974.
 72. Shaywitz B. A., Siegal N. J. and Pearson H. A. Megavitamins for minimal brain dysfunction. *J. Am. med. Ass.* 238, 1749, 1977.
 73. Frane B., Jackson C. E., Reynolds W. A. and Umphrey J. E. Hypercalcemia and skeletal effects in chronic hypervitaminosis A. *Ann. intern. med.* 80, 44, 1974.
 74. Di Benedetto R. J. Chronic hypervitaminosis A in an adult. *J. Am. med. Ass.* 201, 700, 1967.
 75. Haworth J. C. *et al.* The use and abuse of vitamin A. *Can. med. Ass. J.* 104, 521, 1971.
 76. Gerber A., Rabb A. P. and Sobel A. E. Vitamin A poisoning in adults. *Am. J. Med.* 16, 729, 1954.
 77. Furman K. I. Acute hypervitaminosis A in an adult. *Am. J. clin. Nutr.* 26, 575, 1973.
 78. Mahoney C. P., Margolis T., Knauss T. A. and Labbe R. F. Chronic vitamin A intoxication in infants fed chicken liver. *Pediatrics* 65, 893, 1980.
 79. Stimson W. H. Vitamin A intoxication in adults: report of a case with a summary of the literature. *New Engl. J. Med.* 265, 369, 1961.
 80. Bergen S. and Roels O. A. Hypervitaminosis A: report of a case. *Am. J. clin. Nutr.* 16, 265, 1965.
 81. Seibert J. J., Byrne W. J. and Golladay E. S. Development of hypervitaminosis A in a patient on long-term parenteral hyperalimentation. *Pediatr. Radiol.* 10, 173, 1981.
 82. Farrington K., Miller P., Varghese Z., Bailord R. A. and Moorhead J. F. Vitamin A toxicity and hypercalcemia in chronic renal failure. *Br. med. J.* 282, 1999, 1981.
 83. Eaton M. L. Chronic hypervitaminosis A. *Am. J. Hosp. Pharm.* 35, 1099, 1978.
 84. Walker A., Zimmerman M. R. and Leakey R. E. F. A possible case of hypervitaminosis A in *Homo erectus*. *Nature* 296, 1, 1982. I am indebted to Lawrence S. Greene for calling my attention to this research and to Alan Walker for discussing his work with me and making this paper quickly available.
 85. McClintock F. L. *The Voyage of the "Fox" in the Arctic Seas: A Narrative of the Fate of Sir John Franklin and his Companions*. Murray, London, 1859.
 86. Thornton H. R. *Among the Eskimos of Wales, Alaska 1890-93*, p. 212. Johns Hopkins University Press, Baltimore; Oxford University Press, London, 1931.
 87. Stefansson V. *The Friendly Arctic: The Story of Five Years in the Polar Regions*. Macmillan, New York, 1921 (Reprinted 1969 by Greenwood Press).
 88. Best G. *The Three Voyages of Martin Frobisher in Search of a Passage to Cathia and India by the North-West, 1576, 1578*. The Hakluyt Society, London, 1578 (Reprinted, n.d., Burt Franklin, New York).
 89. Gosch C. C. A. *Danish Arctic Expeditions 1605-1620*. The Hakluyt Society, London, 1897 (Reprinted n.d., Burt Franklin, New York).
 90. Zagorskin L. *Lieutenant Zagorskin's Travels in Russian America 1842-1944* (Edited by Michael H. N.). Arctic Institute of North America. University of Toronto Press, Toronto, 1967 (originally published 1847-1848).
 91. Balikci A. *The Netsilik Eskimo*. Natural History Press, Garden City, 1970.
 92. Boas, F. *The Central Eskimo*. Reprinted by University of Nebraska Press, Lincoln, 1964.
 93. Stefansson V. *My Life with the Eskimo*. Macmillan, New York, 1913; *The Stefansson-Anderson Arctic Expedition of the American Museum*. Preliminary Ethnology Report, Anthropological Papers, American Museum of Natural History, Vol. XIV, Part 1, 1-395, 1914.
 94. Veith I. *Hysteria: The History of a Disease*. Phoenix Books, University of Chicago Press, Chicago, 1965.
 95. Rosen G. *Madness in Society: Chapters in the Historical Sociology of Mental Illness*. Torchbooks, Harper & Row, New York, 1969.
 96. Haller J. S. Jr and Haller R. M. *The Physician and Sexuality in Victorian America*. University of Illinois Press, Urbana, 1974.
 97. Alexander F. G. and Selesnick S. T. *The History of Psychiatry*. Mentor Books, New American Library, New York, 1968.
 98. Freud S. On the psychical mechanism of hysterical phenomena, 1893; Some points in a comparative study of organic and hysterical paralysis, 1893; The justification of detaching from neurasthenia a particular syndrome; the anxiety neurosis, 1894; Heredity and the aetiology of the neuroses, 1896; The aetiology of hysteria, 1896. All reprinted in *Collected Papers*, Vol. I, Basic Books, New York, 1959.
 99. Breuer J. and Freud S. *Studies in Hysteria* (Translated by Brill A. A.), Beacon Press, Boston, 1950 (originally published 1895).
 100. Noyes A. P. *Modern Clinical Psychiatry*, 4th edition. W. B. Saunders, Philadelphia 1953.
 101. Malamud W. The psychoneuroses. In *Personality and the Behavior Disorders* (Edited by Hunt J. McV.), Vol. II, pp. 838-860. Ronald Press, New York, 1948.
 102. Parker S. Eskimo psychopathology in the context of Eskimo personality and culture. In *Culture, Disease, and Healing* (Edited by Landy D.), pp. 349-358. Macmillan, New York, 1977 (originally *Am. Anthropol.* 64, 76, 1960).
 103. Giffen N. M. *The Roles of Men and Women in Eskimo Culture*. University of Chicago Press, Chicago, 1930.
 104. Heller C. A. and Scott E. M. *The Alaska Dietary Survey 1956-1961*. Health, Education and Welfare, Washington, DC, no date.
 105. Brill A. A. Piblokto or hysteria among Peary's Eskimos. *J. nerv. ment. Dis.* 40, 514, 1913.
 106. Briggs J. L. *Never in Anger: Portrait of an Eskimo Family*. Harvard University Press, Cambridge, MA, 1970.
 107. Henderson J. N. and Ardour K. K. Comanche ghost sickness: a biocultural explanation. *Med. Anthropol.* 5, 195, 1981.
 108. Morinis E. A. The perils of anthropological misdiagnosis: a new look at Evans-Pritchard's theory of witchcraft. *L'Uomo (Rome)* VI, 345, 1982.

Case Report

Vitamin A toxicity secondary to excessive intake of yellow-green vegetables, liver and laver

Kazuki Nagai¹, Hiroo Hosaka¹, Shuichi Kubo¹, Takeshi Nakabayashi¹, Yasuhiro Amagasaki¹ and Noriko Nakamura²

Departments of ¹Internal Medicine and ²Pathology, Saiseikai Yokohama-shi Nanbu Hospital, Yokohama, Japan

We report a case of sudden onset of vitamin A poisoning. A 20-year-old Japanese woman had been eating pumpkin and only a very limited amount of other foods on a daily basis for 2 years. She was overly concerned about weight reduction. Aurantiasis cutis and abnormal liver function tests were noted by her family doctor in 1995 when she was 18 years old. At that time, she stopped eating pumpkin. However, she secretly continued an excessive intake of other beta-carotene-rich vegetables, liver and laver for about 2 years. Two and one-half years after being seen by her family physician, she experienced sudden onset of low-

grade fever, limb edema, cheilitis, dry skin, and headache. These symptoms worsened daily. A liver needle biopsy was performed, and it showed a normal portal tract along with fat-laden Ito cells in the space of Disse. A final diagnosis of vitamin A poisoning and hepatic injury secondary to an eating disorder was made. Her symptoms and serum beta-carotene levels returned to normal with successful adjustment of her diet.

Key words: Beta-carotene-rich; Hepatic injury; Hypercarotenemia; Laver; Liver; Vitamin A poisoning.

A RECENT advertisement encouraging high intake of yellow-green vegetables was distributed widely through the mass media in Japan. The Japanese people believe strongly that yellow-green vegetables are health-promoting foods with many benefits (1). In Japan, as in many industrialized countries, it is fashionable for young women to be thin. Most of them believe that a high intake of yellow-green vegetables is healthy and also that it is the best means of attaining or maintaining their desired body weight. Yellow-green vegetables are low in calories, their ingestion makes the skin beautiful, and they are thought to be harmless, but excessive intake can lead to toxicity. This is because the majority of yellow-green vegetables eaten are carrots, pumpkin, and other beta-carotene-rich vegetables, all containing vitamin A.

In the past, most cases of systemic and hepatic toxicity due to vitamin A resulted from excessive ingestion

of polar bear liver with its enormous quantities of vitamin A. This has been recognized for more than 50 years (2). The main clinical features of vitamin A poisoning are fever, anorexia, nausea, vomiting, headache, drowsiness, skin changes, and papilledema. To date, many cases of hepatic injury associated with the clinical use of vitamin A have been reported in the United States and Western Europe (3-5), but cases resulting from excessive intake of yellow-green vegetables are rare.

We report such a case of vitamin A poisoning and hepatic injury secondary to an eating disorder. To our knowledge, this is the first such case to be reported in Japan evidenced by liver needle biopsy.

Case Report

A 20-year-old Japanese woman had suffered from secondary amenorrhea from age 16 years. Her daily diet for several years comprised mainly pumpkin, both the flesh and the rind, with a little rice, red meat, and fish. She was preoccupied with weight reduction. In 1995, when she was 18 years old, aurantiasis cutis and abnormal liver function tests were noted by her family doctor. At that time, she stopped her intake of pumpkin.

Received 19 August 1998; revised 2 February; accepted 2 February 1999
 Correspondence: Kazuki Nagai, Department of Internal Medicine, Saiseikai Yokohama-shi Nanbu Hospital, 3-2-10, Koonan-ku, Yokohama City, Kanagawa, 233-8503, Japan. Tel: 81 45 832 1111. Fax: 81 45 832 8355.

TABLE 1
Laboratory data at admission

Hematology			
WBC	3800	(3500-9100)/mm ³	
Eos.	0.3	%	
RBC	311	(376-500)	×10 ⁶ /mm ³
Hb	10.3	(11.3-15.2)	g/dl
Ht	30.8	(33.4-44.9)	%
PLT	15.0	(13.0-36.9)	×10 ⁴ /mm ³
PT	78	(70-110)	%
HPT	77	(70-130)	%
ESR	24	(3-11)	mm/h
Serology			
CRP	3.46	(≤0.05)	mg/dl
IgG	859	(880-2090)	mg/dl
IgA	114	(92-406)	mg/dl
IgM	156	(52-315)	mg/dl
Thyroid functions			
TSH	1.03	(0.35-3.73)	μIU/ml
F-T ₃	2.0	(2.2-4.1)	pg/ml
F-T ₄	0.89	(0.81-1.67)	ng/dl
Blood chemistry			
Total bilirubin	0.5	(0.1-0.8)	mg/dl
Direct bilirubin	0.1	(0.0-0.3)	mg/dl
TTT	0.7	(0.2-4.6)	KU
ZTT	1.2	(4.2-12.2)	KU
AST	58	(≤32)	IU/l
ALT	41	(≤34)	IU/l
LDH	596	(250-440)	IU/l
ALP	163	(93-271)	IU/l
γ-GTP	45	(8-60)	IU/l
Total protein	5.8	(6.3-8.1)	g/dl
Albumin	3.9	(3.8-5.2)	g/dl
Total cholesterol	151	(125-233)	mg/dl
Triglyceride	30	(49-169)	mg/dl
Autoantibodies			
Anti-mitochondrial Ab	-	(-)	
Anti-nuclear Ab	-	(-)	
Anti-DNA Ab	-	(-)	

(-): normal range

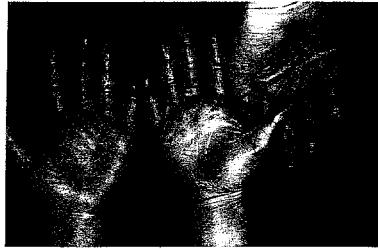

Fig. 1. *Aurantiias cutis*: the patient's skin appeared yellow-orange. (↓ on the right is that of a healthy volunteer).

Early in August 1997, she experienced sudden onset of low-grade fever, headache, and swelling of her fingers. She was admitted to our hospital in late August for

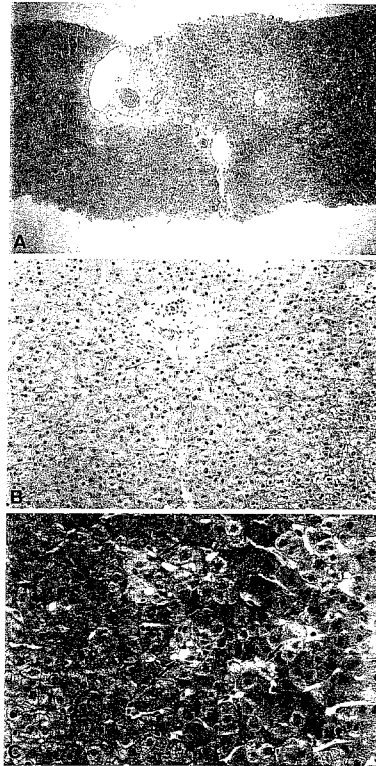


Fig. 5. Liver needle biopsy showed normal portal tracts and fat-laden Ito cells (arrows) in the space of Disse. Stained with (A, B) hematoxylin and eosin, and (C) Masson trichrome. (Original magnification A:×25, B:×50, C:×100.)

additional work-up. She was taking no recreational drugs or medications and had consumed no alcohol. She had never received a blood transfusion. No remarkable diseases were noted from her family history. On physical examination, she appeared somewhat poorly nourished, her height was 148 cm, her weight was 42 kg, and her body temperature was 37.4°C. Her conjunctiva appeared slightly pale but were not icteric. Her skin was severely discolored and appeared yellow-

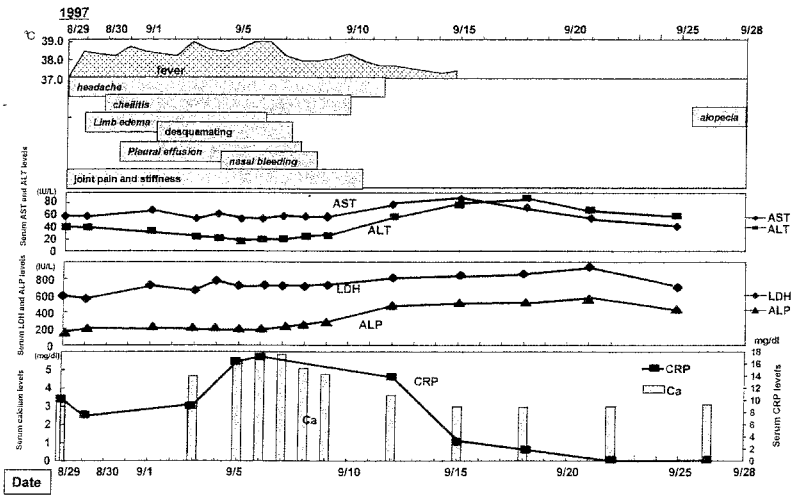


Fig. 2. Clinical course during hospitalization.

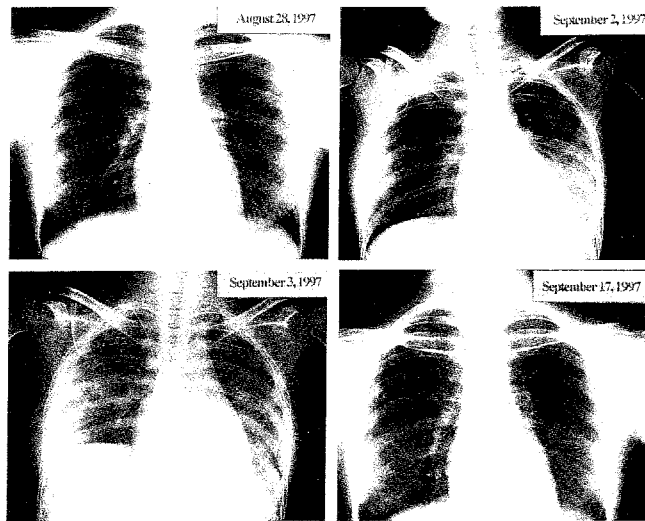


Fig. 3. Serial chest radiographs. Pleural effusion increased gradually.

orange (Fig. 1). Her chest and heart were normal, and there was no abdominal tumor or hepatosplenomegaly. Swelling was noted in her fingers bilaterally. A right cervical lymph node was palpable and was estimated to be approximately 15 mm in diameter. There was slight neck stiffness, but her neurological function was normal.

Laboratory data on admission were as follows. Hematological tests showed her white blood cell count at $311 \times 10^9/\text{mm}^3$, eosinophils at 0.3%, red blood cell count at $311 \times 10^9/\text{mm}^3$, hemoglobin at 10.3 g/dl, and ESR at 24 mm/h (normal 3–11 mm/h). Her serology showed C-reactive protein (CRP) 3.46 mg/dl (normal <0.5 mg/dl), and IgG 859 mg/dl (normal 880–2090 mg/dl), and thyroid functions showed thyroid stimulating hormone (TSH) 1.03 ($\mu\text{IU}/\text{ml}$) (normal 0.35–3.73 $\mu\text{IU}/\text{ml}$), free 3,5,3'-triiodothyronine (F-T₃) 2.0 pg/ml, free thyroxine (F-T₄) 0.89 ng/dl (normal 0.81–1.67 ng/dl). Her blood chemistry showed total bilirubin 0.5 mg/dl, aspartate aminotransferase (AST) 58 IU/l (normal <32 IU/l), alanine aminotransferase (ALT) 41 IU/l (normal <35 IU/l), lactic dehydrogenase (LDH) 596 IU/l (normal 250–450 IU/l), alkaline phosphatase (ALP) 163 IU/l (normal 93–271 IU/l), and triglyceride 30 mg/dl (normal 49–169 mg/dl). Other biochemical markers were within normal limits. Autoantibodies were all negative (Table 1). Viral markers were negative for anti-IgM antibody to hepatitis A (IgM-HAV-Ab), hepatitis B surface-Ag (HBs-Ag), and antibody to hepatitis C (HCV-Ab). Other viral markers were negative for anti-IgM antibody to Epstein-Barr virus (EBV), and cytomegalovirus (CMV), and antibody to measles, herpes-simplex virus, and mumps. Furthermore, serum hepatitis C viral RNA (HCV-RNA) was not detected.

During the clinical course (Fig. 2), her headaches became quite severe, and cheilitis developed soon after she was hospitalized. Her neck stiffness was mild. Clinical features suggested viral meningitis. Lumbar puncture was performed on hospital day 2 after admission, but her cerebrospinal fluid was normal. Her headache, nausea, and cheilitis worsened, and a high fever ensued. Skin desquamation, mouth ulceration, insomnia, somnolence, joint pain and stiffness developed on hospital day 4, and she could not take solids or liquid orally. On hospital day 5, her blood gas analysis showed: pH 7.472, PaO₂ 57.8 mmHg, PaCO₂ 44.7 mmHg, HCO₃ 32.6 mmol/l, base excess 8.8 mmol/l. Pleural effusion developed (Fig. 3) as well as ascites and hepatosplenomegaly by hospital day 7 (Fig. 4). Her neck stiffness became severe. Serum concentrations of AST, ALT, LDH, ALP, and CRP gradually increased, and calcium increased about two-fold by hospital day 10. Repeat lumbar puncture was per-

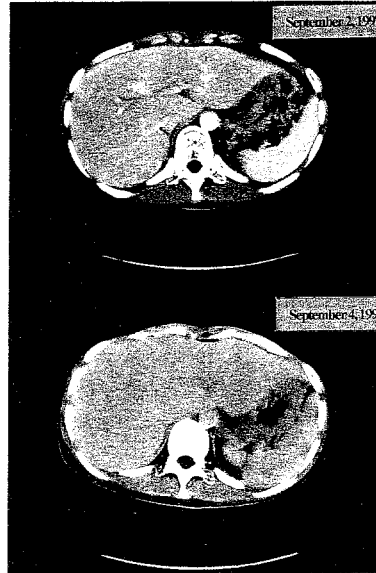


Fig. 4. Abdominal CT. Ascites and hepatosplenomegaly are seen on hospital day 7.

formed; cerebrospinal fluid was again normal. Brain CT and MRI revealed no ventricular enlargement or space-occupying lesion. Anti-viral agent, gamma-globulin, antibiotic, and hyperalimentation therapies were started, but there were no remarkable changes in her symptoms, hepatic transaminases, hemoglobin, or calcium levels. Her condition continued to worsen, and somnolence developed. We began to suspect that she was suffering from malignant lymphoma, since the origin of her fever was unknown, and laboratory data and the right cervical lymph node swelling were suspicious for this. Biopsy of the right cervical lymph nodes was performed, revealing sinus histiocytosis, a non-specific finding. After day 18, her symptoms began to subside, and she became more alert. She began oral intake of liquids and solid foods. However, alopecia developed suddenly on day 28. Liver needle biopsy was performed on day 29. The specimen showed normal portal tracts. Fat-laden Ito cells were seen in the space of Disse (Fig. 5). These clinical features were consistent

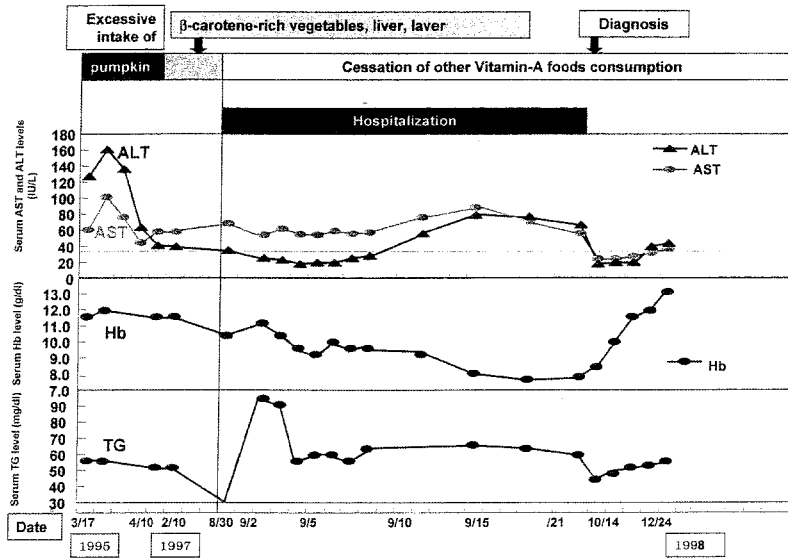


Fig. 6. Clinical parameters in relation to the patient's daily diet.

with vitamin A poisoning and hepatic injury secondary to an eating disorder. She was discharged on September 28.

On October 7, we again reviewed her history. She had stopped her excessive intake of pumpkin more than 2 years previously but had substituted for it an excessive intake of carrots, beta-carotene-rich vegetables, liver, and laver, still concerned with weight reduction (Fig. 6). Thus, the final diagnosis was vitamin A poisoning due to excessive intake of these foods, and hepatic injury related to an eating disorder. Her symptoms resolved as her diet was changed. She was instructed about maintaining a normal diet.

After discharge, her alopecia continued for about 6 months, but her general condition stabilized. Her body weight increased by 6 kg in 6 months. Just prior to discharge, her serum vitamin-A and beta-carotene levels were 681 ng/ml retinol (normal 410–1200 ng/ml) and 272 beta-carotene (normal ≤ 87.0 $\mu\text{g/dl}$).

During follow-up, serum vitamin-A levels showed almost no change and beta-carotene levels declined gradually to within normal limits. AST, ALT, hemo-

globin, TG, and CRP reached normal limits by the end of December. The patient has remained healthy, and menstruation resumed in January 1998 (Fig. 7).

Discussion

Excessive intake of the yellow-green vegetables can lead to vitamin A toxicity. This is because most of the yellow-green vegetables consumed are carrots, pumpkin, and other beta-carotene-rich vegetables, all containing vitamin A. Most cases of vitamin A poisoning are a result of excessive vitamin A supplementation, accidental ingestion of vitamin A, or improper vitamin A therapy (6–10). Vitamin A poisoning from excessive intake of yellow-green vegetables, liver, and laver is very rare indeed. In particular, vitamin A poisoning associated with an excessive intake of laver is extremely rare.

Laver (Nori) is a seaweed consumed in Japan, which contains approximately 250 $\mu\text{g/g}$ beta-carotene. Our patient ate about 10 to 20 g of Nori per day. The vitamin A content was about 1400 to 2800 IU per day. She ate other beta-carotene-rich vegetables daily as well.

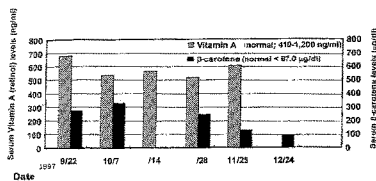


Fig. 7. Vitamin A (retinol) and β -carotene levels September 22 to December 24. On September 22, the patient's blood chemistry test showed retinol 681 ng/ml (normal 410–1200 ng/ml), β -carotene 272 μ g/dl (normal \leq 87.0 μ g/dl). Retinol levels were nearly unchanged, but β -carotene levels gradually declined to within normal limits with decreased intake of yellow-green vegetables, liver, and liver.

Hypercarotenemia causes yellow-orange pigmentation of the skin. This pigmentation has earlier been described under the names "aurantiasis" and "carotenosis" cutis. It is primarily a result of elevation of vitamin A active carotenoids, especially beta-carotene (11). In this case, although the serum beta-carotene level was high, serum retinol levels were almost within normal limits. In other severe cases reported, serum retinol levels were also normal (6). This may be partly due to impaired synthesis of the transport proteins, retinol binding protein, and transthyretin, and possibly also to impaired hepatic release of vitamin A (12). Additionally, although some 60–70% of dietary beta-carotene is converted into retinol in the human gut, excess beta-carotene intake does not cause hypervitaminosis A. This is mainly due to the inhibition of vitamin A production from beta-carotene when dietary intake of beta-carotene is high. When beta-carotene is not converted into retinol, it is taken up unchanged by the intestine. As a result, beta-carotene is generally recognized as a safe nutrient and dietary supplement for humans (13).

In this case, the final diagnosis was vitamin A poisoning due to excessive intake of these foods with resultant hepatic injury associated with the eating disorder. However, two important questions remain. The first is why the patient's symptoms developed acutely under the condition of chronic toxicity. The toxic potential of retinoids may be dramatically affected by simultaneous exposure to other toxic substances. Examples of conditions enhancing vitamin A toxicity are the consumption of alcohol, a low protein intake and possibly a high intake of other fat-soluble vitamins such as E and perhaps D. The threshold for vitamin A toxicity may also be lowered by liver diseases such as

viral hepatitis (9,13). Another factor involved in vitamin A toxicity is age. Elderly persons may have quite a tolerance for high retinoid intake, whereas children can be intoxicated by low amounts (13). Therefore, a partial explanation for our patient's acute onset might have been her age, secondary to the eating disorder. Another explanation might be an unknown virus, which did not seem to affect the liver, since there was no liver failure. We ruled out only HAV, HBV, HCV, EBV, CMV, Herpes simplex, measles, and mumps.

The second issue was whether her hepatic injury was caused directly by vitamin A or by her eating disorder. Ascites and hepatomegaly developed acutely within just a few days. Liver needle biopsy showed fat-laden Ito cells in the space of Disse. These clinical features suggest hepatic injury caused by vitamin A. In vitamin A poisoning, liver function test abnormalities are non-specific, and there are minor elevations of AST and ALT as well as a slight increase in ALP (13). Moreover, common effects of vitamin A poisoning in the human liver include hepatomegaly due to numerous, enlarged fat-storing cells, resulting in portal hypertension, with obstruction of blood flow in the sinusoids and obliteration of the space of Disse (13–15). There are also minor elevations of AST and ALT with eating disorders. Therefore, there is evidence that her hepatic injury was caused by vitamin A and possibly by other aspects of her eating disorder.

The patient has remained healthy. But a strict follow-up will be necessary, because vitamin A overdose can also give rise to an insidious development of cirrhosis, which does not regress after withdrawal of vitamin A (16).

Our experience with this patient was instructive from both a clinical and a public health perspective. The excessive intake of vitamin A-rich foods and juices should be addressed publicly and recognized as potentially hepatotoxic. This case highlights the need for greater educational efforts to prevent the consumption of excessive amounts of these foods.

References

1. Shekelle RS, Lepper M, Liu Shuguey. Dietary vitamin-A and risk of cancer in the Western Elstiric Study. *Lancet* 1981; 28: 1185–90.
2. Rodahl E, Moore T. The vitamin A content and toxicity of bear and seal liver. *Biochem J* 1943; 33: 2741–49.
3. Elias PM, Williams ML. Retinoids, cancer, and the skin. *Arch Dermatol* 1981; 117: 160–80.
4. Stimson WH. Vitamin A intoxication in adults. Report of a case with a summary of the literature. *N Engl J Med* 1961; 265: 369–73.
5. Josephs HW. Hypervitaminosis A and carotenemia. *Am J Dis Child* 1944; 67: 33–43.
6. Leo MA, Lieber CS. Hypervitaminosis A. *Hepatology* 1988; 8: 412–17.

K. Nagai et al.

7. Kransinski SD, Russell RM, Otradovec CL, Sadowski JA, Hartz SC, Jacob RA, et al. Relationship of vitamin A and vitamin E intake to fasting plasma retinol, retinol-binding protein, retinyl esters, carotene, alpha-tocopherol, and cholesterol among elderly people and young adults: increased plasma retinyl ester among vitamin A supplement users. *Am J Clin Nutr* 1989; 49: 112-20.
8. Herbert V. Toxicity of 25,000 IU vitamin A supplements in health food users. *Am J Clin Nutr* 1982; 36: 185-6.
9. Hathcock JN, Hartzan DG, Jenkins MV, McDonald JT, Ramnathan Sundaresan P, Wilkening VL. Evaluation of vitamin A toxicity. *Am J Clin Nutr* 1990; 52: 183-202.
10. A de Francisco K, Zaman, HR, Chowdhury, Wakid MA, Chakraborty J, Yunus Mohamed. Accidental ingestion of vitamin A. *Tropical Doctor* 1995; 25: 187.
11. Cutran CJ, Eriman JW, Nelson RA. Alteration in vitamin A and thyroid hormone status in anorexia nervosa and associated disorders. *Am J Clin Nutr* 1985; 42: 1183-91.
12. Geoffrey CF. Hypervitaminosis A. In: *Drug-induced hepatic fibrosis and cirrhosis. Drug-Induced Liver Disease* 1994; 19: 445-52.
13. Hendriks HFJ, Bosma A, Brouwer A. Fat-storing cells: hyper- and hypovitaminosis A and the relationships with liver fibrosis. *Semin Liver Dis* 1993; 13: 72-80.
14. Russell RM, Boyer JL, Bagheri SA, Hruban Z. Hepatic injury from chronic hypervitaminosis A resulting in portal hypertension and ascites. *N Engl J Med* 1974; 291: 435-40.
15. Hruban Z, Russell RM, Boyer JL, Glasgow S, Bagheri SA. Ultrastructural changes in livers of two patients with hypervitaminosis A. *Am J Pathol* 1974; 76: 451-66.
16. Geubel AP, Gaiogey C, Dive G, Rahier J, Alves N. Liver damage caused by therapeutic vitamin A administration: estimate of dose-related toxicity in 41 cases. *Gastroenterology* 1991; 100: 1701-9.

L. E. Grissom
G. C. Griffin
G. A. Mandell

Hypervitaminosis A as a complication of treatment for neuroblastoma

Received: 9 May 1995
Accepted: 21 June 1995

L. E. Grissom (✉) · G. A. Mandell
Department of Medical Imaging, Alfred I. duPont Institute, 1600 Rockland Road, Wilmington, DE 19803, USA

G. C. Griffin
Department of Pediatrics, Division of Hematology/Oncology, Alfred I. duPont Institute, Wilmington, Delaware, USA

Abstract A case of hypervitaminosis A (HVA) as a complication of therapy for stage-IV neuroblastoma is presented. The patient was randomized to a trial of 13-*cis*-retinoic acid (a vitamin A-related compound) after completing routine chemotherapy. This acid was given as a means of maturing potential minimal residual disease. A routine follow-up bone scan re-

vealed areas of increased activity, initially along the midshaft of the right ulna and subsequently bilaterally, which were ultimately found to be due to HVA. Hypervitaminosis A has not been previously reported in this setting, and awareness of the condition is important in centers where this treatment is contemplated.

Introduction

Chronic HVA in pediatric patients is a rare condition which usually results from unintentional overdosing by parents or caretakers [1]. Occasionally, dietary custom (e.g., Eskimos) results in ingestion of foods with a high content of vitamin A such as bear, shark, or seal liver [2]. Hypervitaminosis A has also been reported in older patients as a consequence of the use of isotretinoin for the treatment of dermatologic conditions such as cystic acne and ichthyosis [3]. We present a case of a young boy being treated with 13-*cis*-retinoic acid for stage-IV neuroblastoma. A routine bone scan in this patient showed increased activity in the ulnar shafts.

Case report

A 4-year-old boy¹ presented with pelvic and adrenal soft tissue masses as well as osseous lesions. His bone marrow also showed evidence of neuroblastoma. He was diagnosed with neuroblastoma stage IV and was treated with chemotherapy on Children's Cancer Group protocol 3891 for high-risk neuroblastoma. During induc-

tion, he received a total of five cycles of chemotherapy with cisplatin, etoposide, doxorubicin, and cyclophosphamide. After the fourth cycle, he had second-look surgery.

After completion of the fifth induction cycle he started consolidation (cisplatin, etoposide, doxorubicin, and ifosfamide with methotrexate). After consolidation he was felt to be grossly tumor free and was randomized to receive biotherapy with 13-*cis*-retinoic acid. This biotherapy consisted of six (14-day) cycles at a dose of 80 mg/m² per dose (doses were given twice a day). The patient received only five cycles of this therapy because of the toxicity noted in this case report. Three months after starting 13-*cis*-retinoic acid therapy, a routine bone scan was performed. This scan showed focal increased activity along the shaft of one ulna and linear increased activity on the contralateral side (Fig. 1). He also had dry, scaly skin. There was no history of trauma, and radiographs were normal. The appearance was felt to be atypical of metastasis, which would tend to be patchy or focal as opposed to linear, and a follow-up bone scan 1 month later was recommended. The second bone scan demonstrated increased activity along the shafts of both ulnae, more linear in appearance than on the first scan (Fig. 2). Correlative radiographs revealed fine periostitis bilaterally (Fig. 3). At this time, the possibility of HVA was considered, and treatment with 13-*cis*-retinoic acid was discontinued. A subsequent bone scan showed decreasing activity, confirming the diagnosis of HVA (Fig. 4).

¹ This patient was treated on Children's Cancer Group protocol no. 3891.

Fig. 1 Bone scan shows focal increased activity in midshaft, left ulna, and linear increased activity in distal right ulna

Fig. 2 Repeat bone scan after 1 month shows increased activity along both ulnar shafts (arrowhead injection activity)

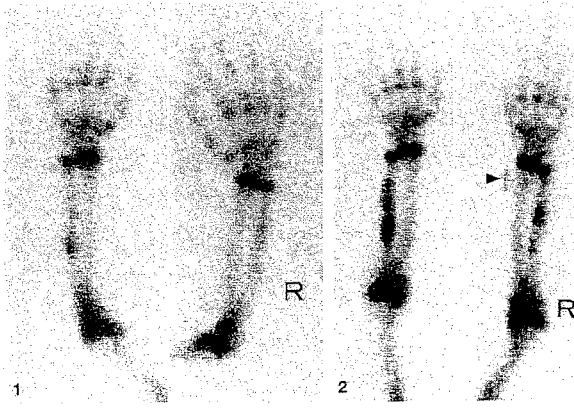
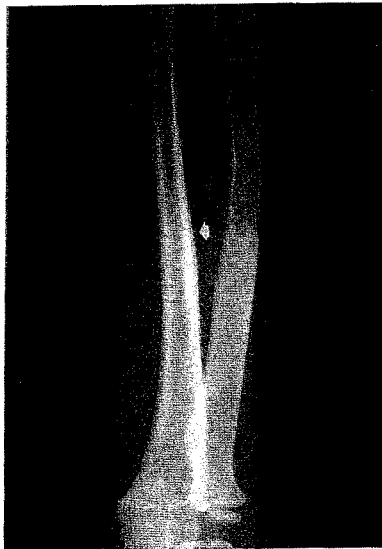

Fig. 3 Radiograph of the forearm performed after the second bone scan shows periosteal reaction along the shaft of the left ulna (arrowhead)



Discussion

Hypervitaminosis A can be acute or chronic. Acute toxicity is characterized by nausea, vomiting, and signs of increased intracranial pressure. The only radiographic manifestation is transient splitting of the sutures, and the withdrawal of the vitamin A rapidly reduces the effects.

Chronic HVA presents clinically with anorexia, pruritus, desquamation of skin, lip fissuring, stiffness or bone pain, soft tissue nodules over the extremities, alopecia, hepatosplenomegaly, and digital clubbing. Increased intracranial pressure and splitting of the sutures has also been reported [4]. Radiographically, the most common manifestation is ulnar periostitis. This is followed in order of decreasing frequency by periostitis of the metatarsals, clavicles, tibiae, and fibulae [3]. Scintigraphy has been shown to be more sensitive than radiography in the early detection of HVA, demonstrating increased activity in the same distribution [6]. Hypervitaminosis A has to be differentiated from Caffey disease (infantile cortical hyperostosis) in infants. Infantile cortical hyperostosis usually occurs during the first 4 months of life and almost always includes the mandible, in contrast to HVA, which usually involves the ulnae and metatarsals and occurs after 12 months of age. The vitamin A effect is thought to be due to activation or release of cell proteases which destroy extracellular cartilage matrix [7]. The end plates of the bones can prematurely fuse, with central tethering or cupping [8].

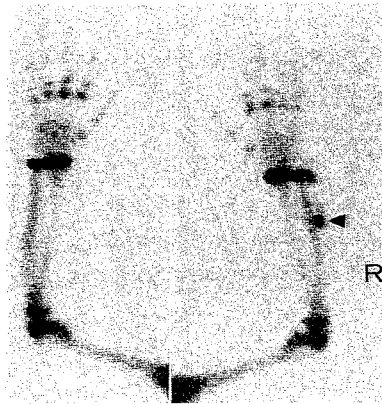


Fig. 4 Follow-up bone scan performed after withdrawal of vitamin A shows normalization of activity in the ulnae. (arrowhead injection activity)

Vitamin A toxicity is usually caused by misguided increased administration of the vitamin (more is better!) or liver ingestion (dietary custom). We report an iatrogenic case of vitamin A toxicity in a patient receiving biotherapy for neuroblastoma. Physicians should be aware of the complication of HVA. Radiologists can be helpful in recognizing the radiographic signs (periostitis and metaphyseal cupping) of HVA. It is important to differentiate this problem from bone metastases in neuroblastoma.

References

1. Caffey J (1950) Chronic poisoning due to excess of vitamin A. Description of the clinical and roentgen manifestations in seven infants and young children. *Pediatrics* 5: 672-687
2. Rodahl K, Moore T (1943) The vitamin A content and toxicity of bear and seal liver. *Biochem J* 37: 166-168
3. Pittsley RA, Yoder FW (1983) Skeletal toxicity associated with long-term administration of 13-*cis*-retinoic acid for refractory ichthyosis. *N Engl J Med* 308: 1012-1014
4. Siegel NJ, Spackman TJ (1972) Chronic hypervitaminosis A with intracranial hypertension and low cerebrospinal fluid concentration of protein. Two illustrative cases. *Neurology* 11: 580-584
5. Resnick D (1988) Hypervitaminosis and hypervitaminosis. W.B. Saunders, Philadelphia, pp 3091-3101
6. Miller JH, Hayon II (1985) Bone scintigraphy in hypervitaminosis A. *AJR* 144: 787-788
7. Dingle JT, Lucy JA, Fell HB (1961) Studies on the mode of action of excess of vitamin A. Effect of excess of vitamin A on the metabolism and composition of embryonic chick-limb cartilage grown in organ culture. *Biochem J* 79: 497-500
8. Ruby LK, Mital MA (1974) Skeletal deformities following chronic hypervitaminosis A. A case report. *J Bone Joint Surg [Am]* 56: 1283-1287

Dr. Bull's post hearing response

Nonclinical studies submitted to NDA 18-662 included studies of isotretinoin, the active ingredient in Accutane, which is a metabolite of vitamin A. Studies in rats were conducted for four weeks, thirteen weeks, and two years. Studies in dogs were conducted for thirteen and 55 weeks. Clinical signs were monitored in each of these studies, and neurological examinations were performed in the two-year rat study and the 55-week dog study. The highest doses in each study were five or more times the equivalent of the human clinical dose.

There was no report of abnormal behavior in any of these studies. There were no abnormal signs reported that were attributable to central nervous system dysfunction. No abnormal microscopic pathology findings were noted in the central nervous system, except for single foci of encephalomalacia (softening in the brain) in two of five high dose (60 mg/kg) dogs and one of six mid-dose (20 mg/kg) dogs in the 55-week study at an interim sacrifice at 30 weeks. No such findings were observed in the pathological examination of animals in that study at 55 weeks.